

Problem-based learning in dentistry: Diagnostic capability of dentists in the detection of calcified carotid artery atheroma on digital panoramic radiographs

Aprendizagem baseada em problemas em odontologia: capacidade diagnóstica de dentistas na detecção de ateromas calcificados da artéria carótida em radiografias panorâmicas digitais

Aprendizaje basado en problemas en odontología: capacidad diagnóstica de los dentistas en la detección del ateroma calcificado de la arteria carótida en radiografías panorámicas digitales

Received: 11/20/2020 | Reviewed: 11/21/2020 | Accept: 11/26/2020 | Published: 12/01/2020

Beatriz Caio Felipe

ORCID: <https://orcid.org/0000-0001-7286-8712>

Universidade Estadual de Maringá, Brazil

E-mail: beatrizfelipe10@hotmail.com

Fernanda Chiguti Yamashita

ORCID: <https://orcid.org/0000-0002-1053-2559>

Universidade Estadual de Maringá, Brazil

E-mail: nandayamashita@gmail.com

Amanda Lury Yamashita

ORCID: <https://orcid.org/0000-0001-8322-2060>

Universidade Estadual de Maringá, Brazil

E-mail: amandayamashita@gmail.com

Ana Carolina Caio Passoni

ORCID: <https://orcid.org/0000-0003-1038-5226>

Universidade Estadual de Maringá, Brazil

E-mail: accpassoni@hotmail.com

Breno Gabriel da Silva

ORCID: <https://orcid.org/0000-0002-8322-9235>

Universidade de São Paulo, Brazil

E-mail: omatematico.breno@gmail.com

Elen de Souza Tolentino

ORCID: <https://orcid.org/0000-0002-4352-4694>

Universidade Estadual de Maringá, Brazil

E-mail: estolentino2@uem.br

Mariliani Chicarelli

ORCID: <https://orcid.org/0000-0002-0024-7471>

Universidade Estadual de Maringá, Brazil

E-mail: mchicarelli@uem.br

Lilian Cristina Vessoni Iwaki

ORCID: <https://orcid.org/0000-0002-1822-3056>

Universidade Estadual de Maringá, Brazil

E-mail: lilianiwaki@gmail.com

Abstract

Objective: The aim of this study was to evaluate the diagnostic capability of dentists in the identification of suggestive images of calcified carotid artery atheroma (CCAA) on panoramic radiographs (PRs) before and after using a problem-based learning method (PBL). **Methodology:** Five dentists (no specialists in oral and maxillofacial radiology) analyzed 102 digital PRs divided into: PRs with suggestive images of CCAA (n=51) and without suggestive images of CCAA (n=51). After the first analysis, the examiners attended an activity on soft tissue calcifications using the PBL method. Afterwards, they analyzed the 102 PRs again. The results of the analysis were calculated using the Cohen's Kappa Test and the Receptor Operational Characteristic Curves (ROC). **Results and Discussion:** Regarding examiners' performance before and after the activity, the intra-examiner test showed reasonable Kappa coefficients (0-0.40). For inter-examiner agreement after the activity, the Kappa coefficient was almost perfect (> 0.80). When comparing examiners' performance after the activity with a template performed by an experienced radiologist, the Kappa Coefficient was > 0.80 with significant agreement (p<0.05). **Conclusion:** The precision and the probability of correctly detecting suggestive images of CCAA on PRs increased when the examiners participated in the active pedagogical method. The continuing education of the dentist and how it can make a difference in the systemic health of patients should be considered.

Keywords: Radiography panoramic; Plaque; Atherosclerotic; Data Accuracy; Problem-based learning method; Teaching.

Resumo

Objetivo: O objetivo deste estudo foi avaliar a capacidade diagnóstica de dentistas na identificação de imagens sugestivas de ateromas calcificados da artéria carótida (ACAC) em radiografias panorâmicas (RPs) antes e depois um método de aprendizagem baseado em problemas (PBL). **Metodologia:** Cinco cirurgiões-dentistas (não especialistas em radiologia oral e maxilofacial) analisaram 102 RPs digitais divididas em: RPs com imagens sugestivas de ACAC (n = 51) e sem imagens sugestivas de ACAC (n = 51). Após a primeira análise e registro dos resultados, os examinadores participaram de uma palestra sobre calcificações em tecidos moles utilizando o método PBL. Posteriormente, eles analisaram as 102 RPs novamente. Os resultados da análise foram calculados por meio do Teste Kappa de Cohen e Curvas de Característica Operacional do Receptor (ROC). **Resultados e Discussão:** Em relação ao desempenho dos dentistas antes e após a atividade, o teste intra-examinador apresentou coeficientes Kappa razoáveis (0-0,40). Para a concordância interexaminador após a atividade, o coeficiente Kappa foi quase perfeito (>0,80). Ao comparar o desempenho dos examinadores após a atividade com um gabarito realizado por um radiologista experiente, o Coeficiente Kappa foi >0,80 com concordância significativa ($p < 0,05$). **Conclusão:** A precisão e a probabilidade de detecção correta de imagens sugestivas de ACAC na RP aumentaram quando os examinadores foram submetidos a um método pedagógico ativo. Deve-se levar em consideração a educação continuada do cirurgião-dentista e como ela pode fazer a diferença na saúde sistêmica dos pacientes.

Palavras-chave: Radiografia panorâmica; Aterosclerose; Problem-based learning method; Ensino.

Resumen

Objetivo: El objetivo de este estudio fue evaluar la capacidad diagnóstica de los dentistas en la identificación de las imágenes sugerentes de ateroma calcificado de la arteria carótida (ACAC) en radiografías panorámicas (RPs) antes y después de utilizar un método de aprendizaje basado en problemas (PBL). **Metodología:** Cinco dentistas (no especialistas en radiología oral y maxilofacial) analizaron 102 RPs digitales divididas en: RPs con imágenes sugerentes de ACAC (n = 51) y sin imágenes sugerentes de ACAC (n = 51). Después del primer análisis, los examinadores asistieron a una actividad sobre calcificaciones de tejidos blandos utilizando el método PBL. Posteriormente, analizaron nuevamente las 102 RPs. Los resultados del análisis se calcularon utilizando la prueba Kappa de Cohen y las curvas características operativas del receptor (ROC). **Resultados y Discusión:** En cuanto al desempeño de los examinadores antes y

después de la actividad, la prueba intra-examinador presentó coeficientes Kappa razonables (0-0,40). Para la concordancia entre examinadores después de la actividad, el coeficiente Kappa fue casi perfecto (> 0.80) Al comparar el desempeño de los examinadores después de la actividad con un modelo realizado por un radiólogo experimentado, el coeficiente Kappa fue > 0.80 con concordancia significativa ($p < 0.05$). Conclusión: La precisión y probabilidad de detectar correctamente imágenes sugerentes de ACAC en RPs aumentó cuando los examinadores se sometieron a un método pedagógico activo. Se debe tener en cuenta la educación continua del dentista y cómo puede marcar una diferencia en la salud sistémica de los pacientes.

Palabras clave: Radiografías panorámicas; Problem-based learning method; Aterosclerosis; Enseñanza.

1. Introduction

Heart disease and stroke are the two most common causes of death worldwide. In 2017, 17.7 million people died of heart disease, of which 6.7 million died from stroke (World Health Organization, 2017). Ischemic stroke is caused by atherosclerosis, which is a chronic inflammatory disease characterized by the narrowing and loss of elasticity of blood vessels, in which fat deposits, called atheromas, adhere to the inner layers of the arteries, reducing blood flow (Wakabayashi, 2010). Calcified atheromas start to form after the deposition of small crystals of cholesterol that grow (in size and volume), leading to increased calcium deposition and production of fibrous tissue by fibroblasts. This causes hardening of the arteries and results in the formation of the calcified carotid artery atheromas (CCAAs) (Bayram et al., 2006).

These calcifications can be incidentally identified in dental imaging exams, such as panoramic radiographs (PRs). It is called an incidental finding since this radiograph is not indicated for this purpose. However, it can be an important tool for early diagnosis atherosclerotic disease. For dentists and patients, there is no additional effort as this type of radiography is part of daily clinical practice (American Dental Association, 2004; American Dental Association Council on Scientific Affairs, 2006). In PRs, suggestive images of CCAAs are described as nodular and heterogeneous masses, independent of the hyoid bone and epiglottis, located below, above or between the spaces of the intervertebral discs C3 and C4 or at an angle of 45° with the angle of the mandible (MacDonald et al., 2012; Roldán-Chicano et al., 2006). However, some radiopacities such as calcified triticeal cartilage and the superior

horn of a calcified thyroid cartilage can be confused with CCAAs (Carter, 2000; Kamikawa, 2009).

The thyroid cartilage is a hyaline cartilage that shows a physiological process of calcification with advancing age. In PRs, it can be seen as a vertical calcification approximately 4 mm wide and 15 mm long, medial to the image of the C4 vertebra (Carter, 2000; Kamikawa, 2009). On the other hand, the triticeal cartilage is the smallest cartilage in the laryngeal skeleton, usually appearing in PRs as a round calcification within the pharyngeal air space and adjacent to C3 or C4, approximately 3 mm wide and 7 mm long (Carter, 2000). It is also hyaline and shows the same physiological process of calcification with advancing age (Carter, 2000). No treatment is needed for these calcifications. However, patients with CCAAs need further medical attention to avoid ischemic strokes (Ertas & Sisman, 2011).

As shown, calcifications in the soft tissues of the neck can be seen in the PRs favoring the early diagnosis of heart and vascular diseases. However, many dentists are unaware of the appearance of these alterations in imaging exams and this screening is not part of the routine of most of them. This work discusses the importance of continuing education for dentists and how it can make a difference in patients' systemic health. The study was conducted using a problem-based learning method (PBL) on soft tissue calcification in PRs and evaluated the diagnostic capability of dentists in the identification of CCAA suggestive images on PRs before and after using this method.

2. Methodology

This retrospective and observational study was approved by the local Committee on Ethics in Research Involving Human Beings of State University of Maringá (UEM) (CAAE: 15847019.7.0000.0104).

CCAAs were investigated in all PRs of Brazilian patients admitted to the University's Oral and Maxillofacial Radiology Sector (UEM) between March and July 2018, totaling 2.022 exams performed for several reasons (65 (63.72%) female; 37 (36.28%) male) aged between 18 and 90 years (65.34 ± 8.61 years). All PRs were performed by the same specialist in Oral and Maxillofacial Radiology using the Orthopantomograph[®] OP300 (Instrumentarium, Finland), with a standardized protocol (66 kVp, 8-10 mA, 16 seconds). Patients remained upright during scanning and were positioned with the Frankfort horizontal plane parallel to the ground and the midsagittal line perpendicular to the ground. Patients were instructed to keep their tongue on the palate with closed lips, breathing lightly and without swallowing. The PRs

images were saved in JPEG (Joint Photographics Experts Group) extension in CLINIVIEW™ 10.2.6 software.

The diagnosis of CCAA suggestive images was performed by an experienced specialist in Oral and Maxillofacial Radiology, resulting in 51 PRs. Likewise, 51 PRs without any calcifications (control group) were selected to pair the sample, totaling 102 RPs. CCAA suggestive images were considered when calcifications were located immediately below, above or between the spaces of C3 and C4 or at an angle of 45 degrees with the angle of the mandible (Figure 1) (Monteiro et al., 2018).

General dentists, with no master's/doctorate, specialization or postgraduate studies in Oral and Maxillofacial Radiology were considered. For this, the graduates (last five years) of the undergraduate course in Dentistry at the university (UEM) were contacted through their records and an invitation to participate in the research was sent by email. Some did not return our contact, others refused to participate, and some had a graduate degree in Radiology and therefore were excluded from the sample. Finally, five dentists voluntarily agreed to participate in the research and signed the consent form.

The 102 images and instructions were shared with the participants through a cloud storage service. Examiners were instructed to analyze images in a semi-dark and quiet room and to take breaks between analysis to avoid eye fatigue. They were instructed not to seek help on the internet, in textbooks or with other colleagues. They had access to all images for a period of one month, when the results of this first analysis were recorded. The one-month deadline was given as there were a large number of PRs and the examiners had no experience with radiology. In addition, each volunteer did not have access to the data or knew the identity of the other participants in order to avoid communication. Also, the radiographs were randomly numbered for each examiner. Finally, the deadline was extended to respect the routine of each volunteer.

Fifteen days later, a resident of oral and maxillofacial radiology gave a lecture and training on soft tissue calcifications detected in PRs to all examiners. Special attention was paid to the CCAAs. The pedagogical method used was the PBL, which is a technique that situates learning in a problem-solving context, where students learn by solving problems and reflecting on them (Tamblyn & Se, 1981). This was done in approximately 4 hours, in person.

Finally, all examiners analyzed the 102 PRs again following the same guidelines as the first assessment. The same deadline for the evaluation was established, counting from the PBL activity. The performance of the examiners was then compared to a template developed by the experienced radiologist who performed the first evaluations.

Statistical analysis

In order to identify possible differences in the prevalence of CCAA suggestive images between sex and age groups, the Chi-Square test was used. Cohen's Kappa Test was applied to test intra and inter-examiner calibration. Receptor Operational Characteristic Curves (ROC) evaluated the examiners performance in diagnosing suggestive CCAA on PRs after the activity. The performance of the examiners after the activity was compared with the radiologist's template using Cohen's Kappa Coefficient. All statistical tests were performed with the R 3.6.2 software (R., Auckland, NZL) at a 5% level of significance ($p < 0.05$).

3. Results and Discussion

The prevalence of CCAA suggestive images according to sex is showed in table 1. Although no statistically significant differences were found between unilateral (right/left sides) and bilateral cases in reference to sexes, women were more affected. Individuals with > 60 years were also more affected, despite no statistically significant differences being found (Table 2).

Table 1. Prevalence of CCAA suggestive images according to sex on left, right and bilateral cases.

Sex	Prevalence of CCAA					
	Right Side		Left Side		Bilatera l	
	Presence	p-Value	Presence	p-Value	Presence	p-Value
Male (n=37)	4 (10.81%)	0,89 ¹	5 (13.51%)	0.98 ¹	8 (21.62%)	0.90 ¹
Female (n=65)	9 (13.84%)		10 (15.38%)		15 (23.07%)	

¹Chi-Square Test. Source: Authors.

Table 2. Prevalence of CCAA suggestive images according to age on left, right and bilateral cases.

Age	Prevalence of CCAA					
	Right Side		Left Side		Bilateral	
	Presence	p-Value	Presence	p-Value	Presence	p-Value
<60 (n=28)	1 (3.57%)	0.16 ¹	4 (14.28%)	0.98 ¹	7 (25%)	0.92 ¹
>60 (n=74)	12 (16.21%)		11 (14.86%)		16 (21.62%)	

¹Chi-Square Test. Source: Authors.

Regarding examiners' performance before and after the activity, the intra-examiner test (Table 3) presented reasonable Kappa coefficients (0 - 0.40) (Landis & Koch, 1977; Stojanović et al., 2014), showing that the intra-examiner agreement was purely random ($p > 0.05$), which means that the examiners' diagnosis after the activity was dissimilar. Regarding the inter-examiner agreement after the activity, the Kappa coefficient was almost perfect (> 0.80) (Landis & Koch, 1977; Stojanović et al., 2014); the null hypothesis that the agreement is purely random has been rejected ($p < 0.05$). When analyzing whether the examiners' performance after the activity suffered positive or negative effects, the results were compared with the radiologist template and tested by Cohen's Kappa Coefficient, which was almost perfect (> 0.80) (Landis & Koch, 1977; Stojanović et al., 2014), with significant agreement ($p < 0.05$) (Table 4), demonstrating significant effects of the PBL for the diagnosis of CCAA suggestive images on PRs.

Table 3. Intra and inter-examiner Cohen's Kappa test considering the bilateral and unilateral (right, left) involvement.

Cohen's Kappa Coefficient - Intra-examiner: Right Side					Inter- examiner Coef.
Examiner 1 Coef.	Examiner 2 Coef.	Examiner 3 Coef.	Examiner 4 Coef.	Examiner 5 Coef.	
0.25	0.20	0.13	0.10	0.32	0.82*
Cohen's Kappa Coefficient - Intra-examiner: Left Side					Inter- examiner Coef.
Examiner 1 Coef.	Examiner 2 Coef.	Examiner 3 Coef.	Examiner 4 Coef.	Examiner 5 Coef.	
0.11	0.26	0.08	0.18	0.21	0.86*
Cohen's Kappa Coefficient - Intra-examiner: Bilateral					Inter- examiner Coef.
Examiner 1 Coef.	Examiner 2 Coef.	Examiner 3 Coef.	Examiner 4 Coef.	Examiner 5 Coef.	
0.32	0.17	0.16	0.20	0.13	0.90*

Coef: Cohen's Kappa Coefficient; * P-value of the kappa test considered significant if < 0.05. Source: Authors.

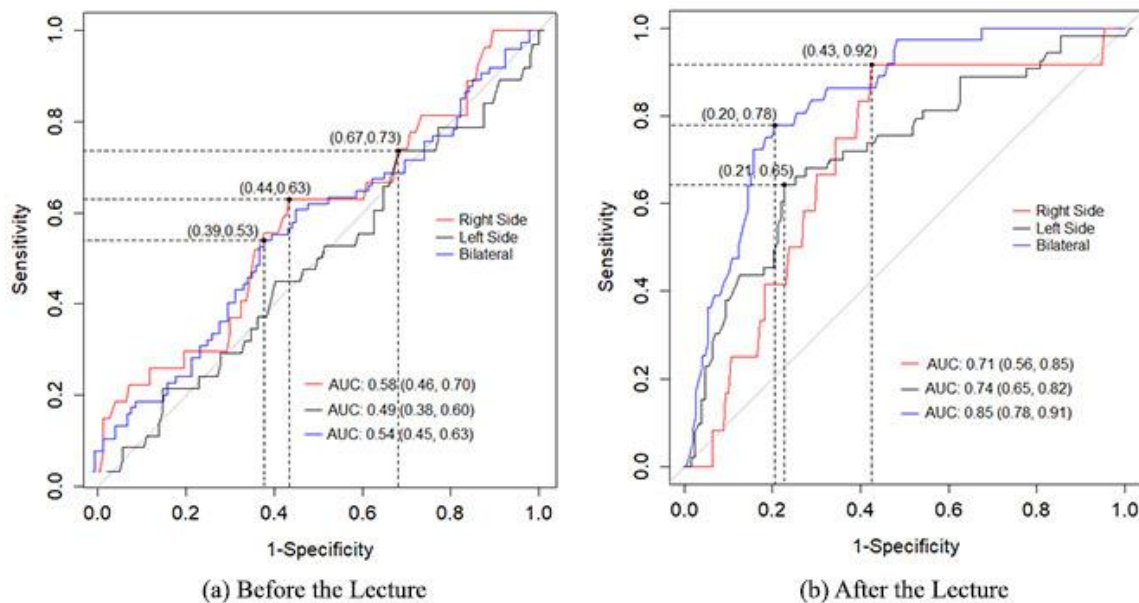
Table 4. Cohen's Kappa test after the activity vs. template prepared by the experienced radiologist considering the bilateral and unilateral (right, left) involvement.

Cohen's Kappa Coefficient – Right Side				
Examiner 1 Coef.	Examiner 2 Coef.	Examiner 3 Coef.	Examiner 4 Coef.	Examiner 5 Coef.
0.85*	0.89*	0.96*	0.88*	0.90*
Cohen's Kappa Coefficient – Left Side				
Examiner 1 Coef.	Examiner 2 Coef.	Examiner 3 Coef.	Examiner 4 Coef.	Examiner 5 Coef.
0.81*	0.90*	0.94*	0.82*	0.87*
Cohen's Kappa Coefficient – Bilateral				
Examiner 1 Coef.	Examiner 2 Coef.	Examiner 3 Coef.	Examiner 4 Coef.	Examiner 5 Coef.
0.79*	0.86*	0.92*	0.95*	0.83*

Coef: Cohen's Kappa Coefficient; * P-value of the kappa test considered significant if < 0.05. Source: Authors.

Figure 1 shows the ROC curve of the performance of examiners before and after the PBL activity, considering the bilateral and unilateral (right, left) involvement. The areas under curve (AUC) were AUC = 0.85; AUC = 0.71; AUC = 0.74 respectively.

Figure 1. ROC curve before and after the activity, considering the bilateral and unilateral (right, left) involvement, denoted by blue, red, and black, respectively.



Source: Authors.

Atherosclerosis can be an asymptomatic disease and early diagnosis is essential to decrease the risk of ischemic strokes (Gaba & Bulbulia, 2019). The gold standard exam for the diagnosis of CCAAs is the carotid doppler ultrasonography (Madden et al., 2007). Although PR is not the exam indicated for the detection of CCAAs, these calcifications can be identified when this exam is requested for other reasons. In addition, PR is one of the most used exams in dentistry (Ertas & Sisman, 2011). For this reason, dentists have an important role in the early diagnosis.

PR is an exam that covers the jaws, facial bones, teeth, and some neck structures with low radiation exposure (Bayer et al., 2011). It shows the critical region of the carotid artery (Bayer et al., 2011) and can be a valuable tool to identify calcifications that indicate cardiovascular disease (Henriques et al., 2011). However, it can be confused with other calcifications, such as that of triticeal cartilage (Wakabayashi, 2010). Carter (2000) described differences between CCAA and calcified triticeal cartilage in PRs. CCAAs appear as irregular and heterogeneous radiopacities, more laterally, while calcified triticeal cartilage appears as a homogeneous oval-shaped radiopacity (Carter, 2000). In case of doubt, an anteroposterior radiography such as the modified Towne technique can be requested (Ahmad et al., 2005). It allows CCAA suggestive images to be seen laterally to the vertebrae, while the calcified triticeal cartilage overlaps these structures (Ahmad et al., 2005).

When comparing PR and doppler ultrasonography in the detection of CCAAs, Ertas et al. (2011) found that PR had 80.5% of accuracy, 79.8% of sensitivity and 20.1% of false negatives. The values of specificity (81.1%) indicate low rates of false positives (18.8%). In a similar study, Madden et al. (2007) found a low sensitivity (31.1%) and negative predictive value (42.5%) indicating a high number of false negatives on PRs. However, the specificity (87.5%) and positive predictive value (78.7%) were high, reflecting a small number of false positives (Madden et al., 2007). In another study comparing PR and CT scans, the accuracy, sensitivity and specificity of PRs in the detection of CCAAs were 62.3%, 22.2% and 90.0%, respectively (Yoon et al., 2008). In a recent meta-analysis (Schroder et al., 2019), the accuracy of PRs in detecting CCAAs was good to excellent in half of the studies with doppler ultrasonography as the reference standard. However, the accuracy was poor when angiography was used as the reference standard (Schroder et al., 2019).

Unlike these studies, where PRs were compared with other imaging exams, we assessed the dentists' abilities to identify CCAA suggestive images before and after the implementation of a pedagogical method. Our results demonstrated an important improvement after the activity, in which the accuracy and sensitivity increased significantly. Before training, most calcifications had not been identified. Subsequently, the volunteers identified the calcifications more accurately and their performances were comparable to the template developed by an experienced radiologist ($p < 0.05$). This reinforces the importance of PR being thoroughly and carefully evaluated by the clinician, allowing for early detection and possible diagnosis of atherosclerosis (Monteiro et al., 2018). Although PR cannot be used as a specific diagnostic method for CCAA, it does suggest the diagnosis and so dentists should guide patients for further medical investigation (Monteiro et al., 2018).

There are recent studies in medicine and dentistry that compare traditional teaching methods with the PBL. They show how PBL can be an important learning tool for long term knowledge retention (Al-Madi et al., 2018; Oderinu et al., 2019), providing more enthusiasm and greater intellectual stimulation for students (Al-Madi et al., 2018; Oderinu et al., 2019). Therefore, it contributes to improve the educational process (Al-Madi et al., 2018; Oderinu et al., 2019; Moreira et al., 2020). In our study, the PBL method improved the examiners' ability to detect images suggestive of CCAAs in PRs. Therefore, we emphasize the importance of continuing education for health professionals. When dentists have the opportunity to learn more about soft tissue calcifications, the systemic health of patients can be positively affected. It is worth mentioning that our sample is very standardized, since all PRs were cautiously conducted by a single radiologist with a standardized protocol. However, one limitation of our

study was that most studies compare PRs with other imaging methods in the diagnosis of calcifications, making it difficult to compare results. To our knowledge, there are no studies that evaluated the diagnostic capability of dentists in identifying soft tissue calcifications, mainly CCAA suggestive images.

4. Conclusion

According to our results, the precision and the probability of correct detection of CCAA suggestive images on PRs increased when examiners were submitted to an active pedagogical method.

References

Ahmad, M., Madden, R., & Perez, L. (2005). Triticeous cartilage: Prevalence on panoramic radiographs and diagnostic criteria. *Oral Surgery, Oral Medicine, Oral Pathology, Oral Radiology and Endodontology*, 99(2), 225–230. <https://doi.org/10.1016/j.tripleo.2004.06.069>

Al-Madi, E. M., Celur, S. L., & Nasim, M. (2018). Effectiveness of PBL methodology in a hybrid dentistry program to enhance students' knowledge and confidence. (a pilot study). *BMC Medical Education*, 18(1), 1–6. <https://doi.org/10.1186/s12909-018-1392-y>

American Dental Association (2004). The selection of patients for dental radiographic examinations. *American Dental Association*, Chicago, 0-19.

American Dental Association Council on Scientific Affairs (2006). The use of dental radiographs: update and recommendations. *J Am Dent Assoc*, 137, 1304-12.

Bayer, S., Helfgen, E. H., Bös, C., Kraus, D., Enkling, N., & Mues, S. (2011). Prevalence of findings compatible with carotid artery calcifications on dental panoramic radiographs. *Clinical Oral Investigations*, 15(4), 563–569. <https://doi.org/10.1007/s00784-010-0418-6>

Bayram, B., Uckan, S., Acikgoz, A., Müderrisoğlu, H., & Aydinalp, A. (2006). Digital panoramic radiography: A reliable method to diagnose carotid artery atheromas? *Dentomaxillofacial Radiology*, 35(4), 266–270. <https://doi.org/10.1259/dmfr/50195822>

Carter, L. C. (2000). Discrimination between calcified triticeous cartilage and calcified carotid atheroma on panoramic radiography. *Oral Surgery, Oral Medicine, Oral Pathology, Oral Radiology, and Endodontics*, 90(1), 108–110. <https://doi.org/10.1067/moe.2000.106297>

Ertas, E. T., & Sisman, Y. (2011). Detection of incidental carotid artery calcifications during dental examinations: Panoramic radiography as an important aid in dentistry. *Oral Surgery, Oral Medicine, Oral Pathology, Oral Radiology and Endodontology*, 112(4), e11–e17. <https://doi.org/10.1016/j.tripleo.2011.02.048>

Gaba, K., & Bulbulia, R. (2019). Identifying asymptomatic patients at high-risk for stroke. *Journal of Cardiovascular Surgery*, 60(3), 332–344. <https://doi.org/10.23736/S0021-9509.19.10912-3>

Henriques, J. C., Kreich, E. M., Baldani, M. H., Luciano, M., Castilho, J. C. (2011). Panoramic Radiography in the Diagnosis of Carotid Artery Atheromas and the Associated Risk Factors. *The Open Dentistry Journal*, 5(3), 79–83. <https://doi.org/10.1016/j.tripleo.2003.08.025>

Kamikawa, R. S. S. (2009). Pesquisa de Calcificação em tecido mole na região cervical por meio das técnicas radiográficas panorâmica e telerradiografia. 75.

Landis, J. R., & Koch, G. G. (1977). The Measurement of Observer Agreement for Categorical Data. *Biometrics*, 33(1), 159–174.

MacDonald, D., Chan, A., Harris, A., Vertinsky, T., Farman, A. G., & Scarfe, W. C. (2012). Diagnosis and management of calcified carotid artery atheroma: Dental perspectives. *Oral Surgery, Oral Medicine, Oral Pathology and Oral Radiology*, 114(4), 533–547. <https://doi.org/10.1016/j.oooo.2012.06.020>

Madden, R. P., Hodges, J. S., Salmen, C. W., Rindal, D. B., Tunio, J., Michalowicz, B. S., & Ahmad, M. (2007). Utility of panoramic radiographs in detecting cervical calcified carotid atheroma. *Oral Surgery, Oral Medicine, Oral Pathology, Oral Radiology and Endodontology*, 103(4), 543–548. <https://doi.org/10.1016/j.tripleo.2006.06.048>

Monteiro, I. A., Ibrahim, C., Albuquerque, R., Donaldson, N., Salazar, F., & Monteiro, L. (2018). Assessment of carotid calcifications on digital panoramic radiographs: Retrospective analysis and review of the literature. *Journal of Stomatology, Oral and Maxillofacial Surgery*, 119(2), 102–106. <https://doi.org/10.1016/j.jormas.2017.11.009>

Moreira, E. E. P., Oliveira, S. M. C. de, & Oliveira, J. V. P. de. (2020). Contributes and challenges of problem-based learning in medical training. *Research, Society and Development*, 9(8), e639985361. <https://doi.org/10.33448/rsd-v9i8.5361>

Oderinu, O. H., Adegbulugbe, I. C., Orenuga, O. O., & Butali, A. (2019). Comparison of students' perception of problem-based learning and traditional teaching method in a Nigerian dental school. *European Journal of Dental Education*, November 2019, 207–212. <https://doi.org/10.1111/eje.12486>

Roldán-Chicano, R., Oñate-Sánchez, R. E., López-Castaño, F., Cabrerizo-Merino, M. C., & Martínez-López, F. (2006). Panoramic radiograph as a method for detecting calcified atheroma plaques. Review of literature. *Medicina Oral, Patología Oral y Cirugía Bucal*, 11(3), 261–266.

Schroder, A. G. D., de Araujo, C. M., Guariza-Filho, O., Flores-Mir, C., de Luca Canto, G., & Porporatti, A. L. (2019). Diagnostic accuracy of panoramic radiography in the detection of calcified carotid artery atheroma: a meta-analysis. *Clinical Oral Investigations*. <https://doi.org/10.1007/s00784-019-02880-6>

Stojanović, M., Apostolović, M., Stojanović, D., Milošević, Z., Toplaović, A., Lakušić, V. M., & Golubović, M. (2014). Understanding sensitivity, Specificity and predictive values. *Vojnosanitetski Pregled*, 71(11), 1062–1065. <https://doi.org/10.2298/VSP1411062S>

Tamblyn, R. M., & Se, B. N. (1981). Problem-Based Learning: An Approach to Medical Education. *American Journal of Occupational Therapy*, 35(8), 539–539. <https://doi.org/10.5014/ajot.35.8.539b>

Wakabayashi, I. (2010). Associations between alcohol drinking and multiple risk factors for atherosclerosis in smokers and nonsmokers. *Angiology*, 61(5), 495–503. <https://doi.org/10.1177/0003319709358694>

World Health Organization (2017). Pan American Health Organization: Cardiovascular Diseases. Retrieved from: https://www.paho.org/bra/index.php?option=com_content&view=article&id=5253:doencas-cardiovasculares&Itemid=1096

Yoon, S. J., Yoon, W., Kim, O. S., Lee, J. S., & Kang, B. C. (2008). Diagnostic accuracy of panoramic radiography in the detection of calcified carotid artery. *Dentomaxillofacial Radiology*, 37(2), 104–108. <https://doi.org/10.1259/dmfr/86909790>

Percentage of contribution of each author in the manuscript

Beatriz Caio Felipe – 12,5%
Fernanda Chiguti Yamashita – 12,5%
Amanda Lury Yamashita – 12,5%
Ana Carolina Caio Passoni – 12,5%
Breno Gabriel da Silva – 12,5%
Elen de Souza Tolentino – 12,5%
Mariliani Chicarelli – 12,5%
Lilian Cristina Vessoni Iwaki – 12,5%