

Reanatomization of anterior teeth with composite resin: case report

Reanatomização de dentes anteriores com resina composta: relato de caso

Reanatomización de dientes anteriores con resina compuesta: reporte de caso

Received: 07/12/2020 | Reviewed: 14/12/2020 | Accept: 20/12/2020 | Published: 26/12/2020

Brenda da Silva Balassa

ORCID: <https://orcid.org/0000-0002-8180-8938>

Universitary Center Ingá, Brazil

E-mail: Balassabh@icloud.com

Iago Demétrio da Silva

ORCID: <https://orcid.org/0000-0002-3591-3278>

State University of Maringá, Brazil

E-mail: Iagodemetrio95@gmail.com

Marília Zeczkowski

ORCID: <https://orcid.org/0000-0002-8108-057X>

ITPAC, Brazil

E-mail: mariliaz21@gmail.com

Ludmila Priscilla Manetti

ORCID: <https://orcid.org/0000-0003-3437-0467>

Methodist University of Piracicaba, Brazil

E-mail: ludmanetti@hotmail.com

Abstract

Dental diastema is a space or absence of contact between two consecutive teeth, which may represent an aesthetic embarrassment for the patient when smiling. For the aesthetic resolution of diastema some factors should be evaluated as, age of the patient, dental structure conservation, reversibility of treatment, cost and longevity. For closing diastema, for a long time, the clinical alternatives were the use of orthodontics and fixed prostheses. Currently, with composite resins, it is possible to reproduce natural characteristics of the teeth with a direct, reversible restorative technique, without the wear of healthy dental structure, with affordable cost, able to provide satisfactory aesthetic results. The aim of this study is to report a case of a patient diagnosed with inter incisor diastema and to present a literature review. Patient, male, 70 years old, was attended at oral clinic of Ingá University Center - Uningá,

complaining about the aesthetics of his smile. Clinically, was observed the presence of a diastema between upper incisor, fracture of incisal edge of central incisors and poor dental positioning. A reverse planning of the case was carried out through diagnostic waxing. With aid of a silicone guide, the diastema was closed through reanatomizations in composite resin. After the proposed treatment, was possible to obtain a satisfactory aesthetic in the patient's smile. The closure of diastema, with the use of composite resins was able to provide a better contour to the teeth, closing the spaces present, resulting in an aesthetic and pleasant smile.

Keywords: Diastema; Esthetics; Dental veneers.

Resumo

Diastema dental é um espaço ou ausência de contato entre dois dentes consecutivos, que podem representar um constrangimento estético para o paciente ao sorrir. Para a resolução estéticas dos diastemas alguns fatores devem ser avaliados como, idade do paciente, conservação da estrutura dental, reversibilidade do tratamento, custo e longevidade. Para o fechamento dos diastemas, durante muito tempo, as alternativas clínicas eram o emprego da ortodontia e das próteses fixas. Atualmente, com as resinas compostas, é possível reproduzir as características naturais dos dentes com uma técnica restauradora direta, reversível, sem o desgaste de estrutura dental sadia, com custo acessível, e capaz de proporcionar resultados estéticos satisfatórios. O objetivo deste estudo é relatar o caso de um paciente diagnosticado com diastema inter incisivo e apresentar uma revisão de literatura. Paciente do gênero masculino, 70 anos, compareceu na clínica odontológica do Centro Universitário Ingá - Uningá, queixando-se da estética de seu sorriso. Cínicamente foi constatado a presença de diastema inter incisivo superior, fratura da borda incisal dos incisivos centrais e mal posicionamento dental. Foi realizado um planejamento reverso do caso através do enceramento diagnóstico. Com o auxílio de um guia de silicone foi feito o fechamento do diastema através de reanatomizações em resina composta. Após o tratamento proposto foi possível obter uma estética satisfatória no sorriso do paciente. O fechamento de diastemas, com a utilização de resinas compostas foi capaz de proporcionar um melhor contorno aos dentes, fechamento dos espaços presentes, resultando em um sorriso estético e agradável.

Palavras-chave: Diastema; Estética; Facetas dentárias.

Resumen

Diastema dental es un espacio o ausencia de contacto entre dos dientes consecutivos, que puede representar una vergüenza estética para el paciente al sonreír. Para la resolución

estética del diastema se deben evaluar algunos factores como, edad del paciente, conservación de la estructura dental, reversibilidad del tratamiento, costo y longevidad. Para el cierre de diastema, durante mucho tiempo, las alternativas clínicas fueron el uso de ortodoncia y prótesis fijas. Actualmente, con resinas compuestas, es posible reproducir las características naturales de los dientes con una técnica restauradora directa y reversible, sin el desgaste de una estructura dental saludable, con un coste asequible, capaz de proporcionar resultados estéticos satisfactorios. El objetivo de este estudio es reportar el caso de un paciente diagnosticado con diastema entre los incisivos y presentar una revisión bibliográfica. Paciente, varón, 70 años, asistió a la clínica del Centro Universitario Ingá - Uningá, quejándose de la estética de su sonrisa. Clínicamente, se observó la presencia de un diastema entre incisivos superiores, fractura del borde incisal de los incisivos centrales y mal posicionamiento dental. Se llevó a cabo una planificación inversa del caso a través de la depilación diagnóstica. Con una guía de silicona, el diastema se cerró a través de reanatomizaciones en resina compuesta. Después del tratamiento, fue posible obtener una estética satisfactoria en la sonrisa del paciente. El cierre del diastema, con uso de resinas compuestas fue capaz de proporcionar un mejor contorno a los dientes, cerrando los espacios presentes, dando como resultado una sonrisa estética y agradable.

Palabras clave: Diastema; Estética; Coronas con frente estético.

1. Introduction

The current society is composed with a large number of people who value and seek for body and facial aesthetics. They seek an appearance within the standards of beauty adopted in the environment in which they live, seeking their own acceptance and that of other individuals. They take into account the beauty of a perfect smile searching for healthy, harmonic teeth, with clear and uniform coloration, so that this smile can provide you with greater acceptance of yourself and by the society (Lamenha, et al., 2007).

There are several conditions that affect the oral cavity that can cause a smile in disharmony, among them are diastema, which is a space or absence of contact between two consecutive teeth. These spaces can occur in all teeth, in jaw and mandible. However, it is more often observed between anterior teeth of the jaw, which may represent an aesthetic constraint for the patient when smiling (Lamenha, et al., 2007). The correction of diastema can be performed through orthodontic treatment and restorative treatment, performing direct or indirect restorations (Schwarz, et al., 2013). Sometimes, orthodontic treatment only does

not present the desired result, and then aesthetic restorative treatment is performed (Sabri, 1999; Kokich & Kinzer, 2005).

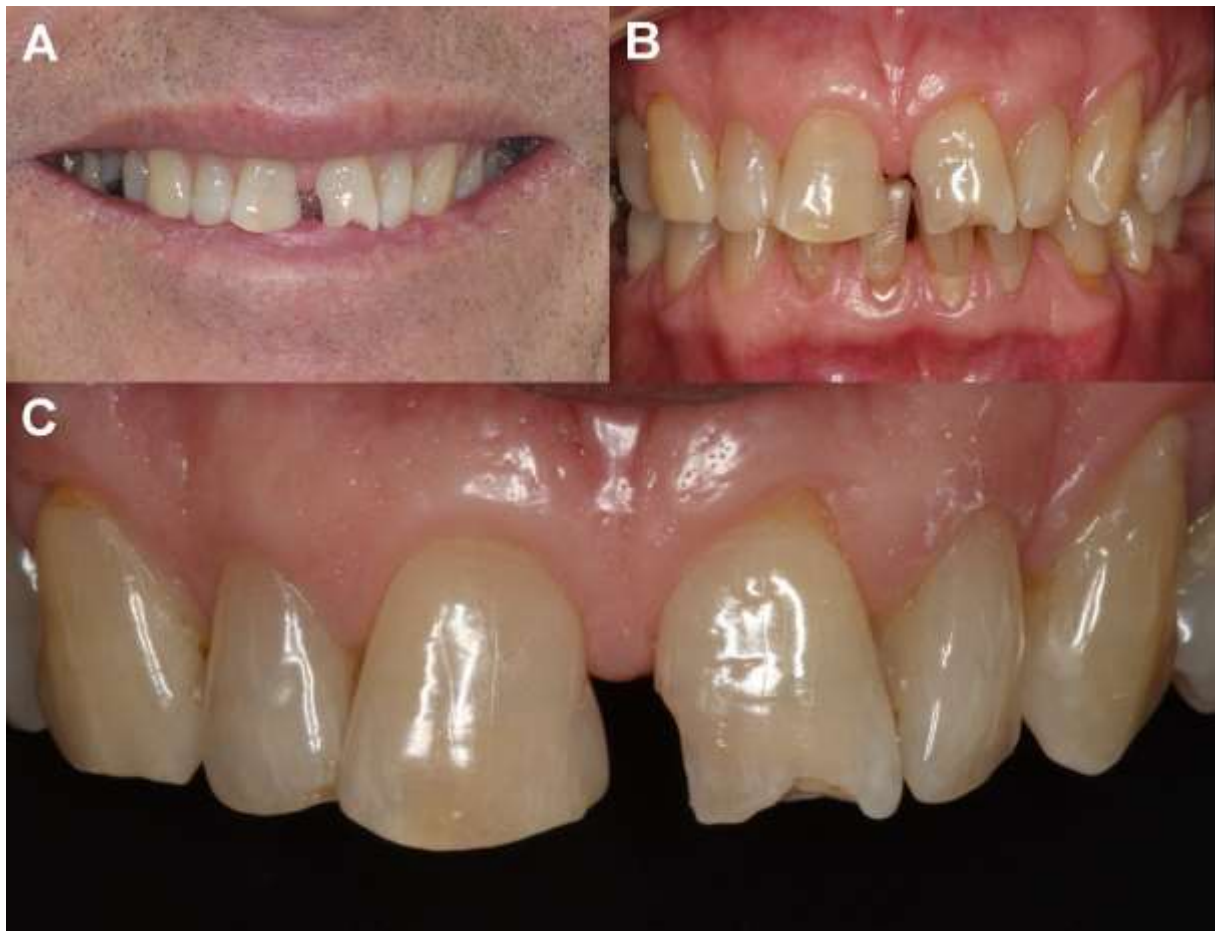Nowadays, the treatment with composite resin has been widely used for presenting several advantages, the one that stands out most is the aesthetic result, because with this material is possible to recreate a natural appearance close to that of dental structures, restoring morphological function and restoring natural aesthetic characteristics of teeth (Schwarz, et al., 2013).

This way, the present study aims to report a successful clinical case conducted in an oral undergraduate clinic of a patient who dissatisfied with his smile due to the presence of a diastema, agreed with the performance of reanatomizations with direct composite resin for the aesthetic reestablishment of the upper anterior teeth.

2. Case Report

A 70-year-old male patient was attended at oral clinic of the Ingá University Center - UNINGÁ, Maringá unit, complaining about his smile. After clinical examination, was possible to observe a change in the angulation of central incisors, in addition to the presence of a diastema between upper incisors and fracture of the incisal edges of the central incisors, resulting in a disharmonious and aesthetically unsatisfactory smile (Figure 1 A and B). After the initial consultation, study models were made, where was found that the cause of the diastema was the low insertion of the patient's lip brake, which was causing an inclination of the central incisors (Figure 1 C). Was explained to patient that the treatment could be done through a frenectomy and orthodontic alignment, but the patient refused due to age. Was offered to patient the reanatomization of anterior teeth, through ceramic laminates or composite resins, the pros and cons of each technique were presented and the patient, finally, opted for reanatomization, by the direct technique with composite resin.

Figure 1. Initial clinical examination. (A) Extraoral smile photography. (B) Intraoral smile photography. (C) Diastema and unsatisfactory aesthetics of upper anterior teeth.



Source: Authors.

At the beginning of the treatment, the chromatic analysis was performed under sunlight, with the aid of Vita Classical color scale (Vita Zahnfabrik, Bad Säckingen, Germany) which assisted in the identification of the hue, chroma, and the color that most closely approached the patient's teeth was A3. The selection colors of composite resin was performed with the application of small increments of resin on the vestibular face of the tooth. A small increment of composite resin OA3.5 (Charisma - Heraeus, Germany) was placed on the cervical third and A3 on the incisal third, photoactivation was performed and after the humidification. The selected colors were equivalent to the color of the dental substrate, which were chosen for the preparation of the restorations.

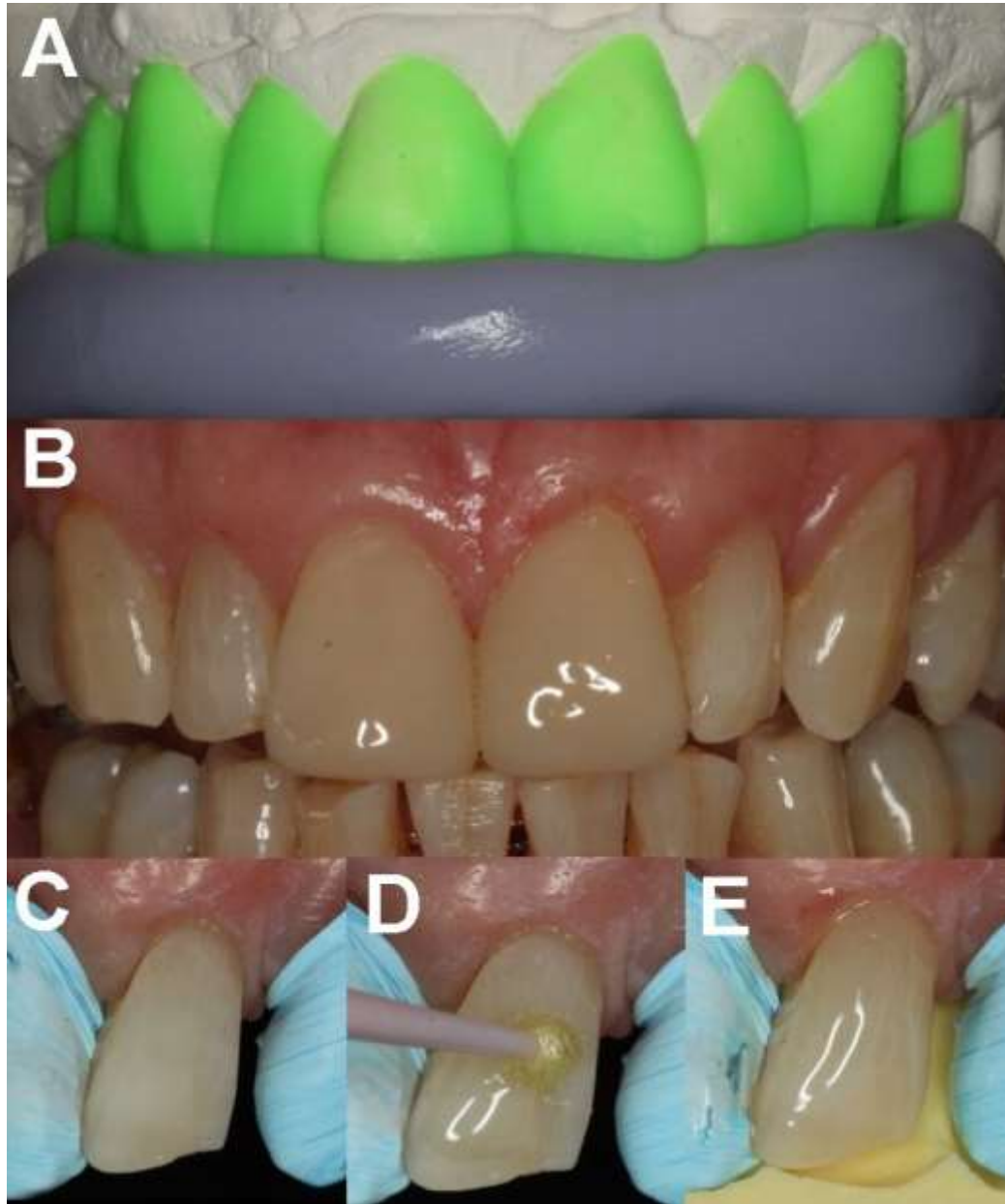
On the study model, a diagnostic waxing and guide in addition silicon (Adsil Putty Soft - Coltene, Rio de Janeiro, RJ, Brazil) was performed to copy the incisal edges and the palatine face, so that it could help with the preparation of composite resin restorations (Figure 2 A). In a first session, the necessary clippings were performed in the guide and the same was

proven in the patient's teeth, adapting properly. Under relative isolation with lip retractor, the restorative stage of central incisors was initiated. Adjacent teeth were protected with teflon strips (IsoTape, TDV Dental Ltda, Pomerode, SC - Brazil), was applied phosphoric acid 37% in gel (Maquira, Maringá, PR), throughout the vestibular, proximal and part of the lingual face for 30 seconds in enamel and for 15 seconds in the dentin, then washed abundantly with water and performed adequate drying of the substrates. The application of the conventional two-step adhesive (Ambar - FGM Dental Products, Joinville, SC - Brazil) was made throughout the conditioned surface, according to the manufacturer's recommendations. Then, the silicone guide was placed in position and a marking was made on it, with exploratory probe on the area that should receive the resin composed by the palatine face. On the guide with this marking, a thin layer of composite resin was applied for enamel in color A3, referring to the palatine enamel, the silicone guide with the composite resin were adapted to the teeth with the aid of a spatula and with this set in position the photoactivation was made. The silicone guide was removed and the palatine enamel was reproduced, thus facilitating the subsequent application of composite resin.

The composite resin referring to dentin in the color OA3,5 was applied, distributing it to close the diastema and giving a new shape to the tooth. The composite resin was carefully inserted with a thin and long spatula and smoothed with the help of a flat-tipped mink hair brush (Tigre, 308, Brazil). To assist in reproduction of the proximal face and to obtain a contact area, a polyester strip was positioned in the inter proximal space and after the insertion of composite resin, it was processed. After applying the dentin resin, a last and only layer of enamel resin was applied and adapted with the brush over entire vestibular face. After the reatomization in composite resin, water soluble gel (KY, Johnson & Johnson) was applied on the restoration and a new photopolymerization was made. The finishing of the restorations was carried out, with the removal of excess material with scalpel lamina number 12 (Advantive, Curitiba, Paraná, Brazil) adjustment of proximal faces with sandpaper strips (Microdont, São Paulo, SP, Brazil) and occlusal adjustment (Figure 2-B).

In a following session, the same restorative procedures described above were performed, but for the preparation of restorations to lateral and canine (Figure 2 C, D and E).

Figure 2. Planning and execution of direct restorations. (A) Diagnostic waxing and silicone guide. (B) First session and restorations of the upper central incisors. (C) Second session, tooth after acid conditioning. (D) Adhesive application. (E) Guide in position to insertion of the palatine layer.

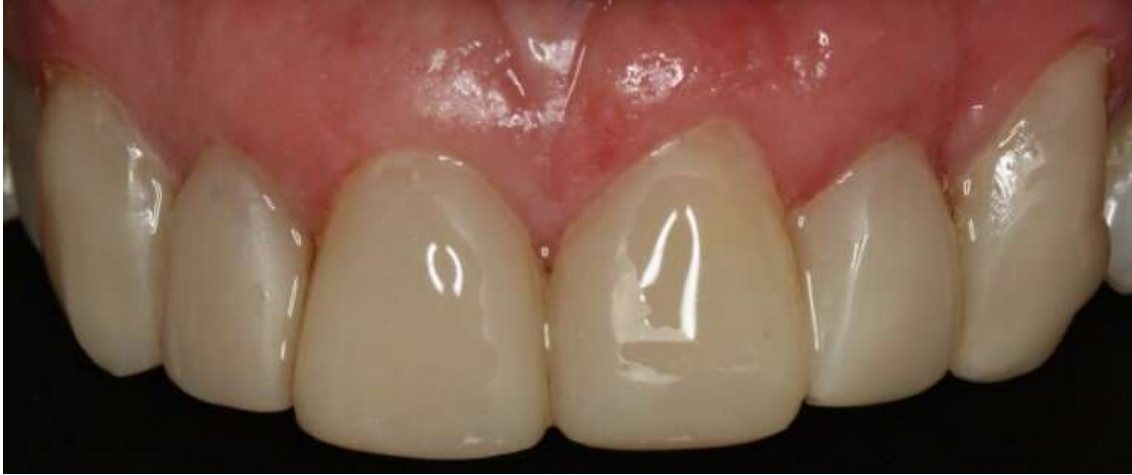

Source: Authors.

After all restorations made, finishing and polishing were performed. For this, abrasive sandpaper discs (Diamond Flex, FGM, Dental Products, Joinville, SC - Brazil), abrasive silicone tips (Viking, KG Sorensen, São Paulo, São Paulo, SP, Brazil) and felt disc (Diamond, FGM, Dental Products, Joinville, SC - Brazil) with diamond paste (Diamond Universal, Maquira, Maringá, PR, Brazil) were used. With the reanatomizations completed, it was

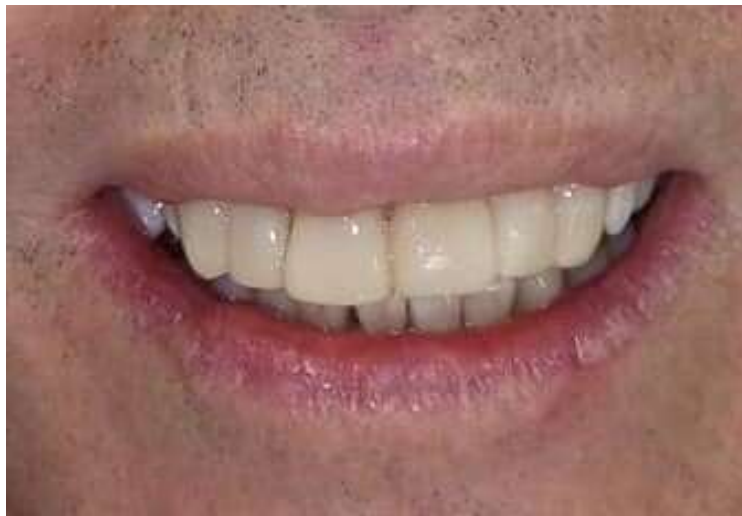possible to restore the harmony of the smile, obtaining a satisfactory aesthetic result and improve the patient's self-esteem (Figure 3 and 4).

Figure 3. Intraoral photography. Closure of diastema and dental reanatomization.



Source: Authors.

Figure 4. Extraoral photography. Patient's final smile.



Source: Authors.

3. Discussion

Dental diastema can be caused by acquired or hereditary factors. Among the factors acquired are abnormal swallowing, habits of biting or sucking the lower lip, insertion of toothpicks or pens between teeth, nail biting or the use of other objects between central incisors or other teeth. Hereditary factors include dental anomalies of shape, size, position and

number, Bolton discrepancy and low insertion of the upper lip brake (Marur, et al., 1997; Garófalo, 2002; Botta, et al., 2009; Silva, et al., 2019; Oliveira, et al., 2014; Silva, et al., 2020). This last characteristic can be observed in our case as an etiological factor of diastema among the upper central incisors of the patient.

Ethnicity is also pointed out as a factor that can influence the incidence of diastema, where black individuals have the highest incidence of involvement (Larry, et al., 1999). Differently in our case, that the affected individual was white.

Diastema is more frequently present in the upper anterior teeth (22.33%) (Pedrini, et al., 2000). Being classified as small when they have a size less than 2 mm, medium with size between 2 mm to 6 mm and large with size above 6 mm (Money, 1999).

Due to the need for aesthetic and functional correction of the smile, many patients seek oral clinics in order to improve its aesthetics, seeking to adapt to beauty standards, having teeth with adequate size, defined and aligned shapes. The dentist should know how to diagnose the case and do a good plan to achieve functional and aesthetic success. The use of composite resin restorations may be the treatment of choice, as it provides acceptable longevity, preservation of dental tissues and lower cost when compared to those involving the laboratory part (Redman, et al., 2003; Devoto, et al., 2010).

In the case of closure diastema with composite resin the advantages are extended because they present a fast technique; in reatomization can reduce the sessions to a single one, depending the number of teeth to be reconstituted; it is safe and effective, it is possible to the dentist to control the color and shape of the original tooth; does not require provisional; the preparation is more conservative than for indirect facets and is reversible, if the desired aesthetic result has not been achieved (Mangani, et al., 2007). The limitations of the composite resin technique are mainly related to cases of unsatisfactory oral hygiene, which favors the degradation of organic matrix of resin and the change in color and texture (Weiss, et al., 2008). It is up to the dentist to guide the patient regarding hygiene and know well which resins are best quality to use in his work.

Regarding aesthetic planning, there are several factors to be considered when analyzing the dental proportion. Usually begins the analysis by the size and shape of the teeth, in order to measure the correct proportion that the tooth should have; then, the texture and color are evaluated (Botta, et al., 2009).

From the diagnostic waxing performed in plaster models, it is possible to determine the size of the restorations to be performed, as well as the exact position of the palatine and incisal surface of the anterior teeth. Thus, it is possible to make a silicone guide, and from this

it is possible to perform dental reconstruction through the insertion of composite resin in the space designated in the waxing, allowing the reconstruction of the teeth to be beyond, more efficient, faster (Baratieri, et al., 2002; Behle, 1995).

Therefore, the restorations of anterior teeth are challenging, because they involve the understanding of dental anatomy and the optical properties of teeth, which are of fundamental importance in the preparation of aesthetic restorations (Chu, et al., 2012; Duarte, et al., 2013). The color taking of the dental element and the selection of composite resin should consider the optical characteristics of the dental structure, such as fluorescence, opalescence, translucency and luminosity (Chu, et al., 2012; Bergoli, et al., 2009; Manauta & Salat, 2013; Villarroel, et al., 2011). When choosing the shade of the resin to be used in the restoration, one should opt for a shade similar to that of natural teeth to obtain greater harmony.

Currently, there are excellent quality resins on the market that have good color stability, surface wear resistance, adequate opacity, diversified colors, which favors the final aesthetic result and the durability of the result obtained (Leinfelder, 1997; Millar, et al., 1997; Pfeiffer & Lange, 2009).

In the present clinical case, a micro-hybrid resin with good properties was used, with the average size of the load particles of 0.05-10 μ m,(information taken from the resin package leaflet) which favored the satisfactory aesthetic result (Rawls & Esquivel-Upshaw, 2005). However, it is important to highlight that micro-hybrids are not the best in aesthetics. But the aesthetic result is adequate, returns the desired appearance to the teeth and has appropriate resistance for dental treatments.

The size of the load particles and their concentration is an important factor, which determines the properties of the composite resin, such as polymerization contraction, water sorption, translucency, surface smoothness and modulus of elasticity, among others. The higher the amount of inorganic load, more feasible it is to obtain a composite with lower values of polymerization contraction and lower water absorption. The smaller the size of the charge particles, the smoother the composite surface becomes (Rawls & Esquivel-Upshaw, 2005; Nahsan, et al., 2012; Van Noort, 2010).

Finishing and polishing are crucial steps in the preparation of composite resin restorations, because it is already quite elucidated that these procedures leave the surface of the composite resin smoothly, thus preventing pigment retention and dental biofilm (Rawls & Esquivel-Upshaw, 2005) which gives a harmonious and beautiful appearance to the patient's teeth and smile.

4. Conclusion

In view of the clinical case presented, it is possible to concluded that the direct restorative technique with use of composite resin proved to be effective, closing the diastema, repairing the fractured incisal edge and poor dental positioning, providing a better contour to the teeth, patient satisfaction, with low cost and with great preservation of dental structure, and this is a possible treatment to be performed for aesthetic improvements in a university clinic.

References

- Baratieri, L. N., Araujo Junior, E. M., Monteiro Junior, S., & Vieira, L. C. C. (2002). *Caderno de dentística: Restaurações adesivas diretas com resinas compostas em dentes anteriores*. São Paulo: Livraria Santos Editora, 131.
- Behle, C. (1995). Placement of direct composite veneers utilizing a silicone buildup guide and intraoral mock-up. *Pract Periodontics Aesthet Dent*, 7(7): 15-25
- Bergoli, C. D., Skupien, J. A., & Marchiori, J. C. (2009). Fechamento de diastema utilizando técnica de venceramento e moldagem com silicona: acompanhamento de dois anos. *Int J Dent*, 8(3), 167-71.
- Botta, A. C., Duarte, S. Jr., Paulin Filho, P. I., Gheno, S. M., & Powers, J. M. (2009). Surface roughness of enamel and four resin composites. *Am J Dent*, 22(5), 252-4.
- Chu, S. J., Devigus, A., Paravina, R. D., & Mielezsko, A. J. (2012). *Fundamentos da cor: seleção e comunicação da cor em odontologia estética*. (2a ed.), São Paulo: Quintessence.
- Devoto, W., Saracinelli, M., & Manauta, J. (2010). Composite in everyday practice: how to choose the right material and simplify application techniques in the anterior teeth. *Eur J Esthet Dent*, 5(1), 102-24.
- Duarte, Jr S., Sartori, N., & Phark, J. (2013). Achieving the ultimate optical properties of composite resin. *Quintessence Dent Technol*, 36, 38.

Garófalo, J. C. (2002). *Procedimentos restauradores e a complementação estética e funcional de tratamentos ortodônticos*. In: Cardoso RJA, Gonçalves EAN. 20º Congresso: arte, ciência e técnica. São Paulo: Artes Médicas, 137-150

Kokich, V., & Kinzer, G. (2005). Managing congenitally missing lateral incisors. Part I: Canine substitution. *J Esthet Restor Dent*, 17:5-10.

Lamenha, E. G. R., Guimarães, R. P., & Silva, C. H. V. (2007). Diastema mediano superior: aspectos etiológicos. *Int J Dent*, 6(1), 2-6.

Larry, J., Oesterle, D. D. S., & Shellhart, W. C. (1999). Maxillary midline diastemas: a look at the causes. *J Am Dent Assoc*, 130(1), 85-94.

Leinfelder, KF. (1997). New development in resin restorative system. *J Am Dent Assoc*, 128(5): 573-84.

Manauta, J., & Salat, A. (2013). *Layers. Camadas. Atlas sobre estratificação das resinas compostas*. São Paulo. Quintessence.

Mangani, F., Cerutti, A., Putignano, A., Bollero, R., Madini, L. (2007). Clinical approach to anterior adhesive restorations using resin composite veneers. *Eur J Esthet Dent*, 2(2), 188-209.

Marur, R. F., Azevedo, E. A., Saad, J. R. C., Dinelli, W., Vieira, S., & Calixto, A. (1997). Diastema por negligência ou imperícia profissional. *Rev Odonto*, 1(1): 28-31.

Millar, B. J., Robinson, P B., & Inglis, A. T. (1999). Clinical evaluation of an anterior hybrid composite resin over 8 years. *Br Dent J*. 182: 26- 30.

Money, B. (1999). *Revista Operatória Dental*. Editora Panamericana. 2(3): 913-21.

Nahsan, F. P., Mondelli, R. F., Franco, E. B., Naufel, F. S., Ueda, J. K., Schmitt, V. L., & Baseggio, W. (2012). Clinical strategies for esthetic excellence in anterior tooth restorations: understanding color and composite resin selection. *J Appl Oral Sci*, 20(2):151-6.

Oliveira, D. C. R. S., Prieto, L. T., Coppini, .E. K., Araújo, C. T. P., Souza, Jr. E., & Paulillo, L. A. M. S. (2014). Resolução estética: fechamento de diastemas e contorno cosmético. *Prosthes. Lab. Sci*, 3(10):107-113.

Pedrini, D., Jardim, P. S., & Pai, W. R. (2000). Transformação de dente conóide e fechamento de diastema em clínica geral. *Rev Faculdade Odontol Lins*, 12: 52-6.

Pfeiffer, P., & Lange, R. T. (2009). Clinical evaluation of ceramic inlays compared to composite restorations. *Oper Dent*, 34:263-72.

Rawls, H. R., & Esquivel-Upshaw, J. (2005). *Resinas restauradoras. In: Anusavice KJ. Phillips - materiais dentários*. 11ª ed. Rio de Janeiro: Elsevier, 375-417.

Redman, C. D., Hemmings, K. W., & Good, J. A. (2003). The survival and clinical performance of resinbased composite restorations used to treat localised anterior tooth wear. *Br Dent J*, 194(10):566-72.

Sabri, R. (1999). Management of missing maxillary lateral incisors. *J Am Dent Assoc*, 130:80-4.

Silva, I. D., Luiz, C. C. S. P., Bachesk, A. B., & Balassa, B. S. (2020). Genetic bases related to the development of non-syndromic dental agenesis: a literature review. *Research, Society and Development*, 9 (11), e2449119882.

Silva, I. D., Pavan, A. J., Camarini, E. T. (2019). Anomalia dentária de número: exodontia de quartos molares impactados em maxila - Relato de caso. *Revista Uningá*, 56 (3): 84-91, ISSN 2318-0579.

Schwarz, V., Simon, L. S., Silva, S. A., Ghiggi, P. C., Cericato, G. O. (2013). Fechamento de diastema com resina composta: relato de caso. *J Oral Invest*, 2(1): 26-31.

Van Noort, R. (2010). Resinas compostas e resinas compostas modificadas por poliácidos. Van Noort R. *Introdução aos materiais dentários*. 3ª ed. Rio de Janeiro: Elsevier, 93-118.

Villarroel, M., Fahl, N., Souza, A. M., Oliveira, O. B Jr. (2011). Direct esthetic restorations based on translucency and opacity of composite resins. *J Esthet Restor Dent*, 23(2):73-87.

Weiss, E. I., Domb, A. J., Matalon, S., Bahir, R., & Beyth, N. (2008). Streptococcus mutans biofilm changes surface-topography of resin composites. *Dent Mater*, 24:732-36.

Percentage of contribution of each author in the manuscript

Brenda da Silva Balassa – 50%

Iago Demétrio da Silva – 30%

Marília Zeczowski – 10%

Ludmila Priscilla Manetti – 10%