

Prospective radiographic evaluation of peri-implant bone maintenance on osseointegrated implants with frictional morse taper connection and platform switching: Cases report

Avaliação radiográfica prospectiva da manutenção óssea peri-implantar nos implantes osseointegráveis com conexão cone morse friccional e plataforma switching: Relato de casos

Evaluación radiográfica prospectiva del mantenimiento óseo peri-implantario en implantes osteointegrados con conexión de cono morse por fricción y plataforma de switching: Informes de casos

Received: 01/28/2021 | Reviewed: 02/03/2021 | Accept: 02/05/2021 | Published: 02/13/2021

Eduardo Cekaunaskas Kalil

ORCID: <https://orcid.org/0000-0002-0824-3918>
Universidade Nove de Julho, Brazil
E-mail: edukalil@uol.com.br

Elaine Marcílio Santos

ORCID: <https://orcid.org/0000-0003-1084-9940>
Universidade Metropolitana de Santos, Brazil
E-mail: elaine.marcilio@unimes.br

Alexandre Melloti Dottore

ORCID: <https://orcid.org/0000-0003-4254-7322>
Universidade Nove de Julho, Brazil
E-mail: drdottore@hotmail.com

Sergio de Sousa Sobral

ORCID: <https://orcid.org/0000-0002-6412-6695>
Universidade Nove de Julho, Brazil
E-mail: sss@uol.com.br

Ana Paula Taboada Sobral

ORCID: <https://orcid.org/0000-0002-6846-6574>
Universidade Metropolitana de Santos, Brazil
E-mail: anapaula@taboada.com.br

Kristianne Porta Santos Fernandes

ORCID: <https://orcid.org/0000-0001-7156-9286>
Universidade Nove de Julho, Brazil
E-mail: kristianneporta@gmail.com

Lara Jansiski Motta

ORCID: <https://orcid.org/0000-0002-7774-4345>
Universidade Nove de Julho, Brazil
E-mail: larajmotta@terra.com.br

Anna Carolina Ratto Tempestini Horliana

ORCID: <https://orcid.org/0000-0003-3476-9064>
Universidade Nove de Julho, Brazil
E-mail: annacrth@gmail.com

Andréa Oliver Gomes

ORCID: <https://orcid.org/0000-0002-4515-3508>
Universidade Nove de Julho, Brazil
E-mail: an_oliver@hotmail.com

Sandra Kalil Bussadori

ORCID: <https://orcid.org/0000-0002-9853-1138>
Universidade Nove de Julho, Brazil
E-mail: sandra.skb@gmail.com

Abstract

Objective: The aim of the present study was to evaluate radiographically the remodeling of the peri-implant bone crest in prosthetic friction morse cone implants, with platform switching, after 12 months of application of prosthetic load. **Materials and Methods:** 16 implants were installed, in 10 patients, rehabilitated with partial, single and multiple metal-ceramic prostheses, submitted to prosthetic function in the period of 12 months. Periapical radiographs to measure the

distance between the mesial and distal marginal bone crest and the platform of each implant, were performed at the time of installing the prostheses and 12 months later. The images obtained at different intervals were digitized and analyzed using *Image J software*^{TD}. Results: At the time of installing the prostheses, the averages of measurements on the distal and mesial surfaces were 0.57 mm (standard deviation 0.45) and 0.55 mm (standard deviation 0.41) respectively. After 12 months in function, the averages obtained were 0.59 mm (standard deviation 0.48) on the distal surface and 0.57 mm on the mesial surface, (standard deviation 0.34). Conclusion: In this radiographic evaluation, it was possible to observe that the implants with prosthetic connection of the frictional Cone Morse type with platform switching presented an average of 0.2mm of cervical bone remodeling, after 12 months in function, seeming to be a good alternative for periodic bone maintenance deploy.

Keywords: Dentistry; Dental implants; Osseointegration.

Resumo

Objetivo: Avaliar radiograficamente a remodelação da crista óssea peri-implantar em implantes com conexões protéticas do tipo cone morse friccional, com plataforma switching, após 12 meses de carga protética. **Materiais e Métodos:** foram instalados 16 implantes, em 10 pacientes e reabilitados com próteses metalocerâmicas parciais, unitárias ou múltiplas; submetidos à função mastigatória durante o período de 12 meses. Radiografias periapicais para determinação da posição da crista óssea marginal mesial e distal em relação a plataforma de cada implante, foram realizadas no momento da instalação das próteses e 12 meses após. As imagens obtidas em diferentes intervalos foram digitalizadas e analisadas no software *Image J*^{TD}. **Resultados:** No momento da instalação das próteses, as médias das medidas nas faces distal e mesial foram 0,57 mm (desvio padrão 0,45) e 0,55 mm (desvio padrão 0,41), respectivamente. Após 12 meses em função, as médias obtidas foram 0,59 mm (desvio padrão 0,48) na face distal e 0,57 mm na mesial (desvio padrão 0,34). **Conclusão:** Por meio da avaliação radiográfica, foi possível observar que os implantes com plataforma switching e conexão protética cone morse friccional apresentaram em média 0,2mm de remodelação óssea cervical, após 12 meses em função, podendo ser uma boa alternativa para manutenção dos níveis ósseos.

Palavras-chave: Odontologia; Implantes dentários; Osseointegração.

Resumen

Objetivo: Evaluar radiográficamente la remodelación de la cresta ósea periimplantaria en implantes con conexiones protéticas de fricción como Morse, después de recibir la carga protésica, inmediatamente después de la instalación de la prótesis y después de 12 meses de carga funcional. **Materiales y métodos:** se instalaron 16 implantes en 10 pacientes y se rehabilitaron con prótesis metalocerámicas parciales, unitarias o múltiples; sometido a la función masticatoria durante el período de 12 meses. Se realizaron radiografías periapicales para determinar la posición de la cresta ósea marginal mesial y distal en relación a la plataforma de cada implante, en el momento de la instalación de las prótesis y 12 meses después. Las imágenes obtenidas a diferentes intervalos fueron digitalizadas y analizadas mediante el software *Image J*^{TD}. **Resultados:** En el momento de la instalación de las prótesis, los promedios de las medidas en las superficies distal y mesial fueron de 0,57 mm (desviación estándar 0,45) y 0,55 mm (desviación estándar 0,41), respectivamente. Después de 12 meses en función, los promedios obtenidos fueron de 0,59 mm (desviación estándar 0,48) en la superficie distal y 0,57 mm en la mesial (desviación estándar 0,34). **Conclusión:** A través de la evaluación radiográfica se pudo observar que los implantes con plataforma switching y conexión protésica con como morse de fricción mostraron un promedio de 0.2 mm de remodelado óseo cervical, luego de 12 meses en función, y pueden ser una buena alternativa para mantenimiento de los niveles óseos.

Palabras clave: Odontología; Implantes dentales; Osteointegración.

1. Introduction

Osseointegrated implants are now an indispensable tool in the oral rehabilitation of patients who have partially or totally lost their dental arch. Nowadays, it is well established that dental implants contribute to the masticatory and aesthetic rebitation after tooth loss (Schropp et al., 2003; Paolantonio et al., 2001; Covani et al., 2003). In addition, studies show the healing time of the socket after a dental extraction for implant installation, which was 6 months in the protocol advocated by Branemark in 1985, can be abbreviated, as full medical use is not required. The implant socket can be installed at the time of dental extraction without the same surgical procedure or after early healing of the socket 8 weeks after dental extraction (Covani et al., 2003; Juodzbaly, 2003; Schropp et al., 2005).

The morse cone system has advantages in terms of interface sealing, which results in less micro-infiltrations by micro-organisms that cause peri-implantation and has superior mechanics when compared to the external hexagon (Silva et al., 2020).

In the posterior mandible region, osseointegrated implants are subjected to great chewing forces, such that their micro and macrogeometry and prosthetic connection are important characteristics in order to adequately support these forces. The geometrical characteristics and surface treatments of the implant are factors that influence the success of the immediate or early installation, increasing the primary stability and the bone-implant contact and associated with the type of prosthetic connection, are factors that will preserve the peripheral biological tissues. implant, such as alveolar bone and soft tissue (Schropp et al., 2005).

Increased preservation of these structures avoids or decreases the occurrence of biological complications such as peri-implant bone loss, infectious / inflammatory diseases such as peri-implantitis and soft tissue recession. These complications lead to aesthetic sequelae and diminish long-term implant success.

2. Methodology

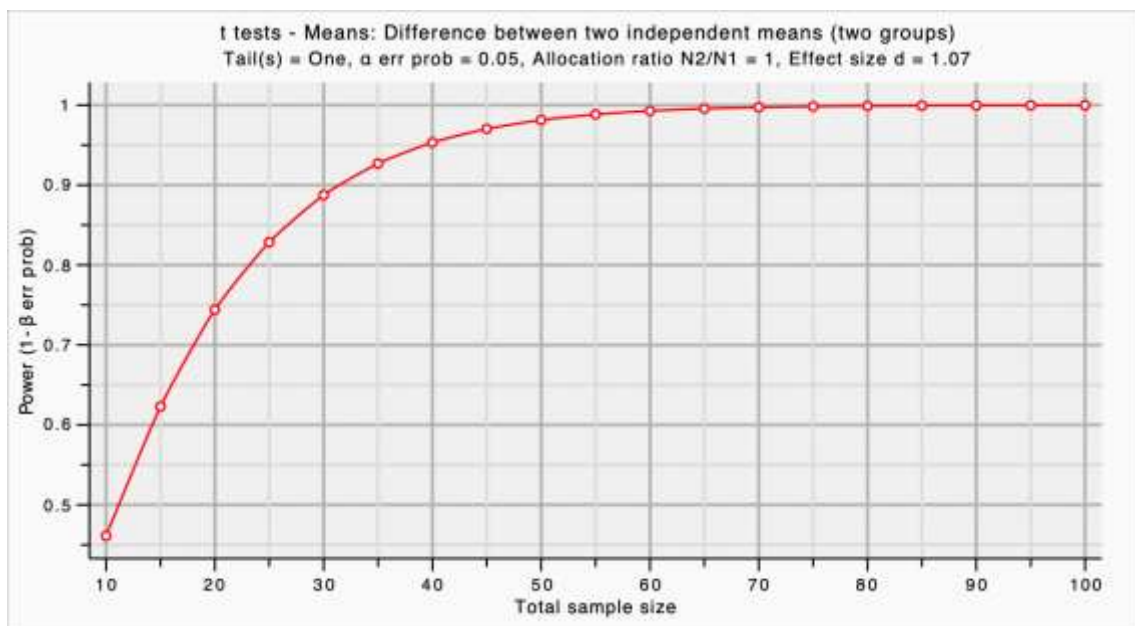
The study followed the regulatory norms of research in human beings and was approved by the Research Ethics Committee of the Metropolitan University of Santos – UNIMES, having been given a favorable opinion (Opinion Number: 2.399.592). The patients were informed of the clinical and surgical procedures to which they were submitted and signed the informed consent form previously approved by the Research Ethics Committee.

2.1 Study design

Sample Calculation

The sample effect size (x / sd) is considered large at 1.07 (Figure 1). With this effect, the power analysis of the test shows that to reach a power of 80% would require at least 15 cases per group, and the study was performed with a total of 16 implants.

Figure 1. Sample Effect Size.



Source: Authors.

Inclusion criteria

Individuals who lacked the premolars or lower or upper premolars who needed prosthetic rehabilitation with osseointegrated implants were selected for the study. Patients should be in good general and dental health.

Exclusion Criteria

Smokers, pregnant women, diabetics, patients with osteoporosis or any other immunosuppressive disease, or at-risk groups.

2.2 Surgical procedures and randomization

Surgical Planning

All patients underwent radiographic examination of the edentulous area and complementary blood tests to assess their health status. If any changes were found, this patient was excluded from the study group. From the imaging exams, the amount of bone available in the region for the installation of osseointegrated implants was determined.

Surgical Procedures

The implant insertion technique followed the following steps:

- Local buccal and lingual anesthesia, with vestibular sac fundus infiltrations and lingual / palatal mucosa.
- Alveolar crest rectilinear incision.
- Mucosal detachment with exposure of underlying bone crest and buccal bone.
- Bed preparation with the sequence of drills corresponding to the implant system (ArcsysTM FGM, Brazil) and installation of 1 to 2 mm infra-bone implants.
- Suture with simple stitches.

2.3 Implant reopening and implant prosthesis confection

A period of at least 3 months was expected for reopening of the implants and installation of the healing abutments. From then on, the implant prosthesis sequence was made. At the time of prosthesis installation over the implants, periapical x-ray was performed to determine the position of the initial mesial and distal marginal bone crest in relation to the implant platform.

Sixteen implants were installed in 10 patients, rehabilitated as partial, single or multiple metal-ceramic prostheses, submitted to masticatory function during a 12-month period. All installed prostheses were screwed onto the screwed abutment of the Arcsys system. At the time of implant implant prosthesis, periapical radiographs were performed to initially assess the position of the bone crest.

2.4 Radiographic evaluations

At the time of prosthesis installation over the implants, periapical x-ray was performed to determine the position of the mesial and distal marginal bone crest in relation to the platform of each implant.

For the standardization of radiographs, a positioner was used for periapical radiography. A portion of condensation silicon was placed on the surface of the evaluated tooth and its antagonist for the impression of the anatomy of these surfaces and adapted to the positioner. This maneuver allowed the same position of the film at different evaluation periods, as well as the standardization of the same incidence of X-rays, the same vertical and horizontal angulation and distance in all radiographic shots of the same patient.

Radiographic images at different intervals were scanned for analysis and measurement of the distance between the proximal and distal bone ridges and the implant platform. For this, the Image J program was used (Figure 5).

3. Results

Table 1 shows the distribution of installed implants that received a prosthetic load.

Table 1. Distribution of installed implants that received prosthetic load.

Region	n
35	2
34	1
45	2
36	3
46	3
16	2
37	1
25	1
15	1
Total	16

Source: Authors.

Radiographic Evaluation

Comparison of average results in millimeters over the initial periods (time of prosthesis installation) and final (6 months of functional load) are listed in Table 2.

Table 2. Comparison of means in millimeters before and after mesial and distal region.

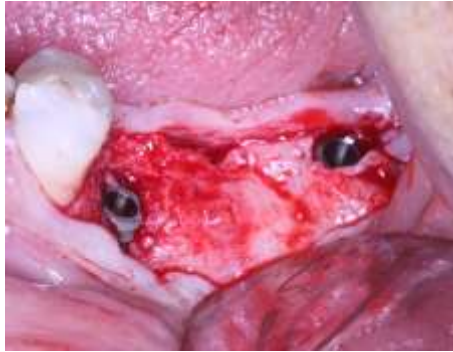
Measurements	Mean	N	Standard deviation	Standard error	IC (95%)	p-value
Distal before	0,57744	16	0,452752	0,113188		
Distal after	0,59919	16	0,483299	0,120825	-0,91-0,48	0,518
Mesial before	0,55650	16	0,411294	0,102824		
Mesial after	0,57369	16	0,345097	0,086274	-0,93-0,58	0,636

Source: Authors.

There was no statistically significant difference between initial and final in the measurement, neither mesial nor distal ($p > 0.05$).

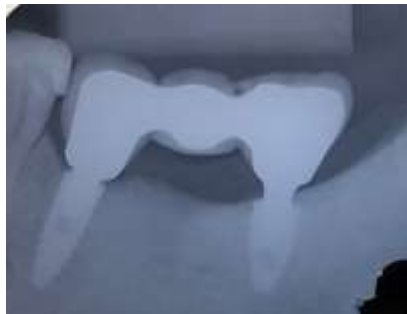In Figure 2, we can observe the moment of installation of the Arcsys 3.8 x 11.5 mm implants in the region 35 and 4.3 x 8.5 mm in the region 37 and in Figure 3 and 4, respectively, the periapical radiographs when the prosthesis was installed. on the implants and with 12 months in function. The Figure 5 mostra the moment of measurement of the distance from the mesial bone crest to the implant platform, in the *Image J software*^{TD}.

Figure 2. Moment of implants 35 and 37 placements.



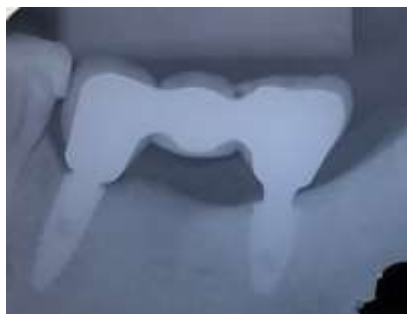Source: Authors.

Figure 3. Radiographic aspect at time of prosthetic placement.



Source: Authors.

Figure 4. Radiographic aspect after 12 months in function.



Source: Authors.

Figure 5. Moment of measurement of the distance from the mesial bone crest to the implant platform, in the *Image J software*^{TD}.



Source: Authors.

4. Discussion

Albrektsson et al. (1986) defined as successful for implant rehabilitation, an annual bone loss of up to 2 mm in the first year in prosthetic function, and this index is still currently used as a measure of success in implant-supported rehabilitations.

In a recent systematic review, Palacios-Garzón et al. (2019) suggested that crestal bone remodeling is always expected when we install osseointegrated implants, varying depending on some factors such as tissue characteristics, vertical implant position, platform switching concept and type of prosthetic connection.

Fickl et al. (2010) showed mean values of crestal bone loss at the time of definitive prosthesis insertion of 0.30 ± 0.07 mm for implants with "platform switching" and 12 months after insertion of the definitive prosthesis, the mean loss crestal bone was 0.39 ± 0.07 mm in internal connection implants.

Kutan-Misirlioglu et al. (2014) obtained an average of 0.9 mm of crestal bone remodeling in 1mm infra-bone platform switching implants and 0.4 mm of crestal bone remodeling in bone platform platform-switching implants, both with 12 months of prosthetic function.

5. Conclusion

The present study showed minimal bone loss around implants in the first 12 months of prosthetic load, with no statistically significant difference between the time of prosthesis installation and the first 12 months in prosthetic function, in agreement with other studies that reported less remodeling of the crestal bone around platform switching implants.

In addition, compared to these authors, the present study showed a lower average of crestal bone remodeling, with values obtained of 0.2 mm between the initial measurement at the time of prosthesis installation and the final measurement at 12 months in function.

Based on this radiographic evaluation, it is possible to suggest that Arcsys implants, with platform switching and frictional cone morse prosthetic connection, allow great crestal bone preservation around the implants in the first 12 months of prosthetic function.

References

Albrektsson, T., Zarb, G., Worthington, P., & Eriksson, A. R. (1986). The long-term efficacy of currently used dental implants: a review and proposed criteria of success. *Int j oral maxillofac implants*, 1(1), 11-25.

Branemark, P. I. (1985). Introduction to osseointegration. *Tissue-integrated prostheses*, 11-76.

- Covani, U., Bortolaia, C., Barone, A., & Sbordone, L. (2004). Bucco-lingual crestal bone changes after immediate and delayed implant placement. *Journal of Periodontology*, 75(12), 1605-1612.
- Covani, U., Cornelini, R., & Barone, A. (2003). Bucco-lingual bone remodeling around implants placed into immediate extraction sockets: A case series. *Journal of Periodontology*, 74(2), 268-273.
- Fickl, S., Zuhr, O., Stein, J. M., & Hürzeler, M. B. (2010). Peri-implant bone level around implants with platform-switched abutments. *The International journal of oral & maxillofacial implants*, 25(3), 577.
- Juodzbaly, G. (2003). Instrument for extraction socket measurement in immediate implant installation. *Clinical oral implants research*, 14(2), 144-149.
- Kutan-Misirlioglu, E., Bolukbasi, N., Yildirim-Ondur, E., & Ozdemir, T. (2014). Clinical and Radiographic Evaluation of Marginal Bone Changes around Platform-Switching Implants Placed in Crestal or Subcrestal Positions: A Randomized Controlled Clinical Trial. *Clinical Implant Dentistry and Related Research*.
- Palacios-Garzón, N., Velasco-Ortega, E., & López-López, J. (2019). Bone loss in implants placed at subcrestal and crestal level: A systematic review and meta-analysis. *Materials*, 12(1), 154.
- Paolantonio, M., Dolci, M., Scarano, A., d'Archivio, D., Di Placido, G., Tumini, V., & Piattelli, A. (2001). Immediate implantation in fresh extraction sockets. A controlled clinical and histological study in man. *Journal of periodontology*, 72(11), 1560-1571.
- Schropp, L., Kostopoulos, L., Wenzel, A., & Isidor, F. (2005). Clinical and radiographic performance of delayed-immediate single-tooth implant placement associated with peri-implant bone defects. A 2-year prospective, controlled, randomized follow-up report. *Journal of Clinical Periodontology*, 32(5), 480-487.
- Schropp, L., Wenzel, A., Kostopoulos, L., & Karring, T. (2003). Bone healing and soft tissue contour changes following single-tooth extraction: a clinical and radiographic 12-month prospective study. *International Journal of Periodontics & Restorative Dentistry*, 23(4).
- Silva, R. M. M. da, Rolim, A. K. A., Delgado, L. A., Sousa, J. T., Ribeiro, R. A., Rodrigues, R. de Q. F., & Rodrigues, R. A. (2020). Cone morse x external hexagon, advantages and disadvantages in the clinical aspect: literature review. *Research, Society and Development*, 9(7), e454973947. <https://doi.org/10.33448/rsd-v9i7.3947>