

Large solitary neurofibroma of the cheek mucosa: a case report

Extenso neurofibroma solitário em mucosa jugal: relato de caso

Neurofibroma solitario extenso en la mucosa de la mejilla: reporte de caso

Received: 02/12/2021 | Reviewed: 02/18/2021 | Accept: 02/22/2021 | Published: 02/28/2021

Andre Luís Costa Cantanhede

ORCID: <https://orcid.org/0000-0001-5830-6713>

State University of Campinas, Brazil

E-mail: andre_ctbmf@hotmail.com

Carolinne da Glória Araújo

ORCID: <https://orcid.org/0000-0002-6362-0798>

Federal University of Maranhao Hospital, Brazil

E-mail: carolinne.odontoufma@gmail.com

Priscila Mayara Silva de Almeida

ORCID: <https://orcid.org/0000-0001-9068-4810>

Federal University of Maranhao Hospital, Brazil

E-mail: priscilaodonto@live.com

Hassan Lavalier de Oliveira Lima

ORCID: <https://orcid.org/0000-0001-9394-4526>

Federal University of Maranhao Hospital, Brazil

E-mail: hassan.lima@gmail.com

Abstract

Neurofibromas are uncommon benign tumors in the oral cavity, which are composed of Schwann cells, perineural-like cells, and fibroblasts. The diagnosis can be confirmed by histological examination and immunopositivity for the S-100 protein indicating its neural origin. Surgical excision is the treatment of choice, and the intraoral approach is the best route for a medium-sized lesion and the prognosis is excellent. This paper aims at to present a unusual case of large neurofibroma located at the cheek mucosa of a young man and review important aspects of this tumor in the oral cavity.

Keywords: Neurofibroma; Mucous membrane; Cheek; Mouth neoplasms.

Resumo

Neurofibromas são tumores benignos incomuns da cavidade oral, compostos por células de Schwann, células semelhantes a perineurais e fibroblastos. Seu diagnóstico pode ser confirmado por exame histológico e imunopositividade para a proteína S-100, indicando sua origem neural. A excisão cirúrgica é o tratamento de escolha, sendo a via intraoral a melhor opção para uma lesão de médio porte, sendo o prognóstico excelente. Este artigo objetiva apresentar um caso incomum de extenso neurofibroma localizado na mucosa jugal de um paciente jovem, além de revisar aspectos importantes desse tumor na cavidade oral.

Palavras-chave: Neurofibroma; Membrana mucosa; Bochecha; Neoplasias bucais.

Resumen

Los neurofibromas son tumores benignos poco frecuentes de la cavidad oral, compuestos por células de Schwann, células de tipo perineural y fibroblastos. Su diagnóstico puede confirmarse mediante examen histológico e inmunopositividad para la proteína S-100, lo que indica su origen neural. La escisión quirúrgica es el tratamiento de elección, siendo la vía intraoral la mejor opción para una lesión de tamaño medio, y el pronóstico es excelente. Este artículo tiene como objetivo presentar un caso inusual de neurofibroma extenso localizado en la mucosa de la mejilla de un paciente joven, además de revisar aspectos importantes de este tumor en la cavidad oral.

Palabras clave: Neurofibroma; Membrana mucosa; Mejilla; Neoplasias de la boca.

1. Introduction

Tumors with neurogenic origin are scarcely found in the oral cavity, among them neurofibroma (NF) is a rare tumor originating from the peripheral nerve sheath (Chrysomali et al., 1997; Depprich et al., 2009). The first description of this entity in the oral cavity was made by Bruce in 1954, with only sporadic cases reports of small/medium size lesions being described ever since. This tumor is usually a well-circumscribed, non-encapsulated lesion consisting of a mixture of Schwann cells, perineuronal cells, and endoneural fibroblasts (Chrysomali et al. 1997; Depprich et al. 2009; Broly et al., 2019; Papadopoulos et

al., 1981)

The frequency of this lesion is variable in the literature, ranging from 0.2% to 6.5% of the cases described in the oral cavity, with preferential sites being the tongue, followed by cheek mucosa, lips, palate, and even intraosseous in the alveolar inferior mandibular canal (Papadopoulos et al., 1981; Campos et al., 2012; Deichler et al., 2011). Clinical presentation varies as sessile or pedunculated nodules affecting the oral mucosa, which can be a solitary lesion or as a systemic part of the spectrum of the Neurofibromatosis type 1 (NF-1) (Angiero et al., 2016; Venkataswamy et al., 2016). Also, this tumor can be classified as a dermal or plexiform type – this being more associated with multiple small nerve bundles and locally invasive – the former is more myxoid and arising from a single peripheral nerve (Venkataswamy et al., 2016)

This paper aims to present a case of large solitary neurofibroma in the oral cavity and to provide a literature background on the main aspects of this lesion concerning clinical behavior, diagnosis, and treatment.

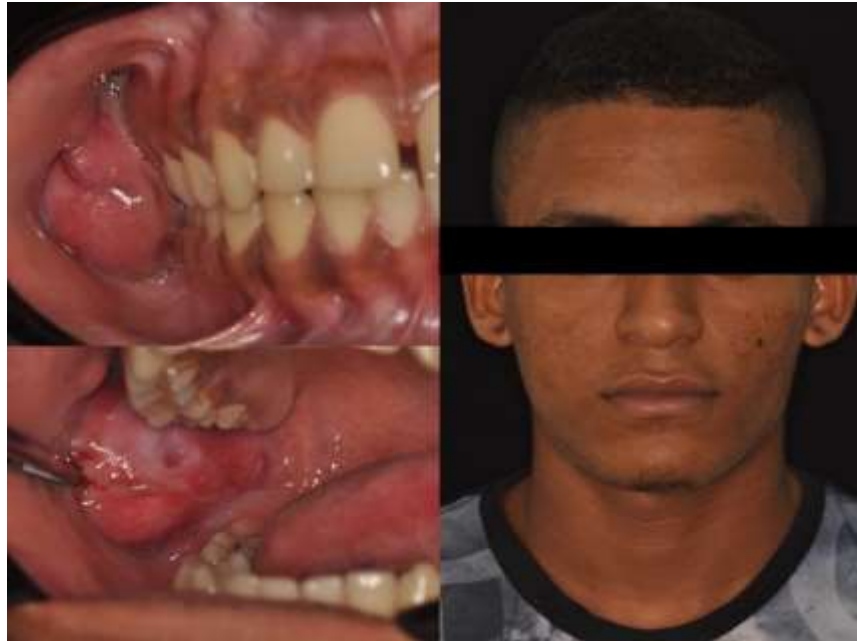2. Methodology

This report represents a descriptive and qualitative content. The case was conducted according to clinical and professional ethics. The patient has authorized the use of his images, clinical, radiographic and socioeconomic data for educational and research purposes, through a signed and Free and Informed Consent Form, which were duly read and explained. The procedures followed were in accordance with ethical standards in human research according to the Helsinki Declaration of 1975, as revised in 1983.

3. Case Report

A 19-year-old black male patient attending the dental clinic at the Federal University of Maranhão was referred to the oral and maxillofacial surgery department - Presidente Dutra Hospital with a chief complaint of a non-inflammatory swelling in the right cheek mucosa area. The patient referred the presence of this mass for about 4 years, with slowing and painless growth (Figure 1); there was no paresthesia associated as well as no history of a traumatic event that he could remember, although during chewing, he traumatized the lesion due to its size, his medical records were clear.

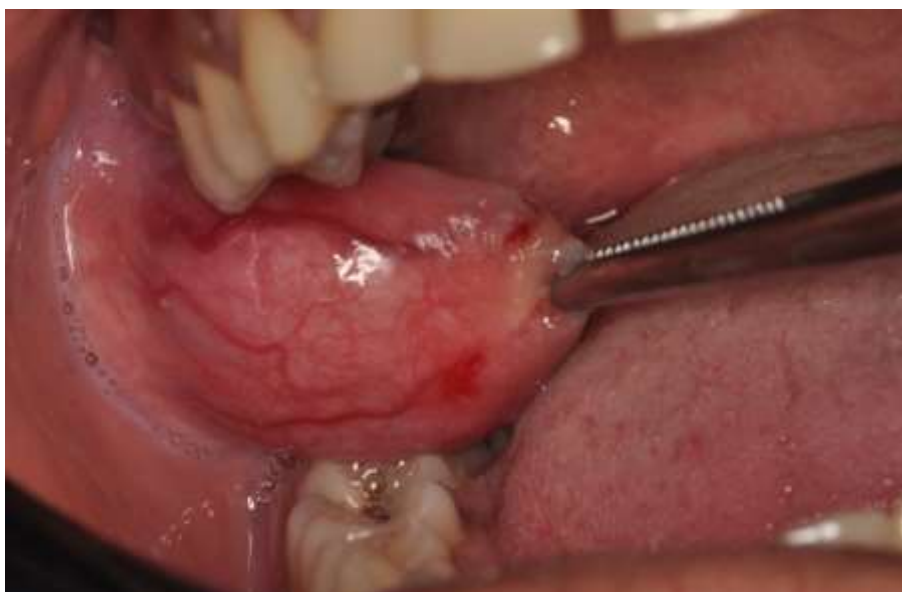Figure 1. Facial aspect of the patient with no facial assymetry. Intra-oral aspect of the mass protuding from cheek mucosa with sessile base.



Source: Authors

During the clinical evaluation, the right cheek area showed a large sessile, elastic consistency, and circumscribed mass, which was covered by normal movable mucosa and presented some vessels visible through it, the lesion itself measured approximately 3,5 x 2,5 x 2cm (Figure 2). We sought for body signs, and no evidence of cutaneous or subcutaneous lesions, nor brown-pigmented café-au-lait spots on the trunk and upper arms were found. We performed fine-needle aspiration with a negative result for liquids or blood, and based on the clinical features, the presumptive diagnosis was lipoma, fibroma, or traumatic neuroma.

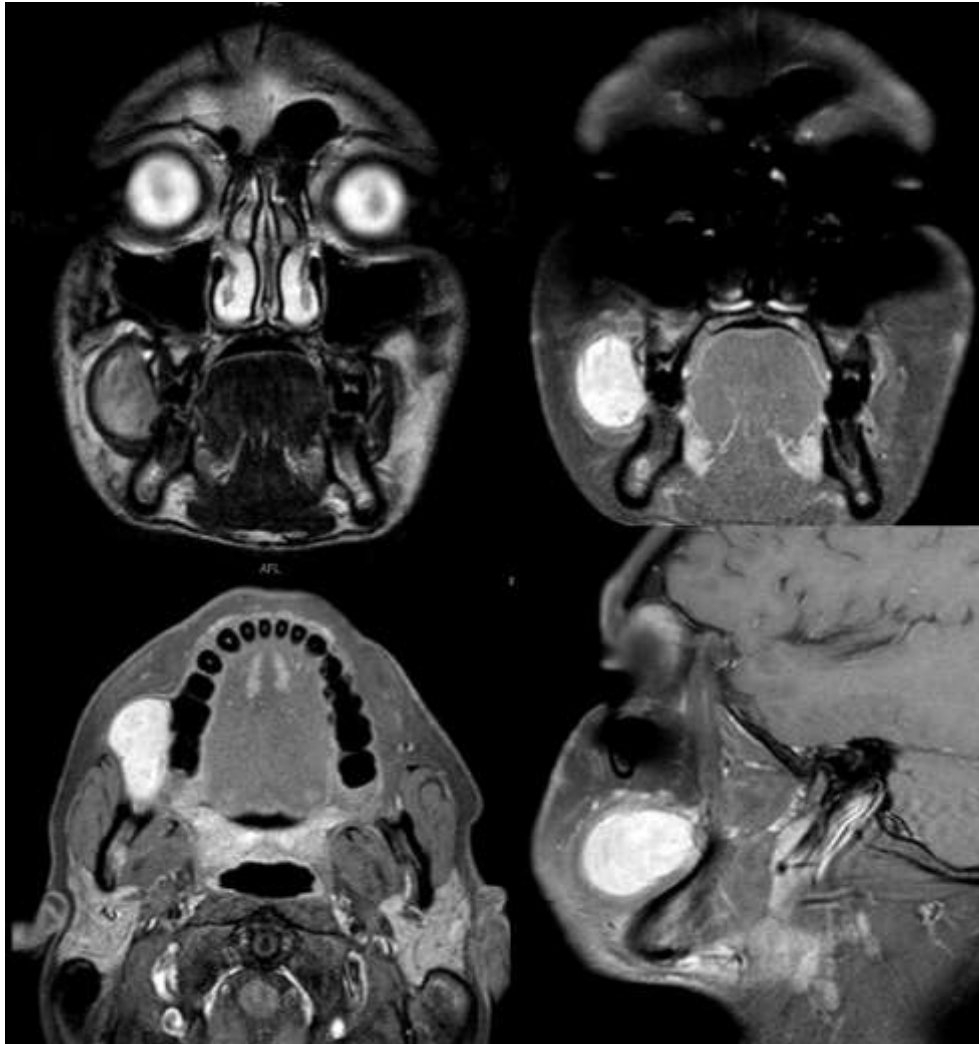
Figure 2. Intra-oral closely view of the tumor with superficial vessels under buccal mucosa. Previous aspiration of the lesion was negative.



Source: Authors

Magnetic resonance imaging (MRI) was requested and showed an isolated well-circumscribed mass expanding from the right buccal space tissues, with a hypointense homogenous signal at T1 and a T2-weighted image with high signal intensity, (Figure 3) thus our clinical hypothesis focused on lipoma and traumatic neuroma.

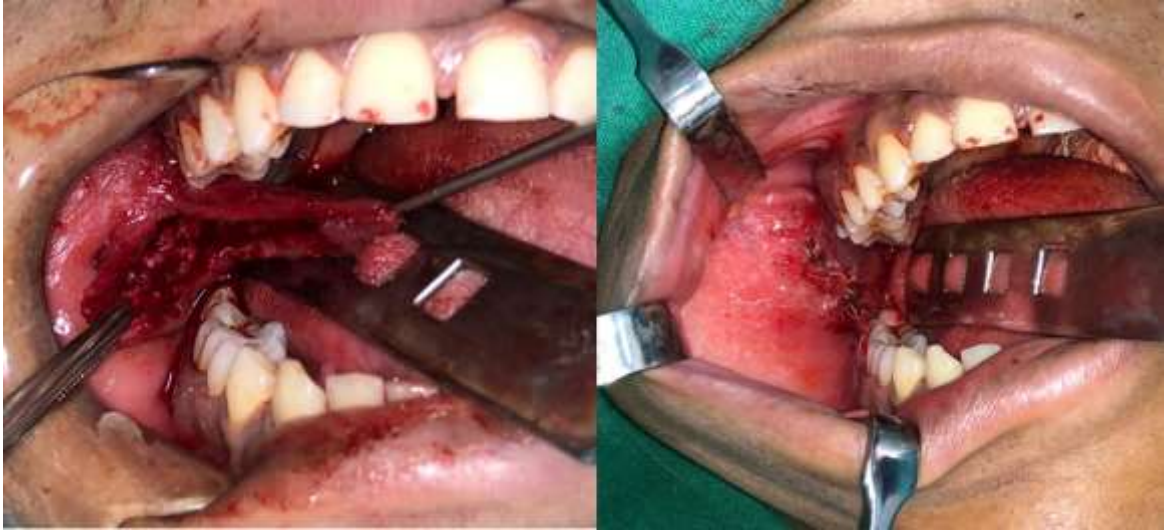Figure 3. MRI coronal views (above) - T1-weighted image show a low homogeneous signal of the mass. Axial and sagittal views (below) at T2-weighted image showing the high signal intensity of the mass.



Source: Authors

Due to the benign character of the lesion, our surgical team performed its complete excision under IV sedation and local anesthesia with infiltration of 2 cartridges of Articaine 4% + epinephrine 1:100.000 in the surrounding tissue. Firstly, a mucosa-only incision and rhomboid divulsion surrounding the lesion until reaches its base was made. With an Allis clip, the base of the lesion was grasped and the lesion was fully excised with electrocautery and no major vessels could be seen. The mucosa excess was removed and the access closed with absorbable sutures (Figure 4), the operation was uneventful, the patient was discharged hours later with pain and edema medication, additionally, an external compressive dressing.

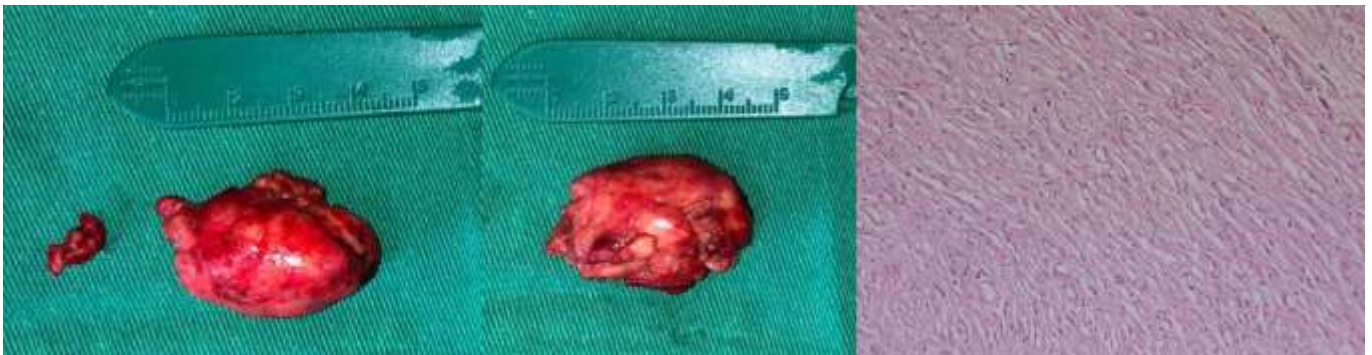Figure 4. Intra-oral aspect of the surgical site after complete excision of the lesion, excess of mucosa was removed and simple continuous resorbable suture was performed.



Source: Authors

The specimen was sent to histopathological evaluation with additional immunohistochemical screening, with the final diagnosis of neurofibroma and positive staining for S-100 protein, with no evidence of ongoing mitosis (Figure 5). The patient attended follow-up consultations at 1 week, 1 month, and 6 months, never returning afterward. No infection occurred during this period, local mucosa healed well and the patient's only referred local numbness, without major distresses.

Figure 5. Macroscopic aspect of the lesion (left and right side). Histopathology demonstrated well-spaced, spindle-shaped cells with elongated, thin nuclei and scant cytoplasm, surrounded by a collagenous matrix situated in the myxoid stroma. Later immunohistochemical analysis was positive for staining with Vimentin and the cells were positive for protein S-100 and CD57, consistent with neural tissue origin.



Source: Authors.

4. Discussion

Solitary oral neurofibromas consist of slow-growing, rarely painful submucosal masses, and neurological disturbances are often uncommon (Broly et al., 2019). They mainly appear in the third decade of life although occurrence between 10 months and 70 years old has been described in the literature, with no gender predilection (Deprich et al., 2009; Marocchio et al., 2007; Salla et al., 2011).

Their etiological factor is unclear, some authors believe that solitary neurofibromas seem to contain hyper material of a hamartomatous and non-neoplastic nature. Maxillofacial lesions usually originate from branches of the trigeminal and

occasionally from the seventh pair (Chrysomali et al., 1997; Broly et al., 2019). The neural origin of the lesion presented in this report is thought to arise from the buccal nerve, as after its surgical excision the main patient complaint was paresthesia in the right inner cheek and posterior vestibular mucosa.

Broly et al., (2019) reviewed the literature and found 26 cases of neurofibromas in the oral cavity reported in English literature with just one case located at the cheek. All of which were found to developing from trigeminal branches.

As solitary neurofibromas can be presented in association with generalized NF-1 (or von Recklinghausen's disease of the skin), therefore, the presence of a solitary lesion requires physical examination and family history to exclude the disease (Depprich et al., 2009; Bruce, 1954). In our case, there were no clinical signs, nor family history suggestive of NF-1.

Neurofibroma sometimes is found as a firm oval or rounded-shape mass located in subcutaneous/submucosal tissues, thus making a differential diagnosis with lipoma, fibroma and sharing the same neural origin with other tumors (eg. schwannoma, traumatic neuroma, nerve sheath myxoma) (Chrysomali et al., 1997; Broly et al., 2019). Therefore, MRI and histological examination are mandatory to confirm the diagnostic. In our case, the MRI T2 signal depicted a high-intensity signal, this correlates with a myxoid, edematous and weakly cellular aspects observed in histopathological examination.

A histopathological analysis is essential and treatment, in this case, aims at the complete removal of the lesion, preserving the associated nerve bundles as much as possible. Campos et al. (2012) studied the clinicopathological features and immunohistochemical profile of 22 neurofibromas (NFs) of the oral cavity, they found 18 cases (81,8%) affecting oral soft tissues and 16 cases (72,7%) of these as solitary lesions, without exceeding 2cm in diameter; besides, none of the initial clinical hypothesis was made as neurofibromas. Another study by Salla et al (2009), investigated epidemiological features of oral peripheral nerve sheath tumors in a Brazilian population, they found only 32 cases (0,2%) from 21,476 specimens biopsied within a forty-year period, 10 (28,6%) of them were composed by solitary neurofibromas with only 2 (5,6%) linked with NF-1, thus making this lesion extremely rare.

From a histological standpoint, there should be an immunopositivity for the S-100 protein in about 85–100% of the cases, which confirms its neural origin (Depprich et al., 2009; Venkataswamy et al., 2016; Salla et al., 2011). This is in agreement with the study by Campos et al. (2012), whose research found only 5 cases with less than 5% positivity for S-100. In our case, later immunohistochemical evaluation revealed positive staining for S-100.

There is no specific rate of recurrence for this lesion in the literature, however, careful surgical dissection and excision should be performed as the associated nerve can be injured, leaving the patient with unpleasant sequelae (Depprich et al., 2009; Papadopoulos et al., 1981; Marocchio et al., 2007). Angiero et al. (2016) successfully removed oral neurofibromas in 10 patients using a diode laser (wavelength 980nm, 2.0 W power in continuous mode with a 320 μ optical fiber for 45s), 6 out 10 patients did not require local anesthesia, and surgical sites healed extremely well after 15 days. In our case, no major surgical complications were noted and giving the intra-oral access, the patient had no major neurological or aesthetic damage.

5. Final Considerations

Oral swellings in the oral cavity might have sometimes similar clinical presentations, yet from different origins (e.g odontogenic or not; benign or malignant). Neurofibromas can present themselves as solitary lesions in different sites in the oral cavity, thus making them less likely to be the first hypothesis in clinical diagnosis. MRI (T1, T2, and DP weighted views) should be considered in all cases of large lesions with soft-tissue infiltration for more information about the limits and extension. Surgical excision is the main treatment of this pathology, and immunopositivity for the S-100 should be tested in all suspected cases.

Competing Interests

The authors deny any conflicts of interest related to this study.

References

- Chrysomali, E., Papanicolaou, S. I., Dekker, N. P., & Regezi, J. A. (1997). Benign neural tumors of the oral cavity: a comparative immunohistochemical study. *Oral Surg Oral Med Oral Pathol Oral Radiol Endod.* 84(4):381-90. [10.1016/s1079-2104\(97\)90036-6](https://doi.org/10.1016/s1079-2104(97)90036-6).
- Depprich, R., Singh, D. D., & Reinecke, P. et al. (2009). Solitary submucous neurofibroma of the mandible: review of the literature and report of a rare case. *Head Face Med.* 5, 24. <https://doi.org/10.1186/1746-160X-5-24>
- Bruce, K. W. (1954). Solitary neurofibroma (neurilemmoma, schwannoma) of the oral cavity. *Oral Surg Oral Med Oral Pathol.*7:1150-1159. [https://doi.org/10.1016/0030-4220\(54\)90307-2](https://doi.org/10.1016/0030-4220(54)90307-2)
- Broly, E., Lefevre, B., Zachar, D. et al. (2019). Solitary neurofibroma of the floor of the mouth: rare localization at lingual nerve with intraoral excision. *BMC Oral Health.* 19, 197. <https://doi.org/10.1186/s12903-019-0888-0>
- Papadopoulos H., Zachariades N., & Angelopoulos A. P. (1981). Neurofibroma of the mandible. Review of the literature and report of a case. *Int J Oral Surg.* 10(4):293-7. [https://doi.org/10.1016/s0300-9785\(81\)80074-9](https://doi.org/10.1016/s0300-9785(81)80074-9).
- Campos, M. S., Fontes A., Marocchio L. S., Nunes F. D., & de Sousa S. C. (2012). Clinicopathologic and immunohistochemical features of oral neurofibroma. *Acta Odontol Scand.* 70(6):577-82. <https://doi.org/10.3109/00016357.2011.640286>.
- Deichler J., Martínez R., Niklander S., Seguel H., Marshall M., & Esguep A. (2011). Solitary intraosseous neurofibroma of the mandible. Apropos of a case. *Med Oral Patol Oral Cir Bucal.* 16(6): e704-7. <https://doi.org/10.4317/medoral.16853>
- Angiero F., Ferrante F., Ottonello A., Maltagliati A., & Crippa R. (2016). Neurofibromas of the Oral Cavity: Clinical Aspects, Treatment, and Outcome. *Photomed Laser Surg.* 34(2):56-60. <https://doi.org/10.1089/pho.2015.3925>.
- Venkataswamy A. R., Ranganath S. P., Challapalli S. M., & Mohanthy L. (2016). Nonsyndromic solitary neurofibromas in the oral cavity: case series and literature review. *J Indian Acad Oral Med Radiol.* 28:52-6. <https://doi.org/10.4103/0972-1363.189992>
- Marocchio L. S., Oliveira D. T., Pereira M. C., Soares C. T., & Fleury R. N. (2007). Sporadic and multiple neurofibromas in the head and neck region: a retrospective study of 33 years. *Clin Oral Investig.* 11(2):165-9. <https://doi.org/10.1007/s00784-006-0096-6>.
- Salla, J. T., Johann, A. C. B. R., Garcia, B. G., Aguiar, M. C. F., & Mesquita, R. A. (2009). Retrospective analysis of oral peripheral nerve sheath tumors in Brazilians. *Brazilian Oral Research* 23(1), 43-48. <https://doi.org/10.1590/S1806-83242009000100008>