

## Evolutionary Leap in Endodontics. Case report

Salto Evolutivo em Endodontia. Relato de caso

Salto Evolutivo em Endodoncia. Reporte de un caso

Received: 03/04/2021 | Reviewed: 03/10/2021 | Accept: 03/15/2021 | Published: 03/21/2021

**Jose Maurício Paradella de Camargo**

ORCID: <https://orcid.org/0000-0003-1894-9225>

São Paulo State University, Brazil

E-mail: [mauricio@clinicacamargo.com](mailto:mauricio@clinicacamargo.com)

**Rafael Verardino de Camargo**

ORCID: <https://orcid.org/0000-0002-6546-9980>

University of São Paulo, Brazil

E-mail: [rafael@clinicacamargo.com](mailto:rafael@clinicacamargo.com)

**Luciano Tavares Angelo Cintra**

ORCID: <https://orcid.org/0000-0003-2348-7846>

São Paulo State University, Brazil

E-mail: [luciano.cintra@unesp.br](mailto:luciano.cintra@unesp.br)

**Flávio Duarte Faria**

ORCID: <https://orcid.org/0000-0003-4269-7902>

São Paulo State University, Brazil

E-mail: [flaviodfaria96@gmail.com](mailto:flaviodfaria96@gmail.com)

**Alberto Consolaro**

ORCID: <https://orcid.org/0000-0002-5902-5646>

University of São Paulo, Brazil

E-mail: [consolaro@uol.com.br](mailto:consolaro@uol.com.br)

**Densen Cao**

ORCID: <https://orcid.org/0000-0001-7637-1754>

CAO Group, Material Science and Engineering, United States

E-mail: [densen.cao@caogroup.com](mailto:densen.cao@caogroup.com)

**Renato de Toledo Leonardo**

ORCID: <https://orcid.org/0000-0002-0672-9981>

São Paulo State University, Brazil

E-mail: [renato.leonardi@unesp.br](mailto:renato.leonardi@unesp.br)

### Abstract

The Leap protocol combines the newest and most active association of reciprocal-rotary instrumentation, aluminum insert ultrasonic, and diode laser. The reciprocal-rotary technique consists of Niti instruments used in different motions depending on the stage of the treatment and promotes the balanced cutting effectiveness and reduced risk of fracture files. Moreover, it creates a centered and tapered shape. The aluminum tip for the ultrasonic unit delivers agitation, emulsification, and cavitation of antiseptic solutions that improve the cleaning. The dye and laser use cause the ablation and final disinfection. This paper describes the case of a patient with asymptomatic apical periodontitis in an upper first right molar submitted to endodontic treatment performed with Leap protocol. After conventional procedures, the root canals were prepared by using reciprocal-rotary instrumentation techniques. Between each file a new solution was placed and activated with the ultrasonic handpiece. At the end of instrumentation, the root canals were aspirated, dried with paper points, the indocyanine dye was placed into the root canals and, DaVinci laser was used for 30 seconds. The gutta-percha cones matching the final Niti file were used coated with AH Plus sealer. A periapical radiograph was taken to verify obturation and its anatomical complexity. Six months after the procedure, the patient was asymptomatic, and the radiographic examination showed healthy periradicular tissues. It is concluded that the use of Leap protocol in conventional endodontic treatment was effective, suggesting that this therapy may provide additional benefits to patients when compared to the conventional technique.

**Keywords:** Endodontics; Technological development; Root canal therapy.

### Resumo

O protocolo Leap combina a associação mais recente e ativa de técnicas de instrumentação rotativa-recíproca, inserto ultrassônico e laser de diodo. A técnica rotativa-recíproca consiste em instrumentos Niti utilizados em diferentes movimentos dependendo da fase do tratamento e promove a eficácia de corte equilibrada e redução do risco de fraturas das limas. Além disso, cria uma forma centralizada e afilada. O inserto ultrassônico oferece agitação, emulsificação e cavitação de soluções antissépticas que melhoram a limpeza. O uso do corante e do laser causa a ablação e desinfecção final. Este trabalho descreve um caso clínico com periodontite apical assintomática em primeiro molar superior direito submetido a tratamento endodôntico realizado com protocolo Leap. Após procedimentos

convencionais, os canais radiculares foram preparados por meio de técnicas de instrumentação rotatória recíproca. Entre cada lima, nova solução era colocada e ativada com peça de mão ultrassônica. Ao final da instrumentação, os canais radiculares foram aspirados, secos com pontas de papel, o corante indocianina verde colocado nos canais radiculares e o laser DaVinci utilizado por 30 segundos. Os cones de guta-percha correspondentes à lima Niti final foram usados besuntados com o selante AH Plus. Uma radiografia periapical foi realizada para verificar a obturação e sua complexidade anatômica. Seis meses após o procedimento, o paciente estava assintomático, e o exame radiográfico mostrou tecidos periapicais saudáveis. Conclui-se que a utilização do protocolo Leap no tratamento endodôntico convencional foi eficaz, sugerindo que essa terapia pode trazer benefícios adicionais aos pacientes quando comparada à técnica convencional.

**Palavras-chave:** Endodontia; Avanço tecnológico; Tratamento de canal radicular.

### Resumen

El protocolo Leap combina la asociación más nueva y activa de técnicas de instrumentación rotatoria-recíproca, inserto ultrasónico y láser diodo. La técnica rotación-recíproca consiste en instrumentos Niti utilizados en diferentes movimientos según la etapa del tratamiento y promueve la efectividad de corte equilibrado y reducción del riesgo de fracturas de limas. Además, crea forma centrada y cónica. La punta ultrasónica proporciona agitación, emulsificación y cavitación de soluciones antisépticas que mejoran la limpieza. El uso de tintes y láser, provocan ablación y desinfección. Este trabajo describe un caso clínico con periodontitis apical asintomática en primer molar superior derecho sometido a tratamiento endodóntico realizado con protocolo Leap. Después de procedimientos convencionales, los conductos radiculares se prepararon utilizando técnicas de instrumentación rotatoria-recíproca. Entre cada lima se colocó nueva solución y se activó con la pieza de mano ultrasónica. Al final de la instrumentación, se aspiraron los conductos, se secaron con puntas de papel, se colocó el tinte de indocianina en los conductos y se utilizó láser DaVinci durante 30 segundos. Los conos de gutapercha que coincidían con la lima Niti final se utilizaron recubiertos con el sellador AH Plus. Se tomó radiografía periapical para verificar la obturación y su complejidad anatômica. Seis meses después del procedimiento, la paciente se encontraba asintomática y el examen radiográfico mostró tejidos perirradiculares sanos. Resulta que el uso del protocolo Leap en el tratamiento de endodoncia convencional fue efectivo, lo que sugiere que esta terapia puede brindar beneficios adicionales a los pacientes en comparación con la técnica convencional.

**Palabras clave:** Endodoncia; Desarrollo tecnológico; Tratamiento del conducto radicular.

## 1. Introduction

Endodontics is a clinical procedure, developed with different kinds of techniques<sup>1</sup>. Root canal treatment is not only one specific procedure. A relevant number of variables must be taken under consideration, and a correct evaluation of all these variables will drive the professional to choose the essential treatment. Unfortunately, a lot of dentists perform the root canal treatment according to one specific unique way, without taking into consideration the diagnosis or the biological factors related to the tooth (Bergenholtz 2016). Contemporary Endodontics is a science that embodies the etiology, diagnosis, prevention, and treatment of apical periodontitis and its repercussion in the human organism (Cintra et al. 2018). Levels of success show that after 4 years of endodontic therapy, approximately 50% of root canal treatments must be performed again depending on the dental group and the level of the canal filling (de Sousa Gomide Guimarães et al. 2019). This confirms that many clinicians base their practice of endodontics on opinions, personal history, and empirical deductions. “Responsible Endodontics” must be constructed under the guise of scientific, clinical, radiographic, and histopathological evidence.

The practice of endodontics should be addressed with a sense of responsibility and consideration of different options. One must give more serious attention to technological resources available for diagnosis, root canal negotiation, cleaning, shaping, and filling techniques that will increase post-treatment success (Plotino et al. 2016). During the last two decades, several new technologies have appeared on the market. Technologies for anesthesia (Mladenovic et al. 2019), electronic apex (foramen) locators (Zand et al. 2017), digital radiographs (Bruellmann et al. 2016), cone-beam computed tomography scans (Bueno et al., 2018), ultrasound units (De-Deus et al. 2020), lasers (Akbari et al. 2017), operating microscopes (Al Shaikhly et al. 2020), 3D concepts of obturation (Celikten et al., 2015) and 100 % inorganic root canal sealers (Khalil et al. 2016) are some examples. The most relevant change observed during this period has been the use of laser (Zorita-García et al., 2019). Even adequate biomechanical preparations with the use of a massive sort of NiTi instruments, ultrasonic irrigation, and antiseptic

solutions are not able to disinfect the root canal system (Xang et al., 2017). The remaining bacterium inside dentinal tubules, lateral canals, and anfractuositities can infect the root canal mass (Gonçalves et al., 2016). Microorganisms and its byproducts are doubtless related to the induction and perpetuation of pulpal, periradicular infections, and systemic diseases (Nagendrababu et al., 2019). There are more than 500 bacterial species known to be natural inhabitants of the oral cavity. However, the microbiota of root canals and related structures constitute a group of approximately 150 bacterial species identified. Infected root canals typically harbor a mixed microbiota, usually in combinations of 4-6 species per root canal with a high prevalence of anaerobes (Gomes et al. 2018).

Thus, successful endodontic therapy depends on proper cleaning and shaping of the root canal system and the elimination of microorganisms from the root canal, pulp tissue and necrotic debris (Rôças et al., 2016). To optimize the cleaning and shaping of the root canal, the mechanized rotary and oscillating and ultrasonic irrigation must work in conjunction with a more advanced tool. This is the reason lasers are becoming extremely important. It can be used to improve irrigation due to the cavitation effect, but mainly to eliminate bacteria that remain after prior protocols as biomechanical preparation and irrigation with ultrasonic units (Zorita-García et al., 2019). Moreover, the use of indocyanine green to dye bacterium improves the efficacy of 810um diode laser ablation (Bolhari et al., 2018).

Research shows that after adequate biomechanical preparation with the use of NiTi instruments in different motions, irrigation with antiseptic solutions/ultrasonic units and laser ablation with Indocyanine green, can eliminate the infection of the root canal system (Bolhari et al. 2018, Ghorbanzadeh et al. 2020). Considering all of these current technological resources, the Leap protocol was proposed as a way of aggregating all possible scientific-technological resources to achieve ever higher success rates. The evolutionary Leap protocol carries in its principle the name Leap, that is "Evolutionary Approach", as well as making reference to the name of who developed it "Leonardo Endodontics Advanced Procedure"

## 2. Methodology

This paper presents a case study (Pereira et al. 2018) carried out by an endodontic specialist who received the case from another non-specialist professional. It is a complex clinical case due to the difficulty in locating the root canals and the need to use modern technological resources for its execution and success. Thus, this paper describes the case of a patient with asymptomatic apical periodontitis in an upper first right molar submitted to endodontic treatment performed with Leap protocol. An informed consent form was signed before any procedure was carried out.

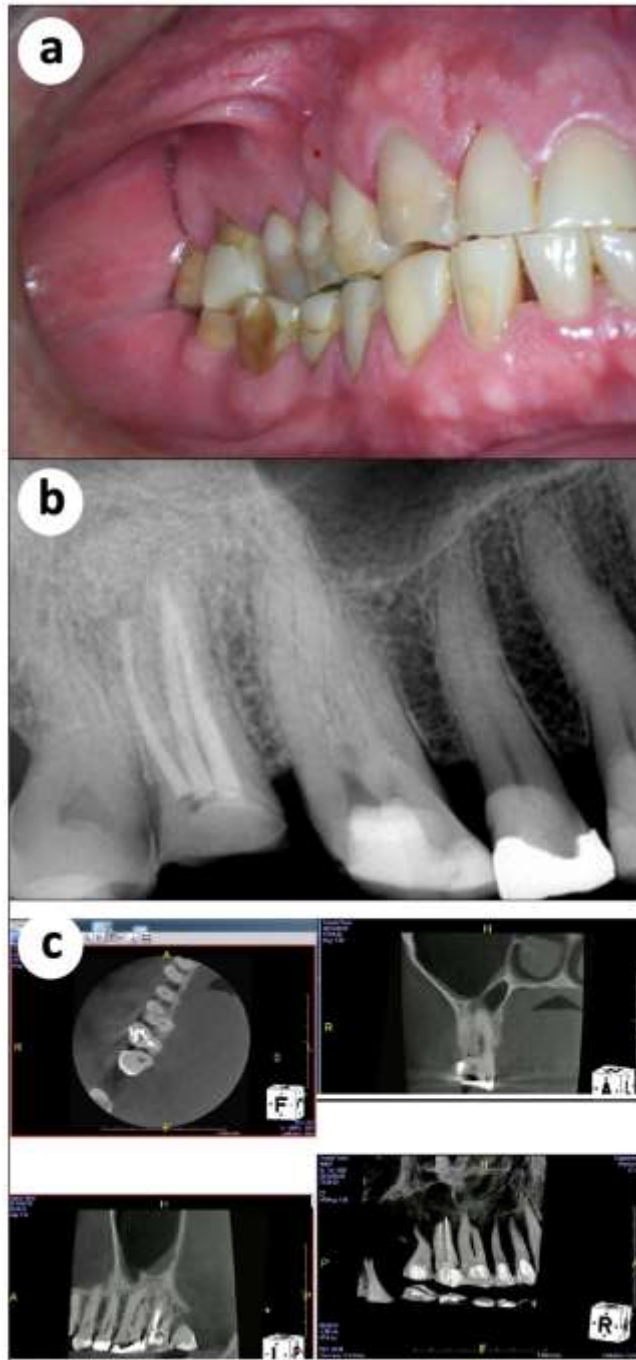
## 3. Case Report

A 54-year-old male patient presented in our clinic referred from another dentist. The chief complaint indicated a complicated anatomy case. The previous dentist was not able to perform Endodontics in the upper first right molar due to difficulties to localize and treat the MB2 and the DB root canals. The examiner noted an area of temporary crown restoration (Figure 1a). A periapical radiograph was taken and suggested previous intervention and an atypical root canal anatomy (Figure 1b).

The patient was submitted tomography to help us understand the actual anatomy. The results indicated the presence of curvatures in the apical area of the tree roots. Moreover, the exam suggested the presence of a fourth root canal in the palatal root, and a periapical lesion in the apical region of the MB root, close to the maxillary sinus (Figure 1c).

**Figure 1.** (a) Oral view demonstrating periodontal injury in most of the dentition and temporary cement in tooth 16; (b) Radiographic finding complex anatomy and previous access and temporary cement; (c) Tomographic view indicating curvatures in the apical area of the three roots, a fourth root canal in the palatal root, and a periapical lesion upon the MB root,

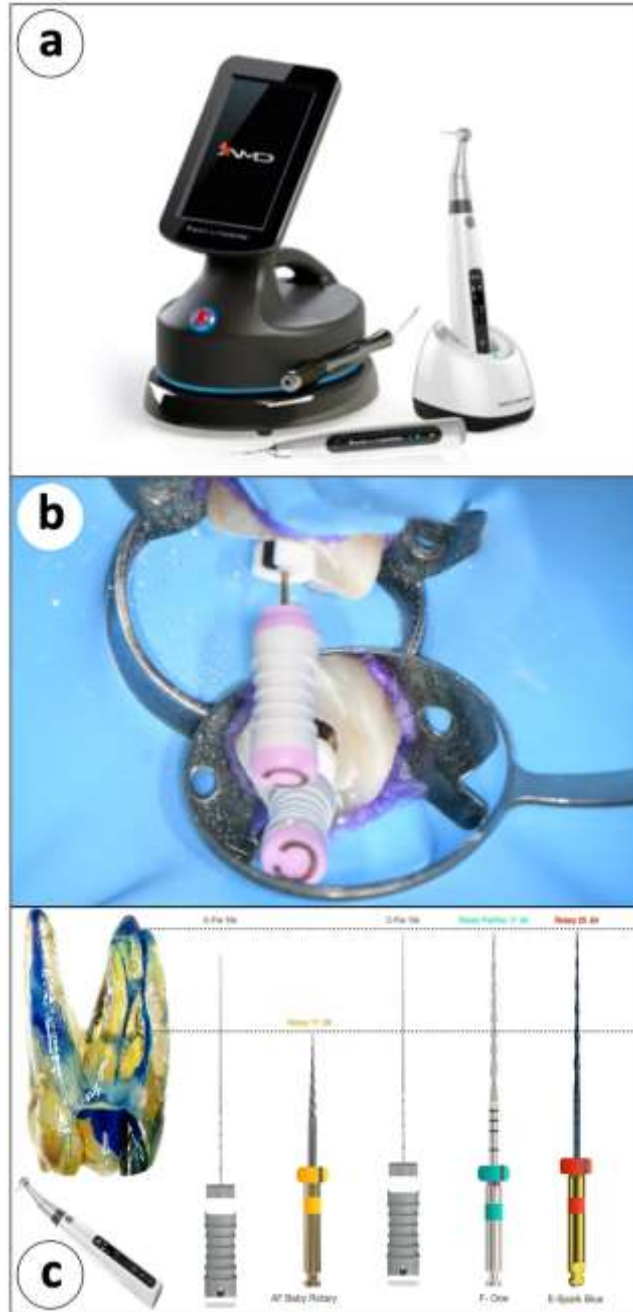
close to the maxillary sinus



Source: Authors.

Isolation used rubber dam before temporary cement elimination and access performed to initiate endodontic treatment. The pulp chamber was then filled with sodium hypochlorite (NaOCl). In the sequence, the evolutionary Leap Protocol, Rotary/Oscillating Hand Piece and Ultrasonic Unit (E-Connect Inc. China ), and Da Vinci AMD Lasers (AMD, CAO Group Utah) (Figure 2a), started. Initially, the procedure was the exploration of each root canal with a pre-curved #15 K stainless steel hand file (Figure 2b). This file was used as to an estimated working length as determined on the periapical radiograph to establish a glide path to the foramen. The sequence of the protocol (Figure 2c), starts with a Niti #17 .08 Orifice Opener (Figure 3a) introduced into the root canal in the handpiece set for rotation is advanced until resistance or the middle third of the tooth. The handpiece's apex locator feature is used to verify the working length.

**Figure 2.** (a) The DaVinci diode laser (left), ultrasonic unit (middle) and endodontic handpiece (right); (b) Exploration of each root canal with a pre-curved #15 K stainless steel hand file to establish glide path and patency; (c) The sequence of the protocol. 15 .02, 17 .08, 15 .02, 17 .04 and 25 .04.

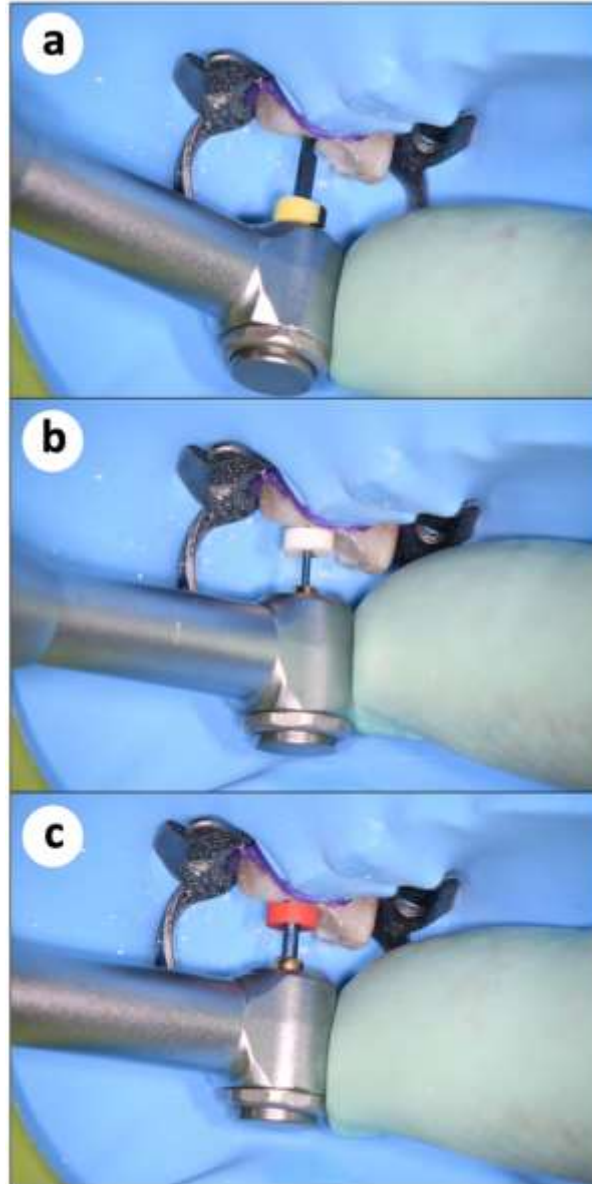


Source: Authors.

The following file in the series is the #17 .04 Niti file used in rotation mode until the working length. (Figure 3b). The length of each root canal was verified with the apex locator feature to be; MB 21mm, ML 21mm, DB 21mm, and D 20mm. NaOCL was suctioned, and a new irrigation solution added between changes of files. Irrigation solution was agitated in the canals with the ultrasonic unit (US) to maximize NaOCl penetration into the lateral canal anatomy, once the files were not able to reach. Each time a new solution was placed into the root canal. Then, file #25 .04 Niti in reciprocating mode was used in the working length (Figures 3c).



**Figure 3.** (a) File Niti #17 .08 Orifice Opener introduced into each root canal in the handpiece set for rotation advanced until resistance or the middle third of the tooth; (b) File #17 .04 Niti file used in rotation mode until the working length; (c) File #25 .04 used in the reciprocation mode of the motor until working length.

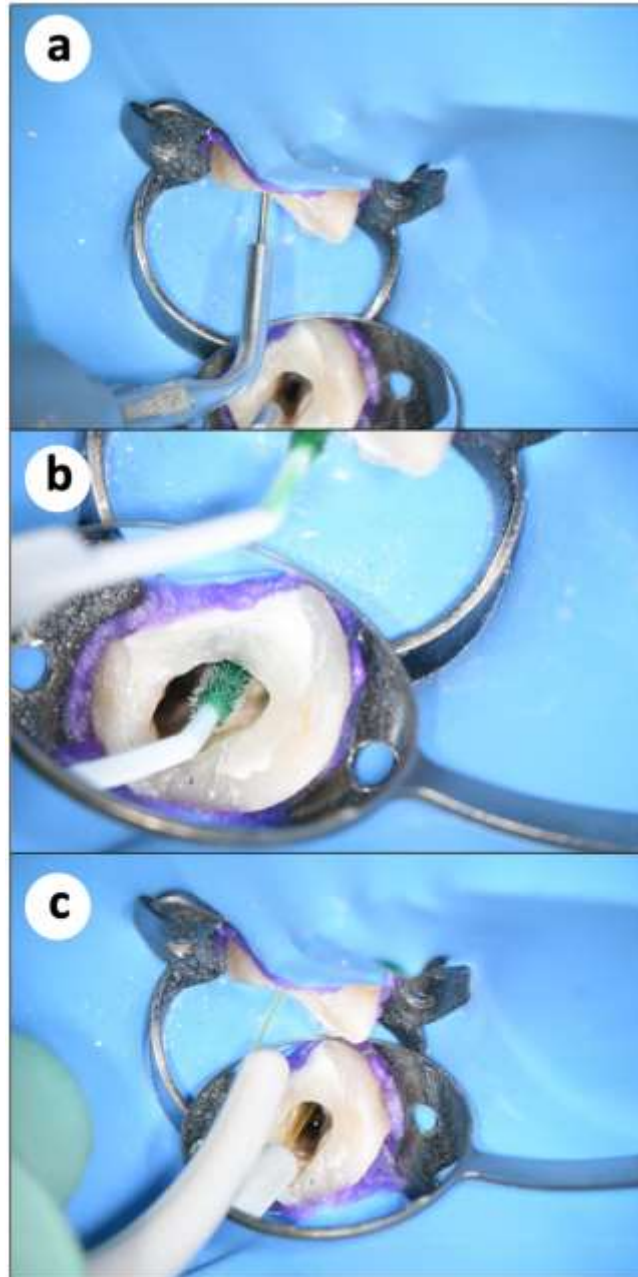


Source: Authors.

Again, the irrigation solution in the root canal system is activated with the ultrasonic (US) handpiece. The root canals were irrigated with NaOCl and the US activation (Figure 4a), aspirated and dried with paper points. In continuity, indocyanine dye was placed into the root canals, filling the canals to the level of the orifice of the entrance of the root canal (Figure 4b). The DaVinci laser with an endodontic tip was placed on the laser handpiece, activated, and introduced into the root canal filled with the dye and extended into the root canal to 2 mm short of the WL. The tip was kept in this position for 30 seconds; then, the tip was withdrawn while keeping it activated (Figure 4c). This was repeated in the other four root canals.

**Figure 4.** (a) The root canals were irrigated with NaOCl and activated with US; (b) Indocyanine dye placed into the root canals, filling the canals to the level of the orifice of the entrance of the root canal; (c) The DaVinci laser with an endodontic tip was placed on the laser handpiece, activated, and introduced into the root canal filled with the dye and extended into the

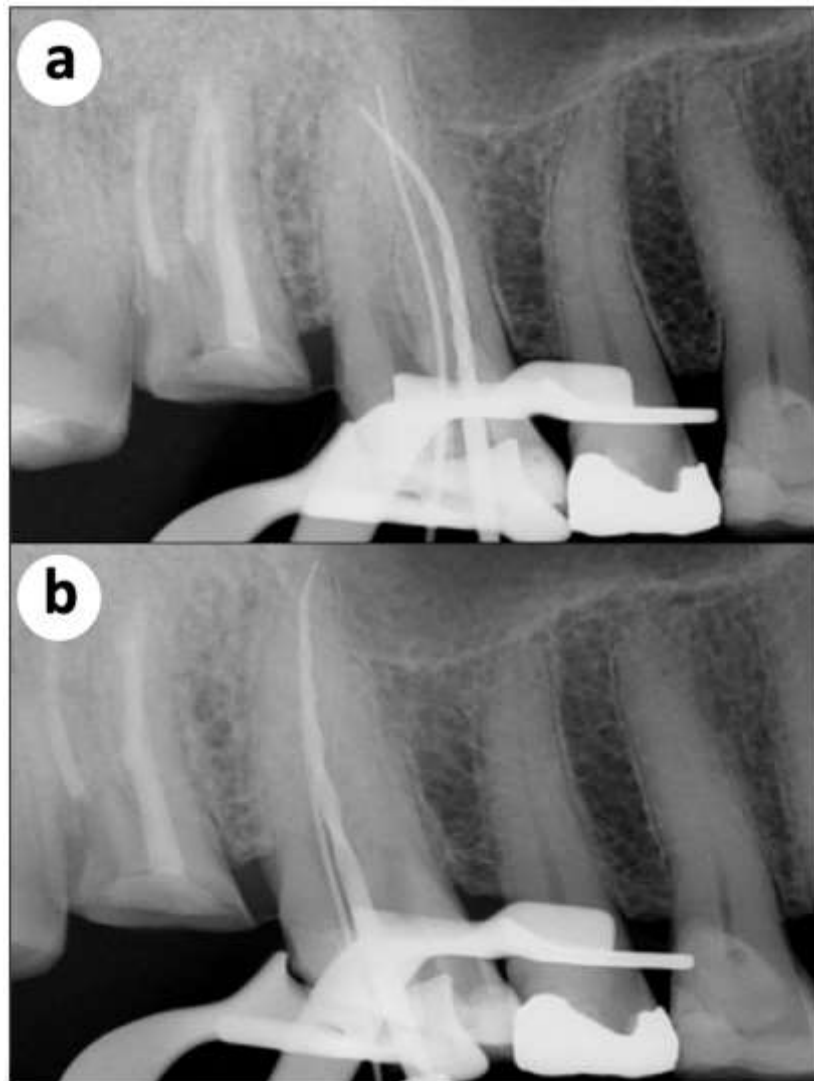
canal to 2 mm short of the WL.



Source: Authors.

Again, irrigation with US and NaOCl was performed for each root canal, aspirated and dried to WL in preparation for obturation. To confirm instrumentation to the apical area, a final all files were placed into each root canal, and a periapical radiograph was taken. (Figure 5a,b).

**Figure 5.** (a) Periapical radiograph with endodontic files inserted in the mesial and palatine root channels; (b) Periapical radiograph with endodontic files inserted in the distal and palatine root channels;

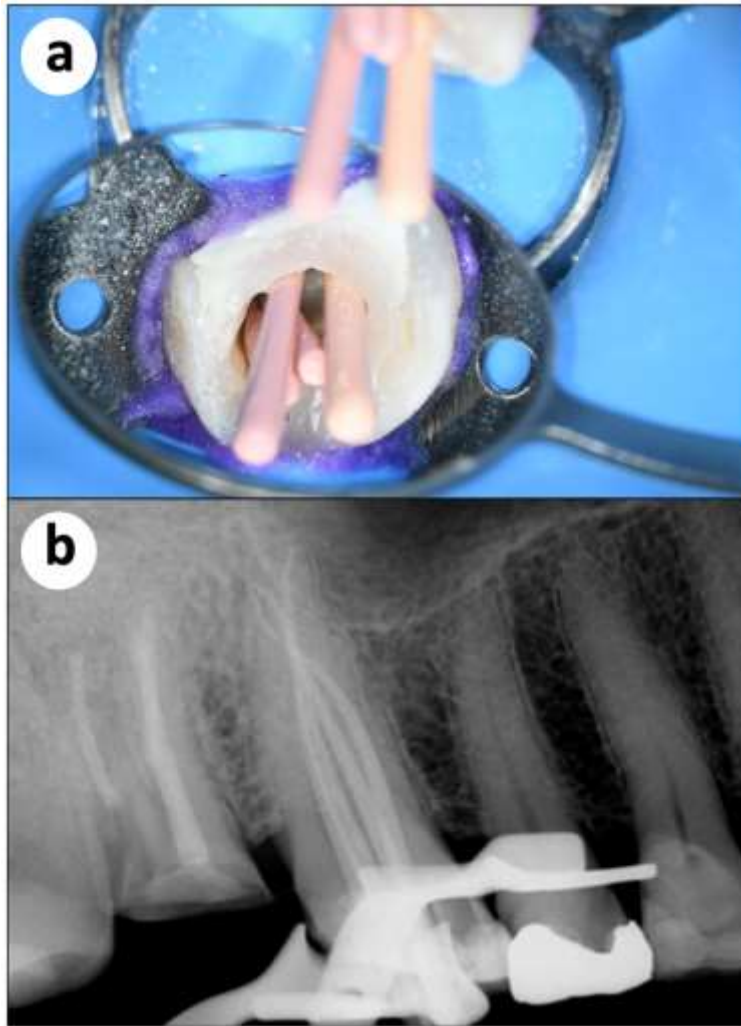


Source: Authors.

Fitted gutta-percha cones matching the final Niti file used in the root canal (#25 .04) was coated with AH Plus sealer (Dentsply Sirona, York, PA) and inserted to the established WL using a single cone technique (Figure 6a,b). The ultrasonic tip was used to cut off the portion of the gutta-percha cones extending beyond the canal orifice (Figure 7a). A periapical radiograph was taken to verify obturation to the root canals and its anatomical complexity. (Figure 7b,c).

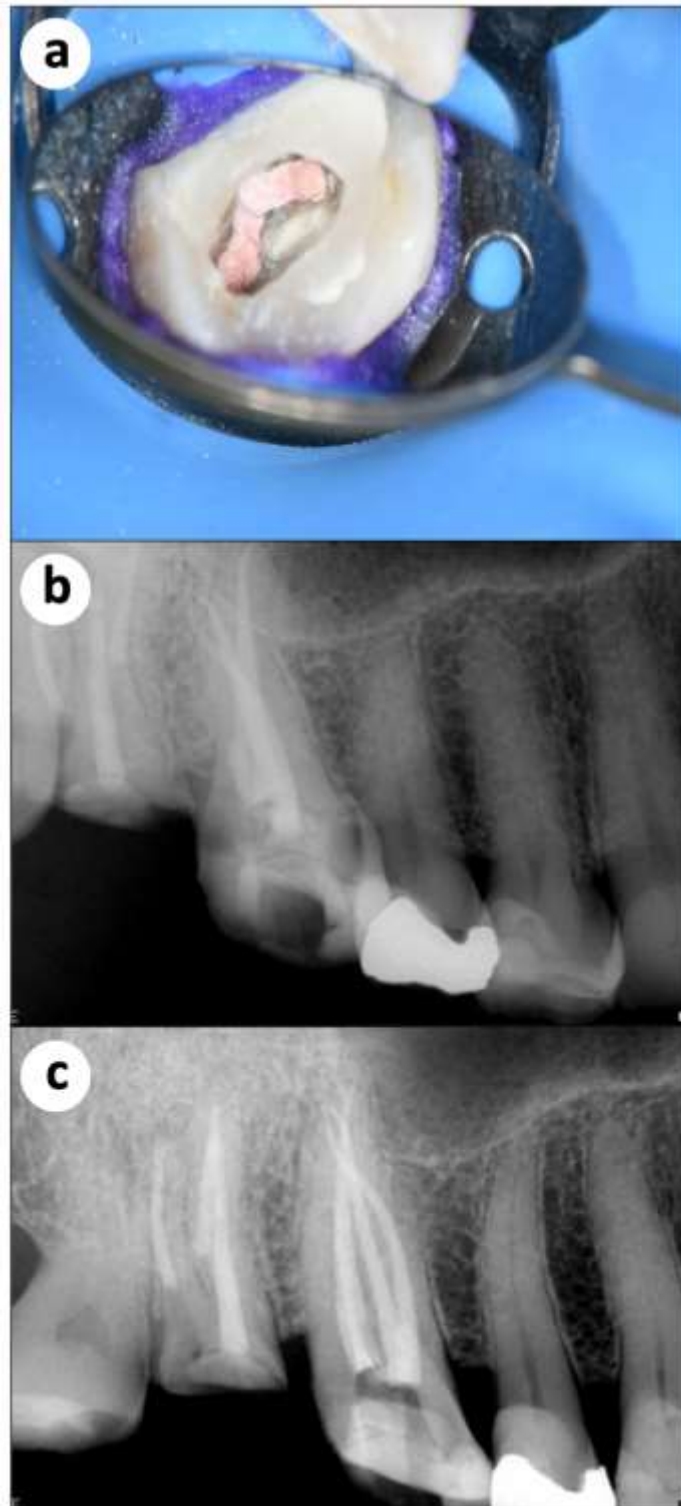


**Figures 6.** (a) Clinical and (b) radiographic aspects of the fitted gutta-percha cones matching the final Niti file (#25 .04) inserted to the established W.L.



Source: Authors.

**Figure 7.** (a) The ultrasonic tip was used to cut off the portion of the gutta-percha cones extending beyond the canal orifice; (b, c) Final radiographic images after root canal filling.



Source: Authors.

#### 4. Results and Discussion

Endodontics is a science that must consider the etiology, diagnosis, prevention, and treatment of apical periodontitis and its repercussion in the human organism (Cintra et al. 2018). The majority of current literature shows that after 2 to 4 years of endodontic therapy, approximately 15% of root canal treatments must be performed again (de Sousa Gomide Guimarães et al. 2019). This is an important fact that indicates that something is wrong and changes are needed to reach better results. One may advocate that many clinicians base their practice of endodontics on opinions, personal history, and empirical deductions. “Responsible Endodontics” must be constructed under the guise of scientific, clinical, radiographic, and histopathological evidence.

The practice of endodontics should be addressed with a sense of responsibility and consideration of different options of treatment. One must give more serious attention to technological resources available for diagnosis, root canal negotiation, cleaning, shaping, and filling techniques that will increase post-treatment success. During the last two decades, several new technologies have appeared on the market. Technologies for anesthesia, electronic apex (foramen) locators, digital radiographs, cone-beam computed tomography scans, ultrasound units, lasers, operating microscopes, 3D concepts of obturation and 100 % inorganic root canal sealers are some examples (Celikten et al. 2015, Khalil et al. 2016, Bruellmann et al. 2016, Zand et al. 2017, Akbari et al. 2017, Bueno et al. 2018, De-Deus et al. 2020, Al Shaikhly et al. 2020).

The most relevant change observed during this period has been the use of laser (Wang et al. 2016, Akbari et al. 2017, Zorita-García et al. 2019, Ghorbanzadeh et al. 2020). Even adequate biomechanical preparations with the use of a massive sort of NiTi instruments, ultrasonic irrigation, and antiseptic solutions are not able to disinfect the root canal system (Plotino et al. 2016, Gonçalves et al. 2016, Rôças et al. 2016, De-Deus et al. 2020). The remaining bacterium inside dentinal tubules, lateral canals, and anfractuositities can infect the root canal mass.

In this way, this article described a clinical case where all the current technological resources were used. The result obtained shows that quality endodontics leads to successful treatment, especially in cases of pulp necrosis associated with apical periodontitis.

#### 5. Conclusion

Among the new technologies for the 3D disinfection of the root canal system, which provide safety, speed, accessibility with efficiency, the renowned oscillating-rotary mechanical instrumentation, and ultrasound for irrigation stand out. In addition, resides in diode lasers the fundamental progress that represents a huge evolutionary Leap in Endodontics. It is based upon clinical and scientific evidence, without the need for a theatrical platform, with a simple and fast learning curve. Moreover, allowing the general practitioner to quickly implement in their daily clinical lives and with a little cost. Despite the excellent result at the end of the treatment and the success achieved, more clinical cases using the Leap protocol should be performed in order to confirm success with this type of protocol.

#### References

- Akbari, T., Pourhajibagher, M., Hosseini, F., Chiniforush, N., Gholibegloo, E., Khoobi, M., Shahabi, S., & Bahador, A. (2017). The effect of indocyanine green loaded on a novel nano-graphene oxide for high performance of photodynamic therapy against *Enterococcus faecalis*. *Photodiagnosis and Photodynamic therapy*, 20, 148–153.
- Al Shaikhly, B., Harrel, S. K., Umorin, M., Augsburger, R. A., & Jalali, P. (2020). Comparison of a Dental Operating Microscope and High-resolution Videoscope for Endodontic Procedures. *Journal of Endodontics*, 46(5), 688–693.
- Bergenholtz G. (2016). Assessment of treatment failure in endodontic therapy. *Journal of Oral Rehabilitation*, 43(10), 753–758.

- Bolhari, B., Pourhajibagher, M., Bazarjani, F., Chiniforush, N., Rad, M. R., Pirmoazen, S., & Bahador, A. (2018). Ex vivo assessment of synergic effect of chlorhexidine for enhancing antimicrobial photodynamic therapy efficiency on expression patterns of biofilm-associated genes of *Enterococcus faecalis*. *Photodiagnosis and Photodynamic Therapy*, 22, 227–232.
- Bruellmann, D., Sander, S., & Schmidtman, I. (2016). The design of an fast Fourier filter for enhancing diagnostically relevant structures - endodontic files. *Computers in Biology and Medicine*, 72, 212–217.
- Bueno, M. R., Estrela, C., Azevedo, B. C., & Diogenes, A. (2018). Development of a New Cone-Beam Computed Tomography Software for Endodontic Diagnosis. *Brazilian Dental Journal*, 29(6), 517–529.
- Celikten, B., F Uzuntas, C., I Orhan, A., Tufenkci, P., Misirli, M., O Demiralp, K., & Orhan, K. (2015). Micro-CT assessment of the sealing ability of three root canal filling techniques. *Journal of Oral Science*, 57(4), 361–366.
- Cintra, L., Estrela, C., Azuma, M. M., Queiroz, Í., Kawai, T., & Gomes-Filho, J. E. (2018). Endodontic medicine: interrelationships among apical periodontitis, systemic disorders, and tissue responses of dental materials. *Brazilian Oral Research*, 32(suppl 1), e68.
- de Sousa Gomide Guimarães, M., Samuel, R. O., Guimarães, G., Nalin, E., Bernardo, R. T., Dezan-Júnior, E., & Cintra, L. (2019). Evaluation of the relationship between obturation length and presence of apical periodontitis by CBCT: an observational cross-sectional study. *Clinical Oral Investigations*, 23(5), 2055–2060.
- De-Deus, G., Simões-Carvalho, M., Belladonna, F. G., Cavalcante, D. M., Portugal, L. S., Prado, C. G., Souza, E. M., Lopes, R. T., & Silva, E. (2020). Arrowhead design ultrasonic tip as a supplementary tool for canal debridement. *International Endodontic Journal*, 53(3), 410–420.
- Ghorbanzadeh, A., Bahador, A., Sarraf, P., Ayar, R., Fekrazad, R., & Asefi, S. (2020). Ex vivo comparison of antibacterial efficacy of conventional chemomechanical debridement alone and in combination with light-activated disinfection and laser irradiation against *Enterococcus faecalis* biofilm. *Photodiagnosis and Photodynamic Therapy*, 29, 101648.
- Gomes, B., & Herrera, D. R. (2018). Etiologic role of root canal infection in apical periodontitis and its relationship with clinical symptomatology. *Brazilian Oral Research*, 32(suppl 1), e69.
- Gonçalves, L. S., Rodrigues, R. C., Andrade Junior, C. V., Soares, R. G., & Vettore, M. V. (2016). The Effect of Sodium Hypochlorite and Chlorhexidine as Irrigant Solutions for Root Canal Disinfection: A Systematic Review of Clinical Trials. *Journal of Endodontics*, 42(4), 527–532.
- Khalil, I., Naaman, A., & Camilleri, J. (2016). Properties of Tricalcium Silicate Sealers. *Journal of Endodontics*, 42(10), 1529–1535.
- Mladenovic, R., Pereira, L., Mladenovic, K., Videnovic, N., Bukumiric, Z., & Mladenovic, J. (2019). Effectiveness of Augmented Reality Mobile Simulator in Teaching Local Anesthesia of Inferior Alveolar Nerve Block. *Journal Of Dental Education*, 83(4), 423–428.
- Nagendrababu, V., Segura-Egea, J. J., Fouad, A. F., Pulikkotil, S. J., & Dummer, P. (2020). Association between diabetes and the outcome of root canal treatment in adults: an umbrella review. *International Endodontic Journal*, 53(4), 455–466.
- Pereira, A. S., Shitsuka, D. M., Parreira, F. J., Shitsuka, R. (2018). Metodologia da pesquisa científica. [eBook]. Santa Maria. Ed. UAB / NTE / UFSM. Disponível em: [https://repositorio.ufsm.br/bitstream/handle/1/15824/Lic\\_Computacao\\_Metodologia-Pesquisa-Cientifica.pdf?sequence=1](https://repositorio.ufsm.br/bitstream/handle/1/15824/Lic_Computacao_Metodologia-Pesquisa-Cientifica.pdf?sequence=1).
- Plotino, G., Cortese, T., Grande, N. M., Leonardi, D. P., Di Giorgio, G., Testarelli, L., & Gambarini, G. (2016). New Technologies to Improve Root Canal Disinfection. *Brazilian Dental Journal*, 27(1), 3–8.
- Rôças, I. N., Provenzano, J. C., Neves, M. A., & Siqueira, J. F., Jr (2016). Disinfecting Effects of Rotary Instrumentation with Either 2.5% Sodium Hypochlorite or 2% Chlorhexidine as the Main Irrigant: A Randomized Clinical Study. *Journal of Endodontics*, 42(6), 943–947.
- Wang, X., Cheng, X., Liu, B., Liu, X., Yu, Q., & He, W. (2017). Effect of Laser-Activated Irrigations on Smear Layer Removal from the Root Canal Wall. *Photomedicine and Laser Surgery*, 35(12), 688–694.
- Zand, V., Rahimi, S., Davoudi, P., & Afshang, A. (2017). Accuracy of Working Length Determination using NovApex and Root-ZX Apex Locators: An in vitro Study. *The Journal of Contemporary Dental Practice*, 18(5), 383–385.
- Zorita-García, M., Alonso-Ezpeleta, L. Ó., Cobo, M., Del Campo, R., Rico-Romano, C., Mena-Álvarez, J., & Zubizarreta-Macho, Á. (2019). Photodynamic therapy in endodontic root canal treatment significantly increases bacterial clearance, preventing apical periodontitis. *Quintessence International* (Berlin, Germany: 1985), 50(10), 782–789.