

Facial cellulitis caused by Giant parotid sialolith: a minimally invasive treatment for a rare occurrence

Celulite facial causada por sialolito gigante de parótida: um tratamento minimamente invasivo para uma ocorrência rara

Celulitis facial causada por sialolito gigante de parotid: um tratamiento minimamente invasivo para una ocorrência rara

Received: 03/10/2021 | Reviewed: 03/17/2021 | Accept: 03/20/2021 | Published: 03/27/2021

Moacyr Tadeu Vicente Rodrigues

ORCID: <https://orcid.org/0000-0002-4951-5836>
University of Campinas, Brazil
E-mail: mtadeuvr@gmail.com

Filipe Ebenezzer de Aguiar Schueng

ORCID: <https://orcid.org/0000-0002-8025-5710>
São Lucas University Center, Brazil
E-mail: filipe_schueng@outlook.com

Bruno Coelho Mendes

ORCID: <https://orcid.org/0000-0001-7896-8909>
Sao Paulo State University, Brazil
E-mail: brunoc.mnds@gmail.com

José Marcelo Vargas Pinto

ORCID: <https://orcid.org/0000-0002-1079-0785>
Base Hospital of Porto Velho, Brazil
E-mail: jmvp@bol.com.br

Fabício Guimarães de Souza

ORCID: <https://orcid.org/0000-0002-4142-1114>
João Paulo II Hospital. Rondônia State Government, Brazil
E-mail: fabricao.guimaraes@outlook.com

Cláudio Ferreira Nóia

ORCID: <https://orcid.org/0000-0003-2336-6737>
University of Campinas, Brazil
E-mail: claudion@unicamp.br

Abstract

Sialolithiasis is a common disease that affects the major salivary glands and can occur at any age. Parotid glands are rarely involved and, even rarer are the cases of sialoliths larger than 10 mm. This report presents the rare case of a giant parotid sialolith associated with facial cellulitis in a 75-year-old man. The treatment involved initially non-surgical approach followed by a minimally invasive surgery to restore health and function. The treatment protocol was completely successful and proved effective in clinical and surgical management of giant parotid sialolith associated with facial cellulitis.

Keywords: Parotid gland; Salivary gland calculi; Cellulitis; Treatment protocol.

Resumo

A sialolitíase é uma doença comum que afeta as glândulas salivares maiores e pode ocorrer em qualquer idade. As glândulas parótidas raramente são envolvidas e, mais raros ainda são os casos de sialolitos acima de 10 mm. Este relato apresenta o caso de um raro sialolito parotídeo gigante associado à celulite facial em um homem de 75 anos. O tratamento envolveu uma abordagem inicialmente não cirúrgica seguida por uma cirurgia minimamente invasiva para restaurar saúde e função. O protocolo de tratamento foi totalmente bem-sucedido e se mostrou eficaz no manejo clínico e cirúrgico do sialolito parotídeo gigante associado à celulite facial.

Palavras-chave: Glândula parótida; Sialolitíase; Celulite; Protocolo de tratamento.

Resumen

La sialolitiasis es una enfermedad común que afecta las glándulas salivales más grandes y puede ocurrir a cualquier edad. Las glándulas parótidas casi nunca están afectadas y, aún más raros, son los casos de sialolitos de más de 10 mm. Este reporte presenta el caso de un sialolito parotídeo gigante raro asociado a celulitis facial en un hombre de 75 años. El tratamiento involucró un enfoque inicialmente no quirúrgico seguido de una cirugía mínimamente invasiva

para restaurar la salud y la función. El protocolo de tratamiento fue totalmente exitoso y demostró ser efectivo en el manejo clínico y quirúrgico del sialolito parotídeo gigante asociado con celulitis facial.

Palavras-clave: Glándula parótida; Calculos de las glándulas salivares; Celulitis; Protocolo de tratamiento.

1. Introduction

Sialolithiasis is a common disease that affects the major salivary glands. It is characterized by obstruction of salivary secretion by a calculus, commonly associated with swelling, pain and infection of the affected gland (Bodner, 1993; Bodner, 1999).

Submandibular gland is the most affected gland (80% to 95%), whereas 5% to 20% are found in the parotid gland. The sublingual gland and the minor salivary glands are rarely affected (1% to 2%). Sialoliths can occur at any age, but there is a peak incidence between the third and sixth decades and a male predilection is reported (Lustmann, Regev, & Melamed, 1990; Bodner, 2002).

Sialoliths are mostly composed by calcium phosphate (hydroxyapatite) and also an organic matrix consisting of carbohydrate and amino acids. The mechanism of the formation of sialoliths is still poorly understood, although the pH, mucin content, high Ca^{++} concentration of the gland, salivary stagnation, a nidus and a precipitation of salivary salts. Furthermore, the ascendant, snaky route and against gravity long length of the Wharton's duct can also contribute, probably explaining the higher rate of occurrence in this gland. Infection, inflammation of the gland, or physical trauma to the duct or its orifice are also listed as predisposing factors (Bodner, 1993; Bodner, 2002; Guastaldi, da Silva, Troulis, & Lahey, 2018).

Parotid glands are rarely involved and most often unilaterally, single and located within the ductal system (Ottaviani, Galli, Lucia, & Ventura, 1997). The size of sialoliths may vary from less than 1 mm to a few centimeters (Bodner, 1999; Levy, Remine & Devine; Iqbal, Murthy, & Sharma, 1992; Kesse, Shehab, & Courteney-Harris, 1998). Most of the parotid sialoliths are less than 10 mm in size, whereas giant parotid sialoliths (larger than 15mm) are quite rare. The giant parotid sialoliths are also usually smaller than those in the submandibular gland (Lustmann et al, 1990; Bodner, 2002). The sialolith may eventually undergo migration and be expelled through the duct or through a cutaneous fistula (Brown, Cheah, & Ha, 2016). Além disso as técnicas para exérese são variadas e podem considerar abordagem intrabucal ou extrabucal (Gillespie, 2018).

The present article is a report on an unusual giant parotid sialolith as a cause of facial cellulitis, its diagnosis and management.

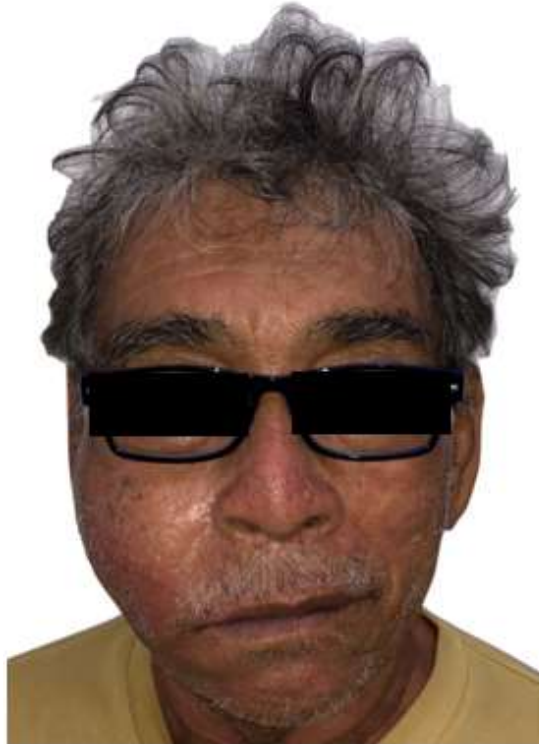2. Methodology

A descriptive and qualitative interventional study was carried out, in the format of a Case Report of a patient's follow-up during treatment. The epidemiological data and, history of the disease, were collected through the physical and electronic records, after authorization of the patient and signature of the Informed Consent, as (Brown et al, 2016).

3. Case Report

A 75-year-old man was referred to the emergency, with a two-week history of fever and a painful, diffuse tender swelling on the right side of the face (Figure 1). He reported intermittent episodes for 5 years of moderate to severe pain and swelling which settled spontaneously or with a course of oral antibiotics. He referred diabetes mellitus and systemic arterial hypertension, controlled by oral metformin and captopril, respectively. There was no history of tooth pain during all of this period, what would reinforce the diagnosis of a non-odontogenic cellulitis.

Figure 1 - Diffuse swelling on the right middle facial third.

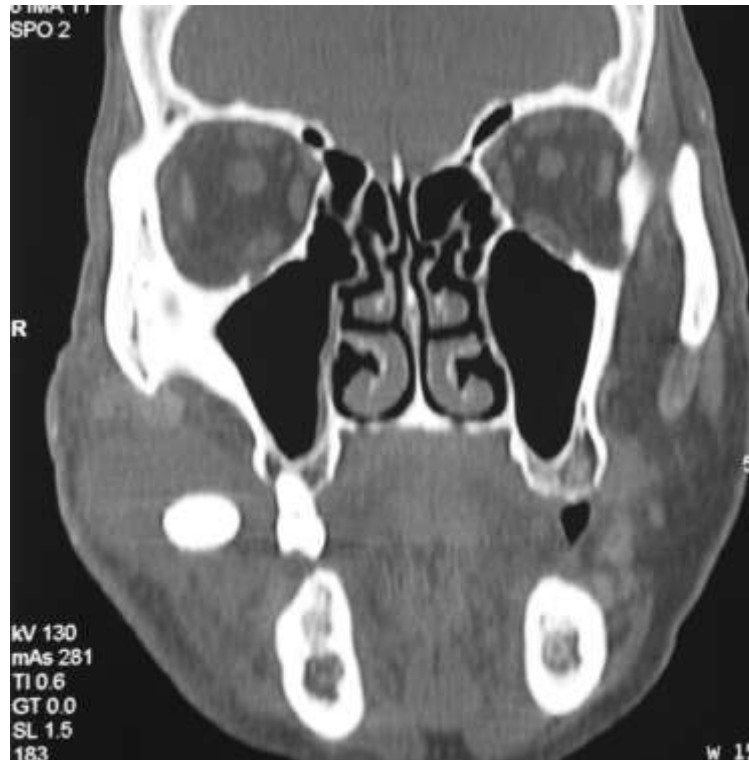

Source: Authors.

Upon inspection, there was a massive painful hyperemic hard swelling on the right parotid and buccal spaces, facial asymmetry, without facial nerve paralysis and purulent drainage. Oroscopy revealed trismus and reddish swelling on the right buccal mucosa as well as no odontogenic source of infection.

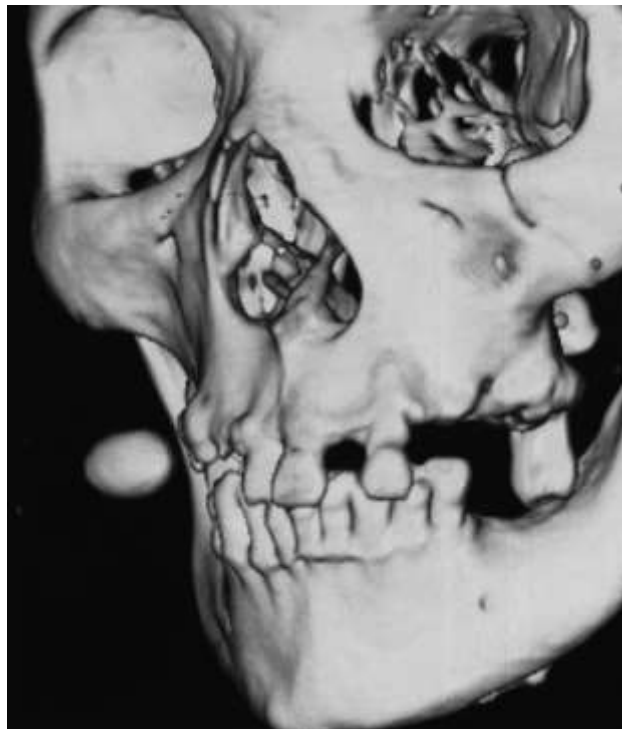Computed tomography revealed a large oval hyperdense image in the buccal space, consistent with the diagnosis of sialolithiasis in the right Stensen's duct (Figure 2 and 3).

Figure 2 - Coronal view in computed tomography showing hyperdense oval image in swelled buccal space, suggestive of parotid sialolith on the right side.



Source: Authors.

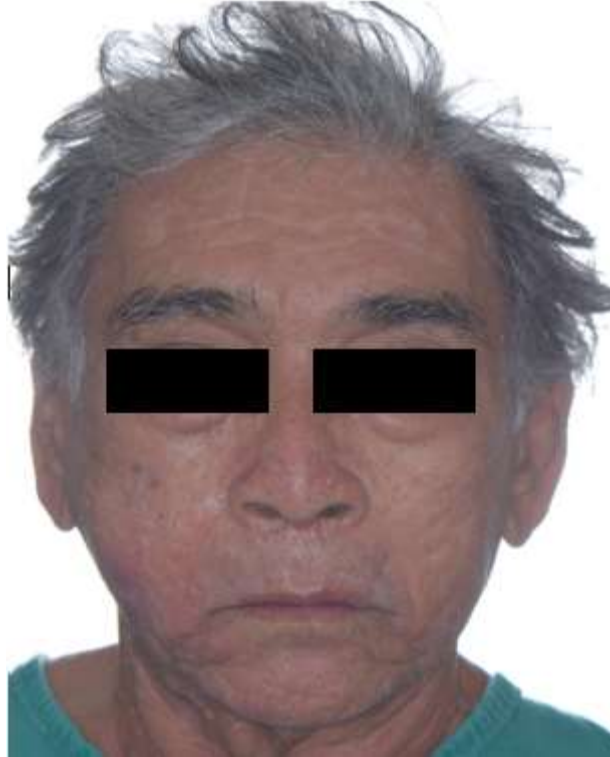Figure 3 - Hyperdense oval image in buccal space, on the right side, in 3D CT image.



Source: Authors.

Considering the patient's clinical conditions, we opted for hospitalization and intravenous antibiotic therapy for initial control of infection and subsequent sialolith surgical removal. The antibiotic therapy consisted of intravenous ceftriaxon (1g, twice a day), metronidazole (500mg, three times a day) and gentamicin (80 mg, three times a day). After 5 days, the swelling, pain and trismus were better and the surgery was performed under general anesthesia (Figure 4).

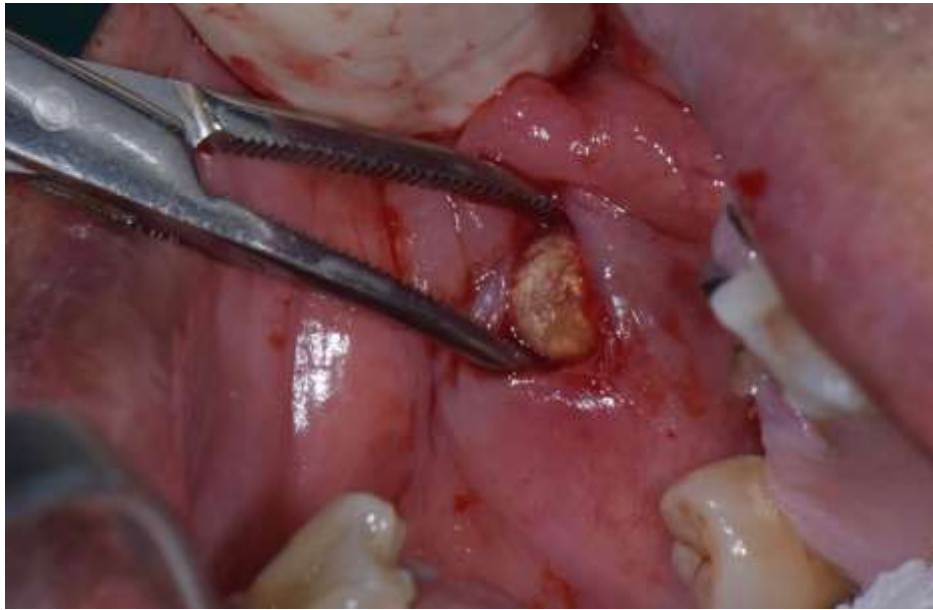
Figure 4 - Clinical aspect after antibiotic therapy.



Source: Authors.

A 15mm mucosal incision was done posterior to the duct orifice and blunt dissection was carried out towards the calculus (Figure 5).

Figure 5 - Sialolith removal by intraoral approach after incision and dissection.



Source: Authors.

A small amount of purulent mucous saliva was discharged after reaching the Stensen's duct surgically and the sialolith was removed afterwards. The sialolith measured 16 X 12 mm (Figure 6).

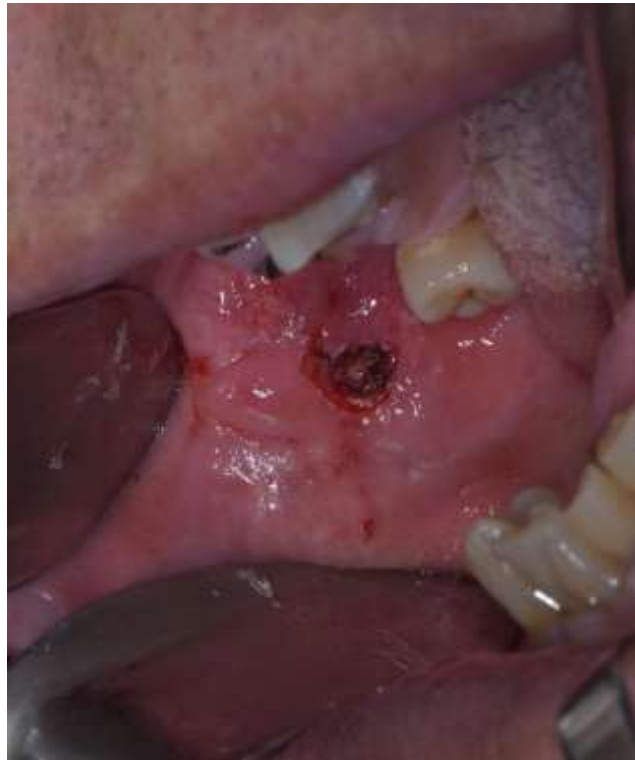Figure 6 - Giant parotid sialolith (>15mm).



Source: Authors.

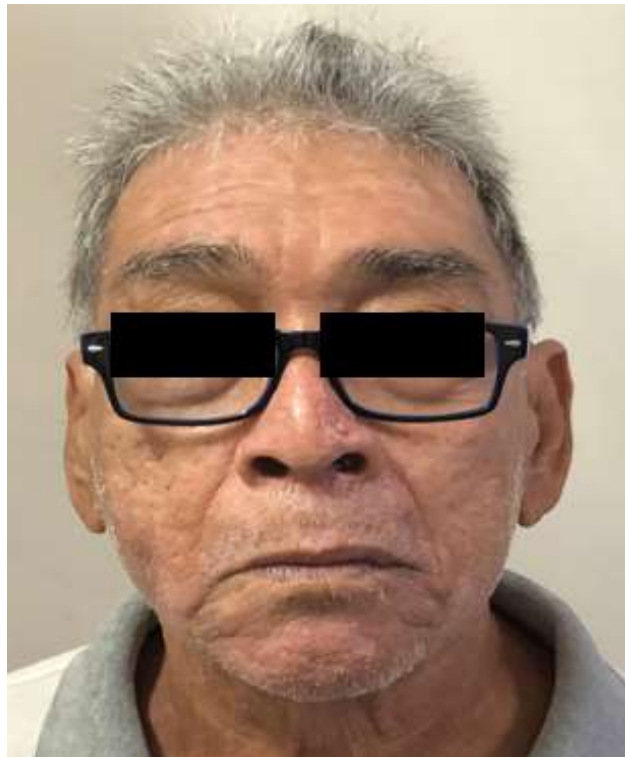No sutures were applied to avoid complications (Figure 7). The recovery was uneventful (Figure 8).

Figure 7 - Final aspect after sialolith removal and hemostasis.



Source: Authors.

Figure 8 - Final clinical aspect after 2 months of treatment.



Source: Authors.

4. Discussion

Parotid sialoliths are considered rare as compared to those of the submandibular gland. The presence of microcalculi in 80 % of normal submandibular and only in 10 % of normal parotid glands may explain the differences of sialoliths incidence in these two glands (Bodner, 1999; Epivatianos, & Harrison, 1989).

The higher incidence of sialolithiasis in elderly patients may be due medication consumption that would reduce the secretory activity, modify electrolyte saliva concentrations and glycoprotein synthesis leading to structural deterioration of cell membranes of the salivary glands (Lustmann et al, 1990; Bodner, 2002; Bodner & Gorsky, 1996).

This case is an acute exacerbation of a longstanding chronic asymptomatic parotid sialolithiasis, mimetizing an odontogenic cellulitis. The sialolith large size (16 x 12 mm) indicates a rare giant parotid sialolith, one of the largest parotid sialolith ever reported.

Iqbal et al. (1992) reported a parotid calculus measured 30 X 25 X 15 mm. Kesse et al. (1998) reported a giant parotid calculus measured 50 mm in length and 30 mm in its longest width, the largest parotid gland calculus ever reported.

Bodner (1999) reported another giant parotid calculus measured 25x13mm. Bodner (2002) showed that only 14 well-documented cases of Giant salivary gland calculi (>15 mm) have been reported in the literature since 1942, involving submandibular and parotid gland, being a quite rare occurrence in the parotid gland with only 2 cases reported in that survey. The treatment objective of giant sialoliths, as for the standardsized stones, is restoration of normal salivary secretion. However, differential diagnosis is essential in cases of orofacial infections. Odontogenic infections usually present themselves as cellulitis. So the precise source of infection must be detected and the less invasive treatment as possible applied to avoid the morbidity caused by sialadenectomy, as usually required in cases of intraglandular sialoliths (Bodner, 2002).

5. Conclusion

In the case presented, the intraductal location and the favorable clinical evolution after antibiotic therapy avoided the need for extraoral drainage, sialadenectomy and other anti-aesthetic and invasive approaches, proving to be a successful treatment protocol for this rare occurrence.

References

- Bodner L. (1993). Salivary gland calculi: diagnostic imaging and surgical management. *Compendium* (Newtown, Pa.), 14(5), 572–586.
- Bodner, L., & Gorsky, M. (1996). Parotid gland secretion of the aging rat. *Archives of gerontology and geriatrics*, 22(1), 63–69. [https://doi.org/10.1016/0167-4943\(95\)00678-8](https://doi.org/10.1016/0167-4943(95)00678-8)
- Bodner L. (1999). Parotid sialolithiasis. *The Journal of laryngology and otology*, 113(3), 266–267. <https://doi.org/10.1017/s0022215100143750>.
- Bodner L. (2002). Giant salivary gland calculi: diagnostic imaging and surgical management. *Oral surgery, oral medicine, oral pathology, oral radiology, and endodontics*, 94(3), 320–323.
- Brown, K., Cheah, T., & Ha, J. F. (2016). Spontaneous cutaneous extrusion of a parotid gland sialolith. *BMJ case reports*, 2016, bcr2016214887. <https://doi.org/10.1136/bcr-2016-214887>
- Epivatianos, A., & Harrison, J. D. (1989). The presence of microcalculi in normal human submandibular and parotid salivary glands. *Archives of oral biology*, 34(4), 261–265. [https://doi.org/10.1016/0003-9969\(89\)90066-6](https://doi.org/10.1016/0003-9969(89)90066-6)
- Gillespie M. B. (2018). Combined Parotid Techniques. *Atlas of the oral and maxillofacial surgery clinics of North America*, 26(2), 133–143. <https://doi.org/10.1016/j.cxom.2018.05.004>
- Guastaldi, F., da Silva, J., Troulis, M. J., & Lahey, E. (2018). Surgical Retrieval of Parotid Stones. *Atlas of the oral and maxillofacial surgery clinics of North America*, 26(2), 105–110. <https://doi.org/10.1016/j.cxom.2018.05.009>
- Iqbal, S. M., Murthy, J. G., & Sharma, N. (1992). Giant parotid calculus—an unusual presentation. *The Journal of laryngology and otology*, 106(5), 446–447. <https://doi.org/10.1017/s0022215100119784>.

Kesse, W. K., Shehab, Z. P., & Courteney-Harris, R. (1998). A megalith of the parotid salivary gland. *The Journal of laryngology and otology*, 112(8), 784–785. <https://doi.org/10.1017/s0022215100141696>

Levy, D. M., Remine, W. H., & Devine, K. D. (1962). Salivary gland calculi. Pain, swelling associated with eating. *JAMA*, 181, 1115–1119. <https://doi.org/10.1001/jama.1962.03050390017005>.

Ottaviani, F., Galli, A., Lucia, M. B., & Ventura, G. (1997). Bilateral parotid sialolithiasis in a patient with acquired immunodeficiency syndrome and immunoglobulin G multiple myeloma. *Oral surgery, oral medicine, oral pathology, oral radiology, and endodontics*, 83(5), 552–554. [https://doi.org/10.1016/s1079-2104\(97\)90119-0](https://doi.org/10.1016/s1079-2104(97)90119-0).