

## **Surgical management of fused 3rd and 4th molars. A case report**

**Estratégia para exodontia de 3º e 4º molares fusionados. Relato de caso**

**Manejo quirúrgico de los terceros y cuartos molares fusionados. Reporte de un caso**

Received: 03/28/2021 | Reviewed: 04/02/2021 | Accept: 04/06/2021 | Published: 04/16/2021

### **Ana Flávia Piquera Santos**

ORCID: <https://orcid.org/0000-0001-7562-772X>  
São Paulo State University, Brazil  
E-mail: [anaflaviaps\\_06@hotmail.com](mailto:anaflaviaps_06@hotmail.com)

### **Laís Kawamata De Jesus**

ORCID: <https://orcid.org/0000-0002-0459-5860>  
São Paulo State University, Brazil  
E-mail: [kawamata\\_lais@hotmail.com](mailto:kawamata_lais@hotmail.com)

### **Henrique Hadad**

ORCID: <https://orcid.org/0000-0001-6446-3643>  
São Paulo State University, Brazil  
E-mail: [henriquehadad@gmail.com](mailto:henriquehadad@gmail.com)

### **Naara Gabriela Monteiro**

ORCID: <https://orcid.org/0000-0002-2857-9195>  
São Paulo State University, Brazil  
Email: [naaragmonteiro@gmail.com](mailto:naaragmonteiro@gmail.com)

### **Leticia Gabriella de Souza Rodrigues**

ORCID: <https://orcid.org/0000-0002-1241-5487>  
São Paulo State University, Brazil  
E-mail: [leticiasrodrigues@gmail.com](mailto:leticiasrodrigues@gmail.com)

### **Kezia Barbosa Mendes**

ORCID: <https://orcid.org/0000-0003-4145-5557>  
São Paulo State University, Brazil  
E-mail: [kezia\\_mendes10@hotmail.com](mailto:kezia_mendes10@hotmail.com)

### **Vinicius Ferreira Bizelli**

ORCID: <https://orcid.org/0000-0003-1813-3509>  
São Paulo State University, Brazil  
E-mail: [viniciusbizelli@gmail.com](mailto:viniciusbizelli@gmail.com)

### **Luara Teixeira Colombo**

ORCID: <https://orcid.org/0000-0001-6261-6044>  
São Paulo State University, Brazil  
E-mail: [luara\\_colombo@hotmail.com](mailto:luara_colombo@hotmail.com)

### **Nelson Padilha Silva**

ORCID: <https://orcid.org/0000-0001-7873-5080>  
São Paulo State University, Brazil  
Email: [nelsonpad@gmail.com](mailto:nelsonpad@gmail.com)

### **Fábio Astolphi de Carvalho**

ORCID: <https://orcid.org/0000-0002-0358-3200>  
São Paulo State University, Brazil  
Email: [fabiodcarvalho@gmail.com](mailto:fabiodcarvalho@gmail.com)

### **André Luiz da Silva Fabris**

ORCID: <https://orcid.org/0000-0002-1777-2125>  
São Paulo State University, Brazil  
E-mail: [andre.fabris@hotmail.com](mailto:andre.fabris@hotmail.com)

### **Leonardo Perez Faverani**

ORCID: <https://orcid.org/0000-0003-2249-3048>  
São Paulo State University, Brazil  
E-mail: [leonardo.faverani@unesp.br](mailto:leonardo.faverani@unesp.br)

### **Alessandra Marcondes Aranega**

ORCID: <https://orcid.org/0000-0001-5856-7972>  
São Paulo State University, Brazil  
E-mail: [alessandra@foa.unesp.br](mailto:alessandra@foa.unesp.br)

### **Oswaldo Magro Filho**

ORCID: <https://orcid.org/0000-0002-9821-2479>  
São Paulo State University, Brazil  
E-mail: [osvaldo.magro@unesp.br](mailto:osvaldo.magro@unesp.br)

**Francisley Ávila Souza**

ORCID: <https://orcid.org/0000-0002-1427-071X>  
São Paulo State University, Brazil  
E-mail: francisley.avila@unesp.br

**Idelmo Rangel Garcia-Júnior**

ORCID: <https://orcid.org/0000-0001-8892-781X>  
São Paulo State University, Brazil  
E-mail: irgcirurgia@gmail.com

**Daniela Ponzoni**

ORCID: <https://orcid.org/0000-0001-5928-0914>  
São Paulo State University, Brazil  
E-mail: daniela.ponzoni@unesp.br

**Paulo Sérgio Perri de Carvalho**

ORCID: <https://orcid.org/0000-0003-1775-3108>  
São Paulo State University, Brazil  
E-mail: paulo.perri@unesp.br

**Ana Paula Farnezi Bassi**

ORCID: <https://orcid.org/0000-0002-0031-4953>  
São Paulo State University, Brazil  
E-mail: apfarnezibassi@gmail.com

**Abstract**

The aim of the present article was to report the case of a young male patient who attended the Surgery clinic of the School of Dentistry of Araçatuba-Unesp with the presence of a supernumerary tooth, 4th molar, fused with a lower left third molar. A panoramic radiograph was requested, showing two united crowns as well as root union, totaling 3 roots. Thus, the proposed treatment was extraction with 3-part dental sectioning, considering the size of the dental element and the amount of roots. The surgery was uneventful and postoperative was performed after 7 days for suture removal. Thus, we can conclude that, to define the diagnosis and treatment plan, it is necessary to perform a complete clinical examination and careful history, and always have imaging tests at hand.

**Keywords:** Supernumerary tooth; Oral surgery; Medical history taking; Mouth abnormalities; Fused teeth.

**Resumo**

O objetivo do presente artigo é relatar o caso de um paciente jovem do sexo masculino que compareceu ao ambulatório de Cirurgia da Faculdade de Odontologia de Araçatuba-Unesp com a presença de um dente supranumerário, 4º molar, fusionado a um terceiro molar inferior esquerdo. Foi solicitada radiografia panorâmica, evidenciando duas coroas unidas e também a união radicular, totalizando 3 raízes. Assim, o tratamento proposto foi a extração com seccionamento dentário em 3 partes, considerando o tamanho do elemento dentário e a quantidade de raízes. A cirurgia transcorreu sem intercorrências e o pós-operatório foi realizado após 7 dias para retirada da sutura. Assim, podemos concluir que, para definir o diagnóstico e o plano de tratamento, é necessário um exame clínico completo e uma anamnese criteriosa, tendo sempre à mão os exames de imagem.

**Palavras-chave:** Dente supranumerário; Cirurgia bucal; Anamnese; Anormalidades da boca; Dentes fusionados.

**Resumen**

El objetivo del presente artículo fue reportar el caso de un paciente joven de sexo masculino que acudió a la Clínica de Cirugía de la Facultad de Odontología de Araçatuba-Unesp con la presencia de un diente supernumerario, 4º molar, fusionado con un tercer molar inferior izquierdo. Se solicitó una radiografía panorámica en la que se objetivaron dos coronas unidas y unión radicular, totalizando 3 raíces. Así, el tratamiento propuesto fue la extracción con seccionamiento dentario en 3 partes, considerando el tamaño del elemento dentario y la cantidad de raíces. La cirugía transcurrió sin incidentes y el postoperatorio se realizó a los 7 días para retirar la sutura. Así, podemos concluir que, para definir el diagnóstico y plan de tratamiento, es necesario realizar una exploración clínica completa y una historia cuidadosa, y tener siempre a mano las pruebas de imagen.

**Palabras clave:** Diente supernumerario; Cirugía bucal; Anamnesis; Anomalías de la boca; Dientes fusionados.

## 1. Introduction

There are three types of anomalies with similar concepts that can be confused, namely, fusion, twinning and concrescence. Twinning is an anomaly in which there are two crowns, but the elements are joined by the root, that is, there is only one root canal, being common in deciduous teeth and there is no change in the number of teeth. The concrescence occurs when there is dental union by cementum without dentin union, its occurrence is higher in third molars. Finally, fusion occurs when there is a formation of a single dental element, but with distinct root canals, it can occur partially or totally, and usually

occurs in deciduous dentition, with a decrease in the total number of teeth (Steinbock, et al., 2014; Prakash, et al., 2012; Rosas, et al., 2004).

According to previous studies (Steinbock, et al., 2014; Guler et al., 2013), the incidence of these anomalies in primary teeth ranges from 0.5-2.5% and in permanent teeth 0.1-1.0%. The prevalence is higher in upper lateral incisors (55%) and central (33%) followed by lower incisors (6%) and maxillary canines (4%) (Goswami & Jangra, 2017; Liang, et al., 2012), may be unilateral or bilateral, occurs in both sexes and affects both in the maxilla and mandible, with higher occurrence in the mandible (Goswami & Jangra, 2017; Steinbock, et al., 2014; Guler et al., 2013; Rao & Hegde, 2010; Delany & Goldblatt, 1981). The prevalence of the 4th molar is 0.1-3.8% (Guler et al., 2013), and they are more common in the maxilla.

Supernumerary tooth is a developmental change in which there is an increase in the number of teeth in the dental arch. The prevalence is higher in the maxilla and in the mandible, the most affected area is premolars (Bamgbose, et al., 2019; Duarte, et al., 2006). Its incidence ranges from 0.3 to 3.8%, affecting more men than women (Garvey, et al., 1999). They are more common in permanent dentition, with a prevalence between 0.1% and 3.8% (Yang, 2012; Rajab & Hamdan, 2002), may be single (76-86%) or bilateral (12-23%), cases with multiple supernumerary teeth are usually related to syndromes (Bamgbose, et al., 2019; Duarte, et al., 2006). Its classification is according to its shape and position being the most common mesiodens (between the two central incisors), followed by 4th molars, premolars, lateral incisors and canines (Bamgbose, et al., 2019; Duarte, et al., 2006).

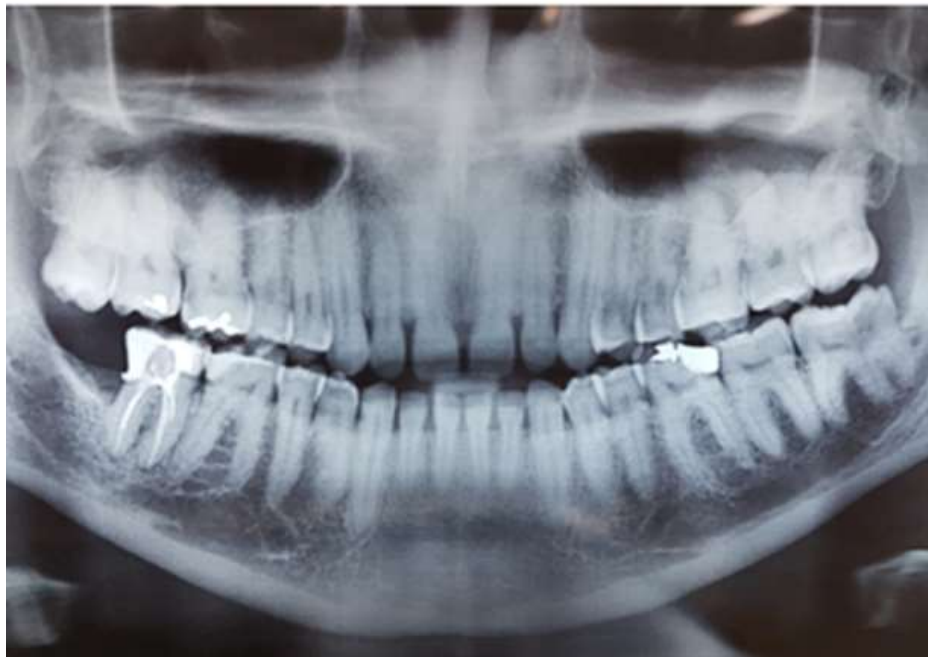## 2. Methodology

The methodology applied in this study followed the guidelines described in Pereira (2018) and consists of the report of a clinical case of a male patient, 18 years old, who was evaluated at the Surgical Clinic of the Faculty of Dentistry of Araçatuba (FOA / UNESP) for extraction of third molars. The present clinical case was submitted to Plataforma Brasil and approved by the Research Ethics Committee (CAAE: 37537220.4.0000.5420).

## 3. Case Report

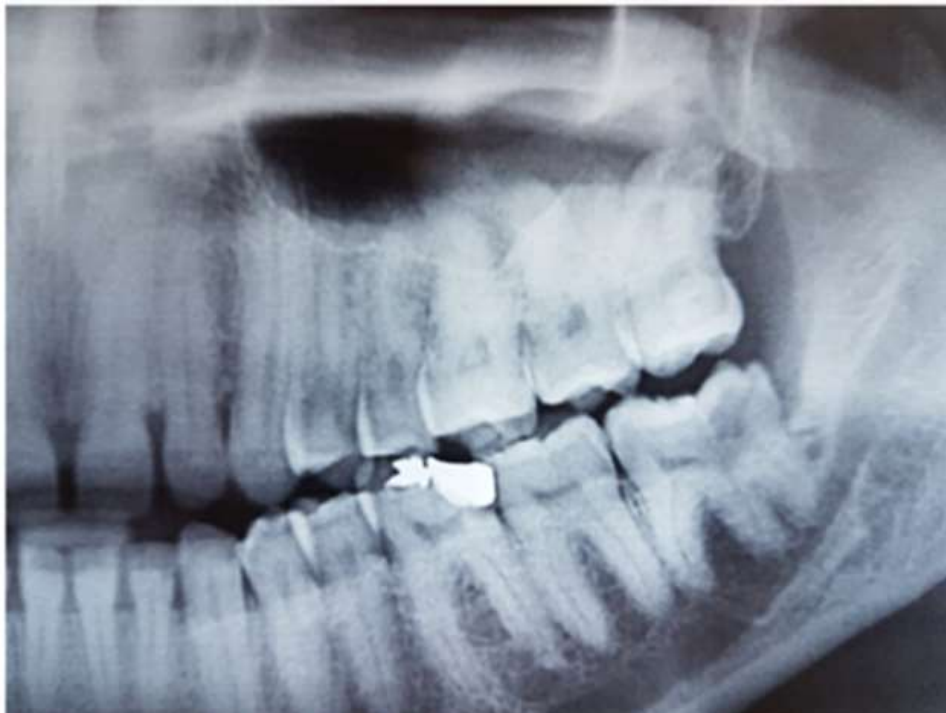Young male patient, 18 years old, with no reported systemic changes, attended the Surgery Clinic of the University of Dentistry of Araçatuba (FOA / UNESP) for evaluation. Clinical examination revealed the presence of elements 18 and 28 erupted in the oral cavity and the presence of 38 submucosal. In panoramic radiography it was possible to observe the presence of fusion between the third and fourth molars (Figures 1,2). In the previous history, the patient reported previous pericoronitis. The proposed treatment plan was extraction of the third molar fused to the fourth molar. The surgical procedure was performed under local anesthesia, followed by an intrasulcular incision (Figure 3a) and osteotomy, exposing the entire crown of the tooth. It was decided to section into 3 parts (mesio-distal direction), using high-speed drill number 702 (Figure 3b) and extractor to cleave (Figure 3c). The 3 parts of the tooth were removed separately, starting with the mesial part (Figure 3d, 3e) followed by irrigation and inspection of the socket (Figure 3f). Figure 2g shows that the roots were separated along with the crown. Finally, sutures in 4-0 silk sutures (Figure 3g) were performed. The surgery was uneventful and the suture was removed 7 days postoperatively.

**Figure 1.** Preoperative panoramic radiography. Total view of the radiograph, which showed the presence of the upper third molars (18 and 28), left lower third molar (38) fused with supernumerary tooth - 4th molar and absence of tooth 48.



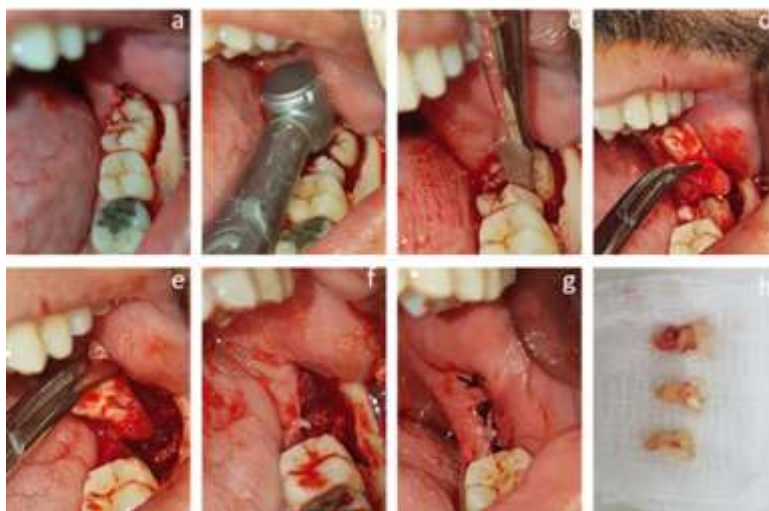
Source: Own authorship.

**Figure 2.** Preoperative panoramic radiography. Cut radiograph, widening the view of the area of interest 38 fused with 4<sup>o</sup> molar.



Source: Own authorship.

**Figure 3.** Transoperative images. (a) mandibular bone tissue exposed with osteotomy of the area, (b) 3-part dissection, separating the 3 roots, (c) cleavage, (d) and (e) removal of the dental element, (f) surgical cavity, (g) flat suture with 4-0 silk thread, (h) tooth sectioned into 3 parts.



Source: Own authorship.

#### 4. Discussion

Dental anomalies generally affect a large part of the population, both in deciduous and permanent dentition, and in some cases are the cause of malocclusions. Therefore, each case should be studied carefully and the treatment plan should be well defined and sharp.

This paper reports a specific case of changes in shape and number, namely fusion and supernumerary teeth. Fusion occurs most frequently in deciduous dentition (0.5-12.5%) (Cai, et al., 2019; Açikel, et al., 2018; Steinbock, et al., 2014; Prakash, et al., 2012; Rosas, et al., 2004), predominantly in incisors and canines (Goh & Tse, 2020; Açikel, et al., 2018; Goswami & Jangra, 2017; Steinbock, et al., 2014; Rosas, et al., 2004; Delany & Goldblatt, 1981), without affecting the total number of teeth in the arch (Liang, et al., 2012). It may be related to syndromes such as osteopetrosis, chondroectodermal dysplasia, achondroplasia, among others and may occur due to interference from environmental factors such as exposure of the fetus to alcohol, hypervitaminosis or thalidomide use during pregnancy (Bamgbose, et al., 2019; Liang, et al., 2012). In relation to supernumerary teeth, they are more common in the population and occur in both dentitions.

When it comes to posterior supernumerary teeth, the most common is the 4th molar. A recently published systematic review (Guler, et al., 2013) showed that the 4th molars are located distally to the third molar, usually isolated and impacted. Its prevalence is between 0.1-3.8%, being more common in the maxilla and may or may not be associated with syndromes, but the incidence is higher in non-syndromic patients (Guler, et al., 2013).

The presence of alterations, both in shape and number, end up causing occlusion problems, such as crowding caused by the lack of space in the arch, as a consequence comes the difficulty of cleaning and the presence of caries (Açikel, et al., 2018); overload on some teeth, causing periodontal problems; and aesthetic problems (Steinbock, et al., 2014).

For diagnosis and treatment choice, imaging exams such as panoramic radiography and / or computed tomography should be available. Imaging exams are extremely important for the visualization of roots, adjacent structures and if other alterations are present (Guler, et al., 2013). Panoramic radiography provides two-dimensional imaging, so there is often image overlap. In those cases where panoramic radiography is not sufficient for diagnosis and study, computed tomography should be



ordered, which provides three-dimensional images closer to reality, showing exact location and distance between the tooth and important adjacent structures such as the mandibular canal example (Guler, et al., 2013; Rao & Hegde, 2010).

There are treatment options for both changes. When fusion occurs in deciduous anterior teeth, extraction can be done, depending on the case, it is necessary to use space maintainer or dental plastic (Steinbock, et al., 2014). In anterior permanent teeth, the bone tissue is mature, thus, the extraction and installation of implants or orthodontic space correction may be performed (Goh & Tse, 2020; Kim, et al., 2019; Rosas, et al., 2004; Velasco, et al., 1997); Root canal treatment can also be followed by dental plastic surgery (Vinothkumar, et al., 2017; Steinbock, et al., 2014).

When fusion occurs in permanent posterior teeth, conservative treatments are more restricted, considering the complexity and number of channels (Liang, et al., 2012). Crowns may be separated with or without associated endodontic treatment, but may cause dentin exposure, causing dental sensitivity, as reported in some studies (Steinbock, et al., 2014).

Another possible treatment would be extraction, which depends on the location of the change, the age of the patient, root development and whether conservative treatment is impossible (Steinbock, et al., 2014). When it comes to surgical treatment, some care should be taken to reduce local trauma and preserve as much bone tissue as possible. Surgical techniques involve extractors and forceps and can be used by applying excessive force to the tooth dislocation, traumatizing the area (Liang, et al., 2012). In the case reported in this article, it involves the third molar, being in the posterior region, the greatest risk is of mandibular angle fracture. In this context, exodontic techniques have been modified to reduce trauma in the operated region, and therefore to reduce the signs and symptoms of the postoperative period (pain, edema and trismus) (Saund & Dietrich, 2013; Hornig & Offermann, 2005).

Minimally invasive surgical techniques use high-speed drills or a straight piece for dental dissection, separating the roots with the purpose of reducing local trauma without excessive force and promoting a more comfortable postoperative period (Saund & Dietrich, 2013; Hornig & Offermann, 2005). It can be done with or without previous osteotomy, which is only used in cases of teeth included or without support point for the use of extractors. The aim is to avoid, whenever possible, alveolectomies to preserve bone tissue. When necessary, they should be performed internally in the alveoli, doing the odontectomy and root sectioning.

The treatment proposed in the case reported in this article was extraction because it is a lower third molar fused with a supernumerary tooth, partially covered by mucosa, lack of arch space and proximity to the mandibular canal. The procedures were explained to the patient, as well as the risks and guidelines. After patient acceptance, dental sectioning was used, separating the third molar from the fourth molar, trying to reduce as much trauma as possible. The same treatment was performed in a similar case previously reported (Rao & Hegde, 2010), which also highlighted the importance of imaging exams, especially computed tomography.

## 5. Conclusion

It is concluded that there are different types of treatment when it comes to dental fusion, always considering the age of the patient, the location of the lesion, the presence of other anomalies and the systemic condition of the patient. Thus, it is of utmost importance to perform a complete clinical examination and careful history, and use imaging tests to complete a diagnosis and define the best treatment plan for the patient.

This article reports a relatively rare case, where two types of abnormalities are found: fusion and supernumerary tooth, therefore containing relevant clinical application, presenting treatment options mentioned in the literature, which should be evaluated by the clinician individually for each case. The choice of treatment must be made through careful assessments of the clinical history (anamnesis) and the patient's oral status, as well as, through imaging tests such as panoramic, periapical and

occlusal radiography, if applicable; in addition to computed tomography whenever possible, obtaining more detailed images, facilitating the diagnosis and definition of the treatment plan.

## References

- Açikel, H., İbiş, S., & Tuğç, E. S. (2018). Primary Fused Teeth and Findings in Permanent Dentition. *Medical principles and practice*, 27(2), 129-132.
- Bamgbose, B. O., Okada, S., Hisatomi, M., Yanagi, Y., Takeshita, Y., Abdu, Z. S., Ekuase, E. J., & Asami, J. I. (2019). Fourth molar: A retrospective study and literature review of a rare clinical entity. *Imaging science in dentistry*, 49(1), 27-34.
- Cai, X., Cui, L., & Chen, K. (2020). Impacted Right Maxillary Third Molar Fused With Supernumerary Tooth. *Journal of the College of Physicians and Surgeons—Pakistan*, 30(5), 552.
- Delany, G. M., & Goldblatt, L. I. (1981). Fused teeth: a multidisciplinary approach to treatment. *The Journal of the American Dental Association*, 103(5), 732-734.
- Duarte, F., Ramos, C., & Fonseca, L. (2006). Dentes supranumerários. *Temática 1*, pp.53-66.
- Garvey, M. T., Barry, H. J., & Blake, M. (1999). Supernumerary teeth--an overview of classification, diagnosis and management. *Journal of the Canadian Dental Association*, 65(11), 612-616.
- Goswami, M., & Jangra, B. A. (2017). Rare Concomitant Occurrence of Talon Cusp in Fused Mandibular Permanent Teeth: Report of Two Cases. *International journal of clinical pediatric dentistry*, 10(2), 208-212.
- Goh, V., & Tse, O. D. (2020). Management of Bilateral Mandibular Fused Teeth. *Cureus*, 12(4), e7899.
- Guler, D. D., Tunc, E. S., Arici, N., & Ozkan, N. (2013). Multidisciplinary Management of a Fused Tooth: A Case Report. *Case reports in dentistry*, 2013, 634052.
- Hornig, H. P., & Offermann, T. (2005). Implant preparation: atraumatic tooth extraction using easy X Trac system tooth extractor. *Dental products report*, 7, 68-69.
- Kim, E. C., Symington, O., & Kulkarni, G. (2019). Conservative Management of Fused and Geminated Permanent Anterior Teeth. *Journal of dentistry for children*, 86(3), 164-168.
- Liang, R. Z., Wu, J. T., Wu, Y. N., Smales, R. J., Hu, M., Yu, J. H., & Zhang, G. D. (2012). Bilateral maxillary fused second and third molars: a rare occurrence. *International journal of oral Science*, 4(4), 231-234.
- Prakash, A. R., Reddy, P. S., & Rajanikanth, M. (2012). Paradental cyst associated with supernumerary tooth fused with third molar: A rare case report. *Journal of Oral and Maxillofacial Pathology*, 16(1), 131-133.
- Pereira, A. S., Shitsuka, D. M., Parreira, F. J., & Shitsuka, R. (2018). Metodologia da pesquisa científica. UFSM.
- Rajab, L. D., & Hamdan, M. A. (2002). Supernumerary teeth: review of the literature and a survey of 152 cases. *International journal of paediatric dentistry*, 12(4), 244-254.
- Rao, D. B., & Hegde, S. (2010). A talon cusp on fused teeth associated with hypodontia: report of a unique case. *European journal of dentistry*, 4(1), 75-80.
- Saund, D., & Dietrich, T. (2013). Minimally invasive tooth extraction doorknobs and strings revisited. *Dental update*, 40(4), 325-326.
- Steinbock, N., Wigler, R., Kaufman, A. Y., Lin, S., Abu-El Naaj, I., & Aizenbud, D. (2014). Fusion of Central Incisors with Supernumerary Teeth: A 10-year Follow-up of Multidisciplinary Treatment. *Journal of endodontics*, 40(7), 1020-1024.
- Velasco, L. F., de Arango, F. B., Ferreira, E. S., & Velasco, L. E. (1997). Esthetic and functional treatment of a fused permanent tooth: a case report. *Quintessence international*, 28(10), 677-680.
- Vinothkumar, T. S., Kandaswamy, D., Arathi, G., Ramkumar, S., & Felsypremila, G. (2017). Endodontic Management of Dilacerated Maxillary Central Incisor fused to a Supernumerary Tooth using Cone Beam Computed Tomography: An Unusual Clinical Presentation. *The journal of contemporary dental practice*, 18(6), 522-526.
- Yang, G. (2012). Supernumerary teeth and gemination. *British Journal of Oral and Maxillofacial Surgery*, 50(1), e15.