

Pyogenic granuloma in a transgender woman: Possible association to the hormonal therapy

Granuloma piogênico em mulher transgênero: Possível associação à terapia hormonal

Granuloma piógeno en una mujer transgénero: Posible asociación con la terapia hormonal

Received: 04/23/2021 | Reviewed: 05/06/2021 | Accept: 05/24/2021 | Published: 06/08/2021

Luana Eduarda de Oliveira

ORCID: <https://orcid.org/0000-0001-6153-9235>

State University of Londrina, Brazil

E-mail: luanaeduarda12@gmail.com

Christopher Brian Bernini e Lima

ORCID: <https://orcid.org/0000-0002-9789-720X>

State University of Londrina, Brazil

E-mail: christopher_lima@hotmail.com

Fabio Augusto Ito

ORCID: <https://orcid.org/0000-0001-6666-0069>

State University of Londrina, Brazil

E-mail: fabioaito@gmail.com

Heliton Gustavo de Lima

ORCID: <https://orcid.org/0000-0002-2384-5554>

Federal University of Parana, Brazil

E-mail: helitonlima@ufpr.br

Ademar Takahama Junior

ORCID: <https://orcid.org/0000-0002-0680-3926>

State University of Londrina, Brazil

E-mail: fabioaito@gmail.com

Abstract

Transgender persons can be understood as those whose gender identity does not conform to the norms imposed by society regarding the gender designated at birth, based on the genitalia. Obviously, secondary sex characteristics are contingent on sex steroids. Hormonal reassignment has two aims: to reduce the hormonally induced secondary sex characteristics of the original sex and to induce the secondary sex characteristics of the new sex. The use of these sex steroid hormones can favor the development of oral mucosal lesions, such as pyogenic granuloma, which it is a non-neoplastic vascularized lesion, common in the oral cavity, caused by trauma, local irritants, or hormonal factors. The etiology is currently unclear, but trauma and increased level of estrogen and progesterone have been suggested as potential contributing factors. Therefore, the main purpose of this article is to report a pyogenic granuloma developing in a male-to-female transsexual patient which may be associated to the hormonal therapy and highlights the effects of hormone therapy on oral tissues.

Keywords: Transsexualism; Estradiol; Cyproterone acetate; Pyogenic granuloma.

Resumo

Pessoas transgênero são aquelas cuja identidade de gênero não se enquadra nas normas impostas pela sociedade quanto ao gênero designado ao nascer, com base na genitália. Obviamente, as características sexuais secundárias dependem dos esteroides sexuais. A redesignação hormonal tem dois objetivos: reduzir as características sexuais secundárias induzidas por hormônios do sexo original e induzir as características sexuais secundárias do novo sexo. O uso desses hormônios esteroides sexuais pode favorecer o desenvolvimento de lesões da mucosa oral, como o granuloma piogênico, que é uma lesão vascularizada não neoplásica, comum na cavidade oral, causada por trauma, irritantes locais ou fatores hormonais. A etiologia atualmente não é clara, mas trauma e aumento do nível de estrogênio e progesterona têm sido sugeridos como potenciais fatores contribuintes. Portanto, o objetivo principal deste artigo é relatar um granuloma piogênico em desenvolvimento em uma mulher transgênero que pode estar associado à terapia hormonal e destacar os efeitos da terapia hormonal nos tecidos orais.

Palavras-chave: Transexualidade; Estradiol; Acetato de ciproterona; Granuloma piogênico.

Resumen

Las personas transgéneras pueden entenderse como aquellas cuya identidad de género no se ajusta a las normas impuestas por la sociedad en cuanto al género designado al nacer, con base en los genitales. Obviamente, las características sexuales secundarias dependen de los esteroides sexuales. La reasignación hormonal tiene dos objetivos: reducir las características sexuales secundarias inducidas por hormonas del sexo original e inducir las

características sexuales secundarias del nuevo sexo. El uso de estas hormonas esteroides sexuales puede favorecer el desarrollo de lesiones de la mucosa oral, como el granuloma piógeno, que es una lesión vascularizada no neoplásica, frecuente en la cavidad oral, provocada por traumatismos, irritantes locales o factores hormonales. Actualmente, la etiología no está clara, pero se han sugerido como posibles factores contribuyentes el trauma y el aumento del nivel de estrógeno y progesterona. Por lo tanto, el propósito principal de este artículo es informar un granuloma piógeno que se desarrolla en una mujer transgénero que puede estar asociado a la terapia hormonal y destaca los efectos de la terapia hormonal en los tejidos orales.

Palabras clave: Transexualidad; Estradiol; Acetato de ciproterona; Granuloma piógeno.

1. Introduction

Localized gingival enlargements are common in clinical practice and usually develop as a response to chronic local irritation or trauma (Buchner, Shnaiderman-Shapiro & Vered, 2010). Pyogenic granuloma (PG) is defined as a non-neoplastic inflammatory hyperplasia, characterized by inflamed granulation tissue which may be originate in the oral cavity or skin (Vilmann, A., P., H., 1986). When affects pregnant woman, it is called pregnancy pyogenic granuloma (PPG), occurring in up to 5% of pregnancies (Jafarzadeh, Sanatkhani & Mohtasham, 2006). The exact etiology of PPG is currently unknown, but trauma and increased hormonal level (estrogen and progesterone) have been suggested as the main potential contributing factors (Manegold-Brauer & Brauer, 2014). The hormonal imbalance is responsible for favoring vascular endothelial growth factor production in macrophages, inducing chronic tissue reaction, and stimulating vascular proliferation in areas subject to small trauma or chronic irritative factors (Adeyemo, Hassan & Ajayi, 2011), such as dental biofilm.

The Gender Identity Disorder is characterized by a strong and persistent identification with the opposite sex and persistent discomfort with biological sex itself and other roles assigned to it (American Psychiatric Association, 2013). Cross-sex hormonal therapy interests transgender patients as a means of matching their gender identification and physical appearance. It induces the development of the secondary sex characteristics of the desired sex and diminishes those of the biological sex (Hembree et al., 2009). In male-to-female transgenders, hormonal treatment with estrogens and antiandrogens induces breast enlargement, a female distribution of fat, and a reduction of male-pattern hair growth (Michel, Mormont & Legros, 2001). We present here a case of a PG developing in a male-to-female transgender patient which may be associated to the hormonal therapy.

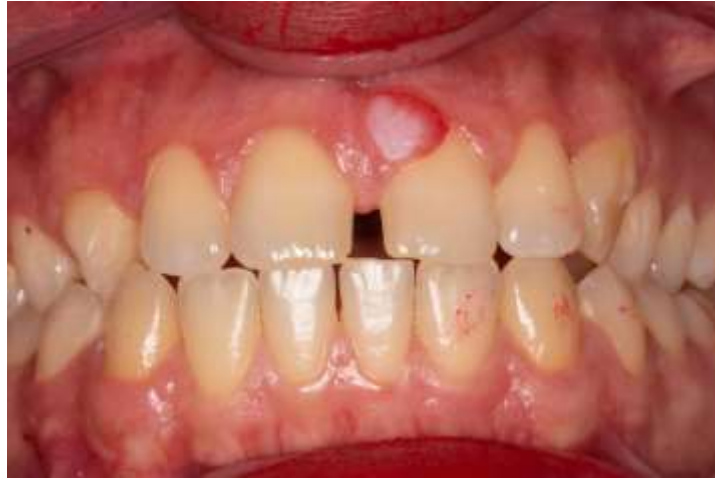2. Methodology

This paper consists of a clinical case report, characterized as a descriptive, exploratory and qualitative study (Pereira et al., 2018). This case report describes the clinical and microscopic features of a PG developing in a male-to-female transgender patient. In addition, relevant data from the literature regarding the effects of hormone therapy on oral tissues were discussed. For the accomplishment of this study, a signed consent form was obtained from the patient for treatment, use of images and scientific exposure, respecting ethical principles. Relevant data from the literature regarding the effects of hormone therapy on oral tissues also were discussed.

3. Case Report

A 27-year-old male-to-female transgender patient was referred to service of Stomatology at the State University of Londrina (UEL) complaining of a lesion in the gum. During anamnesis, she reported the beginning of the cross-sex hormone therapy about 1.5 year ago, which consisted of Cyproterone Acetate (50 mg/day) and Estradiol Valerate (4 mg/day). Besides, she reported the current use of fluoxetine, promethazine, and diazepam for the treatment of depression and anxiety. On physical examination it was noticed a single nodular lesion, measuring about 0,5 cm of diameter and a regular contour, sessile, fibroelastic consistency and reddish color with whitish areas, located in marginal gingiva of teeth 11 and 21 (Figure 1).

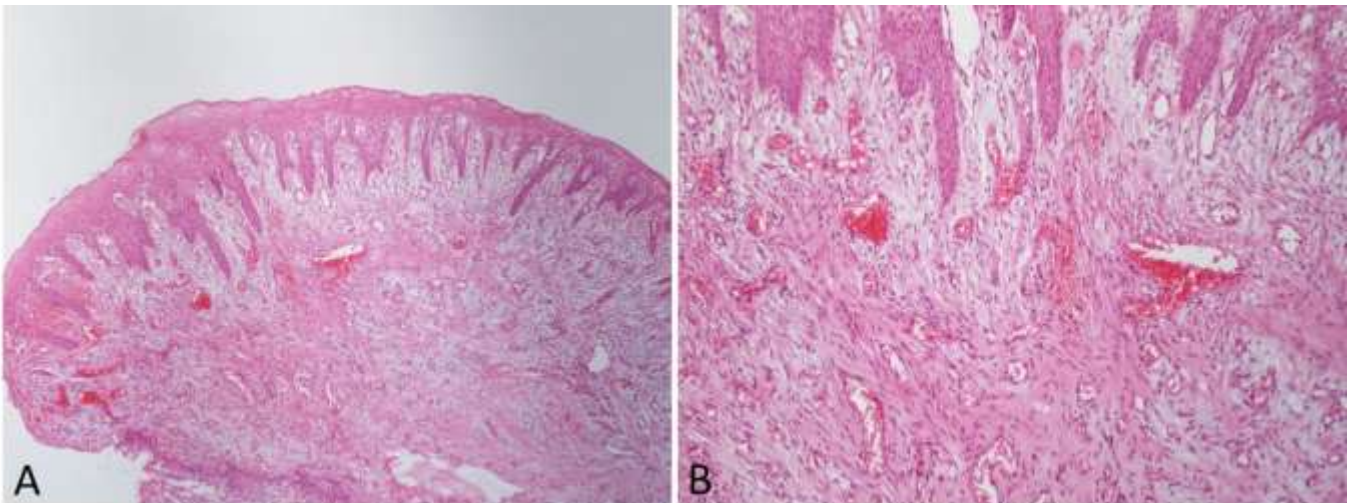
Figure 1. Clinical appearance of the lesion.



Source: Stomatology UEL.

Persistent for 10 months and no painful symptomatology. No radiographic changes were observed in the region of the lesion. The patient had good oral hygiene and presence of diastema between the upper central incisors. After complete clinical examination, our diagnostic hypotheses were of PG and peripheral ossifying fibroma. The conduct was excisional biopsy besides scaling and root planing during the surgical procedure. Histopathological analysis was compatible with histopathological diagnosis of PG (Figure 2). After 36 months there was no recurrence of the lesion.

Figure 2 - Histopathological features of pyogenic granuloma. A) and B) microscopic examination revealing presence of mucosa lined by a stratified squamous epithelium, with areas of hyperplasia. Submucosally, fibrous connective tissue with well vascularized granulation tissue, chronic inflammatory infiltrate, and areas of fibrosis. (HE, 40x and 100x).



Source: Stomatology UEL.

4. Discussion

PG is usually considered to be a reactive tumor-like lesion which arises in response to various stimuli such as a chronic low-grade local irritation, traumatic injury, hormonal factors, or certain kinds of drugs (Regezi, Sciubba & Jordan, 2003). Although PG may occur in all ages, it is predominant in the second decade of life in young adult females, possibly

because of the vascular effects of female hormones (Al-Khateeb & Ababneh, 2003). In this present case, the patient was in hormone treatment to change of sex.

Transgender people have the perception of their physical appearance as unattractive is common, particularly before the onset of sex reassignment treatment and during the transition to the other sex (Gomez-Gil et al., 2009). Individuals who feel unattractive tend to have more social anxiety and to suffer mixed adaptive emotional disorders such as anxiety and depression (Leary & Kowalski, 1995). Because of prejudice and the fear of being disclosed, many patients with gender dysphoria do not seek medical care but often resort to self-medication to affirm the sex with which they self-identify (Asscheman, Gooren & Eklund, 1989). It is known that most transgender women and transvestite self-medicate due to lack of access to health services (Kruger et al., 2019). Most arrive at the health service taking a large dosage of birth control pills or medications for hormonal stabilization, believing that this way will accelerate the modification of your body characteristics (Amaral et al., 2017). In our case, the patient suffered from depression and anxiety, where the same made use of fluoxetine, promethazine, and diazepam for the treatment. These drugs are associated with an increased risk of dry mouth, also known as xerostomia, resulting in accumulation of biofilm with many effects on oral health, and may have a negative impact on quality of life (Fox, Busch & Baum, 1987). In our patient no change in relation to the salivary flow was observed. The etiology of PG is complex, it is believed that the inflammatory reaction to the local dental biofilm irritation under poor oral hygiene may lead to a PG (Neville & Day, 2002). Increased concentrations of estrogen and progesterone raises the levels of *Prevotella intermedia* in the subgingival biofilm, diminishes the host response to bacterial biofilm, increases vascular permeability, favors the infiltration of fluids into the perivascular tissues and enhances the inflammatory response (Mealey & Moritz, 2003), having an important role in the development of the lesion.

Feminizing treatment for male-to-female individuals consists of using an estrogen or antiandrogen alone or in combination. Individuals should be treated with the lowest effective hormone doses, and the focus of treatment should be based on the individual's response and not just hormone levels (Hembree et al., 2009). The combination will stimulate a decrease in male pattern hair growth, change body fat distribution and induce breast tissue formation. In addition, the hormone combination will decrease testicular size and erectile function (Unger, 2016). The estrogen most often used is 17- β estradiol, while cyproterone and spironolactone are favored over flutamide or gonadotropin-releasing hormone agonists as antiandrogens (Tangpricha, 2017). In our case, the patient initiated cross-sex hormone therapy about 1.5 years ago, which consisted of estradiol velerate (4mg/day) and cyproterone acetate (50 mg / day).

It is known that in male to female transgender patients commencing oral estrogen there were significant changes in circulating inflammatory markers. The greatest health concern for hormonal therapy in transgender women is venous thromboembolism (Werinard & Safer, 2015). The "first-pass" hypothesis of liver metabolism of estrogen proposes that there is a decrease of thromboembolic and other cardiovascular events with the use transdermal as opposed to oral estrogen therapy (Goodman, 2012). While some guidelines for transgender medical care express concerns for elevated cancer risk with certain hormone regimes, current data suggest that the risk of cancer may not rise (Wierckx et al. , 2013). During the anamnesis, our patient did not report any systemic changes or family history, beyond depression and anxiety, nor did he report any side effects in the mouth caused using hormonal therapy.

Sex steroid hormones exert influences on cellular proliferation, differentiation, and growth in target tissues. Estrogen can influence the cytodifferentiation of stratified squamous epithelium as well as the synthesis and maintenance of fibrous collagen. The action of the hormones on these cells changes the effectiveness of the epithelial barrier to bacterial insult and collagen maintenance and repair. These hormones may alter immunologic factors and responses, including antigen expression and presentation, cytokine production as well as the expression of apoptotic factors and cell death. Progesterone has been shown to stimulate the production of prostaglandin E2 and enhance the accumulation of polymorphonuclear leukocytes in the

gingival sulcus and down regulates interleukin 6 production by human gingival fibroblasts. As a result, to these effects, an exaggerated inflammatory response of periodontal tissues may be seen stage with the variation in the level of sex steroid hormone (Krejci & Bissada, 2002). The gingiva can be proposed as another “target organ” for the direct action of estrogen and progesterone hormone (Agha-Hosseini, Tirgari & Shaigan, 2006).

The estrogen affects the salivary peroxidases, by changing the oxidation–reduction potential impairing their action against various types of bacteria. Both estrogen and progesterone, associated with inflammatory mediators, can promote changes in vascular responses and connective tissue turnover in the periodontium. This association may explain the higher prevalence of inflammation during periods of hormonal fluctuation (Figueiredo et al., 2017). In the present case, the patient reported having stopped hormonal therapy and no recurrence has been noted during a 3-year follow-up, suggesting strongly believe that the development of PG in our patient, occurred due to hormonal therapy.

Trauma has also been implicated in etiopathogenesis oral PG because can cause release of various endogenous substances including angiogenic factors from the tumor cells and it may also cause disturbances in the vascular system of the affected area. As there is a site predilection for labial gingiva in the anterior region of the oral vestibule, some authors have postulated that habitual tooth brushing may also be considered as a significant cause of microtrauma and irritation to the gingiva (Yih et al., 2000). In our case, the patient reported that no trauma occurred in the oral cavity prior to the appearance of the lesion.

Excisional biopsy is indicated for treatment of PG, except when the procedure would produce marked deformity; in such a case, incisional biopsy is mandatory. Although conservative surgical excision and removal of causative irritants (plaque, calculus, foreign materials, trauma) are the usual treatments for gingival lesions, the excision should extend down to the periosteum and the adjacent teeth should be thoroughly scaled to remove the source of continuing irritation (Esmeli, Lozada-Nur & Epstein, 2005). If uncontrolled bleeding occurs, management should be based on the individual condition and should range from supportive therapy such as desiccation of bleeders; local, firm compression and oral hygiene to blood transfusion (Wang et al., 1997). Although, there were no complications in the trans-surgical period, it is worth emphasizing the importance of the care of the dentist in the treatment of the PG, since life-threatening massive hemorrhages have been reported. Histologically, PG is composed of proliferative capillaries surrounded by inflammatory tissue forming a lobular. This composition means that easy hemorrhaging and, sometimes, pain are distinguishing features of PG (Tsai et al., 2015).

5. Final Considerations

In summary, this case highlights that the hormonal association can play an important role in the development of lesions of the oral mucosa, such as PPG. However, this lesion does not have a clear etiology, requiring further studies in a controlled manner, with methodologies consolidated in the literature. Trans health is an evolving field that includes physiological, psychological, and societal considerations for the optimization of health. Medical and dental follow-up should be carried out with the aim of promoting health and educating transgender people and the population in general, as the use of sex hormones can bring oral manifestations, as well as impacting quality of life.

References

- Adeyemo, W. L., Hassan, O. O., & Ajayi, O. F. (2011). Pregnancy-associated pyogenic granuloma of the lip: a case report. *Niger J Med* 2011, 20(1), 179-180.
- Agha-Hosseini, F. H., Tirgari, F., & Shaigan, S. (2006). Immunohistochemical analysis of estrogen and progesterone receptor expression in gingival lesions. *Iran J Public Health*, 35(2), 38-41.
- Al-Khateeb, T., & Ababneh, K. Oral pyogenic granuloma in Jordanians: a retrospective analysis of 108 cases. (2003). *J Oral Maxillofac Surg*, 61(11), 1285-1288. 10.1016 / s0278-2391 (03) 00729-8.

- Amaral, A. F. R., Silva, D. G., Cordeiro, D. M., Assunção, L. F. O., Alves, N. R., Oliveira, T. C., et al. (2017). Side effects arising from hormonal therapy in girls transsexuals. *Brazilian Journal of Surgery and Clinical Research*, 20(3), 103-110.
- American Psychiatric Association (APA). (2013). Diagnostic and statistical manual of mental disorders. APA.
- Asscheman, H., Gooren, L. J., & Eklund, P. L. (1989). Mortality and morbidity in transsexual patients with cross-gender hormone treatment. *Metabolism*, 38(9), 869-873. 10.1016 / 0026-0495 (89) 90233-3.
- Buchner, A., Shnaiderman-Shapiro, A., & Vered, M. (2010). Relative frequency of localized reactive hyperplastic lesions of the gingiva: a retrospective study of 1675 cases from Israel. *J Oral Pathol Med*, 39(8), 631-638. 10.1111 / j.1600-0714.2010.00895.x.
- Esmeili, T., Lozada-Nur, F., & Epstein, J. (2005). Common benign oral soft tissue masses. *Dent Clin North Am*, 49(1), 223-240. doi:10.1016/j.cden.2004.07.001.
- Figueiredo, C. S. A., Rosalem, C. G. C., Cantanhede, A. L. D., Thomaz, E. B. A. F., & Cruz, M. C. F. N. (2017). Systemic alterations and their oral manifestations in pregnant women. *J Obstet Gynaecol Res*, 43(1), 16-22. 10.1111/jog.13150.
- Fox, P. C., Busch, K. A., & Baum, B. J. (1987). Subjective reports of xerostomia and objective measures of salivary gland performance. *J Am Dent Assoc*, 115(4), 581-584. 10.1016 / s0002-8177 (87) 54012-0.
- Gomez-Gil, E., Canizares, S., Torres, A., Torre, F., Halperin, I., & Salamero, M. (2009). Androgen treatment effects on memory in female-to-male transsexuals. *Psychoneuroendocrinology*, 34(1), 110-117. 10.1016 / j.psyneuen.2008.08.017.
- Goodman, M. P. (2012). Are all estrogens created equal? A review of oral vs. transdermal therapy. *J Womens Health*, 21(2), 161-169. 10.1089 / jwh.2011.2839.
- Hembree, W. C., Cohen-Kettenis, P., Delemarre-van de Waal, H. A., Gooren, L. J., Meyer, W. J., Spack, N. P., et al. (2009). Endocrine treatment of transsexual persons: an Endocrine Society clinical practice guideline. *J Clin Endocrinol Metab*, 94(9), 3132-3154. 10.1210/jc.2009-0345.
- Jafarzadeh, H., Sanatkhan, M., & Mohtasham, N. (2006). Oral pyogenic granuloma: a review. *J Oral Sci*, 48(4), 167-175. 10.2334 / josnusd.48.167.
- Krejci, C. B., & Bissada, N. F. (2002). Women's health issues and their relationship to periodontitis. *J Am Dent Assoc*, 133(3), 323-329. 10.14219 / jada.archive.2002.0171.
- Kruger, A., Sperandei, S., Bermudez, X. P. C. D., & Merchán-Hamann, E. (2019). Characteristics of hormone use by travestis and transgender women of the Brazilian Federal District. *Rev bras epidemiol*, 22 (1). <https://doi.org/10.1590/1980-549720190004.supl.1>.
- Leary, M. R., & Kowalski, R. M. (1995). Emotions and social behavior. Social Anxiety. Guilford Press.
- Manegold-Brauer, G., & Brauer, H. U. (2014). Oral pregnancy tumour: an update. *J Obstet Gynaecol*, 34(2), 187-188. 10.3109 / 01443615.2013.834308.
- Mealey, B. L., & Moritz, A. J. (2003). Hormonal influences: effects of diabetes mellitus and endogenous female sex steroid hormones on the periodontium. *Periodontol 2000*, 32(1), 59-81. <https://doi.org/10.1046/j.0906-6713.2002.03206.x>.
- Michel, A., Mormont, C., & Legros, J. J. (2001). A psycho-endocrinological overview of transsexualism. *Eur J Endocrinol*, 145(4), 365-376. doi:10.1530/eje.0.1450365.
- Neville, B. W., & Day, T. A. (2002). Oral cancer and precancerous lesions. *CA: a Cancer Journal for Clinicians*, 52(4), 195-215. 10.3322 / canjclin.52.4.195.
- Pereira, A. S., Shitsuka, D. M., Parreira, F. J., & Shitsuka, R. (2018). Metodologia da pesquisa científica. UFSM. https://repositorio.ufsm.br/bitstream/handle/1/15824/Lic_Computacao_Metodologia-Pesquisa-Cientifica.pdf.
- Regezi, J. A., Sciubba, J. J., & Jordan, R. C. K. (2003). Oral pathology: clinical pathologic considerations. Philadelphia: WB Saunders.
- Tangpricha, V., & Hejjer, M. (2017). Oestrogen and anti-androgen therapy for transgender women. *Lancet Diabetes Endocrinol*, 5(4), 291-300. 10.1016 / S2213-8587.
- Tsai, K. Y., Wang, W. H., Chang, G. H., & Tsai, Y. H. (2015). Treatment of pregnancy-associated oral pyogenic granuloma with life-threatening haemorrhage by transarterial embolization. *J of Laryngology & Otology*, 129(6), 607-610. 10.1017 / S0022215115001176.
- Unger, C. A. Hormone therapy for transgender patients. (2016). *Transl Androl Urol*, 5(6), 877-884. 10.21037 / tau.2016.09.04.
- Vilmann, A., Vilmann, P., & Vilmann, H. (1986). Pyogenic granuloma: evaluation of oral condition. *British Journal of Oral and Maxillofacial Surgery*, 24(5), 376-382. 10.1016/ 0266-4356 (86) 90023-9.
- Wang, P. H., Chao, H. T., Lee, W. L., Yuan, C. C., & Ng, H. T. (1997). Severe bleeding from a pregnancy tumor: A case report. *J Reprod Med*, 42(6), 359-362.
- Werinard, J. D., & Safer, J. D. (2015). Hormone therapy in transgender adults is safe with provider supervision; A review of hormone therapy sequelae for transgender individuals. *J Clin Transl Endocrinol*, 2(2), 55-60. 10.1016/j.jcte.2015.02.003.24.
- Wierckx, K., Elaut, E., Declercq, E., Heylens, G., Cuyper, G., Taes, Y., Kaufman, J. M., et al. (2013). Prevalence of cardiovascular disease and cancer during cross-sex HRT in a large cohort of trans persons: a case-control study. *Eur J Endocrinol*, 169(4), 471-478. 10.1530 / EJE-13-0493.
- Yih, W. Y., Richardson, L., Kratochvil, F. J., Avera, S. P., & Zieper, M. B. (2000). Expression of estrogen receptors in desquamative gingivitis. *J Periodontol*, 71(3), 482-487. 10.1902 / jop.2000.71.3.482.