

Application of an active oxygen (blue®m) with free connective graft technique for root coverage – a case report

Aplicação tópica do gel com oxigênio ativo (blue®m) auxiliando na cicatrização na técnica de recobrimento radicular com enxerto conjuntivo livre – um estudo de caso

Aplicación tópica de gel con oxígeno activo (blue®m) que ayuda a la curación en la técnica de cobertura radicular con injerto conjuntivo libre – un caso de estudio

Received: 04/26/2021 | Reviewed: 05/04/2021 | Accept: 05/04/2021 | Published: 05/17/2021

Jeferson Luis de Oliveira Stroparo

ORCID:<https://orcid.org/0000-0003-1094-530X>

Universidade Positivo, Brazil

E-mail: jef_stroparo@hotmail.com

Suyany Gabriely Weiss

ORCID:<https://orcid.org/0000-0002-5778-3144>

Universidade Positivo, Brazil

E-mail: suyanyweiss@hotmail.com

Carmen Lucia Mueller Storrer

ORCID:<https://orcid.org/0000-0002-1188-8848>

São Leopoldo Mandic, Brazil

E-mail: carmen.storrer@gmail.com

Tatiana Miranda Deliberador

ORCID:<https://orcid.org/0000-0003-4076-4905>

Instituto Latino Americano de Pesquisa e Ensino Odontológico ILAPEO, Brazil

E-mail: tdeliberador@gmail.com

Abstract

Gingival recession occurs due to the migration of the gingiva in the apical direction, leading to compromising local aesthetics and root hypersensitivity. Connective tissue graft is the gold standard treatment in these cases improving both functional and aesthetics aspects. The purpose of this case is to report root coverage using the free connective tissue grafting technique (CTG) associated with topical application of active oxygen oral gel and mouthwash (blue®m). A 27-year-old female sought care with the main complaint of root hypersensitivity and the presence of gingival recession in the anterior region of the mandible. Clinical examination revealed the presence of type 1 gingival recession in the left mandibular central incisor. The treatment of choice was a modified graft (free connective graft). The graft and recipient bed received applications of blue®m oral gel. The patient was instructed to use blue®m mouthwash and blue®m oral gel after the surgery for 10 days. At 60 days, the patient showed satisfactory healing in the area of the free CTG, with gain of keratinized tissue and partial covering of the gingival recession. Free CTG with the support of the gel and the mouthwash with active oxygen release makes the technique viable, preventing graft necrosis and achieving root coverage and keratinized tissue.

Keywords: Gingival recession; Oral surgery; Oxygen therapies.

Resumo

A recessão gengival ocorre devido à migração da gengiva no sentido apical, levando ao comprometimento da estética local e à hipersensibilidade radicular. Enxerto de tecido conjuntivo é o tratamento padrão ouro nesses casos, melhorando os aspectos funcionais e estéticos. O objetivo deste caso é relatar a cobertura da raiz usando a técnica de enxerto de tecido conjuntivo (CTG) livre associada à aplicação tópica de gel de oxigênio ativo e enxaguatório bucal (blue®m). Uma mulher de 27 anos procurou atendimento com queixa principal de hipersensibilidade radicular e presença de recessão gengival na região anterior da mandíbula. O exame clínico revelou a presença de recessão gengival tipo 1 no incisivo central inferior esquerdo. O tratamento de escolha foi um enxerto modificado (enxerto conjuntivo livre). O enxerto e o leito receptor receberam aplicações de gel oral blue®m. O paciente foi orientado a usar enxaguatório bucal blue®m e gel oral blue®m após a cirurgia por 10 dias. Aos 60 dias, a paciente apresentava cicatrização satisfatória na área do CTG livre, com ganho de tecido queratinizado e cobertura parcial da recessão gengival. A CTG livre com o suporte do gel e o enxaguatório com liberação ativa de oxigênio tornam a técnica viável, evitando a necrose do enxerto, possibilitando o recobrimento radicular com tecido queratinizado.

Palavras-chave: Recessão gengival; Cirurgia oral; Oxigenoterapia.

Resumen

La recesión gingival se produce por la migración de la encía en dirección apical, lo que compromete la estética local y la hipersensibilidad radicular. El injerto de tejido conectivo es el tratamiento estándar de oro en estos casos mejorando tanto los aspectos funcionales como estéticos. El propósito de este caso es reportar la cobertura radicular utilizando la técnica de injerto de tejido conectivo libre (CTG) asociada a la aplicación tópica de gel oral de oxígeno activo y enjuague bucal (blue®m). Una mujer de 27 años solicitó atención con el síntoma principal de hipersensibilidad radicular y presencia de recesión gingival en la región anterior de la mandíbula. El examen clínico reveló la presencia de recesión gingival tipo 1 en el incisivo central mandibular izquierdo. El tratamiento de elección fue un injerto modificado (injerto conectivo libre). El injerto y el lecho receptor recibieron aplicaciones de gel oral blue®m. Se le indicó al paciente que usara enjuague bucal blue®m y gel oral blue®m después de la cirugía durante 10 días. A los 60 días, la paciente presentó cicatrización satisfactoria en la zona de la CTG libre, con ganancia de tejido queratinizado y recubrimiento parcial de la recesión gingival. El CTG libre con el apoyo del gel y el enjuague bucal con liberación activa de oxígeno hace viable la técnica, previniendo la necrosis del injerto y consiguiendo cobertura radicular y tejido queratinizado.

Palabras clave: Recesión gingiva; Cirugía oral; Oxigenoterapia.

1. Introduction

Gingival recession is defined as the exposure of the root of the dental element in the oral environment, due to the migration of the gingiva in the apical direction. ^[1]When this occurs, some pathologies can settle in the patient, ranging from the risk of caries, erosion, root hypersensitivity and lack of esthetics (Zucchelli & Sanctis 2000; Zucchelli *et al.*, 2011; Storrer *et al.*, 2019; Fernandes *et al.*, 2021). The etiological factors of gingival recessions include inadequate restorations, poorly positioned teeth, cavities, periodontal disease and due to the inadequate insertion of the labial frenulum. It is more likely to occur in patients with a thin tissue phenotype (Yadav *et al.*, 2018; Storrer *et al.*, 2019).

The new classification of gingival recessions based on the measurement of interdental clinical insertion is divided into: Type 1 recession (RT1), which has gingival recession without loss of interproximal insertion, Type 2 recession (RT2) in which there is gingival recession but with loss of interproximal insertion, in which the measure of the cemento-enamel junction is less than or equal to the loss of buccal insertion, Recession type 3 (RT3) in which there is gingival recession but with loss of interproximal insertion, in which the measure of the cemento-enamel junction is greater than the loss of oral insertion (Cortellini & Bissada 2020).

The free gingival graft technique (FGG) has great predictability of success in treating gingival recessions, having also been widely used to gain keratinized tissue. However, it has some disadvantages, such as the discrepancy in texture and color-mismatch between the healed graft and the graft recipient area (Zucchelli *et al.*, 2006; Zucchelli & Mounssif 2015; Yoshino *et al.*, 2020; Araujo *et al.*, 2021). The use of subepithelial connective tissue graft (CTG) is reported to be the gold standard for correcting these defects, including as its greatest advantage the increase in the volume of soft tissue and the contouring of the gingival margin (Sculean *et al.*, 2014; Thoma *et al.*, 2020).

2. Methodology

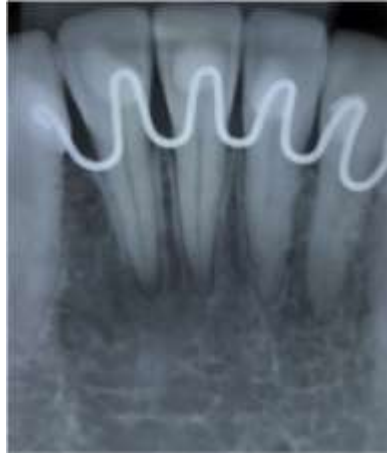
This article is a case report, approached in a descriptive and qualitative way, where considering that oxygenation is a major determinant of healing outcomes, and in order to minimize the main disadvantage of the free CTG, the purpose of this case is to report a root coverage using the free CTG associated with topical application of the gel and mouthwash blue®m to aid healing. The informed consent form was signed by the patient.

3. Case Report

A 27-year-old female (LMBC) came to the clinic at with the main complaint of root hypersensitivity and the presence of gingival recession in the anterior region of the mandible. The patient reported he has been feeling the discomfort for a few

years. Through anamnesis, the patient reported no systemic diseases. Through periapical radiograph, it is possible to observe that the patient has no interproximal bone loss (Figure 1)

Figure 1 - Initial periapical radiography.



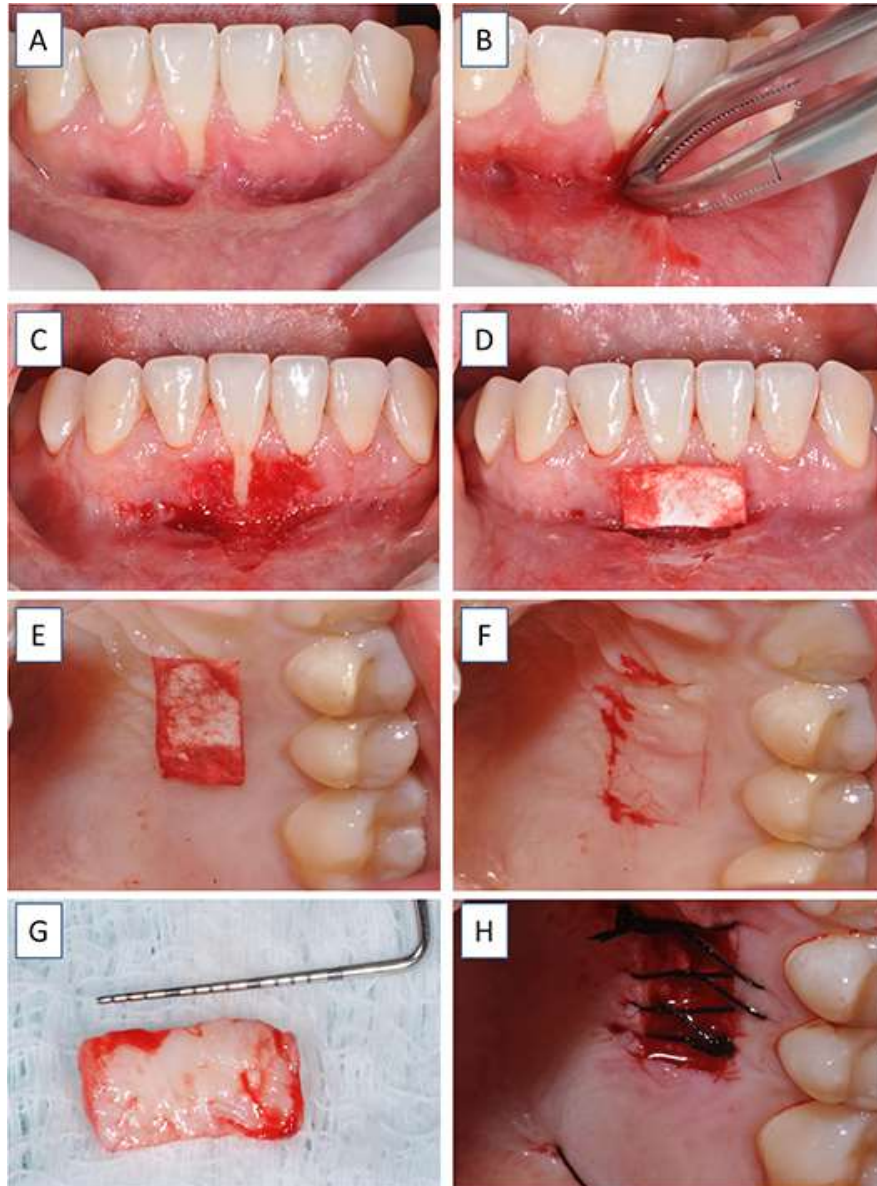
Showing that there is no interproximal bone loss. Source: Authors.

In Clinical examination revealed the presence of type 1 gingival recession (RT 1) in the left mandibular central incisor(41)(Figure 2A), with the influence of the lower lip frenulum and previous orthodontic movement as etiological factors. The treatment of choice was a free connective tissue graft to avoid the whitish aspect of a free gingival graft.

After measuring blood pressure, which presented normal range (120/80mmHg), intra and extra-oral antisepsis was performed followed by infiltrative anesthesia in the antero-inferior region with articaine 4% plus epinephrine 1: 100,000, (Articaine DFL, Rio de Janeiro - RJ, Brazil). In the same surgical procedure, prior to the graft, the lower lip frenectomy was performed. With the aid of two curved hemostatic forceps, the lower lip frenulum was pinched (Figure 2 B) and with a 15c scalpel blade (Solidor, China, People's Republic), it was removed. The gingival region inserted laterally to tooth was de-epithelialized, preparing the recipient bed to receive the graft (Figure 2 C).

Using the sterile suture paper, a surgical map was made to plan the necessary graft size (Figure 2D). The map was taken to the donor bed (palate) in the region between the distal of the canine and mesial of the first molar (Figure 2E), to demarcate the region of graft removal (Figure 2F). With a 15c scalpel blade (Solidor, China, People's Republic), the incision was made, and the graft was removed as in the FGG technique (Figure 2G). After its removal, it was left on sterile gauze moistened with saline solution and the donor bed was sutured with continuous scalloped suture (Figure 2H).

Figure 2 - Frenectomy surgery, preparation of the recipient bed and removal of the tissue graft.



A) Presence of type 1 gingival recession in tooth 41; B) Double clamping with curved hemostat on the lower lip frenulum to perform the frenectomy; C) Frenectomy performed and desepithelized gingival area to receive the graft; D) Surgical map with the role of the suture thread to plan the size of the graft to be removed from the donor bed; E) The surgical map positioned on the donor bed between the distal of the canine and the mesial of the first molar; F) Marked region for graft removal; G) Gingival graft removed; H) Donor bed sutured. Source: Authors.

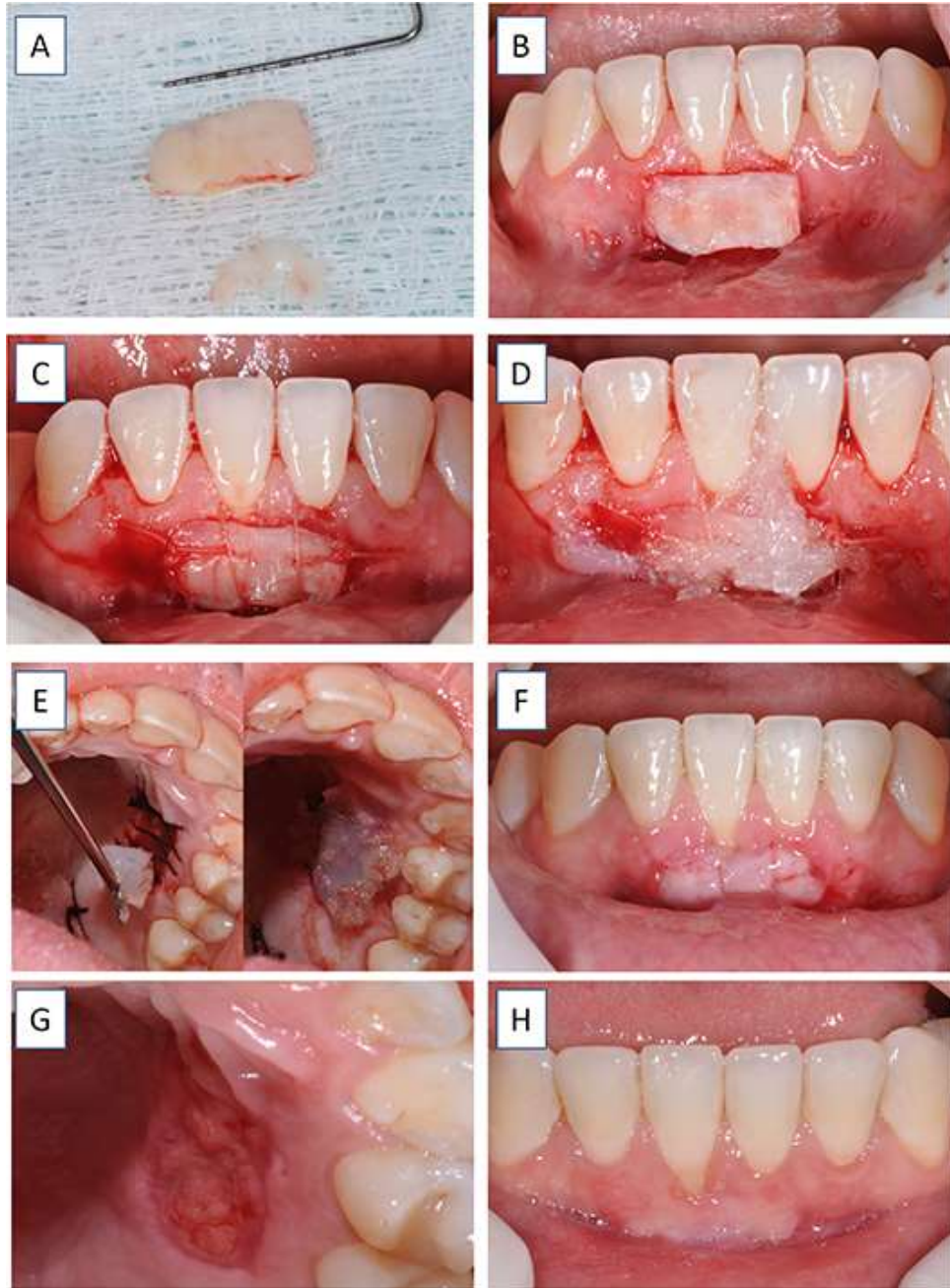
The removed graft was then de-epithelialized with a No. 15c scalpel blade (Solidor, China, People's Republic), removing the entire epithelium, leaving only the connective tissue portion (figure 3A). The free connective graft was then positioned on the recipient bed (Figure 3B) and was sutured using a 5-0 absorbable suture thread (Vicryl, São Paulo-SP, Brazil) with a simple suture on each end and a compressive suture on the graft (Figure 3C). Oral gel with active oxygen (blue@m, 5 Pillars Research B.V. - Holland, Netherlands) was used in the graft recipient bed (figure 3D) and in the donor bed (Figure 3E).

Amoxicillin 500mg was prescribed, one capsule every eight hours for seven days, ibuprofen 600mg, one tablet every eight hours for three days, paracetamol 750mg, one tablet every eight hours for three days. The patient was orientated to use

blue@oral mouthwash every eight hours for 10 days as well as to use the blue@oral oral gel once a day until the sutures were removed.

The patient reported little postoperative pain. The sutures were removed 10 days after the operation, and it was possible to see that the free connective graft and the donor area of the graft showed satisfactory healing (Figure 3F and 3G). After 40 days of post-operative, the healing tissue was clinically observed and a decrease in the whitish area of the graft was noted suggesting better irrigation in the region (Figure 3H).

Figure 3- Free connective tissue graft and postoperative.

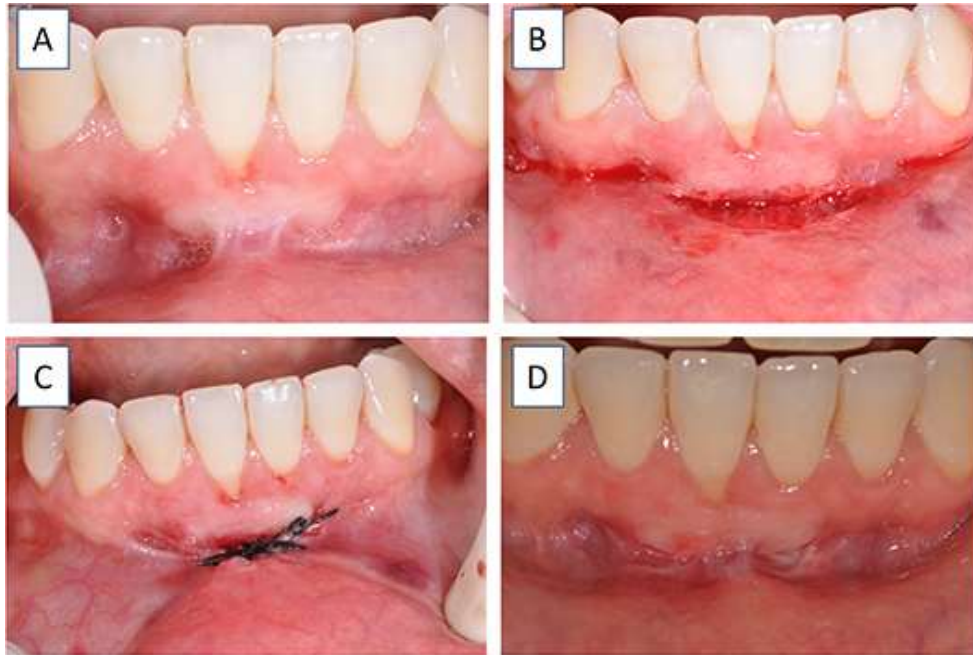


A) De-epithelialized graft, left with the portion of connective tissue and fatty tissue, with out the presence of epithelial tissue; B) Free connective tissue graft positioned in the recipient bed; C) Graft sutured in the recipient bed with simple and compressive suture; D) Blue@oral oral gel placed on the graft recipient bed, active oxygen bubbles can be seen in action; E) Oral Gel blue@oral placed on the graft donor bed, active oxygen bubbles can be seen in action; F) 10-day post operative period in the recipient area; G) 10-day post operative period of the donor; H) 40-day post operative period of the graft recipient area. Source: Authors

At 47 days, the lower lip frenulum had a small recurrence (Figure 4A), so a new intervention (Figure 4B) was necessary, as previously described in the first surgery, and simple sutures were performed (Figure 4C).

At 60 days, the patient showed excellent healing in the area of the free CTG, with gain of keratinized tissue and partial covering of the gingival recession (Figure 4D). The patient was followed up for 60 days and the results achieved were maintained, as well as the patient's total satisfaction regarding aesthetics and elimination of root hypersensitivity.

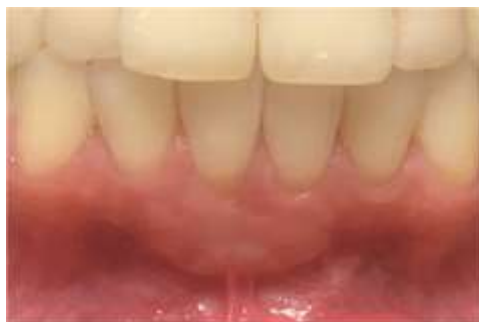Figure 4 - Postoperative of free connective tissue graft and new intervention for frenectomy.



A) 47 days post operative period of the first surgery, B) Frenectomy performed, C) Simple sutures in the área of the frenectomy, D) 60 days post operative period of the first surgery. Source: Authors.

At 280 days postoperatively, the patient returned for follow-up, and a considerable gain in keratinized tissue and almost the absence of color discrepancy between the graft's receiving area and the keratinized mucosa could be noted (Figure 5).

Figure 5 – Final result.



280 days after the first surgery a considerable gain in keratinized tissue and almost the absence of color discrepancy between the graft's receiving area and the keratinized mucosa. Source: Authors.

4. Discussion

Gingival recession causes discomfort and impairs the aesthetics of the patient. Root coverage should generate an increase the keratinized gingiva band (Yoshino *et al.*, 2020), eliminate dentin hypersensitivity (Eisenbud, 2012) and avoid the accumulation of plaque (Rasperini *et al.*, 2011; Zucchelli *et al.*, 2011; Mattos *et al.*, 2019; Yoshino *et al.*, 2020;).

The free gingival graft is one of the oldest techniques of gingival grafting, and its efficiency is proven in the long term, but the success of this graft depends on the transplanted connective tissue, its integration takes around 17 days showing a fibrous tissue that can differentiated from the receiving area (Cairo, 2017; Lafzi *et al.*, 2019), which is the main disadvantage of FGG in aesthetic areas. Due to this limitation, we opted to perform the free CTG. Looking at the post-operative follow-up photos of the present case, it is possible to observe that the whitish staining in the recipient bed was minimized but not eliminated. This is also a limitation of the free connective graft in this case report.

Subepithelial connective tissue grafts are considered one of the best methods for root coverage and also to increase the width and thickness of keratinized gums (Han *et al.*, 2008; Henriques *et al.*, 2010; Yadav *et al.*, 2018) with good predictability due to the blood supply coming from both the periosteum and the flap that covers the graft, thus preventing its necrosis (Yadav *et al.*, 2018). However, in the technique used in this clinical case, connective tissue was used as a technique for free gingival graft, anchored in the recipient bed, which is the only source of blood supply for the graft.

Oxygen plays an important role in wound healing. It is required, among others, for collagen deposition, epithelization, and angiogenesis, besides providing resistance to infections (Lafzi *et al.*, 2019). It has been demonstrated that topical application of a product that releases oxygen (blue@m) reduces the severity of inflammation *in vivo* (Eisenbud, 2012; Imano *et al.*, 2019). To aid healing and increase local angiogenesis, it was decided to daily apply the blue@m oral gel in the immediate postoperative period and until the sutures were removed, as well as to indicate the use of the blue@m mouthwash in order to minimize risk of necrosis of the free conjunctive graft. The free gingival graft has its epithelium coming from the palate which favors its predictability and decreases the chance of necrosis; however, it has a disadvantage, the discrepancy in color and texture in contrast to the recipient bed (Yoshino *et al.*, 2020).

As for the histological aspect, connective tissue cells are derived from mesenchymal cells, being pluripotent stem cells, however this connective tissue is an adult tissue that contains a small amount of these mesenchymal stem cells, being able to be transformed into fibroblasts, and myoblasts that contribute to tissue repair, in addition to the production of growth factors and cytokines, which influence the differentiation of other cells such as muscle and epithelial cells. When this technique is performed, the tissue tends to have a color and texture like keratinized mucosa due to the influence of the cells of the recipient site. Thus, the need to remove this epithelium, cells that had different coloring and texture from the donor site (palate) are removed, making the FCG become more aesthetic than the FGG (Montanari, 2016; Yoshino *et al.*, 2020).

The FGG de-epithelialization technique, with the removal of the epithelial portion, is already established in the literature (Mattos *et al.*, 2019) and was used in this case to perform the FCG. However, there is a chance of necrosis due to the removal of the epithelium, so we decided to apply products that have the release of active oxygen in their formulas. It is known that the presence of oxygen in wound healing is essential because it promotes increased cellular metabolism, increased collagen synthesis, increased antibacterial activity, promotes, and facilitates the release of growth factors, increases angiogenesis, and promotes revascularization (Eisenbud, 2012). Besides, its antimicrobial effects have also been demonstrated (Imano *et al.*, 2019).

As the active oxygen-releasing gel (blue@m) developed by dental surgeons from the Netherlands, helps in the healing and formation of keratinized tissue (Imano *et al.*, 2019).in the present case, in the technique of free connective tissue grafting, satisfactory healing was observed probably due to the angiogenic stimulus and the antibacterial effect of the blue@m products used. The clinical result shows absence of necrosis in the initial 10-day postoperative period. We suggest that the use of

products with active oxygen release this technique became a viable procedure, since other attempts had already been made by the same team and we were unsuccessful due to necrosis of the free conjunctive graft. In addition, a tissue of color and texture similar to the recipient bed was observed in the postoperative follow-up (Montanari, 2016; Imano *et al.*, 2019).

5. Conclusion

It is concluded that the technique of free connective graft performed, with the support of the gel and the mouthwash with the release of active oxygen (blue®m), has become a viable technique, preventing graft necrosis and achieving root coverage and keratinized tissue gain. New clinical trials and must be carried out to observe the effects of oxygen therapy on the technique of free connective tissue grafting

Acknowledgments

The authors declare there are no conflicts of interest.

References

- Araujo, N. J. de, Franco, L. B. R., Delanora, L. A., Barra, R. H. D., & Almeida, J. M. de. (2021). Utilização da Técnica de Enxerto Gengival Livre para reconstrução de tecido mole após excisão de um Fibroma Ossificante Periférico. *RSD* 10(2):e36710212622. <https://rsdjournal.org/index.php/rsd/article/view/126224>
- Cairo, F. (2017). Periodontal plastic surgery of gingival recessions at single and multiple teeth. *Periodontol* 2000, 75(1), 296-316
- Cortellini, P., & Bissada, N. F. (2018). Mucogingival conditions in the natural dentition: Narrative review, case definitions, and diagnostic considerations. *J Periodontol.*; 89 1:204-213. 10.1002/JPER.16-0671
- Eisenbud, D. E. (2012) Oxygen in wound healing: nutrient, antibiotic, signaling molecule, and therapeutic agent. *Clin Plast Surg.* 39(3):293-310. 10.1016/j.cps.2012.05.001
- Fernandes, T. C. de M., Sega, K. R., Costa, P. P., Ito, F. A. N., Maia, L. P., & Pedriali, M. B. B. P. (2021) Associação de retalho reposicionado coronário, proteína derivada da matriz do esmalte e enxerto de tecido conjuntivo subepitelial como tratamento de recessões gengivais múltiplas: Relato de caso. *RSD* 10(3):e17510313190. <https://rsdjournal.org/index.php/rsd/article/view/13190>
- Han, J. S., John, V., Blanchard, S. B., Kowolik, M. J., & Eckert, G. J. (2008). Changes in gingival dimensions following connective tissue grafts for root coverage: comparison of two procedures. *J Periodontol*, 79(8), 1346-1354.
- Henriques, P. S. G., Pelegrine, A. A., Nogueira, A. A., & Borghi, M. M. (2010). Application of subepithelial connective tissue graft with or without enamel matrix derivative for root coverage: a split-mouth randomized study. *J Oral Sci*, 52(3), 463-471
- Imano, M. H., Chaves, L. H., Storrer, C. L. M., Amaral, C. F., Candido, B. F., & Deliberador, T. M. (2019). Uso do Gel de Oxigênio como Otimizador da Cicatrização Tecidual em Áreas Doadoras e Receptoras na Técnica de Enxerto Gengival Livre. *IMPLANT NEWS PERIO*; 1: 1.
- Lafzi, A., Kadhodazadeh, M., Mojahedi, S. M., Amid, R., Shidfar, S., & Baghani, M. T. (2019). The Clinical Evaluation of the Effect of Low-Level Laser Therapy on the Donor and Recipient Sites of the Free Gingival Graft: A Case Series. *J Lasers MedSci*; 10(4):355-360. 10.15171/jlms.2019.58
- Mattos, P. M., Papalexou, V., Tramontina, V. A., Kim, S. H., Lucyszyn, S. M., Bettega, P. V. C. et al. (2019). Evaluation of 2 techniques of epithelial removal in subepithelial connective tissue graft surgery: a comparative histological study. *J Periodontal Implant Sci.* 50(1):2-13. 10.5051/jpis.2020.50.1.2
- Montanari, T. (2016). *Histologia: texto, atlas e roteiro de aulas práticas. (3a ed.)*, Ed. da autora. 229. <http://www.ufrgs.br/livrodehisto> ISBN: 978-85-915646-3-7
- Rasperini, G., Rocuzzo, M., Francetti, L., Acunzo, R., Consonni, D., & Silvestri, M. (2011). Subepithelial connective tissue graft for treatment of gingival recessions with and without enamel matrix derivative: a multicenter, randomized controlled clinical trial. *Int J Periodontics Restorative Dent*, 31(2), 133-139.
- Sculean, A., Cosgarea, R., Stahli, A., Katsaro, C., Arweiler, N. B., Brex, M., & Deppe, H. (2014). The modified coronally advanced tunnel combined with an enamel matrix derivative and subepithelial connective tissue graft for the treatment of a isolated mandibular Miller Class I and II gingival recession: a report of 16 cases. *Quintessence Int*, 45(10), 829-835
- Storrer, C. L. M., Muller, L. L., Pissai, J. F., Andrade, C. F., Trevisani, C. R. T., & Deliberador, T. M. (2019) Treatment of Miller Class I Gingival Recession with Using Non pedicle Adipose Tissue after Bichotomy Surgical Technique: A Case Report. *Case Rep Dent*: 1049453. 10.1155/2019/1049453
- Thoma, D. S., Gasser, T. J. W., Jung, R. E., & Hämmerle, C. H. F. (2020) Randomized controlled clinical trial comparing implant sites augmented with a volume-stable collagen matrix or an autogenous connective tissue graft: 3-year data after insertion of reconstructions. *J Clin Periodontol.* 47(5):630-639. 10.1111/jcpe.13271

Yadav, A. P., Kulloli, A., Shetty, S., Ligade, S. S., Martande, S. S., & Gholkar, M. J. (2018). Sub-epithelial connective tissue graft for the management of Miller's class I and class II isolated gingival recession defect: A systematic review of the factors influencing the outcome. *J Investig Clin Dent*. 9(3):e12325. 10.1002/JPER.16-0671

Yoshino, H., Hasuike, A., Sanjo, N., Daisuke, S., Tatesuya, K., Hidekazu, N., et al. (2020). CO₂ Laser De-epithelization Technique for Subepithelial Connective Tissue Graft: A Study of 21 Recessions. *In Vivo*. 34(2):869-875. 10.21873/invivo.11851

Zucchelli, G., & De Sanctis, M. (2000). Treatment of multiple recession-type defects in patients with esthetic demands. *J Periodontol*. 71(9), 1506-1514.

Zucchelli, G., Gori, G., Mele, M., Stefanini, M., Mazzotti, C., Marzadori, M., Montebugnoli, L., & De Sanctis, M. (2011). Non-carious cervical lesions associated with gingival recessions: a decision-making progress. *J Periodontol*. 82(12), 1713-1724

Zucchelli, G., & Mounssif, I. (2015). Periodontal plastic surgery. *Periodontol 2000*, 68(1), 333-368.

Zucchelli, G., Testori, T., & De Sanctis, M. (2006). Clinical and anatomical factors limiting treatment outcomes of gingival recession: a new method to predetermine the line of root coverage. *J Periodontol*. 77(4), 714-721.