

Peripheral odontogenic myxoma: Clinical case with a literature review

Mixoma odontogênico periférico: Caso clínico com revisão de literatura

Myxoma odontogênico periférico: Caso clínico con revisión de literatura

Received: 05/05/2021 | Reviewed: 05/10/2021 | Accept: 05/12/2021 | Published: 05/29/2021

Carlos Eduardo Nogueira Nunes

ORCID: <https://orcid.org/0000-0003-4223-4633>

Federal University of Ceará, Brazil

Email: caduunogueiraa@gmail.com

Anne Diolina Araújo Morais

ORCID: <https://orcid.org/0000-0002-7208-5520>

Federal University of Ceará, Brazil

E-mail: annemorais85@gmail.com

João Victor Morais de Lima

ORCID: <https://orcid.org/0000-0002-5682-934X>

Federal University of Ceará, Brazil

E-mail: joaovictormorais98@gmail.com

Filipe Nobre Chaves

ORCID: <https://orcid.org/0000-0001-6345-8156>

Federal University of Ceará, Brazil

E-mail: filipenobrechaves@gmail.com

Marcelo Bonifácio da Silva Sampieri

ORCID: <https://orcid.org/0000-0001-7942-6642>

Federal University of Ceará, Brazil

E-mail: mar_sampieri@hotmail.com

Denise Hélen Imaculada Pereira de Oliveira

ORCID: <https://orcid.org/0000-0001-6020-2374>

Federal University of Ceará, Brazil

E-mail: denise.oliveira@sobral.ufc.br

Abstract

Peripheral odontogenic myxoma (POM) is a rare and extra-osseous variant of odontogenic myxoma (OM), classified as a relatively rare benign odontogenic tumor, yet presenting locally aggressive behavior. The objective this manuscript is to report a case of POM in a 75-year-old patient, located in the right maxilla, and in addition, to perform a literature review of the data in relation to clinical, radiographic aspects, hypothesis of diagnosis, and treatment. A male patient, 75 years old, clinical examination constatct the presence of a nodule, with a smooth surface, on the right upper alveolar ridge, measuring 20 x 25 mm, with a color similar to the mucosa, a softened consistency, involving teeth 14 and 15, and with an undetermined time of evolution was observed. The diagnostic hypothesis was a peripheral ossifying fibroma and differential diagnosis of peripheral giant cell lesion. An excisional biopsy was performed together with extraction of the involved teeth. Histopathological examination and histochemical reaction was confirm the histopathological diagnosis of POM. The reported case is extremely rare due to the clinical presentation of the lesion, causing bone resorption with tooth mobility. In addition, the age range of involvement is very different from that presented in the literature, between the second and fourth decade of life. The final diagnosis was very important, as it is a lesion with a great potential for recurrence, long-term follow-up should be more careful, and in case of recurrence, a new intervention must be performed.

Keywords: Odontogenic myxoma; Oral pathology; Dentistry; Oral cavity.

Resumo

O mixoma odontogênico periférico (OMP) é uma variante rara e extra-óssea do mixoma odontogênico (OM), classificado como tumor odontogênico benigno relativamente raro, porém apresentando comportamento localmente agressivo. O objetivo deste manuscrito é relatar um caso de OMP em paciente de 75 anos, localizada em maxila direita, e, além disso, realizar uma revisão bibliográfica dos dados em relação aos aspectos clínicos, radiográficos, hipótese de diagnóstico e tratamento. Paciente do sexo masculino, 75 anos, ao exame clínico constatou-se a presença de nódulo, de superfície lisa, no rebordo alveolar superior direito, medindo 20 x 25 mm, de coloração semelhante à mucosa, consistência amolecida. envolvendo os dentes 14 e 15, e com tempo de evolução indeterminado. A hipótese diagnóstica foi de fibroma ossificante periférico e diagnóstico diferencial de lesão periférica de células gigantes. Uma biópsia excisional foi realizada juntamente com a exodontia dos dentes envolvidos. O exame histopatológico e a reação histoquímica confirmaram o diagnóstico histopatológico de POM. O caso relatado é extremamente raro devido à apresentação clínica da lesão, causando reabsorção óssea com mobilidade dentária. Além disso, a faixa etária de acometimento é muito diferente da apresentada na literatura, entre a segunda e a quarta década de vida. O diagnóstico final foi muito importante, por se tratar de uma lesão com grande potencial de recidiva, o seguimento em longo prazo deve ser mais cuidadoso e, em caso de recidiva, nova intervenção deve ser realizada.

Palavras-chave: Mixoma odontogénico; Patologia oral; Odontología; Cavidade oral.

Resumen

El mixoma odontogénico periférico (MO) es una variante rara y extraósea del mixoma odontogénico (MO), clasificado como un tumor odontogénico benigno relativamente raro, pero que presenta un comportamiento localmente agresivo. Objetivo de este manuscrito es reportar un caso de POM en un paciente de 75 años, localizado en el maxilar derecho, y además, realizar una revisión de la literatura de los datos en relación a aspectos clínicos, radiográficos, hipótesis de diagnóstico y tratamiento. Paciente de sexo masculino, 75 años, al examen clínico se constata la presencia de un nódulo, de superficie lisa, en el reborde alveolar superior derecho, de 20 x 25 mm, de color similar a la mucosa, consistencia blanda, involucrando los dientes 14 y 15, y con un tiempo de evolución indeterminado. La hipótesis diagnóstica fue un fibroma osificante periférico y diagnóstico diferencial de lesión periférica de células gigantes. Se realizó biopsia excisional junto con extracción de los dientes afectados. El examen histopatológico y la reacción histoquímica confirmaron el diagnóstico histopatológico de POM. El caso reportado es extremadamente raro debido a la presentación clínica de la lesión, provocando reabsorción ósea con movilidad dentaria. Además, el rango de edad de afectación es muy diferente al presentado en la literatura, entre la segunda y la cuarta década de la vida. El diagnóstico final fue muy importante, ya que se trata de una lesión con un gran potencial de recidiva, el seguimiento a largo plazo debe ser más cuidadoso y en caso de recidiva se debe realizar una nueva intervención.

Palabras clave: Mixoma odontogénico; Patología buccal; Odontología; Cavidad bucal.

1. Introduction

Odontogenic myxoma (OM) is an unusual, slow growth, benign mesenchymal tumor, locally invasive, and classified as an odontogenic tumor due to the great histological similarity that it presents with the odontogenic ectomesenchyme (Dotta et al, 2020; Francisco et al, 2016; Kawase-Koga et al, 2014; Leiser et al, 2009). This is in addition to its location in areas of tooth support in the maxillary bones, and its occasional association with missing or unbroken teeth (Oliveira et al, 2018; Raubenheimer et al, 2012; Aytac-Yazicioglu et al, 2008; Kapoor et al, 2015). OMs are classified into two variants: central odontogenic myxoma, (the most commonly found), and peripheral odontogenic myxoma (POM) (Aytac-Yazicioglu et al, 2008; Tasnime et al, 2016; Singh et al, 2013).

POM is considered a rare variation of OM, with few cases present in the literature, it is characterized as less aggressive in terms of local infiltration, and also presents a lower recurrence rate (Raubenheimer et al, 2012; Aytac-Yazicioglu et al, 2008; Kapoor et al, 2015). Some theories argue that it forms through the action of altered fibroblasts and myofibroblasts, considered capable of producing excess muco-polysaccharides yet generally unable to form mature collagen (Aytac-Yazicioglu et al, 2008; Perrotti et al, 2006). However, there is no consensus in the literature as to the formation of this OM subtype (Aytac-Yazicioglu et al, 2008; Perrotti et al, 2006; Chrcanovic & Gomez, 2019).

Currently, there is little data in the literature that compare POMs to central odontogenic myxomas, however, some studies argue that these lesions have a predilection for males and are usually located on the hard palate, parotid region, jugal mucosa, or mouth floor (Perrotti et al, 2006; Shimoyama et al, 2000; Elzay et al, 1978; Singh et al, 2013; Chrcanovic & Gomez, 2019).

Due to the wide spectrum of soft tissue injuries described in the literature with similarity to POM clinical characteristics, diagnosis of this tumor is a major challenge (Kanitkar et al, 2017). A definitive diagnosis and appropriate treatment can only be formulated when clinical, histological, and radiographic components are combined (Dotta et al, 2020; Kanitkar et al, 2017). The objective of this work is to report a rare clinical case of a POM, while conducting a comprehensive review of the cases reported in the literature.

2. Methodology

This article focuses on the search for a practical answer for healthcare professionals on how to deal with cases of rare oral lesions that are difficult to diagnose and with varied therapeutic possibilities. This article is a clinical case report and

literature review with both a qualitative and descriptive approach. According to Estrela et al. (2018), such a study is characterized as a research in which direct data collection occurs, with the researcher being the primary instrument. This study was legally supported by an Informed Consent Form (TCLE) from the Federal University of Ceará - Campus Sobral. Stomatology Sector.

The literature review was carried out, with no date restrictions until December 2019, in the PubMed / Medline database. The terms used were: “peripheral myxoma” and “oral”. The inclusion criteria were: 1. Case report or series of cases of POM containing complete information on the clinical and histopathological aspects, and 2. a series of cases of odontogenic tumor, reporting at least one case of POM properly characterized. The exclusion criteria were: 1. Animal studies and literature reviews; 2. POM articles with a different focus than the one mentioned in the inclusion criteria; 3. hybrid tumors partially composed of a POM, (which may behave differently); and 4. any language other than English.

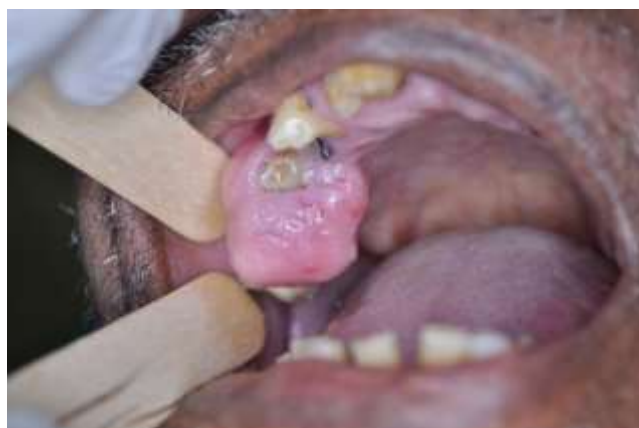The focus made only on the peripheral myxoma variant, which is considered rare, greatly reduced our findings compared to other similar reviews that addressed the myxoma entirely (Dotta et al, 2020).

The review resulted in a total of 42 titles / abstracts, with 11 meeting the inclusion criteria. Of the 11 articles selected for review, nine were clinical case reports and two involved more than one clinical case (two cases and four cases), totaling 15 cases diagnosed with PMD. The information was compiled into a spreadsheet by one reviewer and verified by a second reviewer.

3. Case Description

Male patient, 75 years old, paraplegic, sought the stomatology service complaining of painless maxillary edema. We emphasize that during anamnesis and filling out the dental record, the patient was informed that the service environment was a dental teaching school and that his case would be the object of study, signing a free and informed consent form (ICF). On clinical examination, the presence of a nodule, with a smooth surface, was found in the upper right alveolar crest, measuring 20 x 25 mm, with a color similar to the mucosa, with a soft consistency, involving teeth 14 and 15 (Figure 1), and with an indefinite evolution time.

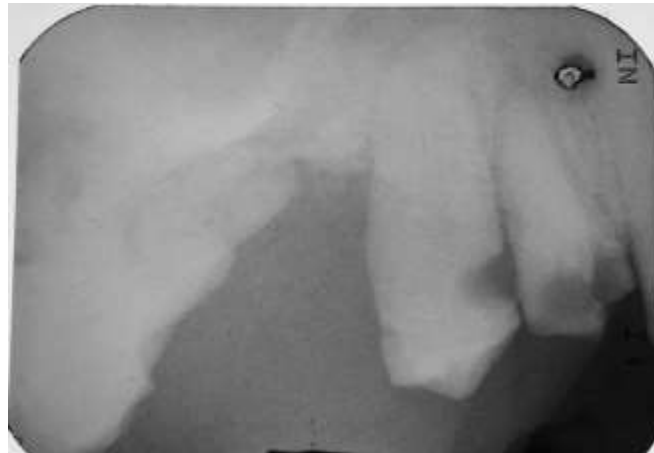Figure 1 - Presence of a smooth surface nodule in the upper right alveolar crest, measuring 20 x 25 mm, mucosa-like in color, soft in consistency, involving teeth 14 and 15.



Source: Authors.

The patient reported the absence of any previous surgical procedure in the area involved, and no symptoms or systemic comorbidity. Image examination revealed that the lesion generated irregular bone resorption involving teeth 14 and 15, which presented mobility, however the lesion did not present intraosseous involvement (Figure 2).

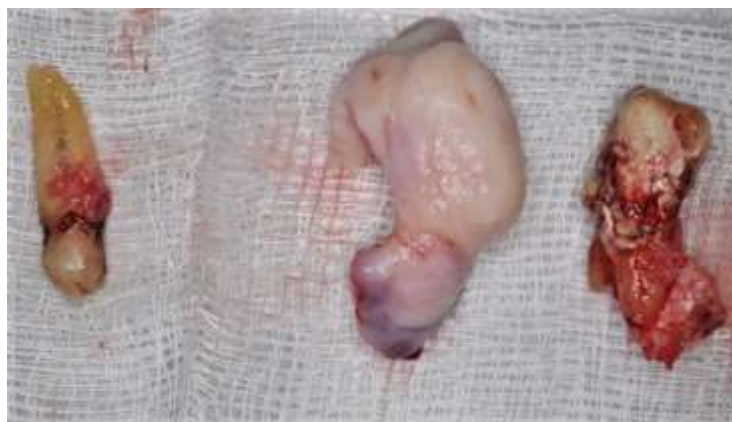Figure 2 - periapical radiography showing that the lesion caused irregular bone resorption involving teeth 14 and 15 that had mobility.



Source: Authors.

The diagnostic hypothesis was a peripheral ossifying fibroma and differential diagnosis of peripheral giant cell lesion. An excisional biopsy was performed together with extraction of the involved teeth (Figure 3).

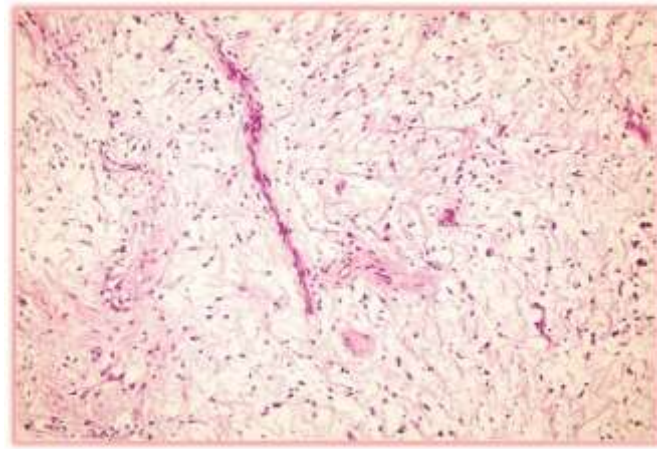
Figure 3 - fragment of complete lesion and teeth 14 and 15 after performing a surgical procedure (excisional biopsy + extractions) performed in an outpatient setting.



Source: Authors.

Histopathological examination revealed large mesenchymal cells, fusiform and ovoid nuclei with basophilic cytoplasmic projections in the middle of the myxoid matrix, permeated by fibrous areas (Figure 4). The Alcian-blue histochemical reaction was positive for myxoid material, indicating the presence of acid glycosaminoglycans in the myxoid stroma, confirming the histopathological diagnosis of POM. Additional immunohistochemical analysis revealed immunopositivity for vimentin, corroborating a probable mesenchymal origin for POM.

Figure 4 - Histological image revealing the presence of large mesenchymal cells, with fusiform and ovoid nuclei with basophilic cytoplasmic projections in the middle of the myxoid matrix, permeated by fibrous areas.



Source: Authors.

4. Results and Discussion

The present study investigated the clinical-pathological aspects of POM as reported in the literature. The small number of reviewed cases is present in Table 1 and may suggest that it is a rare lesion.

In general, a slight predominance of females was observed. However, previous studies report a predilection for males (Aytac-Yazicioglu et al, 2008; Elzay et al, 1978; Tse & Vander, 1985). Most patients by age of involvement were between the second and fourth decade of life. This is in line with part of the literature, which reported occurrences in a younger population, between the second and fourth decade of life (Jain et al, 2013; Dotta et al, 2020). However, according to the literature, the age group most affected is between the fourth and sixth decades of life (Aytac-Yazicioglu et al, 2008; Kapoor et al, 2015; Kanitkar et al, 2017; Chrcanovic & Gomez, 2019). In the current case report, representing an older patient with a POM, a 75-year-old male patient was affected.

Due to the low number of cases of POM being reported in the literature, the oral region most affected by this lesion was not established by the authors. However, in this review, it was evidenced that the most common location in the 16 reported cases was the anterior region of the mandible, followed by the anterior region of the maxilla. As in the current report, Yazicioglu, Eren and Görgün in 2008 reported a case located in the posterior maxilla gingiva; and have also affirmed that myxomas located in the gingiva have an odontogenic origin and thus, cannot be classified as soft tissue myxomas (Aytac-Yazicioglu et al, 2008).

In the literature, other regions are also mentioned, such as the hard palate, the jugal mucosa, and the infra-temporal space (Kapoor et al, 2015; Elzay et al, 1978). POM, when presenting bone destruction tends to occur in elderly patients, yet less often in males (Miettinen et al, 1985; Hill et al, 1990). In addition, cases presenting bone destruction grow more rapidly when compared to those without bone destruction (Miettinen et al, 1985; Hill et al, 1990). The current case proved to be associated with an area of bone resorption involving teeth 14 and 15, which presented mobility.

Due to its rarity, clinical diagnosis of this type of lesion is unlikely to arrive at an initial diagnostic hypothesis of POM. Normally the lesion is initially diagnosed as a peripheral lesion of giant cells, peripheral ossifying fibroma, traumatic fibroma and lesions originating from minor salivary glands (Aytac-Yazicioglu et al, 2008; Tasnime et al, 2016; Perrotti et al, 2006; Shimoyama et al, 2000; Elzay et al, 1978; Kanitkar et al, 2017; Shenoy et al, 2014). This happened in the present case, where these were also the diagnostic hypotheses given, based on the clinical and radiographic appearance. Histopathological examination was necessary to confirm that it was a POM, where it was possible to observe a neoplasm of odontogenic origin

made up of randomly arranged stellate, spindle-shaped, and round cells in a myxoid stroma (Leiser et al, 2009).

Table 1 - Review results (epidemiological data, location, treatment and recurrence of injuries).

AUTHOR/YEAR/NUMBER OF PATIENTS	SEX/AGE	LOCATION	TREATMENT	FOLLOW-UP/RELAPSES
Una Datar/2017/1	F/12	Anterior mandible	Surgical excision and curettage	2 years/none
Tasmine/2016/1	F/14	Anterior maxilla	Surgical excision, curettage and osteotomy	
Reddy/2013/1	F/41	Anterior maxilla	Simple surgical excision	6 months/none
Desai/2015/1	M/11	Infra-temporal space	Surgical excision with free margins	2 years/none
Görgün/2008/1	F/41	Posterior maxilla	Simple surgical excision and extraction of associated tooth	1 year/none
Rao/2014/1	M/22	Posterior mandible	Surgical excision with free margins	
Piattelli/2006/1	M/42	Anterior maxilla	Simple surgical excision	4 years/none
Sah S P/2001/1	F/35	Posterior maxilla	Surgical excision with free margins	1 year/none
Ide/2000/1	M/51	Anterior mandible	Surgical excision and curettage	
Noffke/2012/2	F/53	Anterior mandible	Simple surgical excision	7 years/none
	F/38	Anterior mandible	Simple surgical excision	
Richmond/1978/4	F/35	Hard palate	Simple surgical excision	13 years/none
	M/39	Jugal mucosa	Simple surgical excision	1 year/none
	M/48		Simple surgical excision	3 years/none
	F/28	Posterior mandible	Simple surgical excision	3 years/none

Source: Authors.

Sometimes, in the face of a rare lesion, immunohistochemical analysis is performed to confirm the origin of the tumor cells. In the case of POM, the origin is myofibroblastic and histiocytic (Jain et al, 2013). Thus, in many studies, the immunohistochemical marker vimentin is the most used to confirm a myofibroblastic and histiocytic origin (Raubenheimer et al, 2012; Perrotti et al, 2006; Kanitkar et al, 2017). In addition to immunohistochemical analysis with vimentin, Tasmine et al., 2016 also performed histochemical analysis, (as in the present case) via Alcian-blue staining, which indicates the presence of acidic glycosaminoglycans in the myxoid stroma, confirming a histopathological diagnosis of POM.

Due to their low recurrence rates, intraoral approaches such as enucleation and curettage, have been described as an effective treatment procedure for POM (Perrotti et al, 2006; Shenoy et al, 2014). According to the literature, in current research, and in the present case as well, the most commonly performed treatment is simple surgical excision. However, the effectiveness of this type of treatment in the reported cases cannot be taken for granted, since sometimes follow-up is problematic (as was observed in these articles). Thus, whichever treatment is chosen, monitoring/patient follow-up is of fundamental importance in cases where the histopathological report reveals a POM (Perrotti et al, 2006; Kanitkar et al, 2017).

Upon reaching the diagnosis of OMP, the patient's treatment must be individualized taking into account the specific characteristics of the patient's injury (Francisco et al, 2016; Leiser et al, 2009). However, conservative treatment techniques are preferable compared to more aggressive techniques, as the potential for recurrence in surgical modalities is similar (Dotta et al, 2020). In addition, conservative techniques have advantages such as being less invasive, more economical and shorter hospital

stay (Kawase-Koga et al, 2014). Thus, monitoring the patient to avoid possible relapses is more important than using aggressive techniques that cause marked morbidity and decrease in the patient's quality of life.

5. Conclusion

The final diagnosis was very important, as it is a lesion with great potential for recurrence, long-term follow-up should be more careful and, in case of recurrence, a new intervention should be performed.

New case reports should be published whenever professionals are faced with rare cases like this, demonstrating their conduct so that other professionals acquire this experience and know how to deal when they also come across cases like this.

In the near future, with a satisfactory number of reports and long-term follow-up, it is possible to carry out a systematic quality review in order to clarify exactly what is the best approach for rare injuries like this.

References

- Aytac-Yazicioglu, D., Eren, H., & Görgün, S. (2008). Peripheral odontogenic myxoma located on the maxillary gingiva: Report of a case and review of the literature. *Oral and Maxillofacial Surgery*, 12(3), 167–171. <https://doi.org/10.1007/s10006-008-0122-8>.
- Chrcanovic, B. R., & Gomez, R. S. (2019). Odontogenic myxoma: An updated analysis of 1,692 cases reported in the literature. *Oral Diseases*, 25(3), 676–683. <https://doi.org/10.1111/odi.12875>
- Dotta, J. H., Miotto, L. N., Spin-Neto, R., & Ferrisse, T. M. (2020). Odontogenic Myxoma: Systematic review and bias analysis. *European Journal of Clinical Investigation*, 50(4), 1–14. <https://doi.org/10.1111/eci.13214>.
- Elzay, R. P., & Dutz, W. (1978). Myxomas of the paraoral-oral soft tissues. *Oral Surgery, Oral Medicine, Oral Pathology*, 45(2), 246–254. [https://doi.org/10.1016/0030-4220\(78\)90091-9](https://doi.org/10.1016/0030-4220(78)90091-9).
- Estrela, C (2018). *Metodologia científica: ciência, Ensino, pesquisa. 3 ed. Porto Alegre-RS: Artes Médicas*, v. 1. 707p.
- Francisco, A. L. N., Chulam, T. C., Silva, F. O., Ribeiro, D. G., Pinto, C. A. L., Gondak, R. O., Kowalski, L. P., & Gonçalves-Filho, J. (2017). Clinicopathologic analysis of 14 cases of odontogenic myxoma and review of the literature. *Journal of Clinical and Experimental Dentistry*, 9(4), e560–e563. <https://doi.org/10.4317/jced.52953>.
- Hill, T. L., Jones, B. E., & Park, K. H. (1990). Myxoma of the skin of a finger. *Journal of the American Academy of Dermatology*, 22(2), 343–345. [https://doi.org/10.1016/0190-9622\(90\)70044-I](https://doi.org/10.1016/0190-9622(90)70044-I).
- Jain, V. K., & Reddy, S. N. (2013). Peripheral odontogenic myxoma of maxillary gingiva: A rare clinical entity. *Journal of Indian Society of Periodontology*, 17(5), 653–656. <https://doi.org/10.4103/0972-124X.119287>.
- Kanitkar, S., Kamat, M., Tamagond, S., Varekar, A., & Datar, U. (2017). Peripheral odontogenic myxoma in a 12-year-old girl: A rare entity. *Journal of the Korean Association of Oral and Maxillofacial Surgeons*, 43(3), 178–181. <https://doi.org/10.5125/jkaoms.2017.43.3.178>.
- Kapoor, P., Gandhewar, T. M., Andrade, N. N., & Desai, R. S. (2015). Peripheral myxoma of the infratemporal region: An unusual case report. *Journal of Oral Biology and Craniofacial Research*, 5(3), 232–235. <https://doi.org/10.1016/j.jobcr.2015.07.004>.
- Kawase-Koga, Y., Saijo, H., Hoshi, K., Takato, T., & Mori, Y. (2014). Surgical management of odontogenic myxoma: A case report and review of the literature. *BMC Research Notes*, 7(1), 1–7. <https://doi.org/10.1186/1756-0500-7-214>.
- Leiser, Y., Abu-El-Naaj, I., & Peled, M. (2009). Odontogenic myxoma - A case series and review of the surgical management. *Journal of Cranio-Maxillofacial Surgery*, 37(4), 206–209. <https://doi.org/10.1016/j.jcms.2008.10.001>.
- Miettinen, M., Hockerstedt, K., Reitamo, J., & Totterman, S. (1985). Intramuscular myxoma - A clinicopathological study of twenty-three cases. *American Journal of Clinical Pathology*, 84(3), 265–272. <https://doi.org/10.1093/ajcp/84.3.265>.
- Oliveira, S. V., Rocha, A. C., Cecchetti, M. M., Gallo, C. de B., & Alves, F. A. (2018). Odontogenic Myxoma in a Child treated with enucleation and curettage. *Autopsy and Case Reports*, 8(3). <https://doi.org/10.4322/acr.2018.042>.
- Perrotti, V., Rubini, C., Fioroni, M., & Piattelli, A. (2006). Soft tissue myxoma: Report of an unusual case located on the gingiva. *Journal of Clinical Periodontology*, 33(1), 76–78. <https://doi.org/10.1111/j.1600-051X.2005.00837.x>
- Raubenheimer, E. J., & Noffke, C. E. (2012). Peripheral Odontogenic Myxoma: A Review of the Literature and Report of Two Cases. *Journal of Maxillofacial and Oral Surgery*, 11(1), 101–104. <https://doi.org/10.1007/s12663-011-0194-0>
- Shenoy, V. S., Rao, R. A., Prasad, V., Kamath, P. M., & Rao, K. S. (2014). Soft tissue myxoma- a rare differential diagnosis of localized oral cavity lesions. *Journal of Clinical and Diagnostic Research*, 8(12), KD01–KD02. <https://doi.org/10.7860/JCDR/2014/10189.5288>.
- Shimoyama, T., Horie, N., Kato, T., Tojo, T., Nasu, D., Kaneko, T., & Ide, F. (2000). Soft tissue myxoma of the gingiva: report of a case and review of the literature of soft tissue myxoma in the oral region. *Journal of Oral Science*, 42(2), 107–109. <https://doi.org/10.2334/josnusd.42.107>.

Singh, P., & Davies, H. T. (2013). An ectopic tooth concealing an odontogenic myxoma. *Dental Update*, 40(1), 32–35. <https://doi.org/10.12968/denu.2013.40.1.32>.

Tasnime, S., Saxena, C., Bansal, V., & Wadhwan, V. (2016). Peripheral odontogenic myxoma. *Indian Journal of Dental Research*, 27(4), 437–440. <https://doi.org/10.4103/0970-9290.191896>.

Tse J. J., & Vander S. (1985). The soft tissue myxoma of the head and neck region--report of a case and literature review. *Head Neck Surg*. 7(6):479-483. doi:10.1002/hed.2890070608.