

Imaging protocols for the autopsy service in a time of pandemic emergency minimizing the contagion of SARS-CoV-2 expert government agents

**Protocolos de imagem para o serviço de autópsia em momento de emergência pandêmica
minimizando o contágio dos agentes do governo de perícia por SARS-CoV-2**

**Protocolos de imágenes para el servicio de autopsias em un momento de emergencia pandémica
minimizando el contagio de agentes gubernamentales expertos en SARS-CoV-2**

Received: 05/07/2021 | Reviewed: 05/012/2021 | Accept: 05/14/2021 | Published: 05/30/2021

Antonio Silvestre Figueiredo dos Santos

ORCID: <https://orcid.org/0000-0002-5952-2511>

Catholic University of Salvador, Brazil

E-mail: silvestresmilhao@gmail.com

Richard Siqueira Dias

ORCID: <https://orcid.org/0000-0002-0987-6573>

Institute of Judicial Expertise and Criminal Sciences, Brazil

E-mail: tr.richardsdias@gmail.com

Wendell da Luz Silva

ORCID: <https://orcid.org/0000-0002-7261-3100>

Brazilian Society of Forensic Sciences, Brazil

E-mail: wendell.luz@gmail.com

Abstract

Objective: To contribute to the construction of parameters of biosafety in order to protect government agents in the exercise of their investigative functions in the context of a pandemic, as well as to resolve clinical, pathological and possibly legal issues. *Methodology:* The development of an exploratory review study with a qualitative approach was defined. The methodological design was carried out on the platforms: PubMed and SciELO through the descriptors: Human identification, Radiology, Virtópsia and Autopsy. The exclusion criteria include articles with duplicate information or that do not have information related to the objectives of the study. For inclusion, materials published in Portuguese, English or Spanish were used and at the end 76 articles were obtained. *Results and discussion:* Conventional autopsy is the most common method for post-mortem investigation in humans. However, with the evolution of imaging methods and the current pandemic threatening the health of government agents, Virtópsia has shown itself to be the most promising way to remedy the dichotomy of occupational risk and legal benefit. *Final considerations:* In this article, the main advances in Forensic Radiology in the last 11 years were described, with regard to the use of ante and post mortem radiographs in the identification process. Among the various radiological techniques treated, the following stand out: radiographic techniques produced by radiology professionals with different assessments in the radiological area. The images produced are security methods with invasive manipulation and use of all PPE, suitable for the pandemic moment.

Keywords: Forensic anthropology; Radiology; Autopsy; SARS-CoV-2.

Resumo

Objetivo: Contribuir para a construção de parâmetros de biossegurança de forma a proteger os agentes do governo no exercício das suas funções investigativas em contexto de pandemia, bem como, resolver questões clínicas, patológicas e eventualmente jurídicas. *Metodologia:* Definiu-se o desenvolvimento de um estudo de revisão exploratório com abordagem qualitativa. O desenho metodológico foi realizado nas plataformas: PubMed e SciELO por meio dos descritores: Identificação humana, Radiologia, Virtópsia e Autópsia. Os critérios de exclusão abrangem artigos com informações duplicadas ou que não possuem informações relacionadas aos objetivos do estudo. Para inclusão, foram utilizados materiais publicados em português, inglês ou espanhol e ao final obteve-se 76 artigos. *Resultados e discussão:* A autópsia convencional representa o método mais comum para investigação post-mortem em humanos. Porém, com a evolução dos métodos de imagem e a atual pandemia de ameaça à saúde dos agentes dos governos, a Virtópsia tem se mostrado a forma mais promissora de remediar a dicotomia risco ocupacional e benefício jurídico. *Considerações finais:* Neste artigo, foram descritos os principais avanços da Radiologia Forense, nos últimos 11 anos, no que diz respeito ao uso de radiografias ante e post mortem no processo de identificação. Dentre as diversas técnicas radiológicas tratadas, destacam-se: técnicas radiográficas produzidas por profissionais de radiologia com diferentes

avaliações na área radiológica. As imagens produzidas são métodos de segurança com manipulação invasiva e utilização de todos os EPIs, adequados ao momento pandêmico.

Palavras-chave: Antropologia forense; Radiologia; Autópsia; SARS-CoV-2.

Resumen

Objetivo: Contribuir a la construcción de parámetros de bioseguridad a fin de proteger a los agentes gubernamentales en el ejercicio de sus funciones investigativas en el contexto de una pandemia, así como resolver cuestiones clínicas, patológicas y posiblemente legales. *Metodología:* Se definió el desarrollo de un estudio exploratorio de revisión con enfoque cualitativo. El diseño metodológico se realizó en las plataformas: PubMed y SciELO a través de los descriptores: Identificación humana, Radiología, Virtópsia y Autopsia. Los criterios de exclusión incluyen artículos con información duplicada o que no tengan información relacionada con los objetivos del estudio. Para su inclusión se utilizaron materiales publicados en portugués, inglés o español y al final se obtuvieron 76 artículos. *Resultados y discusión:* La autopsia convencional representa el método más común para la investigación post-mortem en humanos. Sin embargo, con la evolución de los métodos de imagen y la actual pandemia que amenaza la salud de los agentes gubernamentales, Virtópsia se ha mostrado como la forma más prometedora de remediar la dicotomía de riesgo ocupacional y beneficio legal. *Consideraciones finales:* En este artículo se describen los principales avances en Radiología Forense en los últimos 11 años, en cuanto al uso de radiografías ante y post mortem en el proceso de identificación. Entre las diversas técnicas radiológicas tratadas destacan: las técnicas radiográficas producidas por profesionales de la radiología con diferentes valoraciones en el área radiológica. Las imágenes producidas son métodos de seguridad con manipulación invasiva y uso de todos los EPP, adecuados para el momento pandémico.

Palabras clave: Antropología forense; Radiología; Autopsia; SARS-CoV-2.

1. Introduction

In December 2019, the World Health Organization (WHO) reports an outbreak of pneumonia, for reasons initially unknown, in the city of Wuhan, capital of the province of Hubei-China. On January 7, 2020, Chinese scientists isolated a new coronavirus, with symptoms of severe acute respiratory syndrome (Htun et al., 2021; Hui et al., 2021).

Between the months of January 2020 and January 2021, the pandemic has already affected almost one hundred million people and caused the death of around one million worldwide. In view of the high number of deaths, governments do not have biosafety protocols for the proper management of cadavers for the purpose of identification, establishment of the underlying or contributory disease for death (Garrido & Almeida 2020; Jabal et al., 2021).

Those killed by COVID-19 are not classified as violent death, as a rule they do not need to be referred to the Institute of Forensic Medicine. That is, the health authorities are responsible for handling it, and they must provide their employees with adequate training and stay in removing and fighting the proliferation of the virus. However, Death Verification Services (SVO), triggered in cases where the attending physician was unable to declare the cause of death and, in an emergency manner, IMLs are being used (Finegan et al., 2020; Da Silva et al., 2020).

It cannot be omitted that within the national and international recommendations on combating the proliferation of the virus, it includes the minimization of the handling of cadavers, which includes the considerable decrease or even the non-performance of autopsies in this epidemic context. In the case of contaminated corpses, external examinations must be adopted: anthropometric, thanatological and traumatological, by means of photographs of the entire body and their eventual reconstitution by computer (in the places where these tools exist) (De Lima & Júnio, 2020; Rabay et al., 2020). In addition to internal examinations: x-rays and computed tomography and the removal of tissue, blood and secretions samples by guided biopsy or by means of puncture and aspiration. Other imaging options that can be used within the identification of cadavers is the method of intraoral radiography, extra oral (dental radiology) and intraoral scanning, today used as a digital possibility that is used to replace the plaster model of the dental arch of living beings (Hartmann, 2020).

SARS-CoV-2, on the aspects of biosafety, is a pathogen belonging to the same risk group as the agents that cause HIV-AIDS and tuberculosis. Normally, infectious causes are not of medical-legal interest, but SARS-CoV-2 has high mortality rates and its symptoms, in some cases, are mild, which causes the concern of victims of violent death to be carriers of the virus. This is the greatest justification for knowing the national and international recommendations, as well as the

establishment of biosafety protocols for imaging exams, in order to minimize the risk of biological exposure (Carvalho & Silva, 2020; Júnior, 2020; Valentin et al., 2020).

In principle, the limitations regarding the handling of cadavers must comply with the legal order of each country and, although, at the moment, we do not have scientific evidence regarding this form of transmission of SARS-CoV-2, care is taken due to direct contact. With the corpse fluids by means of aerosols and splashes at the autopsy, highlighting the need to use personal protective equipment; need for diagnostic tests for the presence of the virus in the corpse before the autopsy, limited by the availability of laboratory tests (Fineschi et al., 2020; Khoo et al., 2020).

This article seeks to contribute to the construction of parameters of biosafety in order to protect government Agents of Expertise, among them: coroners, pathologists, radiologists and professionals of radiological techniques, in the exercise of their investigative functions in a pandemic context, as well as, resolve clinical, pathological and eventually legal questions. Such problem is fundamental to the valuation of forensic radiology as an investigative science and virtópsia as a digital necroscopic technique. And in its specific objective it is analyzing the framework and terminological and technological between the virtópsia and the autopsy, in order to evidence the effectiveness of the techniques of virtual necroscopes in the investigation of violent and non-violent deaths of contaminated corpses, with the intention of evidencing the real efficiency of Forensic Radiology as a complementary expert method of great significance for the construction of a report within the criminal and legal expertise, thus strengthening the team of the General Department of Technical Scientific Police and the Judiciary.

2. Methodology

In order to achieve the proposed object, it was defined to develop an exploratory review study with a qualitative approach with a focus on the core precepts of the main thinkers in the object's concentration field, as well as in the literature of related areas that also demonstrate depth and commitment to the theme exposed. The methodological design was performed using the platforms: PubMed and SciELO, in order to summarize materials that endorse the proposed theme, the following descriptors were used: Human identification; Radiology; Virtópsia; Autopsy.

The selection of content was carried out through screening by inclusion and exclusion criteria. The exclusion criteria involved articles with duplicate information, or that were not related to the objectives of the study. For inclusion, we selected materials published in Portuguese, English or Spanish, with full access for free and published between 2010 and 2021. First, the titles were analyzed, right after the abstracts, and in sequence the article in its entirety, including content that contemplated the proposed theme. In short, after a critical reading, only 76 were selected.

3. Results and Discussion

3.1 Correlation between macroscopic findings in conventional autopsy and virtopsy

The main objective of forensic radiology is to assist forensic medicine in the documentation, analysis and elucidation of scientific and / or legal issues that arise due to conflicts of interest for the protection of life. In the post-mortem, it seeks to identify the cause of death, estimate the lesions in degree, gender and extent of damage. In ant-mortem, on the other hand, it concentrates a large part of its efforts on the discovery of foreign bodies for the purpose of security and combating drug trafficking and also, on anthropological and paleoradiological analyzes (Asriet al., 2021; Biswas et al., 2021; Marques et al., 2021).

The macroscopic findings in suspected COVID-19 corpses vary in blocks of studies that are also of interest to virtopsy. Taking into account that the inability to visualize certain pathologies in the virtual autopsy, where the comparability of the normal with the abnormal is essential for its verification, it can be suppressed by the artificial and mechanical return of

the organ functioning (Curado et al., 2020).

3.1.1 Brain

The brain, less frequently, presents cerebral edema, encephalitis, meningitis, diffuse ischemic damage and disseminated focal hemorrhagic lesions with suffusions (Kremer et al., 2020).

3.1.2 Lungs

The lungs, in most cases, are heavier than normal, fissured and edematous, often with bronchopneumonia superimposed on focal consolidation areas, more aggressively in the lower lobes, but usually without a focus pattern in the lobes. Pulmonary thromboembolism was a relatively frequent finding, however, deep venous thrombosis was even more prevalent (Sakr et al., 2021).

Table 1. The average lung volume and the increase in lung volume during post-mortem ventilation at different pressures.

	Mean lung volume (in l)	Mean lung volume increase (in l)
Prior ventilation	1.18	-
10 mbar	1.23	0.06 ± 0.09
20 mbar	1.57	0.39 ± 0.37
30 mbar	2.11	0.94 ± 0.72
40 mbar	2.50	1.32 ± 1.07

Source: Adapted from Germerott et al., (2012).

3.1.3 Heart

In the heart, most of the findings come from pre-existing cardiovascular diseases, especially cardiomegaly and atherosclerosis. In the same way that occurs in the lungs, the detection of some pathologies requires the proper functioning of the vessels, since the main characteristic of cardiovascular diseases is partial or total obstruction and complications due to these changes. It is concluded that post-mortem angiotomography is the best tool in these cases (Boland et al., 2020).

Many post-mortem radiological findings in the lungs are false negatives due to the lack of physiology in the organ, since a good part of the pulmonary pathologies are detected due to the difference in tissue density in this region. Therefore, in this case, mechanical ventilation is an accessible possibility to overcome this limitation (Willer et al., 2018; Bradley et al., 2020).

Table 2. Suggestion of protocols for imaging and injection in post-mortem computed angiography.

Postmortem Imaging Phase	Body Position	Section Thickness (mm)	Reconstruction Kerne	Injection Volume (L)	Injection Flow (L/min)
Unenhanced	Supine	1.00	Soft tissue and lung	NA	NA
Arterial, wholebody	Supine	1.00	Soft tissue and medium hard (angiography)	1.5	0.6
Arterial, cardiac	Prone	0.63	Soft tissue and medium hard (angiography)	0.4	0.6
Venous	Supine	1.00	Soft tissue and medium hard (angiography)	1.8	0.6

Source: Adapted from Ross et al., (2014).

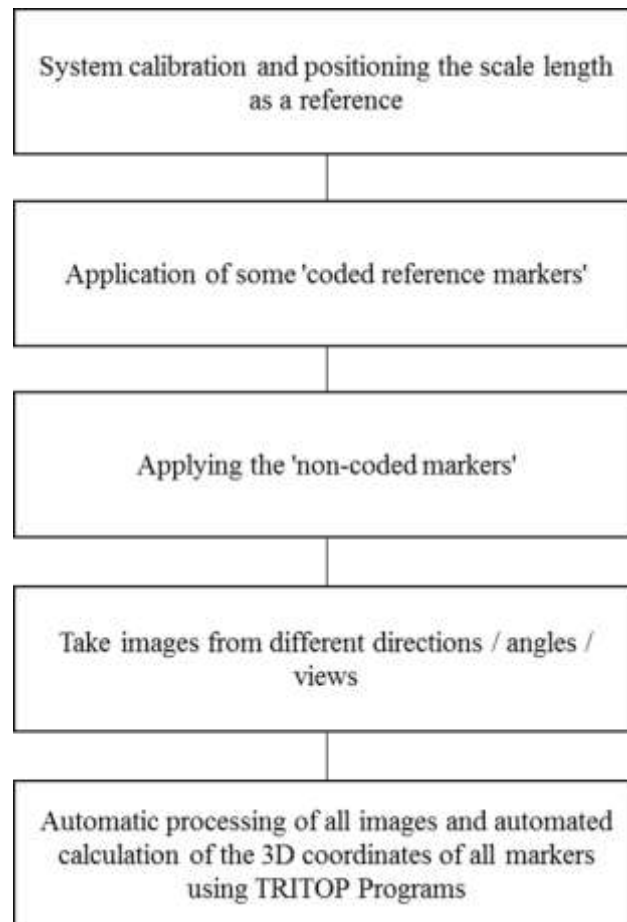
3.2 External documentation

Photogrammetry is the science of making surface measurements using simple photographs. The three-dimensional photogrammetry technique, known as stereophotogrammetry, is a more advanced technique, in which two or more photographs, in different positions, of a given object are made to offer measures that allow reconstructing the object photographed in three dimensions (Fonstad et al., 2013; Nesbit et al., 2018).

Through the technique of photogrammetry, identifying the position of points in three-dimensional space can be determined by triangulation of beam rays for observation. In this sense, several photos are taken from different angles of the object or the body surface through a portable or cell phone with good definition. After collecting the projection equations for the optical elements, the three-dimensional coordinates can be calculated using the spatial orientations of each superficial change (Sims-Waterhouse et al., 2017; Jo & Hong, 2019).

A suggested program for 3D optical digitization based on photogrammetry by measurements in prototyping and design technology would be through the GOM platform, through the software initiatives TRITOP and ATOS. Through this technology, it is possible to detail structures, superficial lesions and identify small objects, in the whole body or in large objects, as shown in the figures below (Siebke et al., 2018; Vaverka et al., 2019).

Figure 1. Shows the suggested Protocol for the photogrammetry technique using the TRITOP 34 software.



Source: The authors (2021).

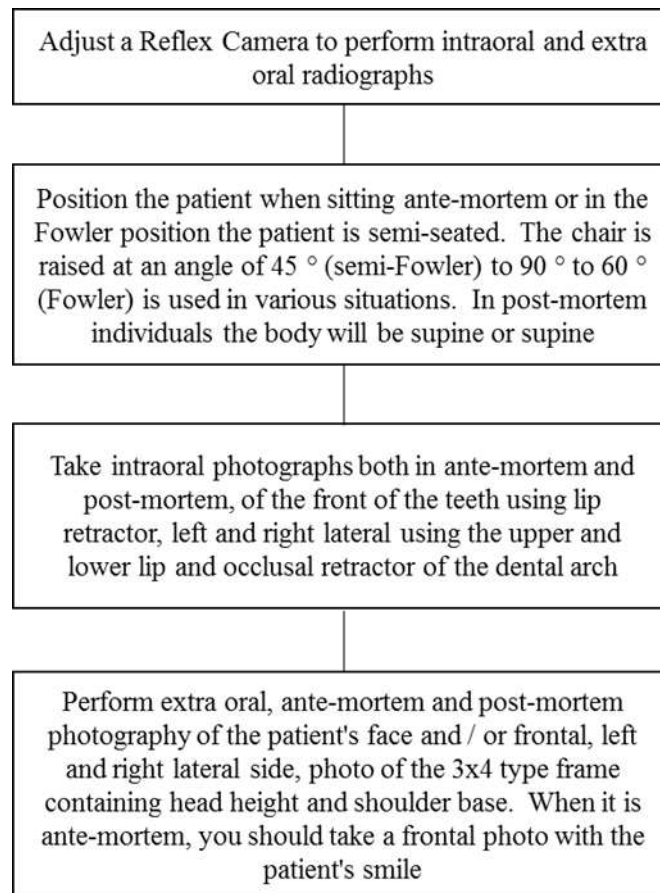
3.3 Dental photogrammetry

Identity is an inherent right to the Human Being, thus being something inalienable. In this way, human forensic identification is a process through which the identity of a person is determined, being extremely important with respect to Forensic Medicine. Identifying a corpse implies looking for the physical and anthropological signs that allow it to safely establish its civilian personality (Cordner & Tidball-Binz, 2017).

There are many methods used in the identification of human remains, currently most are based on the comparison between ante-mortem data provided and post-mortem constructed in imaging laboratories. Although dermatoglyphics, papiloscapy, that is, the fingerprint analysis technique is considered the most accurate, it is not all cases that it can be used, especially when the bodies were mutilated, decomposed, burned, fragmented and now contaminated by SARS- CoV-2 (Joshi & Dwivedi, 2015; De Boer et al., 2018; Li et al., 2020).

Documentation of intra-oral and extra-oral photos widely used in dental radiology consists of taking ante-mortem photographs of the patient for dental treatments. Thus providing a database for the various dental radiology clinics, with photos of the frontal face, profile, upper and lower occlusal, anterior, right and left occlusion. In addition to these digital photos, some radiographs such as Teleradiography/Cephalometric Frontal and Profile, Panoramic, Periapicals and Hand and Wrist for bone age are registered with the documentation (Manigandan et al., 2015; Viner & Robson, 2017).

Figure 2. Shows the Indications to perform dental photogrammetry.



Source: The authors (2021).

Intra-oral radiographs can provide important evidence for identifying individuals when used in Forensic Radiology due to the large amount of information recorded on the radiographic film or digital image in DICOM - Digital Imaging and Communications in Medicine. Characteristics found in anatomy, such as crown size and shape, pulp anatomy, position and shape of the crest of the alveolar bone, are very important. The factors of the changes caused by caries and the restorations made by dentists are also evaluated (Pandit & Boland, 2015).

This dental treatment presents results with unique and individual characteristics that, in most cases, are clearly visible on periapical radiographs. Thus, the identification technique consists essentially of a comparison between radiographs taken in life (ante-mortem), filed in software from dental radiology clinics, in orthodontic folders sent to patients and or dental offices, with those obtained after death (post-mortem) produced in specific laboratories for analysis (Cho et al., 2018).

3.3.1 Internal documentation

This method was developed in Switzerland in 2000, at the Institute of Forensic Medicine and Diagnostic Radiology at the University of Bern, known as PROJECT VIRTOPSY (Virtual Autopsy). Today, USP has become a pioneer in this project here in Brazil, creating criteria for the use of Scientific Radiology in solving crimes (Nissan, 2012; Bolliger & Thali, 2015).

3.3.2 Forensic identification

Throughout the twentieth century, mainly from the second half of the 1980s, with the great advance of information technology and the emergence of computerized radiology, there was a refinement and improvement of the radiological

technique, thus offering greater accuracy in the identifications (Cnudde & Boone, 2013).

The use of radiological images in the identification processes consists in the comparison between the radiographs obtained ante-mortem and those produced post-mortem, which are providers of a large number of information of the individual, becoming a fundamental tool in the processes related to the establishment of an identity (Ruder et al., 2012).

The radiographs most frequently used in the search for a personal identity are those of the skull, face, long bones and teeth (Manigandan et al., 2015). The radiological images, in an identification process, have a value equivalent to fingerprints and dental exams (Wood & Kogon, 2010). One of the radiological methods of image acquisition useful in human identification is Computed Tomography (CT), which can be obtained in the traditional way, in two-dimensional and three-dimensional images (Guillet et al., 2014). The tomographic film displays the name, sex and age of the patient, in addition, performed ante-mortem, CT provides information that can be used to produce a post-mortem replica, considering that craniometric points can be accurately located (Ibrahim et al., 2020).

Another useful tool in the individual identification process is facial reconstruction, which is a method that allows for the recognition by family members of certain remains without identification (Gupta et al., 2015).

When it comes to the facial reconstruction technique, some studies have opted for the use of Magnetic Resonance Imaging (MRI), because it has higher quality in the formation of the image and visualization of soft tissues (Bettoni et al., 2020).

Another alternative technique about human identification through the use of imagery can be used, such as the superimposition of images, or the skull-photo-comparative method, which consists of individual identification by photographic demonstration, using the superposition of individual photo negatives. Taken ante-mortem on those of the skull skeleton (Krishan et al., 2016).

With the evolution of Radiological Technologies, virtual autopsy has arrived and has been contributing enormously to research in the field of forensic pathology. Fast, non-invasive method that also protects family members from suffering, less traumatic than manual autopsy, when it comes to preserving the integrity of the body. It has 100% accuracy in identifying lesions of various types (Chen, 2017).

With this study, it can be concluded that human identification is something extremely relevant not only in the legal sphere, but also in the social sphere and, for that, Radiology, as well as Medical Imaging, contribute spectacularly to the identity determination and legitimize the it causes death of a person, constituting a safe, reliable, fast and practical method, in addition to being cheap, when compared to other methods such as DNA. However, no character taken in isolation has absolute value, as it is the set of signs and their convergence that allows for the positive identification and closing of a cadaveric report, but we cannot fail to mention the participation of this specialty in all social and investigative spheres (Zerbini & Saldiva, 2014; Savadjiev et al., 2019).

3.3.3 Post-Mortem X-rays

The birth of Forensic Radiology in the world accompanies the discovery of X-rays by the German physicist Wilhelm Conrad Roentgen (1872-1919). In 1896, a year after its discovery, the first criminal case occurred in the USA in which the use of X-rays was essential. The radiological examination of the jaw of the victim killed by a firearm demonstrated the authorship of the murder, due to the presence of the lead projectile in the exposed structure (Tchanque-Fossuoet al., 2011; Panchbhai, 2015).

The discovery of X-rays was a turning point for modern medicine (Widder, 2014). The countless accidents and deaths surrounding irresponsible exposures were useful for the advancement of research on the effects of the interaction of radiation with matter. Even with all the progress, at the first moment, the exams were seen as manifestations of the supernatural

(Kalmbach, 2013).

In Brazil, it is not known for sure the first researchers to perform the radiology exam, since both chronologically already worked together. For this reason, it is almost impossible to determine precisely the first scientist to inaugurate the method on national soil, although the reports are varied, ranging from Professor Alfredo Brito in Bahia, through researcher Silvia Ramos in São Paulo, and finally at doctor Francisco Pereira Neves in Rio de Janeiro (Matushita, 2011).

Currently, x-rays are used as a primary imaging method at the Institutes of Forensic Medicine. The choice of this method, in the first analysis, does not go beyond technical criteria, since x-rays are the gold standard in the detection of fractures and foreign bodies because it is more economically viable and easy to handle. However, this method does not have a satisfactory range of findings effective in detecting anatomopathological findings due to SARS-CoV-2 (Morais et al., 2011; Lima et al., 2020).

3.4 Post-Mortem Computed Tomography -TCPM

CT, in turn, is the worldwide chosen method for opening three-dimensional documentation, due to the best cost, biosafety, quality and dynamism. The combination of both methods can develop dynamic ways of estimating the weight, morphological and even microscopic changes of the dead (Dos Santos et al., 2014).

The first study carried out on human cadavers took place in 1977, in which six cases of skull injuries by firearms were described 36. In 2003, researchers at the University of Bern, Switzerland, combined modern imaging methods, such as CT, MRI and photogrammetry to minimally invasive whole body necropsy (Ghosh, 2015).

Post-mortem CT helps a lot in the diagnosis of death from natural causes, with excellent results in cases of craniofacial trauma and firearm trajectory, besides presenting advantages in the detection of small fractures, injuries by firearms, foreign bodies and gases (Grabherr et al., 2014).

3.5 These are nonspecific signs of TCPM

Livor mortis can be seen inside the body in the lungs: on chest CT, the internal livor mortis appears as ground-glass opacity in the dependent lower lobes. Gas bubbles are very common after death due to systemic embolism after major open trauma, artificial respiration or due to the onset of the gas period (Christe et al., 2010; Panda et al., 2015).

3.5.1 They are specific signs of TCPM

Intracranial bleeding is hyper-attenuating both in radiology and in the postmortem image. Signs of strangulation are hemorrhages in the soft tissues of the neck, such as skin, subcutaneous tissue, platysma muscle and lymph nodes. The fluid in the airways with mosaic pulmonary densities and emphysema (aqueous), typical for drowning (Islam et al., 2018).

It is concluded that the postmortem image is a new radiological subspecialty and, unlike diagnostic radiology, standards have not yet been established. In addition to the clinical and postmortem radiology differ significantly in several aspects: the imaging parameters can be adjusted to maximize the quality of the image and the indications in forensic medicine are usually different from those in clinical radiology (Flach et al., 2014).

3.5.2 Post-Mortem Magnetic Resonance - RMPM

MRI can be instrumental in replacing a conventional autopsy in children and neonates, especially for religious families or not, but who deny the authorization of the more invasive exam. Thayyil et al., (2013) demonstrated that 41% of minimally invasive necropsies performed by MRI do not require conventional necropsy.

RMPM is good for visualizing soft tissue injuries in cases of hemorrhage, subcutaneous hematomas, brain and lung

injuries. In addition to presenting disadvantages in terms of variations due to the corpse temperature at less than 10° C, where we found a decrease in the contrast in the relationship between fat and muscle and an increase in contrast in the relationship between water and fat and water and muscle (Sehba et al., 2011; Thayyil et al., 2013; Cordeiro et al., 2019).

3.5.3 Biosafety and infection control

Biosafety is the set of actions aimed at prevention, protection of the worker and / or patient, minimization of risks inherent to the activities of research, production, teaching, technological and operational development and extends to environmental protection and quality (Balthazar et al., 2017; Lacy et al., 2020).

Within the forensic radiology sector, walls and benches must be made in such a way that they are easy to clean, without sharp angles and recesses, thus avoiding the accumulation of dust. The benches in the material processing area are cleaned using sodium hypochlorite solutions, with 70% alcohol or with iodized alcohol. The floor of the entire unit, in addition to the walls and ceiling, are washed daily (Da Silva et al., 2016; Karus et al., 2018).

The handling of newly sterilized instruments requires the use of protective gloves and a disposable apron. Personnel must wear other personal protective equipment (appropriate clothing, hat or cap, mask, goggles or face shield and gloves) (Loveday et al., 2014; Chughtai et al., 2018; Livingston et al., 2020).

4. Conclusion

It is concluded that the application of the image investigation techniques demonstrated in this article, evidence the need for hyper specialized training of radiology professionals.

Thus, the forensic expert in radiological techniques has broad participation and expertise in the handling and adaptation of varied radiological resources to scientifically assist in criminal justice, criminal body examinations, anthropological, dental, judicial and or private. This article brings a new perspective of the importance in this Pandemic moment and the direct participation of the professionals of the radiological techniques in the differential diagnosis of SARS-COV-2 (Ante-mortem) and in the closing of the cadaveric report (Post-mortem). The narrative comes to affirm Forensic Radiology as an investigative and multidisciplinary science. The insertion of this science in academic disciplines is necessary, given the range of knowledge necessary for its safe performance. This knowledge in the training matrix and / or specializing will be a divider for hiring in the specific area, being important for the teacher teacher to have these titles or prerequisite for the exercise of differentiated Forensic activity. It is relatively high to raise the banner of this multidisciplinary professional ready to serve society. It is very important to look responsibly at the use of radiation in its various radiological specialties. And that includes Ports, Airports, Industries, Prisons, Agribusiness, Anthropological and Dental, we have full knowledge of biosafety for each job highlighted here. Finally, the view of the researchers in the article presented, it is a Quantum change to protocols suggested by these scientists that will contribute to good Radiological practices in the challenges of a good diagnosis!

References

- Asri, M. N. M., Nestrgan, N. F., Nor, N. A. M., & Verma, R. (2021). On the discrimination of inkjet, laser and photocopier printed documents using Raman spectroscopy and chemometrics: Application in forensic science. *Microchemical Journal*, 165, 106136.
- Balthazar, M. A. P., Andrade, M., Ferreira de Souza, D., Machado Cavagna, V., & Cavalcanti Valente, G. S. (2017). Occupational risk management in hospital services: a reflective analysis. *Journal of Nursing UFPE/Revista de Enfermagem UFPE*, 11(9).
- Bettoni, J., Balédent, O., Petruzzo, P., Duisit, J., Kanitakis, J., Devauchelle, B., & Dakpé, S. (2020). Role of flow magnetic resonance imaging in the monitoring of facial allotransplantations: preliminary results on graft vasculopathy. *International journal of oral and maxillofacial surgery*, 49(2), 169-175.
- Biswas, U. K., Hossain, M. A., Moinuddin, K. M., & Khan, N. T. (2021). Virtopsy: New Dimension in the Field of Forensic Medicine communities. *Journal of Z H Sikder Women's Medical college*, 3(1).

- Boland, D. M., Reidy, L. J., Seither, J. M., Radtke, J. M., & Lew, E. O. (2020). Forty-three fatalities involving the synthetic cannabinoid, 5-fluoro-ADB: Forensic pathology and toxicology implications. *Journal of forensic sciences*, 65(1), 170-182.
- Bolliger, S. A., & Thali, M. J. (2015). Imaging and virtual autopsy: looking back and forward. *Philosophical Transactions of the Royal Society B: Biological Sciences*, 370(1674), 20140253.
- Bradley, B. T., Maioli, H., Johnston, R., Chaudhry, I., Fink, S. L., Xu, H., & Marshall, D. A. (2020). Histopathology and ultrastructural findings of fatal COVID-19 infections in Washington State: a case series. *The Lancet*, 396(10247), 320-332.
- Carvalho, L. R., & Silva, M. F. (2020). COVID-19 e biossegurança, uma nova perspectiva para a prática odontológica COVID-19 and biosafety, a new perspective for dental practice. *Revista da Faculdade de Odontologia da UFBA*, 50(3).
- Chen, Y. (2017). State of the art in post-mortem forensic imaging in China. *Forensic sciences research*, 2(2), 75-84.
- Cho, H., Zin, T. T., Shinkawa, N., & Nishii, R. (2018). Post-Mortem Human Identification Using Chest X-Ray and CT Scan Images. *International Journal of Biomedical Soft Computing and Human Sciences: the official journal of the Biomedical Fuzzy Systems Association*, 23(2), 51-57.
- Christe, A., Flach, P., Ross, S., Spendlove, D., Bolliger, S., Vock, P., & Thali, M. J. (2010). Clinical radiology and postmortem imaging (Virtopsy) are not the same: specific and unspecific postmortem signs. *Legal medicine*, 12(5), 215-222.
- Chughtai, A. A., Chen, X., & Macintyre, C. R. (2018). Risk of self-contamination during doffing of personal protective equipment. *American journal of infection control*, 46(12), 1329-1334.
- Cnudde, V., & Boone, M. N. (2013). Tomografia computadorizada de raios-X de alta resolução em geociências: uma revisão da tecnologia e aplicações atuais. *Earth-Science Reviews*, 123, 1-17.
- Cordeiro, C., Ordóñez-Mayán, L., Lendoiro, E., Febrero-Bande, M., Vieira, D. N., & Muñoz-Barús, J. I. (2019). A reliable method for estimating the postmortem interval from the biochemistry of the vitreous humor, temperature and body weight. *Forensic science international*, 295, 157-168.
- Cordner, S., & Tidball-Binz, M. (2017). Humanitarian forensic action—Its origins and future. *Forensic science international*, 279, 65-71.
- Curado, M., Rodrigues, J. V., & Pereira, A. D. (2020). Enmarzo de 2020: luchar contra la enfermedad, superar la desesperación, pensar en la salud. *Cadernos Ibero-Americanos De Direito Sanitário*, 9(1), 10-23.
- Da Silva Aquino, I., Porto, J. C. S., da Silva, J. L., Morais, K. F. C., Coelho, F. A., de Sousa Lopes, T., & Mobin, M. (2016). Evaluation of disinfectants for elimination of fungal contamination of patient beds in a reference hospital in Piauí, Brazil. *Environmental monitoring and assessment*, 188(11), 1-4.
- Da Silva, A. S. T., Pinto, R. L. G., & Martins, A. A. (2020). Implementation of the post-death body management protocol in the context of the new Coronavirus / Implementation of the body management protocol in the context of the new Coronavirus. *Journal of Nursing and Health*, 10 (4).
- De Boer, H. H., Maat, G. J., Kadarmo, D. A., Widodo, P. T., Kloosterman, A. D., & Kal, A. J. (2018). DNA identification of human remains in Disaster Victim Identification (DVI): An efficient sampling method for muscle, bone, bone marrow and teeth. *Forensic science international*, 289, 253-259.
- De Lima, L. C., & Júnior, A. D. S. D. (2020). O retorno ao dilema de antigona: a dignidade do corpo morto no contexto pandêmico da COVID-19. *Revista Pensamento Jurídico*, 14(2).
- Dos Santos Rolo, T., Ershov, A., Van De Kamp, T., & Baumbach, T. (2014). In vivo X-ray cine-tomography for tracking morphological dynamics. *Proceedings of the National Academy of Sciences*, 111(11), 3921-3926.
- Finegan, O., Fonseca, S., Guyomarc'h, P., Mendez, M. D. M., Gonzalez, J. R., Tidball-Binz, M., & on the Management, I. A. G. (2020). International Committee of the Red Cross (ICRC): General guidance for the management of the dead related to COVID-19. *Forensic Science International: Synergy*, 2, 129-137.
- Fineschi, V., Aprile, A., Aquila, I., Arcangeli, M., Asmundo, A., Bacci, & Sapino, A. (2020). Management of the corpse with suspect, probable or confirmed COVID-19 respiratory infection - Italian interim recommendations for personnel potentially exposed to material from corpses, including body fluids, in morgue structures and during autopsy practice. *Pathologica*, 112(2), 64-77.
- Flach, P. M., Gascho, D., Schweitzer, W., Ruder, T. D., Berger, N., Ross, S. G., & Ampanozi, G. (2014). Imaging in forensic radiology: an illustrated guide for postmortem computed tomography technique and protocols. *Forensic science, medicine, and pathology*, 10(4), 583-606.
- Fonstad, M. A., Dietrich, J. T., Courville, B. C., Jensen, J. L., & Carbonneau, P. E. (2013). Topographic structure from motion: a new development in photogrammetric measurement. *Earth surface processes and Landforms*, 38(4), 421-430.
- Garrido, R. G., & de Almeida, M. P. (2020). Impasses entre dignidade e saúde no manejo de cadáveres da COVID-19: identificar ou reconhecer?. *Comunicação em Ciências da Saúde*, 31(Suppl 1), 84-93.
- Ghosh, S. K. (2015). Human cadaveric dissection: a historical account from ancient Greece to the modern era. *Anatomy & cell biology*, 48(3), 153.
- Grabherr, S., Grimm, J., Dominguez, A., Vanhaebost, J., & Mangin, P. (2014). Advances in post-mortem CT-angiography. *The British journal of radiology*, 87(1036), 20130488.
- Germerott, T., et al. (2012). Postmortem ventilation: A new method for improved detection of pulmonary pathologies in forensic imaging. *Legal Medicine*, 14(1)223-228.
- Guillet, J. P., Recur, B., Frederique, L., Bousquet, B., Canioni, L., Manek-Hönniger, I., & Mounaix, P. (2014). Review of terahertz tomography techniques. *Journal of Infrared, Millimeter, and Terahertz Waves*, 35(4), 382-411.

- Gupta, S., Gupta, V., Vij, H., Vij, R., & Tyagi, N. (2015). Forensic facial reconstruction: The final frontier. *Journal of clinical and diagnostic research: JCDR*, 9(9), ZE26.
- Hartmann, F. V. G., et al., (2020). Manual COVID-19 - prevenção e tratamento. Hospital da escola de medicina da universidade de Zhejiang. Brasília: *Fepecs*, 2020. <http://www.cmm.zju.edu.cn/cmmenglish/2020/0320/c32029a1986784/page.htm>.
- Htun, Y. M., Win, T. T., Aung, A., Latt, T. Z., Phyo, Y. N., Tun, T. M., & Htun, K. A. (2021). Initial Presenting Symptoms, Comorbidities and Severity of COVID-19 Patients Attending Hmawbi and Indine Treatment Centers During the Second Wave of Epidemic in Myanmar: a Cross-sectional Study. *Research square*, (1)365594.
- Hui, D. S., Zumla, A., & Tang, J. W. (2021). Lethal zoonotic coronavirus infections of humans—comparative phylogenetics, epidemiology, transmission, and clinical features of coronavirus disease 2019, The Middle East respiratory syndrome and severe acute respiratory syndrome. *Current Opinion in Pulmonary Medicine*, 27(3), 146-154.
- Ibrahim, M. A., Abdel-Karim, R. I., Ibrahim, M. S., & Dar, U. F. (2020). Comparative study of the reliability of frontal and maxillary sinuses in sex identification using multidetector computed tomography among Egyptians. *Forensic Imaging*, 22, 200390.
- Islam, M. N., Khan, J., Ikematsu, K., Bagali, P. G., & Raman, V. K. (2018). Digital Autopsy: Popular Tools for an Unpopular Procedure. *Arab Journal of Forensic Sciences & Forensic Medicine*, 1(7), 792-799.
- Jabal, K. A., Ben-Amram, H., Beiruti, K., Batheesh, Y., Sussan, C., Zarka, S., & Edelstein, M. (2021). Impact of age, ethnicity, sex and prior infection status on immunogenicity following a single dose of the BNT162b2 mRNA COVID-19 vaccine: real-world evidence from healthcare workers, Israel, December 2020 to January 2021. *Eurosurveillance*, 26(6), 2100096.
- Jo, Y. H., & Hong, S. (2019). Three-dimensional digital documentation of cultural heritage site based on the convergence of terrestrial laser scanning and unmanned aerial vehicle photogrammetry. *ISPRS International Journal of Geo-Information*, 8(2), 53.
- Joshi, R. R., & Dwivedi, R. (2015). Presentation and Management of Soft-Tissue Foreign Bodies in a Teaching Hospital of Western Nepal. *Journal of Lumbini Medical College*, 3(2), 50-54.
- Júnior, A. B. (2020). Biopolítica, asfixia e pandemias no brasil: sobre a aids e a COVID-19. *Revista Linguagem*, 35(1), 98-118.
- Kalmbach, K. (2013). Radiation and borders: Chernobyl as a national and transnational site of memory. *Global Environment*, 6(11), 130-159.
- Karus, A., Praakle, K., Saar, T., Must, K., Randoja, H., & Viltrop, A. (2018). *Biosafety and biosecurity manual*, (15)1-9.
- Khoo, L. S., Hasmi, A. H., Ibrahim, M. A., & Mahmood, M. S. (2020). Management of the dead during COVID-19 outbreak in Malaysia. *Forensic Science, Medicine and Pathology*, 16, 463-470.
- Kremer, S., Lersy, F., Anheim, M., Merdji, H., Schenck, M., Oesterlé, H., & Cotton, F. (2020). Neurologic and neuroimaging findings in patients with COVID-19: A retrospective multicenter study. *Neurology*, 95(13), e1868-e1882.
- Krishan, K., Chatterjee, P. M., Kanchan, T., Kaur, S., Baryah, N., & Singh, R. K. (2016). A review of sex estimation techniques during examination of skeletal remains in forensic anthropology casework. *Forensic science international*, 261, 165.e1–165.e1658.
- Lacy, J. M., Brooks, E. G., Akers, J., Armstrong, D., Decker, L., Gonzalez, A., & Utley, S. (2020). COVID-19: postmortem diagnostic and biosafety considerations. *The American journal of forensic medicine and pathology*, 41(3), 143.
- Li, R., Yin, K., Zhang, K., Wang, Y. Y., Wu, Q. P., Tang, S. B., & Cheng, J. D. (2020). Application Prospects of Virtual Autopsy in Forensic Pathological Investigations on COVID-19. *Fayixuezhazhi*, 36(2), 149–156.
- Lima, F. L. O., Gomes, L. N. L., Santos, C. S. C. dos., & Oliveira, G. A. L. de. (2020). Diagnosis of COVID-19: importance of laboratory tests and imaging exams. *Research, Society and Development*, 9(9), e25997162.
- Livingston, E., Desai, A., & Berkwits, M. (2020). Sourcing personal protective equipment during the COVID-19 pandemic. *Jama*, 323(19), 1912-1914.
- Loveday, H. P., Wilson, J. A., Pratt, R. J., Golsorkhi, M., Tingle, A., Bak, A., & Wilcox, M. (2014). epic3: national evidence-based guidelines for preventing healthcare-associated infections in NHS hospitals in England. *Journal of Hospital Infection*, 86, S1-S70.
- Manigandan, T., Sumathy, C., Elumalai, M., Sathasivasubramanian, S., & Kannan, A. (2015). Forensic radiology in dentistry. *Journal of pharmacy & bioallied sciences*, 7(Suppl 1), S260.
- Marques, L. J. P., Silva, Z. P. D., Alencar, G. P., & Almeida, M. F. D. (2021). Contribuições da investigação dos óbitos fetais para melhoria da definição da causa básica do óbito no Município de São Paulo, Brasil. *Cadernos de Saúde Pública*, 37, e00079120.
- Matushita, J. P., & Khoury, H. J. (2011). Some Aspects of Diagnostic Radiology in Brazil. *International Atomic Energy Agency (IAEA): IAEA*, 41(10) 43017582.
- Morais, H. H. A. D., Silva, A. P. D., Paiva, A. C. S., Medeiros, F. D. C. D. D., & Araújo, F. A. D. C. (2011). Corpo estranho orgânico em face: relato de caso. *Revista de Cirurgia e Traumatologia Buco-maxilo-facial*, 11(1), 47-53.
- Nesbit, P. R., Durkin, P. R., Hugenholtz, C. H., Hubbard, S. M., & Kucharczyk, M. (2018). 3-D stratigraphic mapping using a digital outcrop model derived from UAV images and structure-from-motion photogrammetry. *Geosphere*, 14(6), 2469-2486.

- Nissan, E. (2012). Virtopsy: The Virtual Autopsy. In *Computer Applications for Handling Legal Evidence, Police Investigation and Case Argumentation*. Springer, Dordrecht. (pp. 991-1015).
- Panchbhai, A. S. (2015). Wilhelm Conrad Röntgen and the discovery of X-rays: Revisited after centennial. *Journal of Indian academy of oral medicine and radiology*, 27(1), 90.
- Panda, A., Kumar, A., Gamanagatti, S., & Mishra, B. (2015). Virtopsy computed tomography in trauma: normal postmortem changes and pathologic spectrum of findings. *Current problems in diagnostic radiology*, 44(5), 391-406.
- Pandit, R. R., & Boland, M. V. (2015). Impact of digital imaging and communications in medicine workflow on the integration of patient demographics and ophthalmic test data. *Ophthalmology*, 122(2), 227-232.
- Rabay Guerra, G. U. S. T. A. V. O., Marcos, H., & Ítalo Hardman, A. N. T. Ô. N. I. O. (2020). De Wuhan ao Planalto Central: Federalismo, Patriotismo Constitucional e o Supremo Frente a COVID-19. *Revista Jurídica* (0103-3506), 4(61).
- Ross, S. G., Bolliger, S. A., et. al.(2014). Postmortem CT Angiography: Capabilities and Limitations in Traumatic and Natural Causes of Death. *RadioGraphics*. 34(1)830-846.
- Ruder, T. D., Kraehenbuehl, M., Gotsmy, W. F., Mathier, S., Ebert, L. C., Thali, M. J., & Hatch, G. M. (2012). Radiologic identification of disaster victims: a simple and reliable method using CT of the paranasal sinuses. *European journal of radiology*, 81(2), e132-e138.
- Sakr, Y., Giovini, M., Leone, M., Pizzilli, G., Kortgen, A., Bauer, M., & Antonucci, E. (2021). The clinical spectrum of pulmonary thromboembolism in patients with coronavirus disease-2019 (COVID-19) pneumonia: A European case series. *Journal of critical care*, 61, 39-44.
- Savadjiev, P., Chong, J., Dohan, A., Vakalopoulou, M., Reinhold, C., Paragios, N., & Gallix, B. (2019). Demystification of AI-driven medical image interpretation: past, present and future. *European radiology*, 29(3), 1616-1624.
- Sehba, F. A., Pluta, R. M., & Zhang, J. H. (2011). Metamorphosis of subarachnoid hemorrhage research: from delayed vasospasm to early brain injury. *Molecular neurobiology*, 43(1), 27-40.
- Siebke, I., Campana, L., Ramstein, M., Furtwängler, A., Hafner, A., & Lösch, S. (2018). The application of different 3D-scan-systems and photogrammetry at an excavation—A Neolithic dolmen from Switzerland. *Digital Applications in Archaeology and Cultural Heritage*, 10, e00078.
- Sims-Waterhouse, D., Piano, S., & Leach, R. (2017). Verification of micro-scale photogrammetry for smooth three-dimensional object measurement. *Measurement Science and Technology*, 28(5), 055010.
- Tchanque-Fossuo, C. N., Monson, L. A., Farberg, A. S., Donneys, A., Zehtabzadeh, A. J., Razdolsky, E. R., & Buchman, S. R. (2011). Dose-response effect of human equivalent radiation in the murine mandible. Part I. A histomorphometric assessment. *Plastic and reconstructive surgery*, 128(1), 114.
- Thayyil, S., Sebire, N. J., Chitty, L. S., Wade, A., Chong, W. K., Olsen, O., & Taylor, A. M. (2013). Post-mortem MRI versus conventional autopsy in fetuses and children: a prospective validation study. *The Lancet*, 382(9888), 223-233.
- Valentin, M. V., Dias, C. C., Barbosa, H. L. M., & Braga, D. O. (2020). Aspectos radiológicos em paciente com covid-19: um relato de caso. *Revista Interdisciplinar de Saúde e Educação*, 1(2), 249-259.
- Vaverka, O., Koutny, D., & Palousek, D. (2019). Topologically optimized axle carrier for Formula Student produced by selective laser melting. *Rapid Prototyping Journal*, 25(9), 1545-1551.
- Viner, M. D., & Robson, J. (2017). Post-Mortem Forensic Dental Radiography-a review of current techniques and future developments. *Journal of Forensic Radiology and Imaging*, 8, 22-37.
- Widder, J. (2014). The origins of radiotherapy: Discovery of biological effects of X-rays by Freund in 1897, Kienböck's crucial experiments in 1900, and still it is the dose. *Radiotherapy and Oncology*, 112(1), 150-152.
- Willer, K., Fingerle, A. A., Gromann, L. B., De Marco, F., Herzen, J., Achterhold, K., & Noël, P. B. (2018). X-ray dark-field imaging of the human lung—A feasibility study on a deceased body. *PLoS One*, 13(9), e0204565.
- Wood, R. E., & Kogon, S. L. (2010). Dental radiology considerations in DVI incidents: A review. *Forensic science international*, 201(1-3), 27-32.
- Zerbini, T., & Saldiva, P. H. N. (2014). The Historical Evolution of the Tools Available for Initial Chronothagnosis. *Brazilian Journal of Forensic Sciences, Medical Law and Bioethics*, 3(2), 165-185.