

The use of Nile Tilapia skin as an occlusive biological dressing for palatal wound healing: A case series

O uso da pele de Tilápia-do-Nilo como curativo biológico oclusivo para a cura de feridas palatais:

Série de casos

El uso de la piel de tilapia del Nilo como apósito biológico oclusivo para la curación de heridas palatales: Serie de casos

Received: 14/06/2021 | Reviewed: 24/06/2021 | Accept: 26/06/2021 | Published: 11/07/2021

Gustavo Gonçalves do Prado Manfredi

ORCID: <https://orcid.org/0000-0001-9623-9769>

Faculdade de Odontologia de Bauru, Brazil

E-mail: gustavomanfredi90@gmail.com

Matheus Volz Cardoso

ORCID: <https://orcid.org/0000-0002-7609-8003>

Faculdade de Odontologia de Bauru, Brazil

E-mail: ddsmatheusvolz@gmail.com

Vitor de Toledo Stuani

ORCID: <https://orcid.org/0000-0001-5290-7614>

Faculdade de Odontologia de Bauru, Brazil

E-mail: vitor.toledo@hotmail.com

Rafael Ferreira

ORCID: <https://orcid.org/0000-0001-5879-2782>

Universidade Federal do Mato Grosso do Sul, Brazil

E-mail: rafael_ferreira@ufms.br

Mariana Schutzer Raghianti Zangrando

ORCID: <https://orcid.org/0000-0003-0286-7575>

Faculdade de Odontologia de Bauru, Brazil

E-mail: mariana@fob.usp.br

Carla Andreotti Damante

ORCID: <https://orcid.org/0000-0002-6782-8596>

Faculdade de Odontologia de Bauru, Brazil

E-mail: cdamante@usp.br

Manoel Odorico de Moraes Filho

ORCID: <https://orcid.org/0000-0003-3378-8722>

Universidade Federal do Ceará, Brazil

E-mail: odorico@ufc.br

Ana Paula Negreiros Nunes Alves

ORCID: <https://orcid.org/0000-0002-5090-6877>

Universidade Federal do Ceará, Brazil

E-mail: ananegreirosnunes@gmail.com

Edmar Maciel Lima Júnior

ORCID: <https://orcid.org/0000-0003-3158-7994>

Universidade Federal do Ceará, Brazil

E-mail: edmarmaciel@gmail.com

Adriana Campos Passanezi Sant'Ana

ORCID: <https://orcid.org/0000-0001-5640-9292>

Faculdade de Odontologia de Bauru, Brazil

E-mail: acpsantana@usp.br

Abstract

Recently, the use of type I collagen obtained from Nile Tilapia (*Oreochromis niloticus*) was proposed for the treatment of second and third-degree burning lesions and diabetic ulcers due to its occlusive and healing properties. The aim of this report is to describe the use of Nile tilapia skin as an occlusive barrier to protect palatal wounds after the removal of free autogenous soft tissue grafts. Two patients with a deficiency in the height of keratinized mucosa were indicated for treatment with free gingival grafts. The palatal donor area was covered with a Nile tilapia skin, stabilized by sutures. Seven days after surgery, patients returned for post-operative care. Patients' reported outcomes were investigated by the use of a visual analogue scale and included pain, discomfort, impact on chewing and speaking. Analgesics consumption was also recorded. Standardized photographs were obtained to monitor wound healing. Patients were followed up for 30 days. Patients reported reduced pain levels, with low consumption of analgesics during the first week

after surgery. No discomfort or difficulty in chewing or speaking was reported. No complications such as hemorrhage or edema were observed. These findings suggest that the Nile Tilapia skin may be an interesting alternative as an occlusive biological dressing in palatal wounds harvest of free gingival grafts.

Keywords: Biomaterial; Pain; Periodontal dressings; Wound healing; Nile tilapia.

Resumo

Recentemente, o uso do colágeno tipo I obtido da tilápia-do-Nilo (*Oreochromis niloticus*) foi proposto para o tratamento de lesões em queimados de segundo e terceiro graus, e em úlceras diabéticas, devido às suas propriedades oclusivas e cicatrizantes. O objetivo deste relato de casos é descrever o uso da pele de tilápia-do-Nilo como uma barreira oclusiva para proteger a ferida palatina após a remoção de enxertos autógenos de tecido mole. Dois pacientes com deficiência na altura de mucosa queratinizada foram indicados para tratamento com enxertos gengivais livres. A ferida palatina foi recoberta com pele de tilápia-do-Nilo e estabilizada por suturas. Sete dias após a cirurgia, os pacientes retornaram para cuidados pós-operatórios, e foram acompanhados por 30 dias. As avaliações foram investigadas pelo uso de escala visual analógica que incluíam dor, desconforto, impacto na mastigação e na fala. O consumo de analgésicos também foi registrado. Fotografias padronizadas foram obtidas para monitorar a cicatrização das feridas. Nos resultados, os pacientes relataram baixos scores de dor e de consumo de analgésicos, na primeira semana de pós-operatório. Nenhum desconforto ou dificuldade para mastigar ou falar foi relatado. Não foram observadas complicações como hemorragia ou edema. Esses achados sugerem que a pele de tilápia-do-Nilo pode ser uma alternativa interessante como curativo biológico oclusivo em feridas palatinas após remoção dos enxertos gengivais livres.

Palavras-chave: Biomaterial; Dor; Curativos periodontais; Cicatrização; Tilápia do Nilo.

Resumen

Recientemente, se propuso el uso de colágeno tipo I obtenido de la Tilapia del Nilo (*Oreochromis niloticus*) para el tratamiento de las quemaduras de segundo y tercer grado, y úlceras diabéticas por sus propiedades oclusivas y cicatrizantes. El objetivo de este informe es describir el uso de piel de tilapia del Nilo como barrera oclusiva para proteger la herida palatina después de la extracción de injertos autógenos libres de tejido blando. Dos pacientes con deficiencia en la altura de la mucosa queratinizada fueron indicados para tratamiento con injertos gingivales libres. El área donante palatina se cubrió con una piel de tilapia del Nilo, estabilizada mediante sutura. Siete días después de la cirugía, los pacientes regresaron para recibir atención posoperatoria. Los resultados informados por los pacientes se investigaron mediante el uso de una escala analógica visual e incluyeron dolor, malestar, impacto al masticar y hablar. También se registró el consumo de analgésicos. Se obtuvieron fotografías estandarizadas para monitorear la cicatrización de heridas. Los pacientes fueron seguidos durante 30 días. Los pacientes informaron disminución del nivel de dolor, con bajo consumo de analgésicos durante la primera semana después de la cirugía. No se informó de molestias o dificultad para masticar o hablar. No se observaron complicaciones como hemorragia o edema. Estos hallazgos sugieren que la piel de Tilapia del Nilo puede ser una alternativa interesante como apósito biológico oclusivo en heridas palatinas después de la extracción de injertos gingivales libres.

Palabras clave: Biomaterial; Dolor; Apósitos periodontales; Cicatrización de heridas; Tilapia del Nilo.

1. Introduction

Autogenous soft tissue grafts are widely used in periodontal and peri-implant surgical procedures. These grafts are generally used for root coverage (Chambrone, Chambrone, Pustigliani, Chambrone, & Lima, 2008), increase in the width of keratinized mucosa (Zucchelli & Mounssif, 2015; Zuhr, Baumer, & Hurzeler, 2014), and soft tissue management around dental implants (Sanz et al., 2012). However, a second surgical site is necessary for harvesting the graft, leading to pain, burning sensation, and, in some cases, delayed wound healing (Yildirim, Ozener, Dogan, & Kuru, 2018).

To reduce the incidence of postoperative complications and to contribute to the healing process, several techniques have been tested. Among these, we can highlight the use of different dressings and protective materials, such as Hawley's plaque (Farnoush, 1978), fibrin-rich plasma (Shayesteh et al., 2012), polyurethane adhesive film (Kaiser, Hafner, Mayer, French, & Lauchli, 2013) and hyaluronic acid (Yildirim et al., 2018), among others. However, an ideal material that has acceptable biological properties, practicality, and low cost has not yet been established.

Nile tilapia skin (NTS) has been investigated as a possible source of collagen type I to the treatment of burning and diabetic lesions (Dorweiler et al., 2018). NTS is mainly composed of collagen type I and has a morphological structure similar to human skin (Alves, 2015). It is resistant to traction, does not generate an inflammatory response in humans (E. M. Lima Junior et al., 2020) presents anti-bacterial and anti-viral occlusal properties, low antigenicity, and is hemostatic (L.; Sun, Li, Yao, Song,

& Hou, 2018). Animal and human studies have suggested its potential use to accelerate wound healing in dermal unresponsive wounds (E M Lima Junior et al., 2017) (E. M. Lima Junior et al., 2020). In pediatric burns, it proved to be an effective therapy due to the low cost of the material (Costa et al., 2019), and for decreasing the use of analgesics and the time of healing (E. M. Lima Junior et al., 2020). In vaginal reconstruction procedures, the use of NTS proved to be a less invasive procedure, easy to perform, and effective (Dias et al., 2019; Dias et al., 2020).

Due to biological properties and potential benefits for the patient, this series of cases will describe the use of NTS as a biological occlusal dressing for palate wounds after the removal of free gingival grafts (FGG).

2. Methodology

Clinical Presentation and Management

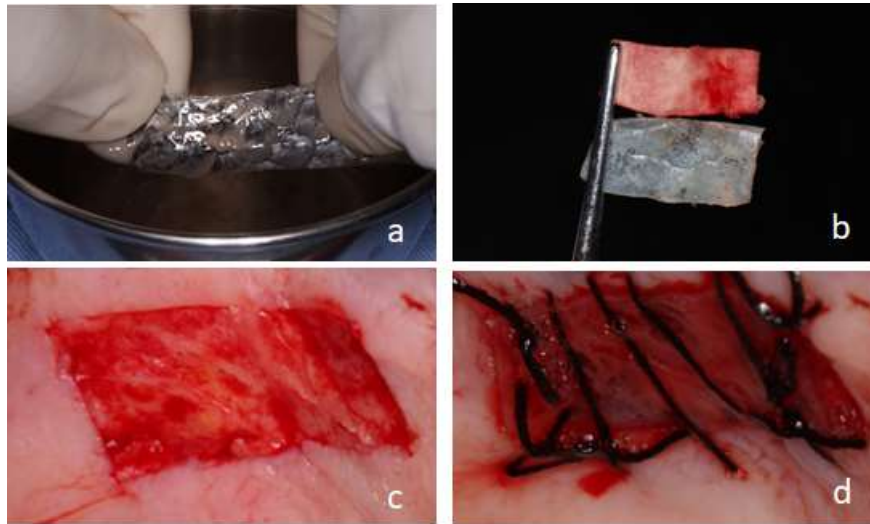A 47-year-old woman and a 38-year-old man, both non-smokers, were referred for periodontal treatment at the Periodontics Clinic at Bauru School of Dentistry – University of Sao Paulo. Both patients had a deficiency in the height of keratinized tissue, so an FGG was recommended at the treatment plan. To reduce postoperative morbidity, the use of NTS as an occlusive biological dressing was considered. The treatment of these patients only begun after the approval of the National Commission of Research ethics (CAAE: 08515519.1.0000.5417) and the patients' agreement with the procedure by signing the Free and Informed Consent Form.

Initially, patients received basic periodontal therapy. Two months later, after both patients reached periodontal stability, FGG was performed according to Sullivan and Atkins (Sullivan & Atkins, 1969). The recipient sites were anesthetized with an infiltrative technique with 4% articaine with epinephrine (1: 100,000) (DFL, Brazil). The recipient site was prepared by an incision on the mucogingival margin with a 15C disposable scalpel blade (Swann-Morton, England) at the buccal region of the interest sites. A split-thickness flap was raised, leaving a very thin layer of connective tissue close to the periosteum. The apical extension of the receptor bed was 2 mm larger than the graft dimension and the lateral extension was delimited by two vertical relaxing incisions.

Then, an infiltrative application was performed in the palatal region adjacent to the upper premolars, leading to mild ischemia. With a 15C blade (Swann-Morton, England), the dimensions of the graft were delimited in the palatal mucosa with a maximum incision depth of 2 mm. With the same scalpel blade and helped by a Kirkland 15/16 periodontal scalpel (Hu-Friedy, USA), the delimited tissue was dissected to the same thickness. Once removed, the graft was positioned at the receptor site and immobilized with simple and compressive sutures so that its cervical margin was at the level of the horizontal incision.

The NTS used in these cases were donated by the Center for Research and Development of Medicines of the Federal University of Ceará after being processed, sterilized, and stored. Before its use, a protocol of three washes with saline solution was performed, massaging it for 5 minutes per wash to eliminate all glycerol excess. Glycerol is the preservatives of the tissue matrix. When the palate bleeding was controlled, NTS was trimmed 2 mm larger than the wound and sutured to the donor site. The suture technique consisted of simple stitches on the edges of the NTS and a comprehensive suture (using 4.0 silk suture ETHICON- - Johnson & Johnson, USA) to promote close contact with the underlying connective tissue (Figure 1).

Figure 1. A) NTS was briefly washed and massaged for 5 minutes three times to remove all glycerol. B) NTS dimensions were adjusted following the surgical map used for harvesting the graft. C) Palate donor site after the removal of 1 mm thick gingival graft. D) The NTS was sutured and stabilized covering the palatal wound.



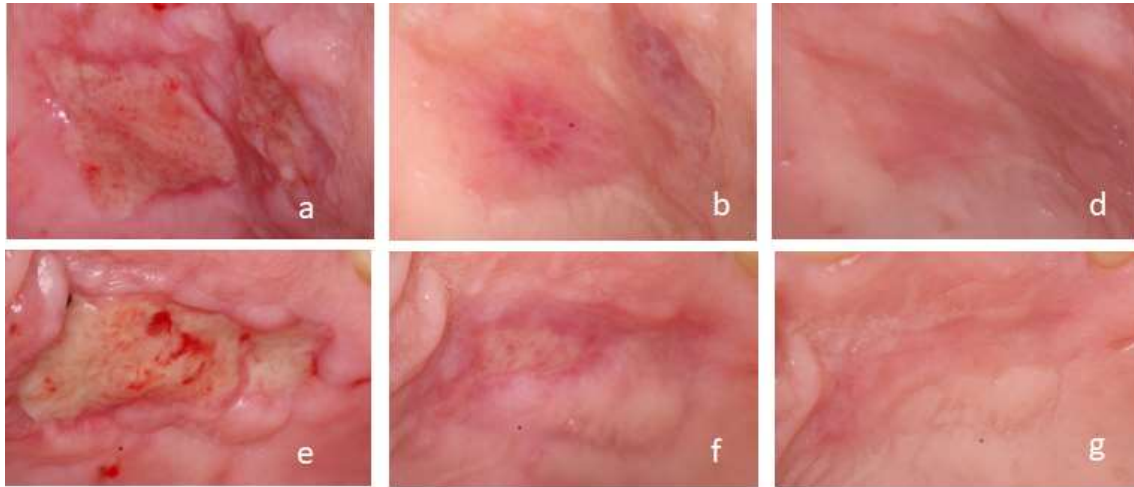
Source: Authors (2021).

All patients were instructed on post-operative care and were prescribed non-steroidal anti-inflammatory b.i.d. for 4 days. Patients were instructed to use analgesics if pain and to record the number of analgesics used during the first 7 days following surgery. The clinical aspect of the palate after 7 days observed in both cases consisted of a wound with slightly swollen edges and covered by granulation tissue with areas of epithelialization. Patients reported that NTS had fallen on the 5th and 6th day respectively, and the sutures were removed on the 7th day.

3. Results

No post-surgical complications, such as infection, tissue necrosis, or bleeding were reported. After 14 and 30 days, the healing process normally proceeded to complete wound resolution (Figure 2). At the reported level of pain, it was verified in the first 7 days that the visual analogue scale (VAS) questionnaire (ranging from 0, to no pain, to 10, to extreme pain) scored 3 in the first patient and 1 in the second. The amount of analgesics pills administered was 8 and 4 per patient, respectively, ingesting only in the first days after surgery.

Figure 2. A) and E) Palate healing after 7 days of graft removal. B) and F) Palate healing after 14 of graft removal. D) and G) Palate healing after 30 of graft removal.



Source: Authors (2021).

4. Discussion

With the increase in the demand for periodontal plastic surgeries and management of peri-implant tissue, there is a constant search for materials that can replace autogenous grafts, facilitating the procedures and reducing postoperative pain. Although many substitutes show optimal clinical application, xenogenic materials still present inferior results and higher costs compared to autogenous grafts. Because of that, the harvesting of palate soft tissue is still recommended.

Therefore, protective materials or dressings for palate wounds are studied to assist in the healing and post-surgical comfort of these patients. Among these materials, the oldest reports are about the use of surgical dressing, introduced in 1923 (Sachs, Farnoush, Checchi, & Joseph, 1984), and the modified Hawley plate (Farnoush, 1978). Both methods are mechanical and do not present any bioactive property that could aid in wound healing. Because of this, the objective of this case series is to bring a possible alternative to these approaches.

In this case series, the potential use of NTS as an occlusive biological dressing for palatal wounds was demonstrated during the healing process after the removal of autogenous grafts. This statement is corroborated by the results observed during the post-surgical process, with a low level of self-reported pain, low consumption of analgesics, no discomfort, no masticatory harm, and no clinical complications. These results are promising considering that the removal of the free gingival graft is often associated with an increase in the patient's degree of morbidity, with the possibility of postoperative bleeding, increased consumption of medications, and impairment of the patient's daily activities (Abraham, Vorrasi, & Kaplan, 2004; Al-Shibani, 2019; Tavelli et al., 2019; Yildirim et al., 2018).

Such benefits are probably related to the NTS type I collagen composition. Collagen is the main protein in the extracellular matrix, presenting low antigenicity, low inflammatory reaction, good biodegradability, and high rates of cell adhesion and proliferation (L. Sun et al., 2020). In the study by Shanmugam et al. (Shanmugam, Kumar, Arun, Arun, & Karthik, 2010), the effects of surgical and collagen dressings were compared. The results showed that collagen dressings accelerated wound healing and resulted in less morbidity than surgical dressing.

NTS present microscopic morphological characteristics similar to the structure of human skin, composed of long and organized compacted collagen fibers, high resistance, and extension to traction fracture (Alves, 2015), which is beneficial for its manipulation during the surgery, especially for the sutures. In addition, these properties contributed to the patients' comfort when reporting that the biomaterial did not interfere with daily activities.

5. Conclusions

As a conclusion of this case series, NTS appears to be a good occlusive biomaterial for the protection of palatal wounds after the removal of epithelized soft tissue grafts. Further studies must be carried out to improve the technique and to investigate the efficacy and the limitations of its use. For this, studies are carried out as randomized clinical trials testing other materials.

Acknowledgments

This study was financed in part by the Superior Brazilian Federal Agency for Support and Evaluation of Graduate Education - Brazil (CAPES) – Finance Code 001.

References

- Abraham, L. C., Vorrasi, J., & Kaplan, D. L. (2004). Impact of collagen structure on matrix trafficking by human fibroblasts. *J Biomed Mater Res A*, 70(1), 39-48. 10.1002/jbm.a.30057
- Al-Shibani, N. (2019). Low-intensity laser for harvesting palatal graft for the treatment of gingival recession: A systematic review. *J Investig Clin Dent*, 10(1), e12368. 10.1111/jicd.12368
- Alves, A. P. N. N., M. E. Q. L. Verde, A. E. C. Ferreira Júnior, P. G. B. Silva, V. P. Feitosa, E. M. L. Lima Júnior, M. J. B. Miranda and M. O. Moraes Filho. (2015). Avaliação microscópica, estudo histoquímico e análise de propriedades tensiométricas da pele de tilápia do Nilo. *Rev Bras Queimaduras* 14(3), 203-210.
- Chambrone, L., Chambrone, D., Pustiglioni, F. E., Chambrone, L. A., & Lima, L. A. (2008). Can subepithelial connective tissue grafts be considered the gold standard procedure in the treatment of Miller Class I and II recession-type defects? *J Dent*, 36(9), 659-671. 10.1016/j.jdent.2008.05.007
- Costa, B. A., Lima Junior, E. M., de Moraes Filho, M. O., Fachine, F. V., de Moraes, M. E. A., Silva Junior, F. R., . . . Rocha, M. B. S. (2019). Use of Tilapia Skin as a Xenograft for Pediatric Burn Treatment: A Case Report. *J Burn Care Res*, 40(5), 714-717. 10.1093/jbcr/irz085
- Dias, Mtpm, Bilhar, A. P. M., Rios, L. C., Costa, B. A., Duete, U. R., Lima Junior, E. M., . . . Bezerra, Lrps. (2019). Neovaginoplasty for radiation-induced vaginal stenosis using Nile Tilapia Fish Skin as a biological graft. *J Surg Case Rep*, 2019(11), rjz311. 10.1093/jscr/rjz311
- Dias, Mtpm, Bilhar, A. P. M., Rios, L. C., Costa, B. A., Lima Junior, E. M., Alves, Apnn, . . . Bezerra, Lrps. (2020). Neovaginoplasty Using Nile Tilapia Fish Skin as a New Biologic Graft in Patients with Mayer-Rokitansky-Kuster-Hauser Syndrome. *J Minim Invasive Gynecol*, 27(4), 966-972. 10.1016/j.jmig.2019.09.779
- Dorweiler, B., Trinh, T. T., Dunschede, F., Vahl, C. F., Debus, E. S., Storck, M., & Diener, H. (2018). The marine Omega3 wound matrix for treatment of complicated wounds: A multicenter experience report. *Gefasschirurgie*, 23(Suppl 2), 46-55. 10.1007/s00772-018-0428-2
- Farnoush, A. (1978). Techniques for the protection and coverage of the donor sites in free soft tissue grafts. *J Periodontol*, 49(8), 403-405. 10.1902/jop.1978.49.8.403
- Kaiser, D., Hafner, J., Mayer, D., French, L. E., & Lauchli, S. (2013). Alginate dressing and polyurethane film versus paraffin gauze in the treatment of split-thickness skin graft donor sites: a randomized controlled pilot study. *Adv Skin Wound Care*, 26(2), 67-73. 10.1097/01.ASW.0000426715.57540.8d
- Lima Junior, E. M., Picollo, N. S., Miranda, M. J. B., Ribeiro, W. L. C., Alves, A. P. N., Ferreira, G. E., & Moraes Filho, M. O. (2017). Uso da pele de tilápia (*Oreochromis niloticus*), como curativo biológico oclusivo, no tratamento de queimaduras. *Rev Bras Queimaduras*, 16(1), 10-17.
- Lima Junior, E. M., de Moraes Filho, M. O., Costa, B. A., Fachine, F. V., Rocha, M. B. S., Vale, M. L., & de Moraes, M. E. A. (2020). A Randomized Comparison Study of Lyophilized Nile Tilapia Skin and Silver-Impregnated Sodium Carboxymethylcellulose for the Treatment of Superficial Partial-Thickness Burns. *J Burn Care Res*. 10.1093/jbcr/iraa099
- Sachs, H. A., Farnoush, A., Checchi, L., & Joseph, C. E. (1984). Current status of periodontal dressings. *J Periodontol*, 55(12), 689-696. 10.1902/jop.1984.55.12.689
- Sanz, I., Garcia-Gargallo, M., Herrera, D., Martin, C., Figuero, E., & Sanz, M. (2012). Surgical protocols for early implant placement in post-extraction sockets: a systematic review. *Clin Oral Implants Res*, 23 Suppl 5, 67-79. 10.1111/j.1600-0501.2011.02339.x
- Shanmugam, M., Kumar, T. S., Arun, K. V., Arun, R., & Karthik, S. J. (2010). Clinical and histological evaluation of two dressing materials in the healing of palatal wounds. *J Indian Soc Periodontol*, 14(4), 241-244. 10.4103/0972-124X.76929
- Shayesteh, Y. S., Eshghyar, N., Moslemi, N., Dehghan, M. M., Motahary, P., Ghobadi, Z., & Golestan, B. (2012). The effect of platelet-rich plasma on healing of palatal donor site following connective tissue harvesting: a pilot study in dogs. *Clin Implant Dent Relat Res*, 14(3), 428-433. 10.1111/j.1708-8208.2009.00263.x
- Sullivan, H. C., & Atkins, J. H. (1969). The role of free gingival grafts in periodontal therapy. *Dent Clin North Am*, 13(1), 133-148.
- Sun, L., Li, B., Song, W., Zhang, K., Fan, Y., & Hou, H. (2020). Comprehensive assessment of Nile tilapia skin collagen sponges as hemostatic dressings. *Mater Sci Eng C Mater Biol Appl*, 109, 110532. 10.1016/j.msec.2019.110532

Sun, L., Li, B., Yao, D., Song, W., & Hou, H. (2018). Effects of cross-linking on mechanical, biological properties and biodegradation behavior of Nile tilapia skin collagen sponge as a biomedical material. *J Mech Behav Biomed Mater*, 80, 51-58.

Tavelli, L., Ravida, A., Saleh, M. H. A., Maska, B., Del Amo, F. S., Rasperini, G., & Wang, H. L. (2019). Pain perception following epithelialized gingival graft harvesting: a randomized clinical trial. *Clin Oral Investig*, 23(1), 459-468. 10.1007/s00784-018-2455-5

Yildirim, S., Ozener, H. O., Dogan, B., & Kuru, B. (2018). Effect of topically applied hyaluronic acid on pain and palatal epithelial wound healing: An examiner-masked, randomized, controlled clinical trial. *J Periodontol*, 89(1), 36-45. 10.1902/jop.2017.170105

Zucchelli, G., & Mounssif, I. (2015). Periodontal plastic surgery. *Periodontol 2000*, 68(1), 333-368. 10.1111/prd.12059

Zuhr, O., Baumer, D., & Hurzeler, M. (2014). The addition of soft tissue replacement grafts in plastic periodontal and implant surgery: critical elements in design and execution. *J Clin Periodontol*, 41 Suppl 15, S123-142. 10.1111/jcpe.12185