

## Pharmacognostic assessment and pre-clinical toxicity of ethanolic extract from *Aspidosperma subincanum* Mart. stem bark (Guatambu)

Avaliação farmacognóstica e toxicidade pré-clínica do extrato etanólico da casca do caule de *Aspidosperma subincanum* Mart. (Guatambu)

Evaluación farmacognóstica y toxicidad preclínica del extracto etanólico de la corteza del tallo de *Aspidosperma subincanum* Mart. (Guatambu)

Received: 06/25/2021 | Reviewed: 07/06/2021 | Accept: 07/13/2021 | Published: 07/23/2021

### **Nilda Maria Alves**

ORCID: <https://orcid.org/0000-0002-9451-5034>  
Universidade de Rio Verde, Brazil  
E-mail: [nilda@unirv.edu.br](mailto:nilda@unirv.edu.br)

### **Marina Alves Coelho Silva**

ORCID: <https://orcid.org/0000-0003-4325-7730>  
Universidade Federal de Goiás, Brazil  
E-mail: [marinalves.coelho@gmail.com](mailto:marinalves.coelho@gmail.com)

### **Leila Maria Leal Parente**

ORCID: <https://orcid.org/0000-0001-6259-6311>  
Universidade Federal de Goiás, Brazil  
E-mail: [sonhopetnatural@gmail.com](mailto:sonhopetnatural@gmail.com)

### **José Realino de Paula**

ORCID: <https://orcid.org/0000-0002-4424-7692>  
Universidade Federal de Goiás, Brazil  
E-mail: [pjrpaula@gmail.com](mailto:pjrpaula@gmail.com)

### **Alessandro de Carvalho Cruz**

ORCID: <https://orcid.org/0000-0002-8878-1678>  
Universidade Federal de Goiás, Brazil  
E-mail: [alessacruz@yahoo.com.br](mailto:alessacruz@yahoo.com.br)

### **Juliana Araújo Diniz**

ORCID: <https://orcid.org/0000-0002-1286-7301>  
Universidade Federal de Goiás, Brazil  
E-mail: [juju\\_jad@hotmail.com](mailto:juju_jad@hotmail.com)

### **Ruy de Souza Lino Júnior**

ORCID: <https://orcid.org/0000-0002-0572-5102>  
Universidade Federal de Goiás, Brazil  
E-mail: [ruylinojr@gmail.com](mailto:ruylinojr@gmail.com)

### **Dâmaris Silveira**

ORCID: <https://orcid.org/0000-0003-1851-5224>  
Universidade de Brasília, Brazil  
E-mail: [damaris@unb.br](mailto:damaris@unb.br)

### **Luiz Carlos da Cunha**

ORCID: <http://orcid.org/0000-0002-1525-8528>  
Universidade Federal de Goiás, Brazil  
E-mail: [lucacunha@gmail.com](mailto:lucacunha@gmail.com)

### **Abstract**

Ethnopharmacological relevance: *Diabetes mellitus* is a disease that affects approximately 10% of the world population. As it is a chronic disease, several patients search for alternatives to the traditional allopathic treatment, such as medicinal plants. In Brazil, the *Aspidosperma subincanum* (Guatambu) is one of the vegetal species commercialized in open markets used for diabetes popular treatment. *Objective*: To perform the phytochemical prospection and pre-clinical assessment of the ethanolic extract from stem bark of *A. subincanum* bark (EEAS). *Material and methods*: *A. subincanum* stem barks were collected in state of Goiás, Brazil and the EEAS was obtained by cold maceration. The phytochemical prospection was performed and acute and subacute toxicity assessments were performed according to OECD guidelines. *Results*: Phytochemical prospection identified the presence of steroids, triterpenes, saponins, tannins, alkaloids, coumarins, and

resins. The acute toxicity showed no death in EEAS doses administered intraperitoneally (500, 1000, and 2000 mg/kg) and orally (5000 mg/kg). The subacute toxicity showed signs of nephrotoxicity, hepatotoxicity, and lung damages in the two highest doses tested (250, 250 mg/kg) in a dose-dependent way. However, the satellite group showed reversion of the lesions after 30 days of EEAS interruption. Conclusion: The acute toxicity of EEAS suggests an  $LD_{50} > 5000$  mg/kg. The oral use of EEAS during a short period (30 days) or more can be hazardous at doses similar to that tested in this study and may represent a risk for those who consume this kind of extract as a medicinal plant.

**Keywords:** *Aspidosperma subincanum*; Diabetes; Toxicological assessment.

### Resumo

Relevância etnofarmacológica: *Diabetes mellitus* é uma doença que afeta aproximadamente 10% da população mundial. Por se tratar de uma doença crônica, diversos pacientes buscam alternativas ao tratamento alopático tradicional, como as plantas medicinais. No Brasil, *Aspidosperma subincanum* (Guatambu) é uma das espécies vegetais comercializadas em feiras livres para o tratamento popular de diabetes. Objetivo: Realizar a prospecção fitoquímica e avaliação pré-clínica do extrato etanólico da casca do caule de *A. subincanum* (EEAS). Material e métodos: As cascas de *A. subincanum* foram coletadas no estado de Goiás, Brasil e o EEAS foi obtido por maceração a frio. A prospecção fitoquímica foi avaliada e as avaliações de toxicidade aguda e subaguda foram realizadas de acordo com as diretrizes da OECD. Resultados: A prospecção fitoquímica identificou a presença de esteroides, triterpenos, saponinas, taninos, alcaloides, cumarinas e resinas. Não houve mortes no teste de toxicidade aguda em doses de EEAS administradas por via intraperitoneal (500, 1000 e 2000 mg/kg) e por via oral (5000 mg/kg). A toxicidade subaguda mostrou sinais de nefrotoxicidade, hepatotoxicidade e danos pulmonares de forma dose-dependente nas duas doses maiores doses testadas (250, 250 mg/kg). No entanto, o grupo satélite apresentou reversão das lesões após 30 dias da interrupção do EEAS. Conclusão: A toxicidade aguda de EEAS sugere um  $DL_{50} > 5.000$  mg/kg. O uso oral de EEAS por curto período (30 dias) ou mais pode ser perigoso em doses semelhantes àquelas testadas neste estudo e pode representar um risco para quem consome esse tipo de extrato como planta medicinal.

**Palavras-chave:** *Aspidosperma subincanum*; Diabetes; Avaliação toxicológica.

### Resumen

Relevancia etnofarmacológica: *Diabetes mellitus* es una enfermedad que afecta aproximadamente al 10% de la población mundial. Al tratarse de una enfermedad crónica, muchos pacientes buscan alternativas al tratamiento alopático tradicional, como las plantas medicinales. En Brasil, *Aspidosperma subincanum* (Guatambu) es una de las especies vegetales que se venden en los mercados abiertos para el tratamiento popular de la diabetes. Objetivo: Realizar la prospección fitoquímica y la evaluación preclínica del extracto etanólico de la corteza del tallo de *A. subincanum* (EEAS). Material y métodos: Las cortezas de *A. subincanum* se recolectaron en el estado de Goiás, Brasil y el EEAS se obtuvo mediante maceración en frío. Se evaluó el cribado fitoquímico y se realizaron evaluaciones de toxicidad aguda y subaguda de acuerdo con las directrices de la OECD. Resultados: La prospección fitoquímica identificó la presencia de esteroides, triterpenos, saponinas, taninos, alcaloides, cumarinas y resinas. No hubo muertes en la prueba de toxicidad aguda con dosis de EEAS administradas por vía intraperitoneal (500, 1000 y 2000 mg/kg) y por vía oral (5000 mg/kg). La toxicidad subaguda mostró signos de nefrotoxicidad, hepatotoxicidad y daño pulmonar de manera dependiente de la dosis a las dos dosis más altas probadas (250, 250 mg/kg). Sin embargo, el grupo satélite mostró reversión de las lesiones 30 días después de la interrupción del EEAS. Conclusión: La toxicidad aguda del EEAS sugiere una  $DL_{50} > 5000$  mg/kg. El uso oral del EEAS por un período corto (30 días) o más puede ser peligroso en dosis similares a las probadas en este estudio y puede representar un riesgo para quienes consumen este tipo de extracto como planta medicinal.

**Palabras clave:** *Aspidosperma subincanum*; Diabetes; Evaluación toxicológica.

## 1. Introduction

The World Health Organization (WHO) defines *Diabetes mellitus* (DM) as a group of diseases with diversified etiologies, characterized by carbohydrate metabolism alteration, which results in hyperglycemia in the absence of treatment (WHO, 2019). According to American Diabetes Association, DM is classified into four general categories: type 1 diabetes (due to autoimmune  $\beta$ -cell destruction), type 2 diabetes (due to a progressive loss of  $\beta$ -cell insulin secretion related to insulin resistance), gestational diabetes (GDM - it may occur during pregnancy), and the fourth group that includes other types of diabetes which occurs from other causes, both exogenous (drug, chemical, or infection-induced diabetes) and endogenous (pancreas alterations) (ADA, 2019).

In 2014 was estimated that 8.5% of the adult world population presented DM (WHO, 2019). In the last estimative for the global prevalence of diabetes, Brazil ranked in the eighth position (the year 2000) and is projected to be in the sixth position until

2030 (Wild et al., 2004). Data from the Brazilian Health Ministry and Integrated Health System indicate that complications associated with DM are responsible for 99% of premature deaths in the country (Rosa & Schmidt, 2008).

As diabetes is a chronic disease, several patients search for alternatives to traditional pharmacotherapy and often use medicinal plants to “*lower blood sugar*”, frequently resorting to the knowledge accumulated in their cultural and familial heritage or even by acquaintances’ indications. Ethnobotany and experimental studies report the use of plant species in the treatment of diabetes signs and symptoms, such as *Allium sativum* L. (Liliaceae), *Annona muricata* L. (Annonaceae), *Aspidosperma subincanum* Mart (Apocynaceae), *Momordica charantia* L. (Cucurbitaceae); *Bauhinia forticata* L. (Caesalpinaceae), *Cissus sicyoides* L. (Vitaceae) among others (Pinto et al., 2013; Rodrigues & Sobreira, 2020).

The plant species *A. subincanum*, popular known as “*guatambu*”, was reported as one of the medicinal plant popular used in the treatment of diabetes and is commercialized in avenues, open and municipal markets in the State of Goiás (Brazil) (Morais et al., 2005; Nogueira et al., 2013).

In the bark of *A. subincanum*, some phytochemicals as indolic alkaloids, saponins, terpenoids, steroids, tannins, oleic acid, and guatambuine were found (Santos et al., 2009). Spectrometric analyses indicated the presence of four alkaloids, subincanadines A and C, in butane-soluble fractions, and subincanadines D and F, in ethyl acetate-soluble fractions (Almeida et al., 2019).

Since medicinal plants to treat symptoms of diabetes are used for long periods, this study aimed to perform a phytochemical prospection and assess pre-clinical toxicity (acute and subacute) of *A. subincanum* bark ethanolic extract.

## 2. Material and methods

### 2.1 Plant material

The barks from *A. subincanum* were collected in Goiânia-Goiás, Brazil, with the owner’s consent, in August 2005. The Dr. Irani Fernandes Pereira Campos identified the plant material and a voucher specimen (n° UFG 21.147) was deposited at the herbarium of the Institute at the Federal University of Goiás (ICB/UFG).

Barks were dried in a forced ventilation oven at 40°C for 72 hours. Subsequently, they were ground in a cutting mill. The powder resulting from the grinding was stored in paper bags and packed in polyethylene bags.

### 2.2 Preparation of extract

The Laboratory of Research, Development, and Innovation of Bioproducts from the Faculty of Pharmacy at the Federal University of Goiás (Goiânia, Brazil) produced the extract. It was utilized 600g of the powder and added 95% ethanol with a proportion of 1:3 (p/v). The mixture was submitted to mechanical stirring for 4 hours, being later filtered through a qualitative filter paper. The dynamic maceration process was repeated three consecutive times.

The extractive solution was submitted to evaporation under vacuum at 40°C maximum until the removal of the solvent and obtaining of *A. subincanum* crude ethanolic extract (EEAS), which was solubilized in a saline solution and DMSO (Sinth®) to administer intraperitoneally (i.p.) and orally (p.o.) in the pre-clinical toxicity assessment.

## 2.3 Pharmacognostic studies

### 2.3.1 Macroscopic bark and powder microscopy analysis

Dried *A. subincanum* barks were analyzed regarding their general aspects, such as form, external and internal surface characteristics, and cross-section. Powder microscopy was also performed (Oliveira et al., 2005).

### 2.3.2 Phytochemical prospection

A powder sample of *A. subincanum* bark was submitted to phytochemical prospection tests. Heterosides anthraquinones, steroids, terpenoids, flavonoids, tannins, alkaloids, coumarins, and resins were analyzed by classical methods with modifications. Humidity, total, and insoluble ashes levels also were determined (Costa, 2001; Matos, 1988).

## 2.4 Pre-clinical toxicity

### 2.4.1 Animals

This study was approved by the Federal University of Goiás Ethics Committee (CEP/UFG) under protocol n° 292/2010. Non-isogenic adult male *Wistar* rats (*Rattus norvegicus*), was obtained from the Goiás State Chemical Industries Bioterium (IQUIGO) and the experimental study was conducted at the Faculty of Pharmacy Experimental Bioterium. The animals were under dark/light cycle – 12h/12h - with free access to filtered water, feed (Purina Labina®), and were submitted to acclimatization in polypropylene and room with a temperature of  $24 \pm 2$  °C for 1 week before treatment beginning.

### 2.4.2 Acute toxicity

The acute EEAS toxicity was performed based on guideline 423 of the Organization for Economic Cooperation and Development (OECD, 2001), with adaptations, and Ordinance 116/96 of the Brazilian Department of Health (ANVISA, 1996) was used.

The animals were separated into six exposure groups (n = 3). Five groups were exposed to EEAS solution by intraperitoneal route (i.p.) at different doses (500, 1000, 2000, 3000, and 5000 mg/kg of body weight (b.w.)) and the sixth group was treated with 5000 mg/kg b.w. of the same solution orally (p.o.). All rats were exposed only once.

After EEAS administration, the animals were continuously observed for three hours and then every hour for 24 hours to check any general behavior or physiological activities disorder.

The animals were assessed with the Hippocratic screening method, which verifies the effects produced by one unknown substance/extract on consciousness state, physical layout, motor system activity and coordination and muscular tonus, central and autonomic nervous system activity (Malone & Robichaud, 1962).

After 24 hours, the animals were anesthetized with a ketamine (Vetnil®) and xylazine (Agener União®) solution and were euthanized by cervical dislocation.

### 2.4.3 Subacute toxicity

The subacute EEAS toxicity was performed based on guideline 407 of the Organization for Economic Cooperation and Development (OECD, 1995), with adaptations and Ordinance 116/96 of the Brazilian Department of Health (ANVISA, 1996) was used.

The animals were individually allocated in metabolic cages and acclimated for a period of five days. They were randomly separated into five exposure groups (n = 8): control (vehicle: saline with DMSO), low (125 mg/kg b.w.), middle (250 mg/kg b.w.), high dose (500 mg/kg b.w) and satellite (500 mg/kg b.w) of EEAS administered orally by gavage.

Daily records for each animal were made regarding ingested water volume, consumed feed weight, excreted urine volume, and produced feces weight. The animals were weighed weekly to determine the body weight gain during the experimental period.

On the 31<sup>st</sup> day of exposure, all the rats, except the satellite group, were submitted to a 12-hour fasting period and anesthetized with a ketamine/xylazine (0.2 mL/100g b.w.; i.p.). Subsequently, the rats were submitted to blood collection by heart puncture to perform the hematological and biochemical exams and urine samples were collected for urinalysis. Finally, the animals were euthanized by cervical dislocation, followed by a macroscopic evaluation of organs and collection of material for histopathological evaluation: liver, kidneys, spleen, stomach, intestine, heart, and lung fragments were collected and fixed in 10% buffered formaldehyde solution. The fragments fixed were processed and stained with hematoxylin and eosin (HE).

The satellite group was carefully observed for an additional period of 30 days without the administration of EEAS, to analyze the reversible aspect and the persistence or occurrence of different toxic effects, after the last administration period of the treatment. After that, they were submitted to the same procedures described for the other groups.

Hematological exams were performed in total blood and included the analyses of total red blood cells, total and differential leucocytes, total platelet counts, and hemoglobin and hematocrit concentration. The following hematological indexes were determined: mean corpuscular volume (MCV), mean corpuscular hemoglobin (MCH), and mean corpuscular hemoglobin concentration (MCHC).

Biochemical exams were performed in blood plasma and consisted of total proteins, albumin, bilirubin, glucose, L-alanine-aminotransferase (ALT), L-aspartate-aminotransferase (AST), urea, creatinine, cholesterol, triglycerides and alkaline phosphatase (ALP), sodium, potassium, calcium, creatine phosphokinase (CPK), and alpha-amylase.

Urinalysis consisted of pH, urobilinogen, bilirubin, glucose, ketones, proteins, occult blood, creatinine, uric acid, and urea.

## 2.5 Statistical Analyses

Data were evaluated by variance analyses (ANOVA) one-way followed by Tukey's post hoc for data with normal distribution. Data were expressed as mean  $\pm$  SEM and were performed with GraphPad Prism 4.0 software, setting  $p < 0.05$  as statistically significant.

## 3. Results

### 3.1 Pharmacognostic tests

#### 3.1.1 Macroscopic analysis and powder microscopy

The external surface of dried *A. subincanum* bark presented brown suber with white plates, marked by longitudinal and transversal fissures. When suber was removed, the external surface presented greenish-yellow color constituting the bark. The internal surface presented a light color with yellowish tones, the fracture was extremely grained and fibrous internally. The cross-section presented light color with yellowish tones.

The observation of microscopy powder of *A. subincanum* bark showed lignified fiber fragments encased in a crystal sheath of prismatic crystals with gelatinous fiber fragments, few stone cells, and small, spherical, and isolated starch grains.

### 3.1.2 Phytochemical prospection

The phytochemical prospection performed in *A. subincanum* bark powder is shown in Table 1 and presented steroids, triterpenes, saponins, tannins, alkaloids, coumarins, and resins. Bark powder humidity level was 8.9%. The result obtained for total ashes was 9.35% and for insoluble ashes, 0.48%.

**Table 1.** Phytochemical prospection of *A. subincanum* bark powder.

Classes	Reactions	Results
Anthraquinone heterosides, Steroids, and Triterpenoids	Borntraeger	-
	Liebermann-Burchard	+
	Keller-Kiliani	-
Cardiotonic heterosides Phenolic compounds	Kedde	-
	FeCl <sub>3</sub>	-
	AlCl <sub>3</sub>	-
Flavonoids Saponins Tannins Alkaloids	Shinoda	-
	Oxaloboric	-
	Foam index	+
	Gelatin	+
	Dragendorff	+
	Metallic salts	+
Coumarins Resins	NaOH	+
	Intumescence factor	+

(-) absence; (+) presence. Source: Authors.

### 3.2 Acute toxicity

There were observed no deaths on animals exposed intraperitoneally to different doses of EEAS (500, 1000, and 2000 mg/kg). Regarding behavior, no significant differences were evidenced in the animals when evaluated through the Hippocratic screening method. The animals maintained consciousness, muscular tonus, and motor coordination within normality.

Considering that EEAS did not show toxicity from 500 to 2000 mg/kg b.w. acute exposure and according to OECD guideline 423, a second toxicity assessment was performed, with a dose 50% higher than that previously used (3000 mg/kg), by the same administration route (i.p.). Additionally, another dose 2.5 times higher (5000 mg/kg) was administered orally to another group of animals. The exposure to these doses by different routes also shown no deaths.

### 3.3 Subacute toxicity

The oral administration of EEAS in different doses (125, 250, and 500 mg/kg b.w.) for 30 days did not induce the occurrence of visible toxicity clinical signs in the animals. There were no significant differences in body mass gain, water consumption, feed consumption, and urine/feces production (data not shown).

The urinalysis of all treated groups presented normal aspects, there was no hemoglobin in the samples and the concentration of nitrites, glucose, ketone bodies, urobilinoglobulin, bilirubin, and crystals remained within reference values in all groups (data not shown). There were also no differences in color, pH, and density of the samples, however, there were significant increases in



leukocytes and proteins, as well, a significant decrease of epithelial cells in the EEAS high dose group (EEAS 500 mg/kg) compared to the control group (Table 2).

Regarding hematological parameters, there were no significant differences among the experimental groups as showing in Table 3).

**Table 2.** Urinalysis of Wistar rats treated for 30 days with different doses of EEAS by oral route.

	Dose (mg/group/day)			
	Control	EEAS 125mg/kg (Low dose)	EEAS 250mg/kg (Middle dose)	EEAS 500 mg/kg (High dose)
Density (mg/L)	1010.7 ± 3.4	1016 ± 8.2	1010 ± 7.1	1006.4 ± 3.7
pH	7.4 ± 0.4	7.1 ± 0.7	7.5 ± 0.288	7.5 ± 0.3
Proteins (g/dL)	147.14 ± 157	340 ± 219	382.5 ± 235	428.6 ± 188.98*
Epithelial cells (unit/ml)	5143 ± 2853.6	23600 ± 8385	19750 ± 18661	2728.6 ± 15217*
Leukocytes (unit/ml)	6714 ± 4347	4600 ± 2073.6	9750 ± 974.5	16000 ± 15000*
Red blood cells (unit/ml)	13857 ± 8802	25400 ± 8876.9	13250 ± 11814.5	20000 ± 17204.6

Data are expressed as mean ± SEM. N=8/group. Control: 5% DMSO in saline (10ml/kg); EEAS: ethanolic extract from *A. subincanum* bark. \*Statistically different from the control group (ANOVA, Tukey's post hoc test, p < 0.05). Source: Authors.

**Table 3.** Hematological parameters of Wistar rats treated for 30 days with different doses of EEAS by oral route.

	Dose (mg/group/day)				
	Control	EEAS 125mg/kg (Low dose)	EEAS 250mg/kg (Middle dose)	EEAS 500 mg/kg (High dose)	Satellite
RBC (10 <sup>6</sup> /mm <sup>3</sup> )	7.1 ± 0.4	6.9 ± 0.4	7.1 ± 0.3	6.9 ± 0.4	6.7 ± 0.5
Hematocrit (%)	38.6 ± 2.3	37.9 ± 2.2	38.2 ± 1.8	37.0 ± 1.9	39.4 ± 3.3
Hemoglobin (g/dL)	12.8 ± 0.8	12.7 ± 0.7	12.8 ± 0.5	12.4 ± 0.5	13.7 ± 1.2
MCV (ft)	53.9 ± 1.9	54.4 ± 2.4	53.8 ± 0.9	52.3 ± 2.8	58.0 ± 2.5*
MCH (pg)	18.1 ± 0.3	18.6 ± 0.4	18.0 ± 0.1	17.9 ± 0.4	20.5 ± 0.6*
MCHC (g/dL)	33.2 ± 0.3	33.6 ± 0.4	33.4 ± 0.4	33.5 ± 0.8	34.7 ± 0.5*
RDW (%)	13.3 ± 0.3	13.3 ± 0.3	13.2 ± 0.4	13.5 ± 0.6	13.6 ± 1.1
WBC (10 <sup>3</sup> /mm <sup>3</sup> )	6.4 ± 2.1	8.3 ± 1.2	7.3 ± 1.4	7.3 ± 1.8	7.1 ± 2.7
Neutrophils (%)	19.6 ± 4,3	16 ± 4.1	19.3 ± 4.3	15.7 ± 3.1	19.3 ± 6.1
Eosinophils (%)	0.6 ± 0.1	0.20 ± 0.4	1.5 ± 1.0	0.4 ± 0.5	0.8 ± 1.1
Lymphocytes (%)	71.3 ± 4.2	7.4 ± 3.7	69.8 ± 4.9	75.0 ± 3.4	73.5 ± 6.6
Monocytes (%)	8.5 ± 1.1	10.4 ± 1.8	9.3 ± 1.1	8.9 ± 2.0	6.7 ± 1.2*
Platelets (10 <sup>3</sup> /mm <sup>3</sup> )	609.9 ± 84.3	595.0 ± 29.1	659.0 ± 57.4	653.7 ± 35.1	550.2 ± 184.2

Data are expressed as mean ± SEM. N=8/group. Control: 5% DMSO in saline (10ml/kg); EEAS: ethanolic extract from *A. subincanum* bark. \*Statistically different from the control group (ANOVA, Tukey's post hoc test, p < 0.05). Source: Authors.

The biochemical parameters evaluated showed a significant increase in AST enzyme activity, in the satellite group (345.2 ± 60.9), compared with the control group (160 ± 46.2). It was also shown a significant decrease in plasma triglycerides concentration in EEAS high dose group (39.3 ± 3.7) and a significant increase in EEAS low dose (64 ± 1.5) and satellite groups (67.7 ± 7.9) compared to the control group (47 ± 5.4) (Table 4).

**Table 4.** Biochemical parameters of Wistar rats treated for 30 days with different doses of EEAS by oral route.

	Dose (mg/group/day)				Satellite
	Control	EEAS 125mg/kg (Low dose)	EEAS 250mg/kg (Middle dose)	EEAS 500 mg/kg (High dose)	
AST (U/L)	160 ± 46.2	156.6 ± 14.9	163.3 ± 17.7	138.0 ± 9.3	345.2 ± 60.9*
ALT (U/L)	103.7 ± 26.6	82.2 ± 3.3	77.6 ± 8.0	105 ± 20.2	92.2 ± 26.4
Creatinine (mg/dL)	0.6 ± 0	0.6 ± 0	0.6 ± 0	0.6 ± 0	0.6 ± 0.0
Urea (mg/dL)	51.9 ± 3.2	51.9 ± 4.5	56.2 ± 3.6	61.7 ± 3.2	55.3 ± 8.6
Cholesterol (mg/dL)	60 ± 1.7	66.2 ± 3.3	62.3 ± 6.0	59.8 ± 2.4	62.3 ± 3.0
Triglycerides (mg/dL)	47 ± 5.4	64 ± 1.5*	50.2 ± 4.2	39.3 ± 3.7*	67.7 ± 7.9*
Glycaemia (mg/dL)	162.9 ± 9.5	144 ± 8.9	144.3 ± 7.4	173.7 ± 17.2	218.3 ± 28.1
Total protein (g/dL)	6.3 ± 0.2	6.4 ± 0.2	6.4 ± 0.1	5.8 ± 0.1	5.3 ± 0.2
Albumin mg/dL)	3 ± 0	3.1 ± 0	2.9 ± 0.1	3.0 ± 0	2.8 ± 0.1
GGT (U/L)	7.6 ± 1.7	5 ± 1.7	5.2 ± 1.4	7.8 ± 3.6	4.5 ± 1.8

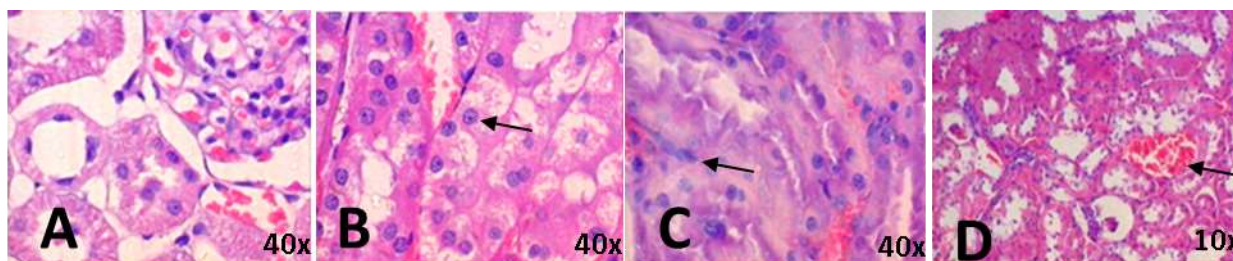
Data are expressed as mean ± SEM. N=8/group. Control: 5% DMSO in saline (10ml/kg); EEAS: ethanolic extract from *A. subincanum* bark. \*Statistically different from the control group (ANOVA, Tukey's post hoc test,  $p < 0.05$ ). Source: Authors.

### 3.4 Histopathological analysis

The histopathological evaluation of the control group demonstrated liver, kidney, spleen, stomach, intestine, heart, brain, and lung tissue integrity. However, the animals from the groups submitted to EEAS treatment showed pathological alterations in the kidneys, liver, and lungs.

In the kidneys of the animals treated with EEAS, it was identified tubular hyaline degeneration, presence of intra-tubular protein cylinders in the proximal convoluted tubules, and hydropic-vacuolar degeneration of epithelial cells of the distal convoluted tubules, processes evidenced by severe degeneration with nuclear pyknosis and cytoplasm disappearance (Figure 1). These findings were observed in the renal cortex, often associated with acute vascular congestion and interstitial hemorrhage. The renal medulla also presented intense congestion. Moreover, mainly the animals from EEAS middle dose (Figure 1C) and EEAS high dose (Figure 1D) presented tissue necrosis, demonstrating a dose-dependent toxic effect.

**Figure 1.** Kidney photomicrography of male Wistar rats treated orally with EEAS for 30 days. **A** - Control (5% DMSO in saline); **B** - EEAS 125 mg/kg (hydropic-vacuolar degeneration (arrow)); **C** - EEAS 250 mg/kg (hyaline degeneration (arrow)); **D** - EEAS 500 mg/kg (hemorrhage (arrow)). The images A, B, and C were taken at 40x magnification and the image D was taken at 10x magnification. HE staining.

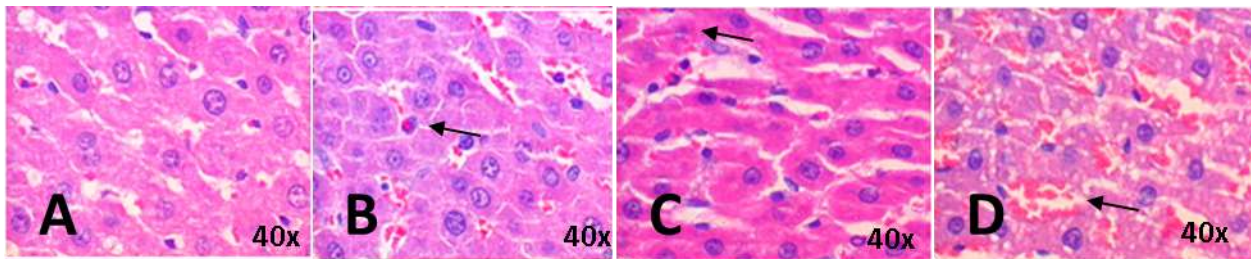


Source: Authors.



The liver tissue of the animals treated with the lowest dose exhibited an increased number of polymorphonuclear leukocytes inside the hepatic sinusoids (Figure 2B). The animals treated with EEAS middle and high doses showed congested vessels, multifocal necrosis, characterized by hepatocytes cariorexic and pyknotic nuclei (Figure 2C and 2D). In 25% of the animals from the high dose group, it was observed microvesicular steatosis and hepatic epithelial cords disorganization with an increase in sinusoidal space (Figure 2D).

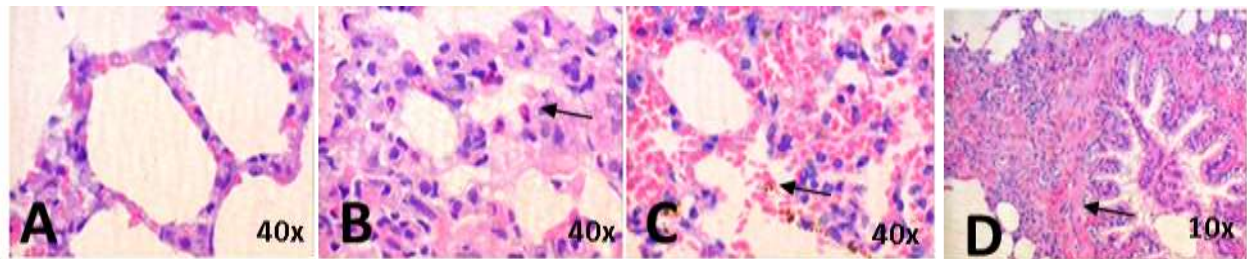
**Figure 2.** Liver photomicrography of male Wistar rats treated orally with EEAS for 30 days. **A** - Control (5% DMSO in saline); **B** - EEAS 125 mg/kg (intravascular and interstitial polymorphonuclear leukocytes (arrow)); **C** - EEAS 250 mg/kg (focal necrosis, with the presence of pyknotic nuclei (arrow)); **D** - EEAS 500 mg/kg (focal necrosis, hepatic steatosis and sinusoid congestion (arrow)). The images were taken at 40x magnification. HE staining.



Source: Authors.

The main microscopic lesions observed in the lungs of the animals from the groups treated with EEAS were interstitial infiltrate, intravascular accumulation of polymorphs (PMNs), chiefly neutrophils, and moderate periarterial and peribronchial fibrosis (Figure 3). These data suggest the presence of an inflammatory process.

**Figure 3.** Lung photomicrography of male Wistar rats treated orally with EEAS for 30 days. **A** - Control (5% DMSO in saline); **B** - EEAS 125 mg/kg (polymorphs (arrow)); **C** - EEAS 250 mg/kg (hemorrhage and hemosiderin (arrow)); **D** - EEAS 500 mg/kg (fibrosis (arrow)). The images A, B, and C were taken at 40x magnification and the image D was taken at 10x magnification. HE staining.



Source: Authors.

The histopathological analyses of the liver, kidneys, and lungs of the satellite group animals demonstrated normal tissue organization, suggesting that the degenerations caused by the subacute toxicity at the high dose are reversible after 30 days (data not shown). Therefore, it was demonstrated that exposure time is decisive for the extract toxicity manifestation, as well as, the administration interruption makes possible the reversion of toxicity symptoms.

#### 4. Discussion

Several plants are considered medicinal and, although their therapeutic activities and safety have not been proven yet, they have been widely used by populations around the world (Farzaei et al., 2020). Another worrisome factor related to the use of medicinal plants is the lack of pharmacobotany standardization. As quality and identification standards of a commercialized drug, pharmacognostic characterization and phytochemical triage may be used, allowing determining qualitatively the main groups of plant drug chemical compounds (Singh et al., 2017).

Regarding plant diagnosis, with the pharmacognostic assessment and the phytochemical prospection were found structures and compounds, which characterize the *A. subincanum* bark and may provide subsidies for quality control of this plant raw material.

The preclinical toxicity tests used to evaluate the safety of EEAS considered the animals' response by different routes of administration therefore two routes were tested in the acute toxicity test, intraperitoneal and oral. There were observed no deaths of rats up to 5000 mg/kg b.w. dose in these two administration routes, during 24 hours of observation. According to the guideline followed (OECD, 2001), a substance is considered practically non-toxic if it presents an LD<sub>50</sub> value above 2000 mg/kg or between 2000 and 5000 mg/kg. Therefore, considering this parameter, from the acute toxicity assessment results, EEAS was shown practically nontoxic.

In contrast with these results, a previous result performed with an ethanolic extract from the bark of *A. subincanum* (Santos et al., 2009), showed that doses up to 300 mg/kg did not cause any deaths in mice by intraperitoneal and oral route. However, toxic effects were observed from 500 mg/kg with severity in a dose-dependent manner until 100% death at the highest dose tested (2500 mg/kg by oral route). The authors concluded also that the extract was better absorbed by the intraperitoneal route than oral since the toxic effects were observed earlier with the lowest doses. Although these results differ considerably from those presented in this study, it can be argued that are metabolic differences between mice and rats, which may be related to these differences (Gannon et al., 2016).

The EEAS was also evaluated regarding the potential to promote injuries in rats after exposure to repeated doses for 30 days. The animals did not show evident clinical signs of toxicity and biochemical/hematological evaluation exhibited isolated changes that were inside the reference values and no treatment-related (Gonçalves et al., 2017; Spinelli et al., 2012). However, other evaluation parameters as urinalysis and histopathological assessment indicated renal, hepatic, and lung alterations.

Renal alterations were evidenced by the increased number of leukocytes and protein in the urine of the animals treated with the highest dose (500 mg/kg). Histopathological assessment data indicated renal tissue degeneration, acute vascular congestion, and interstitial hemorrhage. Additionally, in the groups with the highest doses, 250 mg/kg and 500 mg/kg, a necrotic process was observed. Regarding proteinuria as the first sign of renal disease, and that the presence of leukocytes may be related to glomerulonephritis or other renal diseases (Justiniano, 2012), it was demonstrated that EEAS presented a nephrotoxic effect when administered for a period of 30 consecutive days.

Nephrotoxins may cause chronic renal failure when there is progressive and irreversible nephron loss, and the renal interstitial lesion by drugs may also be involved in this process (Guyton & Hall, 2011). As renal lesions were reverted, which was observed in the satellite group, it is assumed that *A. subincanum* extract presented reversible nephrotoxicity when used for 30 consecutive days.

Liver assessments indicated an increase in aspartate aminotransferase (AST) enzyme activity in the satellite group. The initial phase of a hepatic lesion may be detected by the increase of hepatic enzyme levels in the blood. In hepatic congestion cases, AST level may be presented high, as well as other enzymes such as ALT and alkaline phosphatase. It is important to note that AST

is not a specific liver enzyme, as ALT, since it occurs in other locations in the organism, such as the myocardium, skeletal muscle, kidney, and brain (Willard & Twedt, 2012). Consequently, this isolated finding in the satellite group is not necessarily an indication of the hepatotoxic effect treatment-related.

The hepatic histopathological assessment showed both, the presence of polymorphonuclear leukocytes in hepatic sinusoids in the lowest dose (125 mg/kg) and congestion and necrosis in higher doses, including sinusoidal steatosis in the highest dose of EEAS (500 mg/kg). These results evidenced hepatic damage treatment-related by the presence of inflammatory process, triglycerides deposit in the hepatic sinusoids, indicating incapacity of hepatic elimination of the EEAS in the form of very-low-density lipoprotein (VLDL), which causes steatosis and hepatocyte destruction (McCullough, 2006). As well as the renal alterations, the hepatotoxic effects were reversed 30 days after extract administration suspension (satellite group).

The lungs tissues alterations were also dose-dependent, as in the kidneys and liver. The lowest dose of EEAS produced compatible effects with the inflammatory process, the low dose (250 mg/kg dose) promoted hemorrhage and hemosiderin, and the highest dose (500 mg/kg) presented fibrosis. Evolution of lung damage severity occurred, with an initial inflammatory process, hemorrhage by capillary fragility, accumulation of intra-alveolar hemosiderin, and substitution of lung tissue with fibrous tissue (Noble & Homer, 2004). Similar to the kidneys and the liver, toxicity signs were reversed in the satellite group.

These findings showed that EEAS may be a hazard in high doses, however, a previous study using lower doses of *A. subincanum* extract for 30 days (5 and 100 mg/kg), showed no signs of toxicity in the organ tissues (Santos et al., 2009). To date, a few studies were performed to test the biological activities of *A. subincanum in vivo*, and it is important to note that this plant species exhibited dose-dependent hypotensive effects in low doses (0.03 – 33 mg/kg) (Bernardes et al., 2013) and diuretic effects at 120 mg/kg dose (Ribeiro et al., 2015). These doses are below the risk range present in this study.

## 5. Conclusion

The pharmacognostic assessment and the phytochemical prospection of *A. subincanum* bark may provide a structural characterization of the species and contribute to quality control of this plant raw material.

The single dose of EEAS administered intraperitoneally or orally up to 5000 mg/kg dose, promoted no deaths in 24 hours, and was categorized as a low toxic substance presenting an LD<sub>50</sub> value above 5000 mg/kg.

The extract of *A. subincanum* (guatambu) bark administered orally in rats for 30 consecutive days presented nephrotoxic, hepatotoxic effects and transitory lung damage, in the two highest doses assessed by this study, which were reversed after suspending subacute administration of the extract. Thus, the use of EEAS during a short period (30 days) or more is not safe and may represent a risk for those who consume this kind of extract without caution.

## Acknowledgements

The authors thank to *Fundação de Amparo à Pesquisa do Estado de Goiás – FAPEG*, for financial support to conduct this study.

## References

- ADA. (2019). 2. Classification and Diagnosis of Diabetes: Standards of Medical Care in Diabetes—2019. In *Diabetes Care* (42, S13–S28). <https://doi.org/10.2337/dc19-S002>
- Almeida, V. L. de, Silva, C. G., Silva, A. F., Campana, P. R. V., Foubert, K., Lopes, J. C. D., & Pieters, L. (2019). *Aspidosperma* species: A review of their chemistry

and biological activities. *Journal of Ethnopharmacology*, 231, 125–140. <https://doi.org/10.1016/j.jep.2018.10.039>

ANVISA. (1996). *Normas para estudo de toxicidade e da eficácia de produtos naturais*. Ministério da Saúde - Secretária de Vigilância Sanitária, Brasília.

Bernardes, M. J. C., Carvalho, F. S. De, Lima Silveira, L., Paula, J. R. De, Bara, M. T. F., Garrote, C. F., Pedrino, G. R., & Rocha, M. L. (2013). Hypotensive effect of *Aspidosperma subincanum* Mart. in rats and its mechanism of vasorelaxation in isolated arteries. *Journal of Ethnopharmacology*, 145(1), 227–232. <https://doi.org/10.1016/j.jep.2012.10.057>

Costa, A. F. (2001). *Farmacognosia*. Fundação Calouste Gulbenkian.

Farzaei, M. H., Bayrami, Z., Farzaei, F., Aneva, I., Das, S. K., Patra, J. K., Das, G., & Abdollahi, M. (2020). Poisoning by medical plants. In *Archives of Iranian Medicine*.

Gannon, S. A., Fasano, W. J., Mawn, M. P., Nabb, D. L., Buck, R. C., Buxton, L. W., Jepson, G. W., & Frame, S. R. (2016). Absorption, distribution, metabolism, excretion, and kinetics of 2,3,3,3-tetrafluoro-2-(heptafluoropropoxy)propanoic acid ammonium salt following a single dose in rat, mouse, and cynomolgus monkey. *Toxicology*, 340, 1–9. <https://doi.org/10.1016/j.tox.2015.12.006>

Gonçalves, F. C., Lima Junior, C. Q. de, Gomes, C. M., Blanch, G. T., Costa, S. H. N., & Penna, K. G. D. (2017). Parâmetros hematológicos e bioquímicos de ratos wistar provenientes do biotério da PUC-Goiás. *Revista da Sociedade Brasileira de Ciência em Animais de Laboratório*, 5(2), 123–133.

Guyton, A. C., & Hall, J. E. (2011). *Tratado de Fisiologia Médica*.

Justiniano, A. N. (2012). *Interpretação de exames laboratoriais para o fisioterapeuta*.

Malone, M. H., & Robichaud, R. C. (1962). A hippocratic screen for pure or crude drug materials. *Lloydia*.

Matos, F. J. A. (1988). *Introdução à fitoquímica experimental*. Imprensa Universitária da Universidade Federal do Ceará, Fortaleza.

McCullough, A. J. (2006). Pathophysiology of nonalcoholic steatohepatitis. *Journal of Clinical Gastroenterology*, 40 Suppl 1, S17-29. <https://doi.org/10.1097/01.mcg.0000168645.86658.22>

Morais, I. C., Silva, L. D. G., Ferreira, H. D., Paula, J. R., & Tresvenzol, L. M. F. (2005). Levantamento sobre plantas medicinais comercializadas em Goiânia: abordagem popular (raizeiros) e abordagem científica (levantamento bibliográfico). *Revista Eletrônica de Farmácia*, 2(1), 13–16. <https://doi.org/10.5216/ref.v2i2.1961>

Noble, P. W., & Homer, R. J. (2004). Idiopathic pulmonary fibrosis: new insights into pathogenesis. *Clinics in Chest Medicine*, 25(4), 749–758. <https://doi.org/10.1016/j.ccm.2004.04.003>

Nogueira, J. C. M., Oliveira, S. M. de, Oliveira, A. L. R. de, & Moraes, S. R. P. de. (2013). Levantamento De Uso Popular de plantas medicinais no município de niquelândia - GO. *Enciclopédia Biosfera*, 9(16), 2583–2597.

OECD. (1995). *Guideline 407: Repeated Dose 28-day Oral Toxicity Study in Rodent*. Head of Publications.

OECD. (2001). Test No. 423: Acute Oral toxicity - Acute Toxic Class Method. *Oecd Guideline for Testing of Chemicals, December*, 1–14. <https://doi.org/10.1787/9789264071001-en>

Oliveira, F., Akisue, G., & Akisue, M. K. (2005). *Farmacognosia*.

Pinto, A. Z. de L., de Assis, A. F. S., Pereira, A. G., & Pasa, M. C. (2013). Levantamento Etnobotânico De Plantas Medicinais Comercializadas No Mercado Do Porto Em Cuiabá, Mato Grosso, Brasil. *Boletim Do Grupo de Pesquisa Da Flora, Vegetação e Etnobotânica*, 1(5), 51–70. <http://periodicoscientificos.ufmt.br/index.php/flovet/article/view/1529/1202>

Ribeiro, E. F., De Fátima Reis, C., De Carvalho, F. S., Abreu, J. P. S., Arruda, A. F., Garrote, C. F. D., & Rocha, M. L. (2015). Diuretic effects and urinary electrolyte excretion induced by *Aspidosperma subincanum* Mart. and the involvement of prostaglandins in such effects. *Journal of Ethnopharmacology*, 163, 142–148. <https://doi.org/10.1016/j.jep.2015.01.023>

Rodrigues, L. da S., & Sobreira, I. E. M. M. (2020). Uso de plantas medicinais por adultos diabéticos e/ou hipertensos de uma unidade básica de saúde do município de Caucaia-CE, Brasil. *Revista Fitos*, 14(3), 341–354. <https://doi.org/10.32712/2446-4775.2019.812>

Rosa, R. dos S., & Schmidt, M. I. (2008). Diabetes mellitus: magnitude das hospitalizações na rede pública do Brasil, 1999-2001. *Epidemiologia e Serviços de Saúde*, 17(2), 131–134. <https://doi.org/10.5123/S1679-49742008000200009>

Santos, S. R., Rangel, E. T., Lima, J. C. S., Silva, R. M., Lopes, L., Noldin, V. F., Cechinel Filho, V., Delle Monache, F., & Martins, D. T. D. O. (2009). Toxicological and phytochemical studies of *Aspidosperma subincanum* Mart. stem bark (Guatambu). *Pharmazie*, 64(12), 836–839. <https://doi.org/10.1691/ph.2009.9639>

Singh, D., Pannu, M., Nama, K., Baghel, U., & Yadav, R. (2017). Pharmacognostic evaluation of stem bark and leaves of *Anogeissus pendula* Edgew. *Ancient Science of Life*, 37(1), 239. [https://doi.org/10.4103/asl.asl\\_33\\_17](https://doi.org/10.4103/asl.asl_33_17)

Spinelli, M. O., Junqueira, M. D. S., & Bortolato, J. (2012). *Perfil bioquímico dos animais de laboratório do Biotério da Faculdade de Medicina USP*. 1(1): 76–81. WHO. (2019). Classification of Diabetes Mellitus. In WHO (Ed.), *Classification of Diabetes Mellitus*. 21, 36. Jaypee Brothers Medical Publishers (P) Ltd. [https://doi.org/10.5005/jp/books/12855\\_84](https://doi.org/10.5005/jp/books/12855_84)

Wild, S., Roglic, G., Green, A., Sicree, R., & King, H. (2004). Estimates for the year 2000 and projections for 2030. *Diabetes Care*, 27(5), 1047–1053.

Willard, M. D., & Twedt, D. C. (2012). Gastrointestinal, Pancreatic, and Hepatic Disorders. In *Small Animal Clinical Diagnosis by Laboratory Methods*. 51, 191–225. Elsevier. <https://doi.org/10.1016/B978-1-4377-0657-4.00009-0>