

## **Minimizing the compensatory effects of the Class III malocclusion orthodontic treatment with Biofunctional preadjusted prescription – Case report**

**Minimizando os efeitos do tratamento ortodôntico compensatório da má-oclusão de Classe III com a prescrição pré-ajustada Biofuncional – Relato de caso**

**Minimización de los efectos compensatorios del tratamiento ortodôntico de maloclusión de classe III com prescripción preajustada Biofuncional – Reporte de caso**

Received: 07/06/2021 | Reviewed: 07/13/2021 | Accept: 07/27/2021 | Published: 08/03/2021

### **Wilton Souza Rêgo Netto**

ORCID: <https://orcid.org/0000-0002-5599-8811>  
Inga University Center, Brazil  
E-mail: [Wiltonok@hotmail.com](mailto:Wiltonok@hotmail.com)

### **Raquel Amarante**

ORCID: <https://orcid.org/0000-0002-6176-3656>  
IOPG Dental School, Brazil  
E-mail: [raquelamarante@gmail.com](mailto:raquelamarante@gmail.com)

### **Roberto Grec**

ORCID: <https://orcid.org/0000-0002-7914-1337>  
IOPG Dental School, Brazil  
E-mail: [grec@gmail.com](mailto:grec@gmail.com)

### **Ricardo Cesar Gobbi de Oliveira**

ORCID: <https://orcid.org/0000-0002-0725-2337>  
Inga University Center, Brazil  
E-mail: [rcgobbi@gmail.com](mailto:rcgobbi@gmail.com)

### **Renata Cristina Gobbi de Oliveira**

ORCID: <https://orcid.org/0000-0002-9629-9283>  
Inga University Center, Brazil  
E-mail: [recgo@hotmail.com](mailto:recgo@hotmail.com)

### **Fabrcio Pinelli Valarelli**

ORCID: <https://orcid.org/0000-0002-4285-486X>  
Inga University Center, Brazil  
E-mail: [fabriciovalarelli@gmail.com](mailto:fabriciovalarelli@gmail.com)

### **Karina Maria Salvatore de Freitas**

ORCID: <https://orcid.org/0000-0001-9145-6334>  
Inga University Center, Brazil  
E-mail: [ksmf@uol.com.br](mailto:ksmf@uol.com.br)

### **Paula Cotrin**

ORCID: <https://orcid.org/0000-0002-6230-0522>  
Inga University Center, Brazil  
E-mail: [cotrin@hotmail.com](mailto:cotrin@hotmail.com)

### **Abstract**

**Introduction:** Class III malocclusion has skeletal and dental components that can often impair the patient's facial appearance. Its treatment may involve orthognathic surgery or compensatory orthodontics. **Case report:** This case report presents a Class III malocclusion compensatory orthodontic treatment performed with the Biofunctional prescription brackets. Biofunctional prescription presents a torque value of 0° for the maxillary incisors and +10° for the mandibular incisors, which counteracts to the side effects of the use of Class III intermaxillary elastics, minimizing it, providing a more stable, aesthetic and with a healthier periodontal occlusion. **Conclusion:** The Class III malocclusion compensatory orthodontic treatment performed with Biofunctional prescription obtains satisfactory results, even depending on the patient collaboration with the use of intermaxillary elastics.

**Keywords:** Malocclusion; Angle Class III; Orthodontics corrective; Torque.

### **Resumo**

**Introdução:** A má-oclusão de Classe III possui componentes esqueléticos e dentários que geralmente podem piorar a aparência facial do paciente. Seu tratamento pode envolver cirurgia ortognática ou ortodontia compensatória. **Relato de caso:** Este relato de caso apresenta o tratamento ortodôntico compensatório de uma má-oclusão de Classe III feito com bráquetes com prescrição Biofuncional. Esta prescrição apresenta um valor de 0° para os incisivos superiores e

+10° para os incisivos inferiores, os quais neutralizam os efeitos colaterais do uso dos elásticos intermaxilares de Classe III, minimizando-os, promovendo uma oclusão mais estável, estética e com um periodonto mais saudável. Conclusão: O tratamento ortodôntico compensatório da má-oclusão de Classe III com a prescrição biofuncional obtém resultados satisfatórios, mesmo que dependente da colaboração dos pacientes com o uso dos elásticos intermaxilares.

**Palavras-chave:** Má-oclusão; Classe III de Angle; Ortodontia corretiva; Torque.

### Resumen

Introducción: La maloclusión de clase III tiene componentes esqueléticos y dentales que generalmente pueden empeorar la apariencia facial del paciente. Su tratamiento puede incluir cirugía ortognática u ortodoncia compensatoria. Caso clínico: Este caso clínico presenta el tratamiento de ortodoncia compensatoria de una maloclusión Clase III realizado con brackets con prescripción Biofuncional. Esta prescripción tiene un valor de 0 ° para los incisivos superiores y + 10 ° para los inferiores, que neutralizan los efectos secundarios del uso de elásticos intermaxilares Clase III, minimizándolos, promoviendo una oclusión estética más estable y con más periodonto. sano. Conclusión: El tratamiento de ortodoncia compensatoria de la maloclusión Clase III con prescripción biofuncional obtiene resultados satisfactorios, aunque dependa de la cooperación de los pacientes con el uso de elásticos intermaxilares.

**Palabras clave:** Maloclusión; Angle Class III; Ortodoncia correctiva; Torque.

## 1. Introduction

There are various combinations of dental and skeletal components that can be involved in the Class III malocclusion etiology.(Ellis & McNamara, 1984) The skeletal Class III malocclusion is characterized by a sagittal discrepancy, which may involve deficiency and/or a backward position of the maxilla, or by prognathism and/or forward position of the mandible.(Battagel, 1993; Chang, Kinoshita, & Kawamoto, 1992; Creekmore, 1978; Ellis & McNamara, 1984; Guyer, Ellis, McNamara, & Behrents, 1986; Perrone & Mucha, 2009; Proffit, Fields, & Sarver, 2014) Although class III malocclusion is not the most frequent malocclusion in the population, (Almeida et al., 2020; Garbin et al. 2021) the treatment for this malocclusion is a challenge to all orthodontists. because Its success is related to the patient's growth, mainly related to the mandible's growth, which exceeds that of the maxilla.(Guyer et al., 1986)

The timing of orthodontic treatment for Class III malocclusion is crucial for a successful outcome. Some authors(Battagel, 1993; Campbell, 1983; Chang et al., 1992; Toffol, Pavoni, Baccetti, Franchi, & Cozza, 2008) rely that the orthodontic treatment should be performed as soon as possible, however, there is lack of evidence on long-term benefits.(Woon & Thiruvengatchari, 2017) After the end of the patient's growth, the orthodontic treatment of the skeletal Class III malocclusion can be performed according to two different protocols: surgical-orthodontic treatment or orthodontic camouflage treatment.(Proffit et al., 2014; Tseng et al., 2011) Some patients do not accept surgical-orthodontic treatment for personal reasons, opting for orthodontic camouflage treatment, which may also present good results.(Janson et al., 2005; Stellzig-Eisenhauer, Lux, & Schuster, 2002; Tseng et al., 2011; Valarelli, Nascimento, Batista, Freitas, & Cancado, 2018)

The camouflage orthodontic treatment in adult patients involves the use of intermaxillary elastics. Class III elastics for dental compensations leads to a labial inclination in the maxillary incisors, a retroclination in the mandibular incisors, extrusion and a mesial tipping in the maxillary molars and counterclockwise rotation of the occlusal plane.(Janson et al., 2005; Lin & Gu, 2003)

The Roth prescription is one of the most used in orthodontics.(Keim, Gottlieb, Nelson, & Vogels, 2008) This preadjusted prescription presents a crown torque value of +12°, +8° and -2° in the maxillary central incisors, lateral incisors and canines, respectively. It also presents an angulations value of +5°, +9° and +13° in the maxillary central incisors, lateral incisors and canines, respectively. Besides that, mandibular incisors present zero torque and angulations values.(Feres, Mazzeiro, & Landre Jr, 2009) Biofunctional prescription is another option among orthodontics accessories. It presents a torque value of 0° for the maxillary incisors and +10° for the mandibular incisors.(Alves, 2003) These differences in torques produce contraposition of the Class III elastics side effects (proclination of maxillary incisors and retroclination of mandibular

incisors) leading to a better orthodontic treatment finishing. (Cancado, De Freitas, Valarelli, Vieira Bda, & Neves, 2015; Janson et al., 2005; Valarelli et al., 2018)

The aim of this case report is to describe a compensatory Class III malocclusion treatment whose Class III elastics side effects were minimized with the use of Biofunctional prescription of brackets.

## 2. Methodology

### Diagnosis and Treatment Plan

A 13-year-old female patient presented to IOPG Dental School with chief complaint of her smile. On clinical examination she showed a horizontal growth pattern, passive lip sealing and a slightly concave profile (Figure 1).

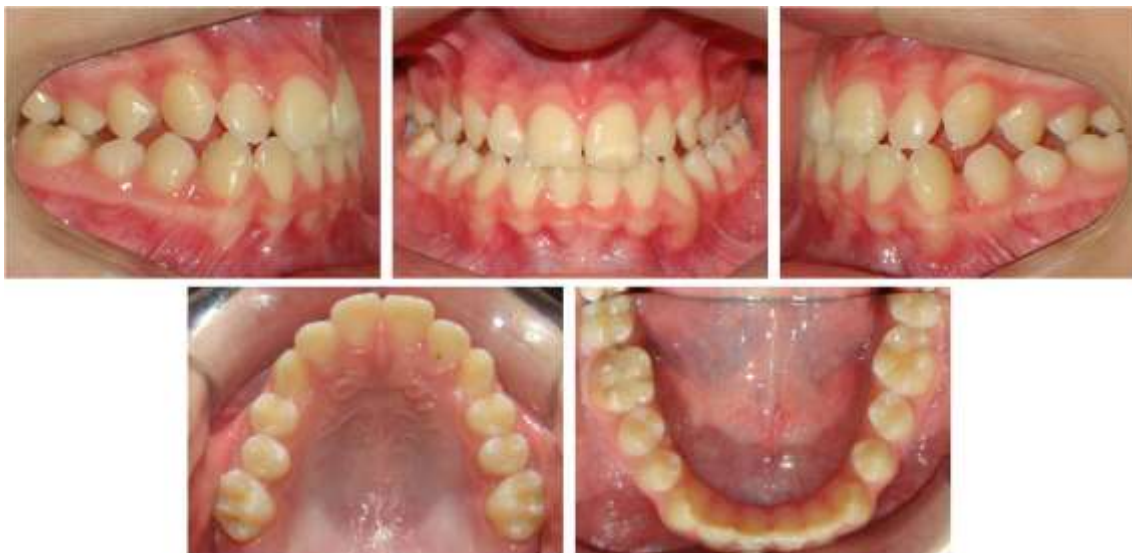**Figure 1:** Pre-treatment facial photographs.



Source: Authors.

Intraoral examination revealed a  $\frac{1}{2}$  cusp Class III malocclusion relationship in the both sides and also posterior bilateral crossbite and open bite. The patient had enamel hypoplasia in the maxillary central incisors, in the right maxillary canine and in the right first mandibular molar (Figure 2).

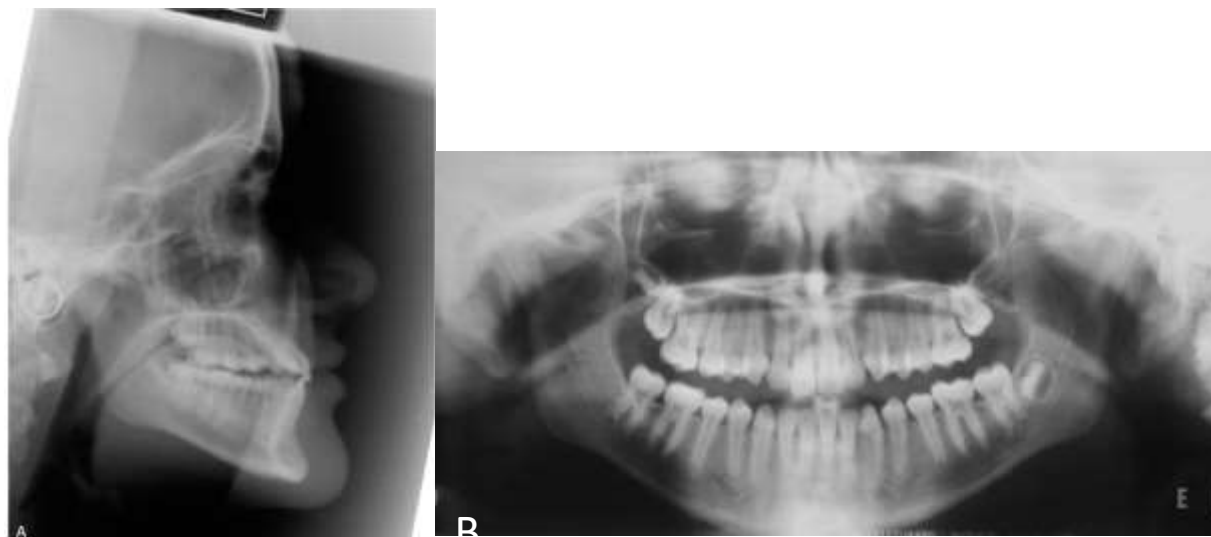
**Figure 2:** Pre-treatment intraoral photographs.



Source: Authors.

In the radiographs, it could be observed that all dental elements were presents, except for the maxillary left third molar germ and mandibular right third molar, who were congenitally missing. The other structures presented normal aspect (Figure 3).

**Figure 3:** Pre-treatment radiographs.



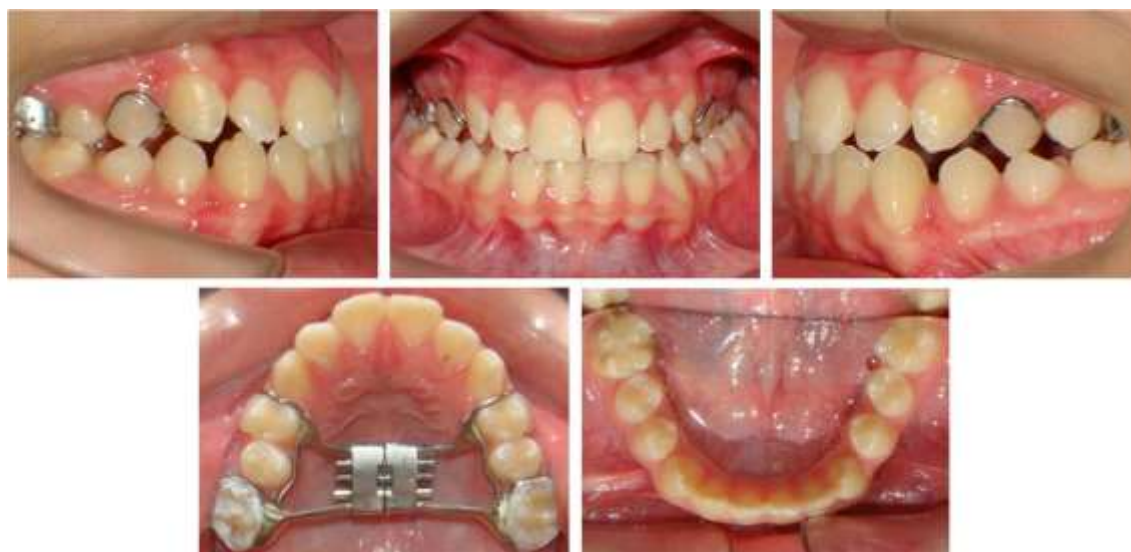Source: Authors.

The following treatment alternatives were presented to the patient: 1) Surgical-orthodontic. The patient had skeletal Class III malocclusion and bilateral posterior crossbite, so, the best option was the surgical correction of these skeletal discrepancies. However, for personal reasons and because the patient still shows some remaining growth this option was discarded by the parents. The second option was the compensatory orthodontic treatment, with a maxillary orthopedic expansion and Class III malocclusion camouflage with Biofunctional prescription.

### **Treatment progress**

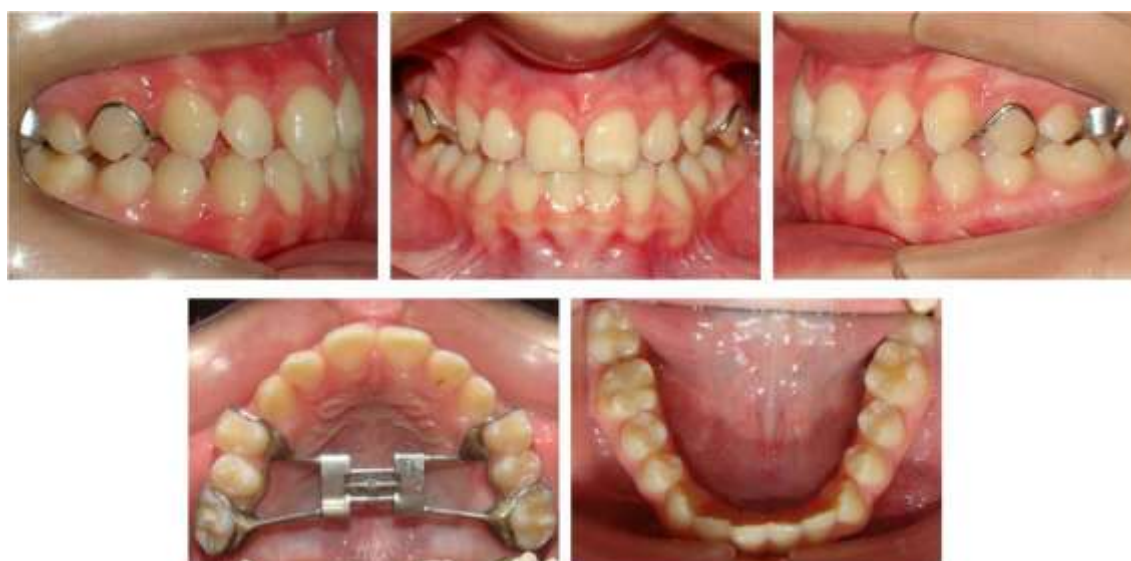Initially, a Hyrax maxillary expander was bonded to perform a rapid maxillary expansion to correct the posterior bilateral crossbite (Figure 4). The Hyrax protocol of activation was as follows: a complete turn on the hyrax screw on the day of installation, and from the second day, 1/4 turn in the morning and 1/4 at night until the opening of the diastema between the maxillary central incisors( or until the palatal cusp of the maxillary first molar contacts the buccal cusp of the mandibular first molar). Once the palatal cusp of maxillary first molar contacted the surface of mandibular first molar cusp, the hyrax screw was locked with a tie wire, leaving the device itself as a retainer for 4 months. After four months it could be observed the crossbite correction (Figure 5)

**Figure 4:** Hyrax maxillary expander.



Source: Authors.

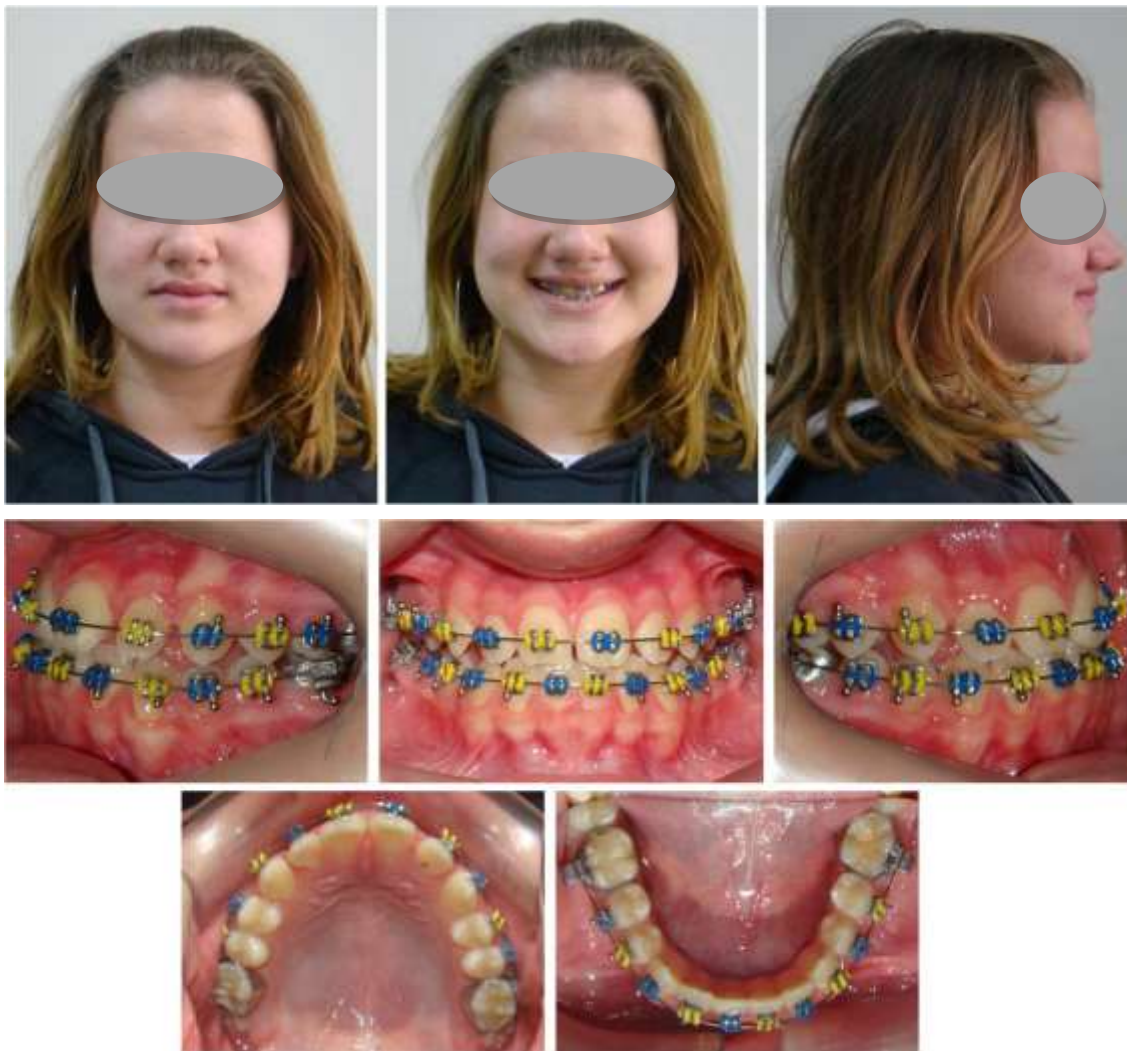**Figure 5:** Crossbite correction.



Source: Authors.

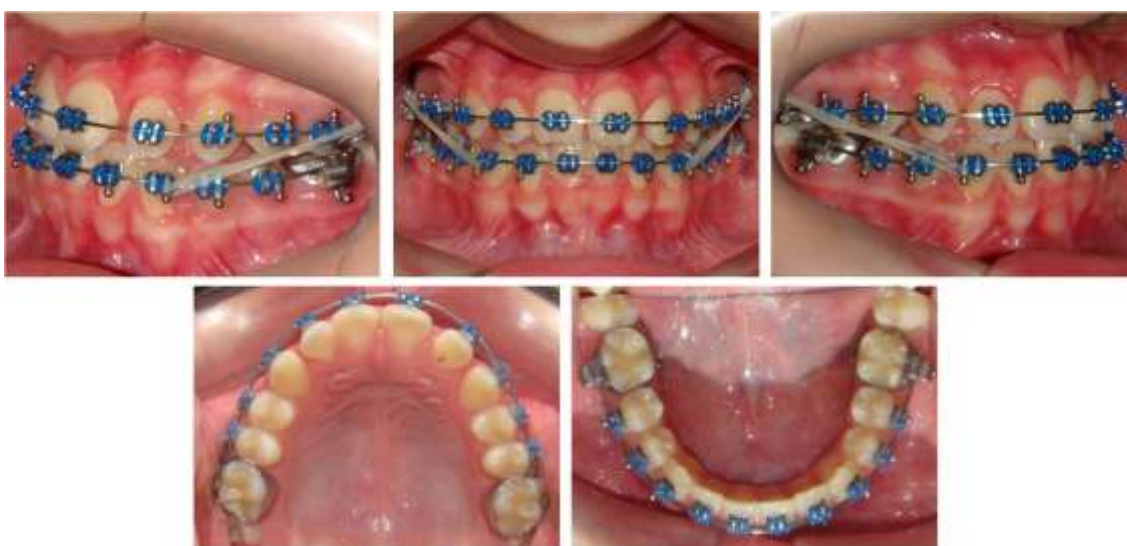After four months, Hyrax expander was removed and a 0.022-in Biofunctional (Morelli®, Sorocaba, SP Brazil) prescription multibracket appliance was bonded and a .012-in round nickel titanium archwire was placed (Figure 6), followed by 0.014-in and 0.016-in round NiTi archwires. Comprehensive orthodontic treatment was performed, with leveling and alignment. After 8 months, 0.019 x 0.025-in NiTi archwires were placed and the patient began to use Class III elastics (3/16-in diameter, 4.58oz). The measurement of the delivered force was performed with a dynamometer. At the first month, the elastics were used just during all night and, from the second month, they were used for 24 hours/day, to correct the Class III malocclusion (Figure 7).

**Figure 6:** 0.022-in Biofunctional prescription multibracket appliance



Source: Authors.

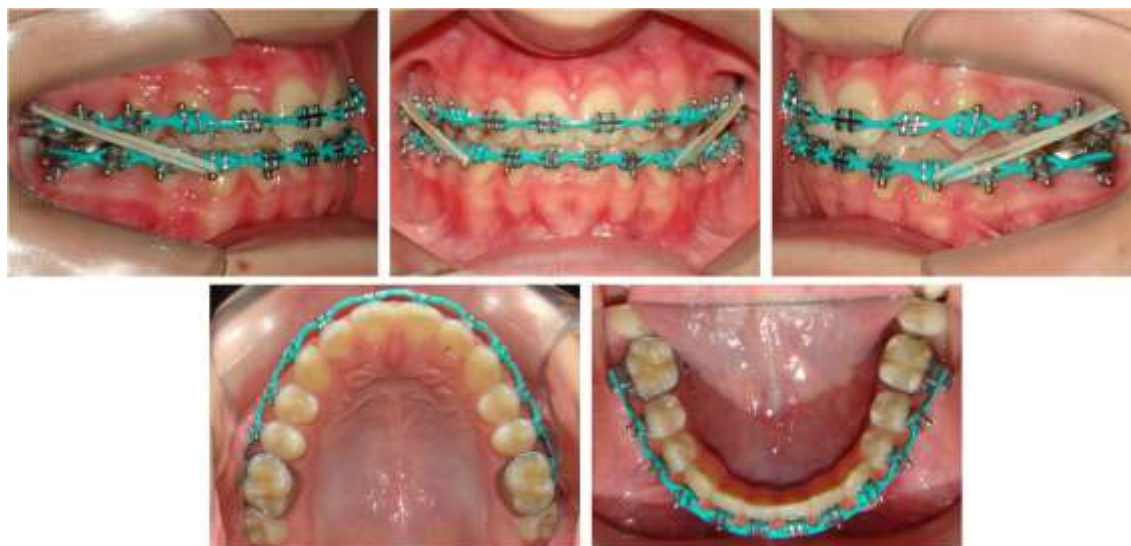**Figure 7:** Intermaxillary Class III elastics.



Source: Authors.

When all teeth were leveled and aligned, ideal 0.019 x 0.025-in stainless steel archwires and elastic chains medium size were placed in both arches (Figure 8). The elastic chains were useful to close the existing spaces that were associated with the use of intermaxillary elastics. Class III elastic was used until the end of the treatment.

**Figure. 8:** Elastomeric chains.



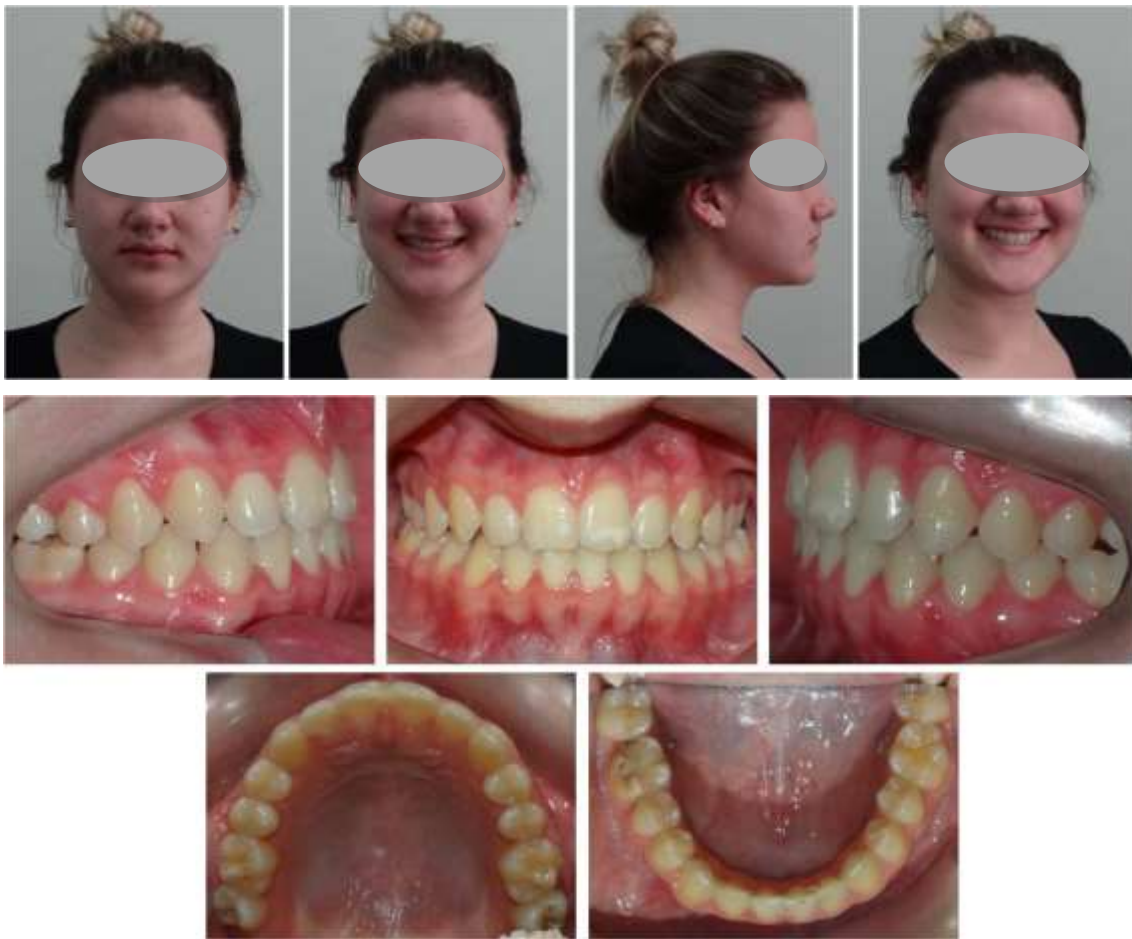Source: Authors.

### 3. Results and Discussion

#### Treatment results

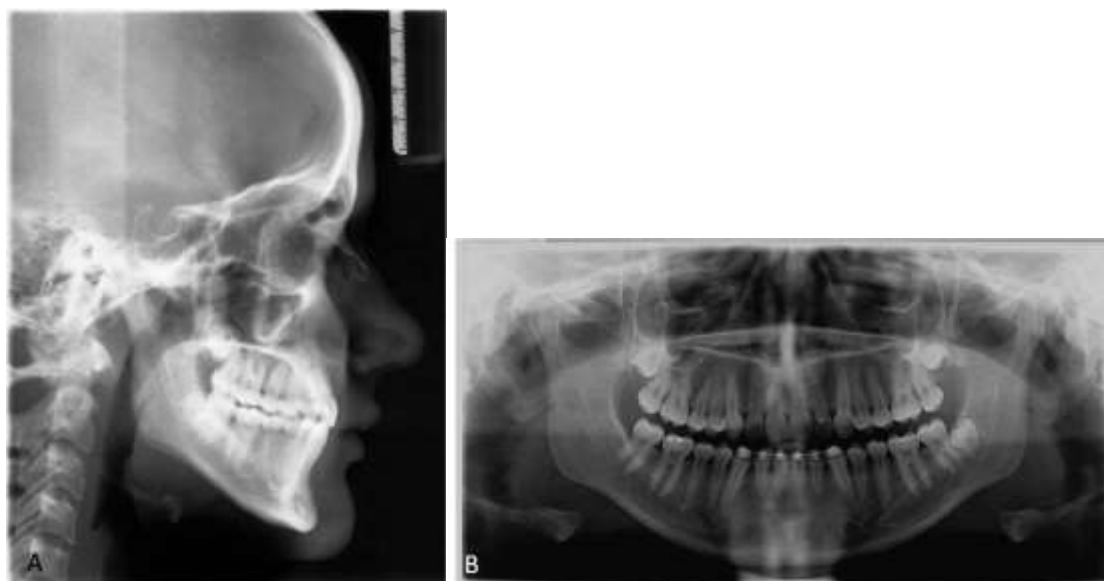
Post-treatment data showed an improved facial profile and Class I canine relationships in both sides. Besides that, it could be observed as well as satisfactory dental alignment and good overjet and overbite. In addition, an acceptable nasolabial angle and buccal corridor were also achieved (Figure 9 and Table). No root resorption was observed at posttreatment (Figure10).

**Figure. 9:** Facial and intraoral posttreatment photographs



Source: Authors.

**Figure. 10:** Posttreatment radiographs.



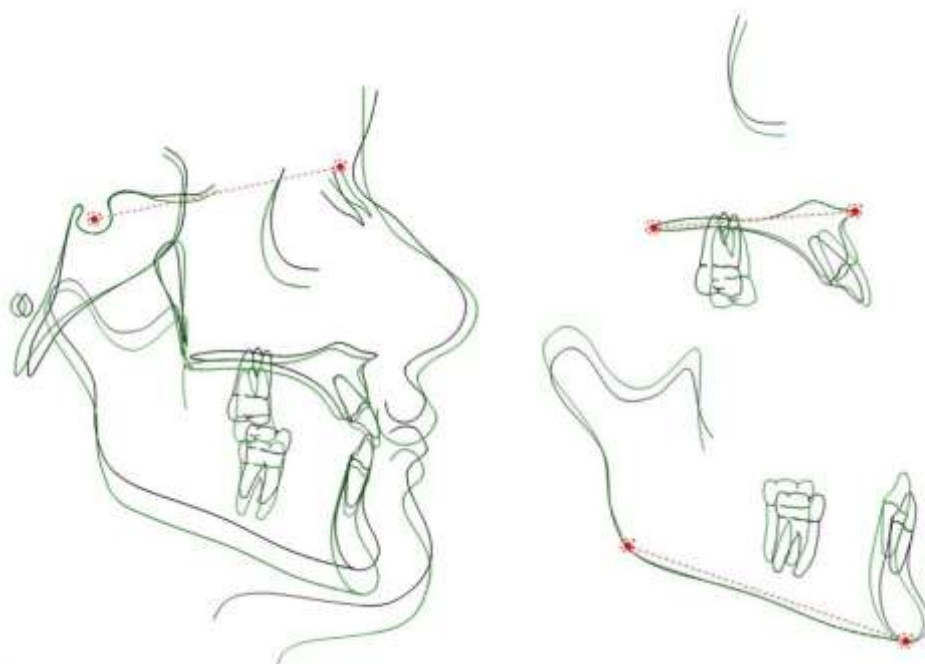
Source: Authors.



The final cephalometric tracing and superimposition showed that the skeletal discrepancy in the sagittal dimension was improved compared with initial measures (Table). In addition, the vertical pattern did not show significant changes during treatment time, but it could be observed a slightly counterclockwise rotation in the occlusal plane.

In the maxillary dentoalveolar component incisors were protruded, slightly extruded and showed similar inclination of the beginning of the treatment. Molars were displaced mesially, extruded and tipped mesially (Table I and Figure 11).

**Figure. 11:** Pretreatment and posttreatment superimposition.



Source: Authors.

The mandibular incisors were extruded and slightly lingual tipped. The mandibular molar was displaced mesially, extruded and slightly tipped distally (Table I and Figure 11).

There was an improvement in dental relationships. The upper lip was protruded and lower lip was retracted which led to an improvement in facial convexity.

## Discussion

Sometimes patients presenting skeletal Class III malocclusion is not willing to undergo orthognathic surgery for personal reasons, like financial costs and surgical risks, or even by being satisfied with their facial appearance. (Bailey, Haltiwanger, Blakey, & Proffit, 2001) These patients end up calling on compensatory orthodontic treatment, also known as orthodontic camouflage treatment.(Burns et al., 2010)

The compensatory treatment is usually performed with the use of Class III intermaxillary elastics and Roth prescription multibracket appliance. Roth prescription presents the following crown torque value:  $+12^\circ$  in maxillary central incisors;  $+8^\circ$  in the maxillary lateral incisors and zero torque value in the mandibular incisors. These torques values together with the effect of Class III intermaxillary elastics promote greater labial inclination of the maxillary incisors and lingual inclination of the mandibular incisors, which may compromise the smile's aesthetics.(Cancado et al., 2015; Janson et al., 2005; Valarelli et al., 2018) According to Alves(Alves, 2003), Biofunctional prescription is an important choice to perform a Class III camouflage treatment. Biofunctional prescription presents 0 torque value in the maxillary incisors and  $+10^\circ$  crown torque

value in the mandibular incisors. These torques values counteract the side effects of the intermaxillary Class III elastics, minimizing the compensatory movements of the mandibular incisors.

In the compensatory orthodontic treatment, proclination of the maxillary incisors and flattening of the occlusal plane contributed to a positive overjet, helping to correct the Class III malocclusion.(Cai, Zhao, & Xiang, 2014; Hu et al., 2012; Kim, Kim, Yu, & Baik, 2014; Nakamura et al., 2017) In this case report, maxillary incisors were uprighted and protruded, which contributed to a more harmonious smile. This happened due to the zero torque that Biofunctional prescription presents in the maxillary incisors, which counteracted the labial tipping effects produced by the Class III elastics. However, some authors(Cai et al., 2014; Hu et al., 2012; Nakamura et al., 2017) found different results in their compensatory orthodontic treatment, where the maxillary incisors were protruded and labial tipped. Mandibular incisors were extruded and slightly lingual tipped. Mandibular incisors in the Biofunctional prescription presents a crown torque value of  $+10^\circ$ , counteracting the Class III elastics effects, reducing the excessive lingual tipping. This would work as a resistant labial crown torque.(Cancado et al., 2015; Janson et al., 2005; Janson, De Souza, Barros, Andrade Junior, & Nakamura, 2009; Valarelli et al., 2018) Some authors(Cai et al., 2014; Goldin, 1989; Janson et al., 2005; Wainwright, 1973) state that controlling the mandibular incisors lingual tipping may induce a greater alveolar bone remodeling response and additionally promoting a body movement of the mandibular incisors. Due to these, compensatory orthodontic treatment with Biofunctional prescription makes the smile more aesthetic besides causing a lower biological cost to the patient (Janson et al., 2009).

#### 4. Conclusion

The Class III malocclusion compensatory orthodontic treatment performed with Biofunctional prescription obtains satisfactory results, even depending on the patient collaboration with the use of intermaxillary elastics. The incisors are in a more appropriate position than with other prescriptions, which leads to a more stable, aesthetic and with a healthier periodontal occlusion.

#### References

- Almeida, M. C, Cotrin, P., Valarelli, F. P., Cançado, R. H., Oliveira, R. C. G., Oliveira, R. C. G., & Freitas, K. M. S. (2020). Comparison of the population characteristics in 3 Brazilian regions. *Res Soc Dev*, 9(10).
- Alves, F. (2003). *Orthodontics: biofunctional therapy*. Editora Santos.
- Bailey, L. J., Haltiwanger, L. H., Blakey, G. H., & Proffit, W. R. (2001). Who seeks surgical-orthodontic treatment: a current review. *Int J Adult Orthodon Orthognath Surg*, 16(4), 280-292.
- Battagel, J. M. (1993). The aetiological factors in Class III malocclusion. *Eur J Orthod*, 15(5), 347-370.
- Burns, N. R., Musich, D. R., Martin, C., Razmus, T., Gunel, E., & Ngan, P. (2010). Class III camouflage treatment: what are the limits? *Am J Orthod Dentofacial Orthop*, 137(1), 9 e1-9 e13; discussion 19-11. 10.1016/j.ajodo.2009.05.017
- Cai, B., Zhao, X. G., & Xiang, L. S. (2014). Orthodontic decompensation and correction of skeletal Class III malocclusion with gradual dentoalveolar remodeling in a growing patient. *Am J Orthod Dentofacial Orthop*, 145(3), 367-380. 10.1016/j.ajodo.2013.04.026
- Campbell, P. M. (1983). The dilemma of Class III treatment. Early or late? *Angle Orthod*, 53(3), 175-191. 10.1043/0003-3219(1983)053<0175:TDOCIT>2.0.CO;2
- Cancado, R. H., De Freitas, K. M., Valarelli, F. P., Vieira Bda, S., & Neves, L. S. (2015). Treatment of Skeletal Class III Malocclusion with the Biofunctional System. *J Clin Orthod*, 49(11), 717-725.
- Chang, H. P., Kinoshita, Z., & Kawamoto, T. (1992). Craniofacial pattern of Class III deciduous dentition. *Angle Orthod*, 62(2), 139-144. 10.1043/0003-3219(1992)062<0139:CPOCID>2.0.CO;2
- Creekmore, T. D. (1978). Class III treatment planning. *J Clin Orthod*, 12(9), 650-655.
- Ellis, E., 3rd, & McNamara, J. A., Jr. (1984). Components of adult Class III malocclusion. *J Oral Maxillofac Surg*, 42(5), 295-305.

- Feres, M. F. N., Mazzeiro, E., & Landre Jr, J. (2009). Estudo comparativo de diferentes prescrições de bráquetes pré-ajustados em modelos virtuais pelo Método de Elementos Finitos. *Rev Dent Press Ortodon Ortop Facial*, 14(4), 53-65.
- Garbin, A. J. I., Garbin, C. A. S., Chiba, F. Y., Saliba, T. A., Moimaz, S. A. S. & Chiba, E. K. (2021). Oclusopatias e necessidade de tratamento em adolescentes de 12 anos de idade. *Res Soc Dev*, 10 (2).
- Goldin, B. (1989). Labial root torque: effect on the maxilla and incisor root apex. *Am J Orthod Dentofacial Orthop*, 95(3), 208-219.
- Guyer, E. C., Ellis, E. E., 3rd, McNamara, J. A., Jr., & Behrents, R. G. (1986). Components of class III malocclusion in juveniles and adolescents. *Angle Orthod*, 56(1), 7-30. 10.1043/0003-3219(1986)056<0007:COCIMI>2.0.CO;2
- Hu, H., Chen, J., Guo, J., Li, F., Liu, Z., He, S., & Zou, S. (2012). Distalization of the mandibular dentition of an adult with a skeletal Class III malocclusion. *Am J Orthod Dentofacial Orthop*, 142(6), 854-862. 10.1016/j.ajodo.2011.03.030
- Janson, G., de Souza, J. E., Alves Fde, A., Andrade, P., Jr., Nakamura, A., de Freitas, M. R., & Henriques, J. F. (2005). Extreme dentoalveolar compensation in the treatment of Class III malocclusion. *Am J Orthod Dentofacial Orthop*, 128(6), 787-794. 10.1016/j.ajodo.2004.08.018
- Janson, G., De Souza, J. E., Barros, S. E., Andrade Junior, P., & Nakamura, A. Y. (2009). Orthodontic treatment alternative to a class III subdivision malocclusion. *J Appl Oral Sci*, 17(4), 354-363.
- Keim, R. G., Gottlieb, E. L., Nelson, A. H., & Vogels, D. S., 3rd. (2008). 2008 JCO Study of Orthodontic Diagnosis and Treatment Procedures. Part 2: breakdowns of selected variables. *J Clin Orthod*, 42(12), 699-710; quiz 727.
- Kim, S. J., Kim, K. H., Yu, H. S., & Baik, H. S. (2014). Dentoalveolar compensation according to skeletal discrepancy and overjet in skeletal Class III patients. *Am J Orthod Dentofacial Orthop*, 145(3), 317-324. 10.1016/j.ajodo.2013.11.014
- Lin, J., & Gu, Y. (2003). Preliminary investigation of nonsurgical treatment of severe skeletal Class III malocclusion in the permanent dentition. *Angle Orthod*, 73(4), 401-410. 10.1043/0003-3219(2003)073<0401:PIONTO>2.0.CO;2
- Nakamura, M., Kawanabe, N., Kataoka, T., Murakami, T., Yamashiro, T., & Kamioka, H. (2017). Comparative evaluation of treatment outcomes between temporary anchorage devices and Class III elastics in Class III malocclusions. *Am J Orthod Dentofacial Orthop*, 151(6), 1116-1124. 10.1016/j.ajodo.2016.10.040
- Perrone, A. P. R., & Mucha, J. N. (2009). O tratamento da Classe III-revisão sistemática-Parte I. Magnitude, direção e duração das forças na protração maxilar. *Revista Dental Press de Ortodontia e Ortopedia Facial*, 14(5).
- Proffit, W. R., Fields, H. W., & Sarver, D. M. (2014). Contemporary orthodontics: Elsevier Health Sciences.
- Stellzig-Eisenhauer, A., Lux, C. J., & Schuster, G. (2002). Treatment decision in adult patients with Class III malocclusion: orthodontic therapy or orthognathic surgery? *Am J Orthod Dentofacial Orthop*, 122(1), 27-37; discussion 37-28.
- Toffol, L. D., Pavoni, C., Baccetti, T., Franchi, L., & Cozza, P. (2008). Orthopedic treatment outcomes in Class III malocclusion. A systematic review. *Angle Orthod*, 78(3), 561-573. 10.2319/030207-108.1
- Tseng, Y. C., Pan, C. Y., Chou, S. T., Liao, C. Y., Lai, S. T., Chen, C. M., . . . Yang, Y. H. (2011). Treatment of adult Class III malocclusions with orthodontic therapy or orthognathic surgery: receiver operating characteristic analysis. *Am J Orthod Dentofacial Orthop*, 139(5), e485-493. 10.1016/j.ajodo.2010.12.014
- Valarelli, F. P., Nascimento, F. E. C., Batista, D. M., Freitas, K. M. S., & Cancado, R. H. (2018). Class III camouflage treatment with the Biofunctional technique. *J Clin Orthod*, 52(6-7), 351-358.
- Wainwright, W. M. (1973). Faciolingual tooth movement: its influence on the root and cortical plate. *Am J Orthod*, 64(3), 278-302.
- Woon, S. C., & Thiruvengatchari, B. (2017). Early orthodontic treatment for Class III malocclusion: A systematic review and meta-analysis. *Am J Orthod Dentofacial Orthop*, 151(1), 28-52. 10.1016/j.ajodo.2016.07.017