

Systemic implications of metallic foreign body syndrome in dairy cattle

Implicações sistêmicas da síndrome de corpo estranho metálico em gado leiteiro

Implicaciones sistémicas del síndrome de cuerpo extraño metálico en ganado lechero

Received: 08/16/2021 | Reviewed: 08/25/2021 | Accept: 09/06/2021 | Published: 09/07/2021

Regina Nobrega de Assis

ORCID: <https://orcid.org/0000-0002-8174-2158>
Federal Rural University of Pernambuco, Brazil
E-mail: reginanobregadeassis@gmail.com

Leonardo Magno de Souza

ORCID: <https://orcid.org/0000-0001-6978-8359>
Federal Rural University of Pernambuco, Brazil
E-mail: leonardomagnovet@hotmail.com

Glíere Silmara Leite Soares

ORCID: <https://orcid.org/0000-0003-1488-0523>
Federal Rural University of Pernambuco, Brazil
E-mail: glieresilmara@hotmail.com

Jobson Filipe de Paula Cajueiro

ORCID: <https://orcid.org/0000-0003-3228-2383>
Federal Rural University of Pernambuco, Brazil
E-mail: jobson.filipe@gmail.com

Rodolfo José Cavalcanti Souto

ORCID: <https://orcid.org/0000-0003-3380-5596>
Federal Rural University of Pernambuco, Brazil
E-mail: Rodolfo.souto@hotmail.com

José Augusto Bastos Afonso

ORCID: <https://orcid.org/0000-0002-6558-644X>
Federal Rural University of Pernambuco, Brazil
E-mail: afonsojab@gmail.com

Carla Lopes de Mendonça

ORCID: <https://orcid.org/0000-0002-4985-4985>
Federal Rural University of Pernambuco, Brazil
E-mail: carlalopes.mendonca@gmail.com

Abstract

This study aimed to evaluate the systemic implications of 37 cattle with traumatic reticulitis, evaluating clinical, laboratory, ultrasonographic and necroscopic changes. A clinical, laboratory and ultrasonographic examination was performed, and the animals were distributed in reticuloperitonitis (GI; n=21) and reticulopericarditis (GII; n=16) traumatic, based on necropsy findings. Blood samples were taken for haematological tests, serum total protein, albumin, globulin, gamma glutamyltransferase (GGT), aspartate aminotransferase (AST), glutamate dehydrogenase (GLDH), creatinine, urea, cortisol, creatine kinase (CK), creatine kinase-MB (CK-MB), cardiac troponin-I (cTn-I), plasma glucose and L-lactate. The abdominocentesis was productive in eight GI (n=8) and seven GII (n=7) animals, allowing the evaluation of physical, cytological and biochemical characteristics of the peritoneal fluid as a total protein, albumin, GLDH, AST, GGT, glucose and L-lactate. Changes in behavior, appetite, dehydration and temperature were observed, most expressive in GII. Hematology showed neutrophilic leukocytosis with regenerative left shift and hyperfibrinogenemia in both groups. Increased globulin, L-lactate concentration and serum GGT, GLDH, CK and CK-MB activity were observed, as well as significant elevation of cTnI (p=0.0190) in GII. In the peritoneal fluid exudate was observed in both groups and a higher concentration of L-lactate in relation to plasma. Ultrasound revealed reticular, cardiac, hepatic and splenic abnormalities. The anatomopathological lesions confirmed the ultrasound findings of both groups. The understanding of the syndrome helps in the diagnosis, as well as the adoption of preventive measures, minimizing the economic impact caused to the dairy cattle breeding.

Keywords: Clinical biochemistry; Dairy cattle; Hardware disease; Peritoneal fluid; Ultrasonography.

Resumo

Este estudo teve como objetivo avaliar as implicações sistêmicas em 37 bovinos com reticulite traumática, analisando alterações clínicas, laboratoriais, ultrassonográficas e necroscópicas. Foi realizado exame clínico, laboratorial e ultrassonográfico, sendo os animais distribuídos, de acordo com o diagnóstico em reticuloperitonite (GI; n=21) e reticulopericardite (GII; n=16) traumática, com base nos achados de necropsia. Amostras de sangue foram coletadas para exames hematológicos, proteína sérica total, albumina, globulina, gama glutamiltransferase (GGT), aspartato

aminotransferase (AST), glutamato desidrogenase (GLDH), creatinina, ureia, cortisol, creatina quinase MB (CK), creatina quinase MB (CK-MB), troponina-I cardíaca (cTn-I), glicose e L-lactato plasmáticos. A abdominocentese foi produtiva em oito animais no GI e em sete no GII, permitindo a avaliação das características físicas, citológicas e bioquímicas do líquido peritoneal como proteína total, albumina, GLDH, AST, GGT, glicose e L-lactato. Foram observadas mudanças de comportamento, apetite, desidratação e temperatura, mais expressivas no GII. As análises hematológicas mostraram leucocitose neutrofílica com desvio à esquerda regenerativo e hiperfibrinogenemia em ambos os grupos. Observou-se aumento da globulina, da concentração de L-lactato e da atividade sérica da GGT, GLDH, CK e CK-MB, além de elevação significativa da cTnI ($p=0,0190$) no GII. No líquido peritoneal, observou-se exsudato em ambos os grupos e maior concentração de L-lactato em relação ao plasma. A ultrassonografia revelou anormalidades reticulares, cardíacas, hepáticas e esplênicas. As lesões anatomopatológicas confirmaram os achados ultrassonográficos de ambos os grupos. A compreensão da síndrome auxilia no diagnóstico, bem como na adoção de medidas preventivas, minimizando o impacto econômico causado à pecuária leiteira.

Palavras-chave: Bioquímica clínica; Doença de hardware; Fluido peritoneal; Gado leiteiro; Ultrassonografia.

Resumen

Este estudio tuvo como objetivo evaluar las implicaciones sistémicas de 37 bovinos con reticulitis traumática, analizando cambios clínicos, de laboratorio, ecográficos y necroscópicos. Se realizaron exámenes clínicos, de laboratorio y ecográficos, y los animales se distribuyeron en reticuloperitonitis (GI; $n = 21$) y reticulopericarditis traumática (GII; $n = 16$), según los hallazgos de la necropsia. Se recolectaron muestras de sangre para pruebas hematológicas, proteína sérica total, albúmina, globulina, gamma glutamiltransferasa (GGT), aspartato aminotransferasa (AST), glutamato deshidrogenasa (GLDH), creatinina, urea, cortisol, creatina quinasa MB (CK), creatina quinasa MB (CK-MB), troponina-I cardíaca (cTn-I), glucosa plasmática y L-lactato. La abdominocentesis fue productiva en ocho animales GI ($n=8$) y siete GII ($n=7$), permitiendo la evaluación de las características físicas, citológicas y bioquímicas del líquido peritoneal como proteína total, albúmina, GLDH, AST, GGT, glucosa y L-lactato. Se observaron cambios de comportamiento, apetito, deshidratación y temperatura, que fueron más expresivos en GII. La hematología mostró leucocitosis neutrofílica con desviación a la izquierda regenerativa e hiperfibrinogenemia en ambos grupos. Hubo un aumento de globulina, concentración de L-lactato, GGT, GLDH, CK y CK-MB, además de un aumento significativo de cTnI ($p=0.0190$) en GII. En el líquido peritoneal se observó exudado en ambos grupos y una mayor concentración de L-lactato en relación al plasma. La ecografía reveló anomalías reticulares, cardíacas, hepáticas y esplênicas. Las lesiones patológicas confirmaron los hallazgos ecográficos en ambos grupos. La comprensión del síndrome ayuda en el diagnóstico, así como en la adopción de medidas preventivas, minimizando el impacto económico causado a la ganadería lechera.

Palabras clave: Bioquímica clínica; Enfermedad de hardware; Líquido peritoneal; Vacas lecheras; Ultrasonido.

1. Introduction

The metallic foreign body syndrome, also called traumatic reticulitis, is a complex of diseases caused by injury to the reticulus due to the ingestion of sharp metallic foreign bodies (Cramers *et al.*, 2005). The targeting of the foreign body when perforating the reticulum may cause damage to several organs adjacent to the reticulum, such as heart, diaphragm, pleura, liver, spleen, gastrointestinal tract, cutaneous reticulum fistula, in addition to the formation of embolic abscesses in the liver, kidneys and brain, polyarthritis fibrinous and vagal indigestion (Roth & King, 1991; Omid & Mozaffari, 2014), resulting in sequelae that result in nonspecific clinical signs that hinder the diagnosis of the disease (Ghanem, 2010; Esawy *et al.*, 2015; Braun *et al.*, 2018).

The variability of signs in many clinical events represents a diagnostic challenge. The association of complementary exams such as laboratory tests (hematological, biochemical and cavity effusions) has been an important aid in the early diagnosis of the disease (Silva, 2011; Santos *et al.*, 2020). The use of cardiac function markers such as cardiac troponin I (cTnI) and myocardial band creatine kinase (CK-MB) in ruminants has been well validated in bovines (Soares *et al.*, 2019), goats (Ribeiro *et al.*, 2020; Souza *et al.*, 2020) and ewes (Souza *et al.*, 2019), as well as in cases of traumatic pericarditis due to direct cardiac injury or in secondary involvement in cases of traumatic reticuloperitonitis (Gune *et al.*, 2008; Attia, 2016).

Allied to laboratory tests, ultrasound examination has become a relevant tool in the diagnosis of this syndrome by more accurately determining the location and extent of lesions, often reducing the need for exploratory laparotomies in cattle (Braun *et al.*, 1993). In view of the economic losses generated in cattle farming as a decrease in milk production, expenses with

unnecessary clinical and surgical treatments, in addition to establishing the diagnosis in advanced stages resulting in death, this paper aimed to study the systemic implications triggered by the metallic foreign body syndrome in dairy cattle.

2. Material and Methods

This is a prospective longitudinal study according to Thrusfield et al. (2018). The paper was carried out at Clínica de Bovinos of Garanhuns, Campus of the Federal Rural University of Pernambuco, according to Yin (2015), obtaining a favorable opinion from the ethics committee on the use of animals CEUA/UFRPE with license n° 72/2018.

Thirty-seven bovines, crossbred, male and female, were studied, with ages varying from two to ten years, diagnosed with traumatic reticulitis, whose final resolution was the necropsy. Based on the anatomopathological findings, the animals were divided in two groups: GI (n=21), composed of animals with reticuloperitonitis (with or without splenic and hepatic involvement) and GII (n=16), composed of animals with traumatic pericarditis.

For the analysis of peritoneal fluid, eight samples GI (n=8) and seven samples GII (n=7) were considered for this study. Ultrasound images were obtained from 18 animals from GI (n=18) and 12 animals from GII (n=12), following the recommendations of Braun et al. (1997).

All animals were submitted to clinical examination according to Dirksen (1993), in parallel, blood samples were taken by venipuncture of the jugular to determine hematological variables according to Harvey (2012) and biochemical tests. The samples of peritoneal fluid were obtained following the recommendations of Dirksen (1993) guided by ultrasound examination, being analyzed according to the recommendations of Zadnik (2010) and Valenciano et al. (2014).

Biochemical tests determined the concentrations of total protein; albumin; globulin, creatinine; urea; glucose and L-lactate; the enzymatic activity of glutamate dehydrogenase (GLDH); aspartate aminotransferase (AST); Glutamyltransferase (GGT), creatine kinase (CK-NAC) and myocardial band creatine kinase (CK-MB). The serum concentrations of cardiac troponin I (cTn-I) and cortisol were determined by enzyme immunoassay and chemiluminescence.

The anatomopathological findings were described according to Santos and Alessi (2011).

The results regarding clinical observations, analysis of peritoneal fluid, ultrasonographic and anatomopathological findings were analyzed using descriptive statistics. As for the data of hematological variables, blood biochemistry and peritoneal fluid, they were initially tested for normal distribution using the Kolmogorov-Smirnov test. The variables that did not meet the premises of normality were subjected to logarithmic (\log_{10}) or radical ($x + 1$) transformation. Then, the data were subjected to analysis of variance (ANOVA one way), using the statistical program MINITAB® 18. With significance in the ANOVA F Test, the contrast between the means was performed by the minimum significant difference (dms) of the Tukey test. The significance level of 5% was considered for all analyzes (Sampai, 2007).

3. Results

Of the 37 cattle studied, 96% of the animals were females, of which 80% of the GI had calved more than 60 days ago, while 54% of the GII animals were admitted to the hospital unit within sixty days after calving. The vast majority of animals were over the age of four in group I (52.38%) and group II (75.0%) and were raised in a semi-intensive regime. In the anamnesis, it was reported that the animals of both groups had been showing decreased appetite and/or milk production for approximately 30 days, this period being longer in animals of group I.

3.1 Clinical findings

Table 1 shows the absolute and relative frequencies of the main clinical findings of cattle affected with traumatic reticulitis (GI and GII). Among the changes in rumen motility, in GI (n = 21), 13 cattle had only borborygmus and five had hypomotility, while among the animals in GII (n=16), 11 had only borborygmus, one had hypomotility and one had ruminal atony. As for intestinal motility, none of the animals evaluated showed increased motility, and hypomotility was found in 14 and 13 bovines from GI and GII, respectively.

Table 1. Absolute (n) and relative (%) frequencies of the main clinical findings observed in cattle affected with traumatic peritonitis (GI) and traumatic pericarditis (GII).

Variables		Clinical findings	
		Traumatic reticulitis	
		GI (n=21)	GII(n=16)
Behavior	Calm	13 (61,90%)	7 (43,75%)
	Apathetic	5(23,80%)	8(50%)
	Agitated	2(9,52%)	-
	NI	1(4,78%)	1(6,25%)
Appetite	Present	14(66,67%)	9(56,25%)
	Absent	4(19,04%)	4(25%)
	Decreased	3(14,29%)	3(18,75%)
Degree of dehydration	1	8(38,09%)	4(25%)
	2	6(28,57%)	5(31,25%)
	3	5(23,80%)	2(12,5%)
	WA	2 (9,52%)	5(31,25%)
Rectal temperature (°C)	<38	4(19,06%)	3(18,75%)
	38-39	9(42,85%)	5(31,25%)
	>39	7(33,33%)	8(50%)
	NI	1(4,76%)	-
Heart rate (bpm)	60-80	11(52,39%)	2(12,5%)
	>80	10(47,61%)	14(87,5%)
Respiratory rate (mrpm)	<24	2(9,54%)	1(6,25%)
	24-36	10 (47,61%)	8(50%)
	>36	9(42,85%)	7(43,75%)
Ruminal motility	Changed	18(85%)	13(81,25%)
Abdominal tension	Increased	9(42,85%)	4(25%)
	Fisiologic	10(47,63%)	11(68,75%)
	NR	2(9,52%)	1(6,25%)
Intestinal motility	Hipomotile	14(66,67%)	13(81,25%)
Liquid sound	Present	7(33,34%)	3(18,75%)
	Absent	11(52,38%)	12(75%)
	NR	3(14,28%)	1(6,25%)
Stasis test	Positive	2(9,52%)	10(62,5%)
	Negative	19(90,47%)	6(37,5%)
Submandibular edema	Present	1(4,76%)	9(56,25%)
	Negative	20(95,2%)	7(43,75%)
Cardiac auscultation	Alteration	4(19,04%)	12(75%)
	WA	17(80,95%)	4(25%)

NR: No researched; NI: Not informed; WA: Without alterations.

Source: Garanhuns Bovine Clinic, Federal Rural University of Pernambuco - Authors (2021).

3.2 Hematological findings

Among the complementary diagnostic tests, Table 2 shows the findings of the blood count and plasma concentrations of total protein and fibrinogen of animals affected with traumatic reticulitis (GI and GII).

Table 2. Mean values, standard errors ($x \pm SEM$), general mean and significance level (P) of the hematological variables observed in cattle affected by traumatic peritonitis (GI) and traumatic pericarditis (GII).

Variables	Hematological findings			
	Traumatic reticulitis			
	GI (n=21)	GII (n=16)	General mean	p
Hematocrit	24,43±1,52 ^A	26±1,18 ^A	25,11±1,0	0,4429
Red cells (x10 ⁶)	5,64±0,36 ^A	5,47±0,32 ^A	5,57±0,24	0,7308
Hemoglobin (g/dL)	8,52±0,52 ^A	8,56±0,51 ^A	8,54±0,35	0,9510
MCV (fL)	44,11±1,07 ^B	48,09±0,93 ^A	45,83±0,79	0,0106
MCHC (%)	33,77±0,55 ^A	32,22±0,69 ^A	33,11±0,43	0,0822
Total leukocytes (/μL)	28850±5393 ^A	23088±3001 ^A	26358,11±3319,7	0,6997
Linfócitos (/μL)	7479±1260 ^A	4628±663 ^A	6246,11±796,95	0,1963
Segmented neutrophils (/μL)	19237±4746 ^A	17609±2527 ^A	18532,97±2875,6	0,5171
Rod neutrophils (/μL)	1283±676 ^A	464±274 ^A	928,81±402,76	0,4976
Eosinophils (/μL)	235,4±84,9 ^A	49,8±28,7 ^A	155,11±51,53	0,0960
Monocytes (/μL)	324,7±69,7 ^A	302,4±66,2 ^A	315,08±48,21	0,8226
Basophils (/μL)	3,29±3,29 ^B	46,9±22,9 ^A	22,14±10,52	0,0428
TPP (g/dL)	8,43±0,35 ^A	7,23±0,24 ^B	7,91±0,24	0,0146
PF (mg/dL)	942,9±79,8 ^A	762,5±98,7 ^A	864,86±63,10	0,1597

MCV: Mean corpuscular volum; MCHC: Mean corpuscular hemoglobin concentration; TPP: Total plasma protein; FP: Plasma fibrinogen; Different letters on the same line differ at the 5% probability level.

Source: Garanhuns Bovine Clinic, Federal Rural University of Pernambuco - Authors (2021).

3.3 Blood biochemistry

Table 3 shows the results of variables related to liver, renal, muscle and cardiac functionality.

Table 3. Mean values, standard errors ($x \pm SEM$), general mean and significance level (p) of the biochemical variables measured in the blood of cattle affected by traumatic peritonitis (GI) and traumatic pericarditis (GII).

Variables	Blood biochemistry			
	Traumatic reticulitis			
	GI(n=21)	GII(n=16)	General mean	p
Total protein (g/dL)	8,38±0,32 ^A	7,26±0,28 ^B	7,9±0,24	0,0172
Albumin(g/dL)	1,80±0,14 ^A	1,58±0,12 ^A	1,71±0,10	0,2632
Globulin(g/dL)	6,58±0,35 ^A	5,68±0,31 ^A	6,19±0,25	0,0770
Relation A/G	0,30±0,03 ^A	0,29±0,03 ^A	0,30±0,02	0,9547
GGT(U/L)	60,5±10,3 ^A	95,1±23,4 ^A	75,47±11,85	0,1195
AST(U/L)	113±20,4 ^A	153,9±30,1 ^A	130,66±17,48	0,2217
GLDH(U/L)	59,6±21,1 ^A	85,2±27,3 ^A	70,67±16,71	0,1995
Creatinine(mg/dL)	1,18±0,24 ^A	1,01±0,13 ^A	1,11±0,15	0,5973
Urea (mg/dL)	39,88±4,9 ^A	40,20±4,53 ^A	40,02±3,36	0,8232
Glucose (mg/dL)	63,83±3,77 ^A	71,75±6,95 ^A	67,13±3,64	0,4228
Cortisol(nmol/L)	88,3±31,5 ^B	148,1±34,6 ^A	113,23±23,05	0,0210
L lactate(mg/dL)	14,87±2,45 ^A	22,28±6,18 ^A	17,96±2,96	0,4492
Total CK (U/L)	391±103 ^A	362,8±84,1 ^A	378,65±68,09	0,9488
CK-MB(U/L)	143,6±25,1 ^A	124,4±25,4 ^A	135,28±17,81	0,8083
cTnI (ng/dL)	0,09±0,02 ^B	0,32±0,11 ^A	0,19±0,05	0,0190

GGT: Gamma glutamyltransferase; AST: Aspartate aminotransferase; GLDH: Glutamate dehydrogenase; total CK: Total creatine kinase; CK-MB: MN creatine kinase; cTnI: Cardiac troponin I; Different letters on the same line differ at the 5% probability level.

Source: Garanhuns Bovine Clinic, Federal Rural University of Pernambuco - Authors (2021).

3.4 Analysis of peritoneal fluid

3.4.1 Physical Analysis

The color of the peritoneal fluid varied from light yellow to amber in both groups, being more intense in group II. As for turbidity, the samples were slightly turbid to turbid, with the exception of two animals with traumatic reticulopericarditis. The odor was unchanged in the majority of samples from both groups, with a fetid odor in group I in two samples and only one in group II.

3.4.2 Biochemical Analysis

The pH of the peritoneal fluid varied from 7 to 8 in both groups. The protein concentration was greater than 3.0g/dL and that of fibrinogen greater than 100mg/dL in most samples (n=10) from both groups. The result of the biochemical variables measured in the peritoneal fluid can be seen in Table 4.

Table 4. Mean values, standard errors ($\bar{x} \pm \text{SEM}$), general mean and significance level (p) of the biochemical variables measured in the peritoneal fluid of cattle affected by peritonitis reticulum (GI) and traumatic pericarditis (GII).

Variables	Peritoneal fluid			
	Traumatic reticulitis			p
	GI (n=8)	GII (n=7)	General mean	
Total protein (g/dL)	4,04±0,70 ^A	3,85±0,54 ^A	3,95±0,43	0,8366
Albumin(g/dL)	1,40±0,26 ^A	1,01±0,17 ^A	1,22±0,17	0,2669
Globulin(g/dL)	2,64±0,48 ^A	2,83±0,41 ^A	2,73±0,31	0,7718
Relation A/G	0,56±0,08 ^A	0,37±0,04 ^A	0,47±0,05	0,0889
GGT(U/L)	47,81±24,0 ^A	86,3±36,7 ^A	65,79±21,20	0,1966
AST(U/L)	85,8±43,9 ^A	147,4±58,1 ^A	114,54±35,44	0,2934
GLDH(U/L)	27,3±20,1 ^A	70,4±47,2 ^A	47,42±24,20	0,2362
CK	187±131 ^A	78,1±22,5 ^A	132,70±63,43	0,5889
Creatinine(mg/dL)	0,75±0,14 ^A	0,90±0,10 ^A	0,82±0,09	0,4150
Urea (mg/dL)	38,08±6,58 ^A	48,2±10,4 ^A	42,78±5,93	0,4868
Glucose (mg/dL)	36,92±9,48 ^A	56,17±8,43 ^A	45,80±6,69	0,1582
L lactat(mg/dL)	16,57±6,79 ^A	41,7±10,4 ^A	28,32±6,72	0,0693

GGT: Gamma glutamyltransferase; AST: Aspartate aminotransferase; GLDH: Glutamate dehydrogenase; Total CK: Total creatine kinase; Different letters on the same line differ at the 5% probability level.

Source: Garanhuns Bovine Clinic, Federal Rural University of Pernambuco - Authors (2021).

3.4.3 Cytological Analysis

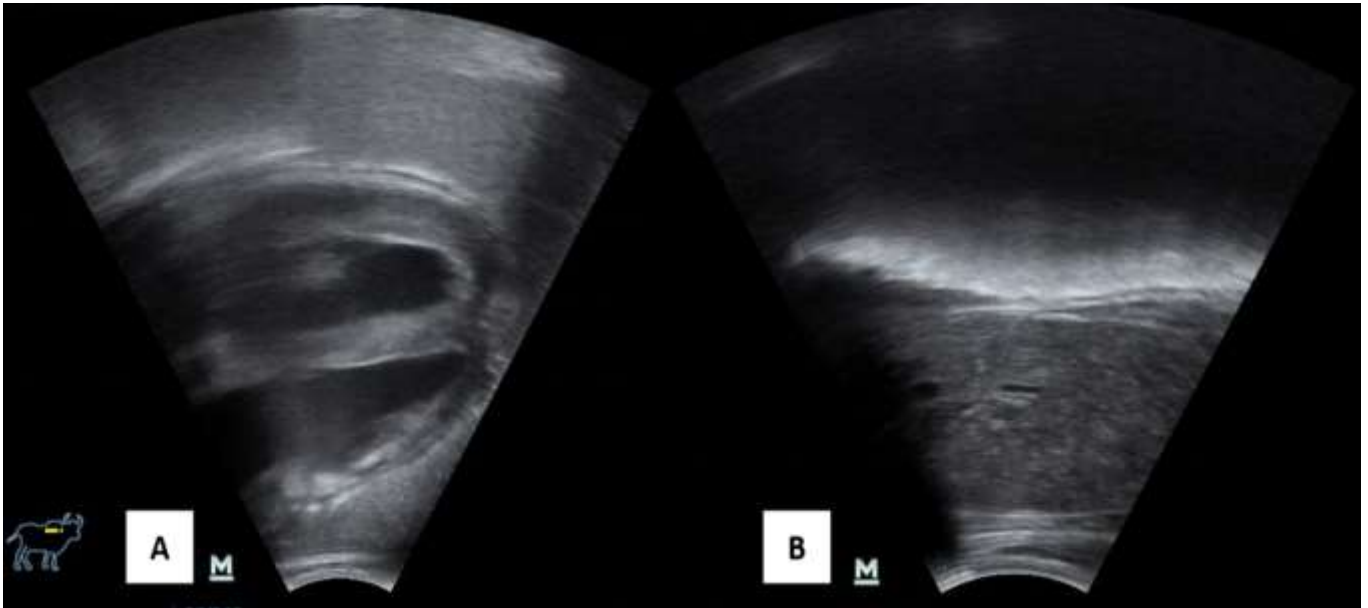
The mean value obtained in the total nucleated cell count (TNCC) in the peritoneal fluid of group I was 12,633.33/μL and of group II 1,138.89/μL with a predominance of polymorphonuclear cells, and the presence of mononuclear cells and some mesothelial cells in both groups. The presence of bacteria was verified in two samples from group I and one from group II.

3.5 Ultrasound findings

Among the main ultrasound findings related to the reticulum of bovines affected by traumatic peritonitis (GI), it was observed that more than 80% had irregular contour (15/18), adhesions (15/18), displacement of their anatomical position (15/18) and change in motility; Similar findings were observed in cattle affected by traumatic pericarditis (GII n=12), which 11 had irregular contours, displacement of their anatomical position and motility alterations, in addition to eight presenting adhesions. Additionally, in GII, an increase in fluid in the thoracic cavity was observed in five cattle and in the pericardium in nine. There were animals with more than one finding.

As for the cardiac ultrasound changes observed in cattle with traumatic pericarditis (GII) were pericardial and epicardial thickening (3/12), the presence of fibrin (3/12), valvular endocarditis (1/12) and the presence of abscess in the interventricular septum (1/12). In GI animals there were no image changes in this organ. It was also possible to verify increased echogenicity in the epicardium, in addition to hypoechoic content between pericardium and epicardium and increased echogenicity of the capsule and splenic parenchyma (Figure 1a and 1b).

Figure 1. (A): Epicardium with increased echogenicity (arrowhead), presence of hypoechoic content between pericardium and epicardium (arrow). (B): Increased echogenicity of capsule (arrow) and loss of splenic parenchyma.



Source: Garanhuns Bovine Clinic, Federal Rural University of Pernambuco - Authors (2021).

During the ultrasound evaluation of the liver, alterations were observed in 5 cattle from GI (n=18) and in 7 from GII (n=12). In this organ, the main findings in GI were the presence of abscesses (4) and perihepatitis (1), and in GII they were abscesses (4) and hepatomegaly (3). Another organ frequently affected in the traumatic peritonitis/pericarditis in this study was the spleen, where the main splenic ultrasound changes were abscesses (7/18 in GI), splenic vein thrombosis (2/18 in GI), dorsal deviation and adherence (2/18 in GI), indefiniteness of the splenic capsule (2/18 in GI and 1/12 in GII), and dilation of the splenic vein (1/12 in GII).

3.6 Anatomopathological findings

The frequencies, absolute (n) and relative (%) of anatomopathological lesions observed in cattle affected by reticulum peritonitis and traumatic pericarditis can be seen in table 5. Twelve cattle in GI (n=21) showed an increase in fluid in the abdominal cavity, while in GII (n=16) in addition to an increase in fluid in the abdominal cavity (11), 13 presented an increase in the fluid in the pericardium and four in the thoracic cavity.

Table 5. Absolute (n) and relative (%) frequency of the main anatomopathological lesions observed in cattle affected by traumatic peritonitis (GI) and traumatic pericarditis (GII).

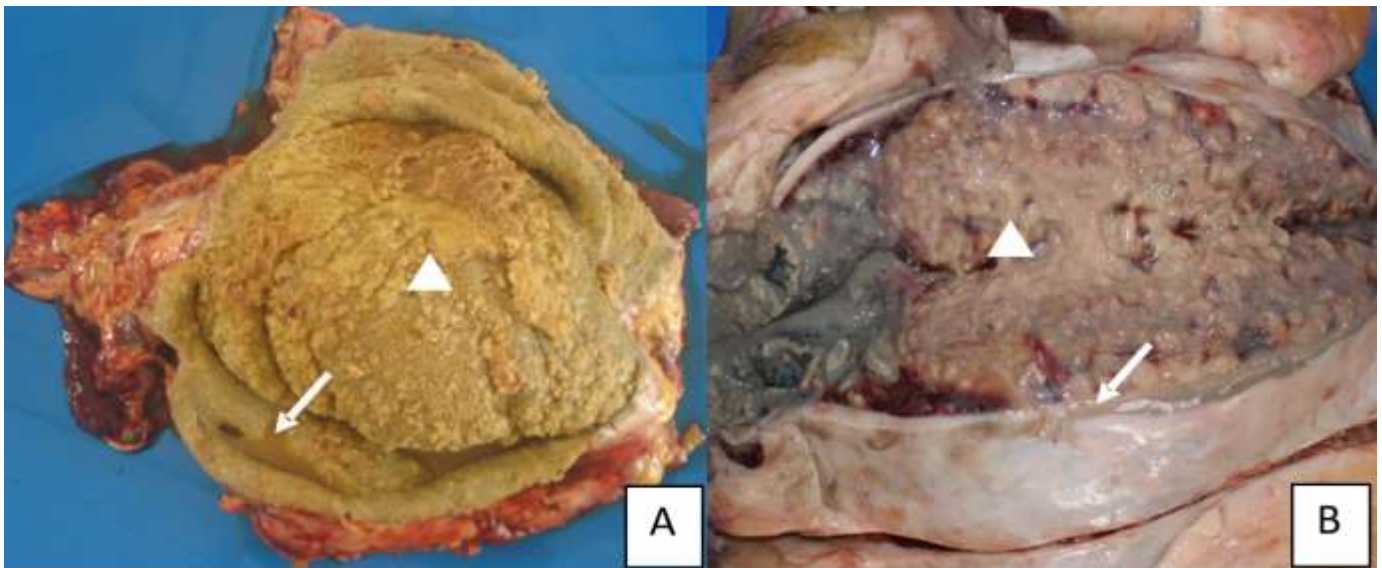
Variables		Anatomopathological Findings	
		Traumatic reticulites	
		GI (n=21)	GII (n=16)
Presence of fibrin	Yes	10(47,61%)	7(43,75%)
Reticulum injury	Yes	21(100%)	16(100%)
Splenic injury	Yes	16(76,19%)	7(43,75%)
	Capsular reaction	15(71,42%)	8(50%)
	Presence of abscesses	11(52,38%)	1(6,25%)
Liver injury	Yes	13(61,90%)	16(100%)
	Presence of abscesses	7(33,33%)	1(6,25%)
	Perihepatitis and congestion/hepatomegaly	6(28,57%)	15(93,75%)
Cardiac injury	Yes	7(33,33%)	16(100%)
Presence of adherence	Ret/ diaphragm	8(38,09%)	7(43,75%)
	Ret/spleen	15(71,42%)	9(56,25%)
	Ret/liver	7(33,33%)	5(31,25%)
	Spleen/diaphragm	6(28,57%)	1(6,25%)
	Diaphragm / pericardium	1(4,76%)	3(18,75%)
	Diaphragm / liver	5(23,80%)	3(18,75%)
Presence of metallic foreign body (perforating or not)	Yes	17(80,95%)	12(75%)

Source: Garanhuns Bovine Clinic, Federal Rural University of Pernambuco - Authors (2021).

Among the main pathological lesions observed in the reticulum of cattle affected by traumatic peritonitis, in GI (n=26) the presence of adhesions (26), fibrin (4), abscesses (3), fistula with the spleen (3) stand out (3) and mucosal perforation; In GII (n=16), adhesions (16), abscess (1), fistula with the diaphragm (1) and with the thoracic cavity (1) were observed.

As for the presence of pathological cardiac lesions, subepicardial hemorrhages (5) and abscesses (2) were observed in GI cattle (n=21), and epicardial fibrin in cattle (9), myocarditis (3), abscesses (2) and valvular endocarditis (1) in GII cattle (n=16). In Figure 2a and 2b deposition of fibrinous material in the epicardium is seen, as well as sero fibrinous effusion in the pericardial sac.

Figure 2. (A): Deposition of fibrinous material in the epicardium (arrowhead), with serofibrinous effusion in the pericardial sac (arrow) (B): Capsule thickening (arrow) and abscess content in the splenic parenchyma (arrowhead).



Source: Garanhuns Bovine Clinic, Federal Rural University of Pernambuco - Authors (2021).

4. Discussion

The vast majority of the cattle studied were females (96%) over the age of four, raised in a semi-intensive to intensive regime, similar to that verified by Roth and King (1991), attributed to the productive longevity of dairy females, in addition to the greater exposure to metallic foreign bodies due to feeding in the trough.

The calving could be considered a relevant risk factor for the disease, as was seen in the animals of both groups, however, GII showed signs of the disease in a shorter time and closer to delivery when compared to GI. According to Esawy *et al.* (2015) the proximity of parturition is considered a risk factor for illness due to the pressure exerted by the fetus in the last trimester of pregnancy or the uterine contractions at the time of delivery that facilitate the perforation of the reticular wall. The chronological difference in the proximity of parturition and clinical care between the groups may be related to the severity of the most evident clinical signs in the traumatic pericarditis reticulum as observed in other studies [Habasha & Yassein, 2014; Esawy *et al.*, 2015) influencing the search time for veterinary care.

4.1 Clinical findings

In general, both groups showed clinical changes characterized by behavioral changes (apathy); of appetite, being absent or decreased; dehydrated with turgor degree ranging from 1 to 3 and rectal temperature above 38°C-39°C. These characteristics were slightly more intense in animals with traumatic pericarditis, findings also reported by Ghanem (2010), Braun *et al.* (2018b). Braun *et al.* (2018a) attributed the rectal temperature below 39°C, in the vast majority of animals, as a result of the chronic clinical evolution and the treatment performed before hospital admission. For some authors, rectal temperature above 39°C is commonly observed in traumatic pericarditis and in acute cases (Braun 2009; Hussein & Staufenbiel, 2014) observation is verified in a small percentage of animals in this study. Both groups showed changes in both heart and respiratory rates. It should be noted that in the group of animals with reticulum pericarditis, the change in heart rate was much more expressive, with tachycardia in almost 90% of the affected animals. Ghanem (2010) and Attia (2016) justified tachypnea as a result of the stress associated with toxemia and septicemia caused by foreign body penetration, right congestive heart failure or lung involvement. Tachycardia, positive stasis proof, edema of the dewlap and changes in cardiac auscultation such as muffling, sound of liquid,

murmurs and arrhythmias were seen more frequently in animals of the GII, which is expected, since the increased frequency of heartbeat results as a compensatory response resulting from increased pressure in the heart resulting from the accumulation of fluid in the pericardial sac (Ghanem, 2010; Esawy *et al.*, 2015; Neamat-Allah, 2015; Attia, 2016). The positive stasis test and edema of the dewlap are related to pericardial effusion that increases cardiac pressure by delaying venous return, elevation of hydrostatic pressure resulting in edema and right congestive heart failure.

Impaired ruminal and intestinal motility was also seen in both groups. Ghanem (2010) and Braun *et al.* (2018b) attribute the hypomotility as a result of the inhibition of the gastric center in the oblong medulla via the vagus nerve as a consequence of the pain caused by the penetration of the foreign body, however, they are considered nonspecific signs, as they can be found in other digestive or systemic disorders.

The increased abdominal tension resulting from the extension of the lesion and the sound of fluid when floting was more frequent in group I compared to group II, which may be related to peritonitis caused by increased vascular permeability due to the inflammatory process, which allows the sequestration of liquid to the abdominal cavity, also justifying the greater number of dehydrated animals in this group (Dev, 2006).

4.2 Hematological findings

The animals of both groups showed values of the erythrocyte series at the lower limit of normality, probably due to the chronic inflammatory condition (Ghanem, 2010; Reddy *et al.*, 2014; Braun *et al.*, 2018b). On the other hand, the leukocyte series revealed high global leukometry due to neutrophilia, as well as a left-shift in both groups. In parallel, hyperfibrinogenesis was reported, as stated by other authors in these diseases (Ghanem, 2010; Silva, 2011; Braun *et al.*, 2018b; Santos *et al.*, 2020). In this study, mean plasma fibrinogen concentration between 800-900mg/dL was found, slightly higher than that considered normal for species, probably due to impaired liver functionality, although preserving the synthesis capacity of this protein to a lesser extent, since some authors reported in these diseases, concentrations higher than 1000mg/dL (Ghanem, 2010; Silva, 2011);

4.3 Analysis of peritoneal fluid

The physical characteristics of the peritoneal fluid were altered, including the increase in volume, in both groups, showing the involvement of the abdominal cavity. According to Mendes *et al.* (2000) the inflammatory process increases vascular permeability facilitating the passage of liquid to the cavity. Regarding the pH values, Van Hoogmoed *et al.* (1999) stated that values below 7.2 are observed in cases of septic peritonitis; in this study, only three samples showed the presence of bacteria, which would justify the values of this variable higher than seven in the vast majority of samples, as also reported by Silva (2018) and Santos *et al.* (2020). The fibrinogen concentration greater than 100mg/dL is indicative of progressive vascular injury in the abdominal viscera (Silva, 2018; Grosche *et al.*, 2012). The mean value of the total superior nucleated cell count in group I is justified by the condition of peritonitis, with splenic and hepatic involvement in some animals, differently from group II. According to Mendes *et al.* (2000) and Lhamas *et al.* (2014) the release of inflammatory cells into the abdominal cavity is a consequence of the inflammatory stimulus in response to peritoneal injury, so the nucleated cell count varies with the inflammatory response and may change the predominant cell type.

4.4 Blood biochemistry

Regarding protein concentrations, only the concentration of total protein differed between groups, presenting a higher average value in group I. The increase in protein concentration in both groups and in greater intensity in group I, was probably due to hemoconcentration in the latter group, associated, both in group I and in group II, with high globulin concentrations and hyperfibrinogenesis, at the same time that hypoalbuminemia is observed in both groups. According to Eckersall (2008),

hyperproteinemia is associated with hyperglobulinemia due to the inflammatory response characteristic of metallic foreign body syndrome and its sequels, justified in this study by the longer clinical evolution of cases of traumatic reticulum peritonitis. Cray *et al.* (2009) stated that hypoalbuminemia occurs in inflammatory processes because the liver prioritizes the production of positive acute phase proteins because they are important in preventing inflammation and contributing to healing. Another factor to be considered is the increase in vascular permeability in the local inflammatory process, enabling the migration of this protein to the abdominal cavity (Dev, 2006).

The enzymatic changes observed in the blood serum of both groups, particularly of the GGT and GLDH enzymes, confirm liver impairment in animals with foreign body syndrome with or without cardiac involvement. This study confirms the measurement of serum GGT activity in cattle because it has greater specificity in detecting chronic liver injuries (Moreira *et al.*, 2012). The magnitude of GLDH activity observed in animals in both groups confirms liver damage, since this enzyme is considered hepatospecific, being an important indicator of liver necrosis in ruminants (Hoffman & Solter, 2008).

The absence of alterations in the serum concentration of urea and creatinine in the blood of cattle with reticulitis was also described by Braun *et al.* (2018b), Silva (2018) and Santos *et al.* (2020). On the other hand, Ghanem (2010) found high levels of these variables in cases of reticulum peritonitis and traumatic pericarditis, associated with renal failure due to dehydration and decreased blood flow and subsequent pre-renal azotemia.

In this study, there was no change in the glycemic levels of both groups studied, however, the glycemic concentrations associated with animals with foreign body syndrome are divergent among the authors for Gunes *et al.* (2008), hyperglycemia is attributed to the stress generated by the disease. Ghanem (2010) and Reddy *et al.* (2014) found hypoglycemia associating it with prolonged anorexia, mild indigestion and primary or secondary liver damage.

The blood cortisol concentration in the group affected by traumatic pericarditis reticulum was significantly higher than the group with traumatic reticulum peritonitis. The increase in peripheral levels of this hormone was verified by Singh *et al.* (2005) in buffaloes with foreign body syndrome, attributing the increase in cortisol to stimulating the activity of the hypothalamic-pituitary-adrenal axis in response to the stress caused by the severity of the disease, demonstrated in this study by the greater clinical impairment of animals in the GII.

Plasma concentrations of L-lactate did not differ between groups I and II. Although these values are lower than those found by Silva (2018) and Santos *et al.* (2020), these are higher than those found in healthy cows (Wittek *et al.*, 2010a). According to Figueiredo *et al.* (2006) the elevation of plasma L-lactate occurs due to the decrease in systemic tissue perfusion due to dehydration, shock, endotoxemia or the combination of these conditions, in addition to the increase in anaerobic metabolism by the affected tissues (Wittek *et al.*, 2006).

Although some authors consider CK-MB to be a marker of heart disease (Undhad *et al.*, 2012) it was found to be elevated in both groups, presenting demeanor similar to CK. Elevated serum CK activity may be associated with both skeletal and cardiac muscle injuries, whether due to prolonged decubitus or muscle necrosis (Hoffman & Solter, 2008), however, Varga *et al.* (2009) state that this enzyme has a low correlation with cardiac changes, in addition to low specificity in the detection of microinjury to bovine myocardial cells. The non-specificity of CK-MB for cardiac abnormalities observed in this study was also reported by Fartashvand *et al.* (2013) who stated that because it is a CK isoenzyme, CK-MB can rise in other cases of muscle injury.

Differently CK-MB, cTnI showed higher concentrations in GII. The high cTnI values in animals with traumatic pericarditis can be justified because it is an indicator of myocardial damage and heart failure in cattle and buffaloes even at an early stage of the disease, since its release into the circulation occurs within eight hours in response to any myocardial microinjury, remaining elevated for up to two weeks as reported by Undhad *et al.* (2012). Mellamby *et al.* (2007) stated that in cases of chronic pericarditis, cTnI values may remain high even they do not correspond with the severity of the disease,

suggesting that these concentrations are higher in acute cases. The increase in cTnI values has previously been reported in other countries in cattle and buffaloes with traumatic pericarditis (Neamat-Allah, 2015; Attia, 2016).

4.5 Biochemistry of peritoneal fluid

The increase in the protein concentration of the peritoneal fluid can be justified by the chronic antigenic stimulus that raises the globulin concentrations (Eckersall, 2008). According to Wittek *et al.* (2010b) the increase in total protein can be associated with the presence of cytological and biochemical characteristics of peritoneal inflammation, also verified in this study. According to Dev (2006) and Lhamas *et al.* (2014) the injury caused in the inflammatory processes leads to an increase in vascular permeability, resulting in increased protein concentration and release of inflammatory cells. Similar results have been described by Wittek *et al.* (2010b) and Santos *et al.* (2020).

The enzymatic activities of AST, GGT, GLDH and CK verified in the peritoneal fluid were high, following the value observed in the blood of animals affected with foreign body syndrome. For Dev (2006) in inflammatory processes, there is an increase in vascular permeability, triggering the release of biochemical variables into organic fluids, among which the enzymes used in this study.

As for glucose, the average concentration in the peritoneal fluid of both groups was slightly lower than that found in blood plasma and lower than that described by Wittek *et al.* (2010b) in cattle without peritonitis, this finding could be related to bacterial consumption, since glucose, according to Wittek *et al.* (2010b), is considered a good marker of septic peritonitis in cattle.

The general mean concentration of L-lactate in the peritoneal fluid (28.32mg/dL) was higher than that found in blood plasma (17.96mg/dL), confirming its relevance as a biomarker of digestive disorders, as it reflects the severity of the disorders, as reported by Santos *et al.* (2020). According to Wittek *et al.* (2006) and Silva (2018) the elevation of this variable in the peritoneal fluid is attributed to the local synthesis of L-lactate by anaerobic glycolysis in processes that culminate in ischemia of the injured tissues.

4.6 Ultrasound and anatomopathological findings

The reticular lesions found at necropsy confirmed the ultrasound findings of this study, which are similar to those found by Braun *et al.* (1993), Silva (2011) and Braun *et al.* (2018b). According to Roth & King (1991), the location and formation of fibrinous adhesions depend on the organ damaged by the foreign body when perforating the reticulum.

The absence of reticular adhesions by ultrasound examination was also verified in the study by Braun *et al.* (2018a). According to Braun *et al.* (1993), the non-visualization of these lesions may be related to their more internal location, making it impossible to access them through the absorption of ultrasound waves. In addition, the authors add that after the acute inflammatory process, fibrinous adhesions in the connective tissue disintegrate transforming into fibrin filaments restoring reticular motility.

The reticular changes verified in this work agree with Roth & King (1991) and Silva (2011) for whom, the metallic foreign body can be found in different organs such as reticulum, diaphragm, pericardium, endocardium and less frequently in the liver and spleen. The non-visualization of the metallic foreign body in some animals of both groups may be due to the extension of the inflammatory process, the adhesions formed and the occurrence of oxidation depending on the type of perforating material found. The sequelae found are associated with the targeting of the foreign body and the chronicity of the inflammatory process (Silva, 2011; Braun *et al.*, 2018a) transforming into fibrin filaments restoring reticular motility.

The good correspondence between the sonographic findings of effusion in the abdominal, thoracic and pericardial cavities with the anatomopathological findings agree with Ghanem (2010) and Silva (2018), who also verified these changes in

imaging exams and in the anatomopathology of cattle with the disease. According to Silva (2011) and Attia (2016), cavity effusion may result from right congestive heart failure, as well as suppurative processes in response to inflammation resulting from perforation of the reticular ruminal wall, being differentiated ultrasonographically by their echogenicity. The pericardial and abdominal effusion found is commonly seen in cases of traumatic pericarditis as verified by Ghanem (2010), Silva (2011) and Hussein & Staufenbiel (2014). Miller *et al.* (2013) state that in this sequel the presence of fluid in the abdominal cavity and in the pericardial sac occurs due to the increase in hydrostatic pressure in the circulatory and lymphatic systems.

The sonographic and macroscopic characteristics of the cardiac alterations in this study, found in group II, are compatible with those reported by Braun (2009), Ghanem (2010), Silva (2011) in cases of traumatic pericarditis. According to Miller *et al.* (2013) the presence of adhesions and fibrin adhered to the epicardium indicate the chronicity of the inflammatory process resulting from foreign body penetration, whereas the hemorrhagic injury observed in group I can be attributed to severe septicemia, endotoxic and anoxia. The ultrasonographic liver changes seen in group II were also found in macroscopy. These lesions are frequently seen in cases of traumatic pericarditis as exposed by Hussein & Staufenbiel (2014), with hepatomegaly (hepatic congestion) as a consequence of right congestive heart failure (Mosier, 2013).

Multiple abscesses in the hepatic parenchyma of animals from both groups characterized by ultrasonography and ratified by necropsy, are frequently found in the syndrome (Ismail; Abdullah, 2014; Braun *et al.*, 2018a), being related to the chronic inflammatory process with formation of embolic abscesses in the liver resulting from the septicemia caused by the trauma (Roth & King, 1991; Esawy, 2015).

Ultrasonographic and anatomopathological lesions of the spleen in group I were also observed by Braun *et al.* (1993), Silva (2011) in other studies carried out in cattle with the syndrome. Being associated with suppurative reaction due to foreign body injury, in addition to chronic and persistent stimulation (Silva, 2011; Hussein & Staufenbiel, 2014; Braun *et al.*, 2018a). Group II injuries are the result of adhesions resulting from the inflammatory process (Hussein & Staufenbiel, 2014).

5. Conclusion

The metallic foreign body syndrome triggered severe systemic changes, of non-specific clinical characteristics, resulting from the direct impairment of reticular, hepatic and cardiac functionality. The importance of the complementary diagnosis, represented by laboratory tests, is emphasized, including cardiac troponin I as a marker of cardiac injury in the bovine species and ultrasonographic diagnosis, which increased the precision of the diagnosis and establishment of the prognosis, avoiding more laborious interventions, providing greater welfare to animals and minimizing economic losses, however, studies are needed to bring information prior to the onset of lesions.

Acknowledgements

This study was financed in part by the Coordenação de Aperfeiçoamento de Pessoal de Nível Superior - Brasil (CAPES) - Finance Code 001. Additionally, the authors would like to thank the Bovines Clinic of Garanhuns/Federal Rural University of Pernambuco (CBG/UFRPE) for the necessary conditions to carry out this work.

References

- Attia, N. E. (2016). Cardiac biomarkers and ultrasonography as tools in prediction and diagnosis of traumatic pericarditis in Egyptian buffaloes. *Veterinary World*, 9(9), 976-982. 10.14202/vetworld.2016.976-982
- Braun, U. (1997). *Atlas und Lehrbuch der Ultraschall-diagnostik beim Rind*. Parey Buchverlag.
- Braun, U. (2009). Ultrasonography of the gastrointestinal tract in cattle. *Veterinary Clinics of North America: Food Animal Practice*, 25(3), 567-590. 10.1016/j.cvfa.2009.07.004

- Braun, U., Gerspach, C., Warislohner, S., Nuss, K. & Ohlerth, S. (2018a) Ultrasonographic and radiographic findings in 503 cattle with traumatic reticuloperitonitis. *Research in Veterinary Science*, 119, 154-161. 10.1016 / j.rvsc.2018.05.019
- Braun, U., Götz, M. & Marmier, O. (1993). Ultrasonographic findings in cows with traumatic reticuloperitonitis. *Veterinary Record*, 133(117), 416-422. 10.1136 / vr.133.17.416.
- Braun, U., Warislohner, S., Torgerson, P., Nuss, K. & Gerspach, C. (2018b). Clinical and laboratory findings in 503 cattle with traumatic reticuloperitonitis. *BMC Veterinary Research*, 14(66), 1-9. 10.1186/s12917-018-1394-3
- Cramers, T., Mikkelsen, K. B., Enevoldsen, C. & Jensen, H. (2005). New types of foreign bodies and the effect of magnets in traumatic reticulitis in cows. *Veterinary Record*, 157(10), 287-289. 10.1136 / vr.157.10.287.
- Cray, C., Zaias, J. & Altman, N. H. (2009). Acute Phase Response in Animals: A Review. *Comparative Medicine*, 59(6), 517-526.
- Dev, K. (2006). *Peritoneal fluid studies in buffaloes suffering from traumatic reticuloperitonitis*. MSc, Chaudhary Charan Singh Haryana Agricultural University, India.
- Dirksen, G. (1993). Sistema digestivo. In: Dirksen, G., Gründer, H. D. & Stöber, M. *Rosenberger Clinical Examination of Cattle*. 3ª ed. Guanabara Koogan, Rio de Janeiro, RJ, Brasil. pp. 166-228.
- Eckersall, P. D. (2008). Proteins, Proteomics, and the Dysproteinemia. In: Kaneko JJ, Harvey JW, Bruss ML, Clinical biochemistry of domestic animals. *Academic Press*, 117-155.
- Esawy, E. E. El., Badawy, A. M. & Ismail, S. F. (2015). Ultrasonographic Diagnosis and Clinical Evaluation of the Foreign Body Complications in the Compound Stomach of Cattle and Buffaloes. *Journal of Advanced Veterinary Research*, 5(3), 109-120.
- Fartashvand, M., Nadalian, M. G., Sakha, H. & Safi, S. (2013). Elevated serum cardiac troponin I in cattle with Theileriosis. *Journal of Veterinary Internal Medicine*, 27(1), 194-199. 10.1111 / jvim.12014
- Figueiredo, M. D., Nydam, D. V., Perkins, G. A., Mitchell, H. M. & Divers, T. J. (2006). Prognostic value of plasma l-lactate concentration measured cowside with a portable clinical analyzer in holstein dairy cattle with abomasal disorders. *Journal of Veterinary Internal Medicine*, 20(6), 1463-1470. 10.1892/0891-6640 (2006)20 [1463: pvopl] 2.0.co; 2
- Ghanem, M. M. (2010). A comparative study on traumatic reticuloperitonitis and traumatic pericarditis in Egyptian cattle. *Turkish Journal of Veterinary and Animal Sciences*, 34(2), 143-153. 10.3906 / vet-0804-16
- Grosche, A., Füll, M. & Wittek, T. (2012). Peritoneal fluid analysis in dairy cows with left displaced abomasum and abomasal volvulus. *Veterinary Record*, 170(16), 1-6. 10.1136 / vr.100381
- Gunes, V., Atalan, G., Citil, M. & Erdogan, H. (2008). Use of cardiac troponin kits for the qualitative determination of myocardial cell damage due to traumatic reticuloperitonitis in cattle. *Veterinary Record*, 162(16), 514-517. 10.1136 / vr.162.16.514.
- Habasha, F. G. & Yassein, S. N. (2014). Advance techniques in traumatic reticuloperitonitis diagnosis: review. *AL-Qadisiya Journal of Veterinary Medicine Sciences*, 13(2), 50-57.
- Harvey, J. W. (2012). Hematology procedures. In: Harvey, J. W. *Veterinary hematology. A diagnostic guide and color atlas*. Elsevier. St. Louis. 11-32.
- Hoffman, W. E. & Solter, P. F. (2008). Diagnostic enzymology of domestic animals. In: Kaneko, J. J., Harvey, J. W., Bruss, M. L. *Clinical biochemistry of domestic animals*. (Eds.). Academic Press, 351-378.
- Hussein, H. A. & Staufenbiel, R. (2014). Clinical presentation and ultrasonographic findings in buffaloes with congestive heart failure. *Turkish Journal of Veterinary and Animal Sciences*, 38(5), 534-545. 10.3906 / vet-1404-111
- Ismail, H. K. H. & Abdullah, O. A. (2014). Metallic foreign body in the liver of cow: a case report. *Iraqi Journal of Veterinary Sciences*, 28(2), 109-111. 10.33899 / ijvs.2014.117978
- Lhamas, C. L., Freitas, G. S. R., Duarte, C. A. & Thiesen, R. (2014). Evaluation of peritoneal fluid in horses. *Ciência Animal Brasileira*, 24, 3-12.
- Mellanby, R. J., Henry, J. P., Cash, R., Ricketts, S. W., Dias Bexiga, J. R., Mellor, D. J. (2007). Serum cardiac troponin I concentrations in cattle with pericarditis. *Veterinary Record*, 161(13), 454-455. 10.1136 / vr.161.13.454
- Mendes, L. C. N., Peiró, J. R., Marques, L. C. & Borges, A. S. (2000). Laboratory evaluation of peritoneal fluid in experimental models used to induce an intra-abdominal inflammatory reaction in horses. *Revista Eletrônica de Educação*, 3, 21-27.
- Miller, L. M., Van Vleet, J. F. & Gal, A. (2013). Sistema cardiovascular e vasos linfáticos. In: Zachary, J. F. & McGavin, M. D. *Bases of pathology in veterinary medicine*. Mosby Elsevier, 1408-1543.
- Moreira, C. N., Souza, S. N., Barini, A. C., Araújo, E. G. & Fioravanti, M. C. S. (2012). Serum γ -glutamyltransferase activity as an indicator of chronic liver injury in cattle with no clinical signs. *Arquivo Brasileiro de Medicina Veterinária e Zootecnia*, 64(6), 1403-1410. 10.1590/S0102-09352012000600001
- Mosier, D. A. Doenças vasculares e trombozes. In: Zachary, J. F. & McGavin, M. D. *Bases of pathology in veterinary medicine*. Mosby Elsevier, 170-241.
- Neamat-Allah, A. N. F. (2015). Alterations in Some Hematological and Biochemical Parameters in Egyptian Buffaloes Suffering from Traumatic Reticuloperitonitis and Its Sequelae. *Bulletin of University of Agricultural Sciences and Veterinary Medicine*, 72(1), 117-122. 10.15835/buasvmcn-vm: 11021

- Omid, A. & Mozaffari, A. A. (2014). Reticulo-cutaneous fistula due to the ingestion of a long metallic rod in a cow. *Asian Pacific Journal of Tropical Biomedicine*, 4(7), 586-588. 10.12980/APJTB.4.2014B102.
- Reddy, L. V. P., Reddy, B. S., Naik, B. R. & Prasad, C. (2014). Haematological and Clinical Alterations with Traumatic Reticuloperitonitis in Cattle. *International Journal of Veterinary Science*, 3(4), 203-205.
- Ribeiro, A. C. S., Conceição, A. I., Soares, G. S. L., Correia, F. R., Oliveira-Filho, J. P., Soares, P. C., Mendonça, C. L. & Afonso, J. A. B. (2020). Hemogasometry, cardiac biomarkers and blood metabolites in goats with experimentally induced acute ruminal lactic acidosis. *Small Ruminant Research*, 191, 1-6. 10.1016/j.smallrumres.2020.106187
- Roth, L. & King, J. M. (1991). Traumatic reticulitis in cattle: a review of 60 fatal cases. *Journal of Veterinary Diagnostic Investigation*, 3(1), 52-54. 10.1177/104063879100300111.
- Sampaio, J. B. M. (2007). *Estatística aplicada à experimentação animal*. (3a ed.), FEPMVZ.
- Santos, J. F., Rego, R. O., Afonso, J. A. B., Soares, P. C. & Mendonça, C. L. (2020). Biomarkers blood and peritoneal fluid of bovines with intestinal diseases and traumatic reticulites. *Ciencia Animal Brasileira*, 21:e-50941. 10.1590/1809-6891v21e-50941.
- Santos, R. L. & Alessi, A. C. (2011). *Patologia Veterinária*. Roca.
- Silva, J. R. B. (2018). *Videolaparoscopia e ultrassonografia como métodos auxiliares no diagnóstico das enfermidades abdominais dos bovinos*. MSc, Faculty of Veterinary Medicine and Animal Science - Paulista State University "Júlio de Mesquita Filho", Botucatu.
- Silva, N. A. A. (2011). *Achados epidemiológicos, clínicos e ultrassonográficos em bovinos acometidos com reticulopericardite traumática*. MSc, Federal Rural University of Pernambuco, Garanhuns.
- Singh, R., Garg, S. L., Sangwan, N. & Singh, J. (2005). Peripheral concentration of cortisol in buffaloes suffering from foreign body syndrome. *Buffalo Bill*, 24, 88-90.
- Soares, G. S. L., Ribeiro, A. C. S., Cajueiro, J. F. P., Souto, R. J. C., Oliveira Filho, E. F., Mendonça, C. L. & Afonso, J. A. B. (2019). Cardiac biomarkers and blood metabolites in cows with clinical ketosis. *Semina: Ciências Agrárias*, 40(6), 3525-3540. 10.5433/1679-0359.2019v40n6Supl3p3525
- Souza L. M., Mendonça, C. L., Assis, R. N., Oliveira Filho, E. F., Soares, G. S. L., Souto, R. J. C. & Afonso, J. A. B. (2020). Changes in cardiac biomarkers in goats naturally affected by pregnancy toxemia. *Research in Veterinary Science*, 130, 73-78. 10.1016/j.rvsc.2020.02.016
- Souza, L. M., Mendonça, C. L., Assis, R. N., Oliveira Filho, E. F., Gonçalves, D. N. A., Souto, R. J. C., Soares, P. C. & Afonso, J. A. B. (2019). Cardiac biomarkers troponin I and CK-MB in ewes affected by pregnancy toxemia. *Small Ruminant Research*, 177, 97-102. 10.1016/j.smallrumres.2019.06.020
- Thrusfield, M., Christley, R., Brown, E., Diggle, P. J., French, N., Howe, K., Kelly, L., O'Connor, A., Sargeant, j. & Wood, H. (2018). *Veterinary Epidemiology*. 4th ed. Wiley-Blackwell, Hoboken, N.J. 319-338.
- Undhad, V. V., Fefar, D. T., Jivani, B. M., Gupta, H., Ghodasara, D. J., Joshi, B. P. & Prajapati, K. (2012). Cardiac troponin: an emerging cardiac biomarker in animal health. *Veterinary World*, 5(8), 508-511. 10.5455/vetworld.2012.508-511
- Valenciano, A. C., Arndt, T. P., Rizzi & T. E. (2014). Effusions: Abdominal, Thoracic, and Pericardial. In: Valenciano, A. C., Cowell, R. L. *Diagnostic and Hematology of the dog and cat*. Elsevier. St. Louis, 244-265.
- Van Hoogmoed, L., Rodger, L. D., Spier, S. J., Gardner, I. A., Yarbrough, T. B. & Synder, J. R. (1999). Evaluation of peritoneal fluid pH, glucose concentration, and lactate dehydrogenase activity for detection of septic peritonitis in horses. *Journal of the American Veterinary Medical Association*, 214, 1032-1036.
- Varga, A., Schober, K. E., Holloman, C. H., Stromberg, P. C., Lakritz, J. & Rings, D. M. (2009). Correlation of serum cardiac troponin I and myocardial damage in cattle with monensin toxicosis. *Journal of Veterinary Internal Medicine*, 23(5), 1108-1116. 10.1111/j.1939-1676.2009.0355.x.
- Wittek, T., Füll, M. & Constable, P. D. (2010a). Prevalence of endotoxemia in healthy postparturient dairy cows and cows with abomasal volvulus or left displaced abomasum. *Journal of Veterinary Internal Medicine*, 18(4), 574-580. 10.1892/0891-6640(2004)18<574:poeihp>2.0.co;2
- Wittek, T., Grosche, A., Locher, L. & Füll, M. (2006). Diagnostic Accuracy of D-Dimer and Other Peritoneal Fluid Analysis Measurements in Dairy Cows with Peritonitis. *Journal of Veterinary Internal Medicine*, 24(5), 1211-1217. 10.1111/j.1939-1676.2010.0548.x.
- Wittek, T., Grosche, A., Locher, L., Alkassam, A. & Füll, M. (2010b). Biochemical constituents of peritoneal fluid in cows. *Veterinary Record*, 166(1), 15-19. 10.1136/vr.b5584
- Yin, R.K. (2015). *O estudo de caso*. Bookman.
- Zadnik, T. (2010). A retrospective study of peritoneal fluids in cows with abdominal disorders. *Veterinary Glasnik*, 64: 187-195. 10.2298/VETGL1004187T