

Current stage of the immediate load on the jaw

Estágio atual da carga imediata na mandíbula

Etapas actual de la carga inmediata en la mandíbula

Received: 08/24/2021 | Reviewed: 08/29/2021 | Accept: 09/01/2021 | Published: 09/05/2021

Ricardo Seixas de Paiva Lima

ORCID: <https://orcid.org/0000-0002-6322-6504>
Universidade Santo Amaro, Brasil
E-mail: ricardoseixasdepaiva@gmail.com

Gustavo Seixas de Paiva Lima

ORCID: <https://orcid.org/0000-0002-1075-7643>
Odontocentro prof. Javan Paiva, Brasil
E-mail: gs.odonto@gmail.com

Caio Vinícios Gonçalves Roman Torres

ORCID: <https://orcid.org/0000-0001-9864-6894>
Universidade Santo Amaro, Brasil
E-mail: Cvgrt@hotmail.com

Heloisa Fonseca Maranhão

ORCID: <https://orcid.org/0000-0002-6128-8576>
Universidade Santo Amaro, Brasil
E-mail: hfmaraao@prof.unisa.br

Wilson Roberto Sendyk

ORCID: <https://orcid.org/0000-0002-3742-1330>
Universidade Santo Amaro, Brasil
E-mail: wilsen@terra.com.br

Angélica Castro Pimentel

ORCID: <https://orcid.org/0000-0002-6317-6439>
Universidade Santo Amaro, Brasil
E-mail: draangelicacp@uol.com.br

Abstract

Dentistry, like all science, is growing and improving its techniques. The immediate load is proof of this in the implantology area. Implants are inserted in a single session, and after a few hours the prosthesis is installed on the implants, allowing the patient to chew and return to social life. Among the basic requirements for its implementation is a judicious study of each case. Patients are subjected to careful evaluation of their systemic and occlusal health and of their bone volume and bone quality, which allows immediate fixation of the implant to the bone. Conventionally, the implant is fixed in the bone bed and is subjected to a second surgical intervention within 4 to 6 months to expose the prosthetic contact surface and place the prosthesis definitively. In the immediate load, the titanium fixation is attached to the bone and then the fixed prosthesis is installed in a single session. Our objective is to conduct a literature review on the current stage of implants with immediate load in the jaw and to describe an accompanying 1-year clinical case. With the current survey of the topic, we observe that the immediate load in the jaw is still a viable alternative to rehabilitation in edentulous patients.

Keywords: Edentulous Jaw; Dental Implant loading, Immediate; Implant-Suported Dental Prosthesis.

Resumo

A odontologia, como toda ciência, está crescendo e aprimorando suas técnicas. A carga imediata é a prova disso na área de implantologia. Os implantes são inseridos em uma única sessão, e após algumas horas a prótese é instalada sobre os implantes, permitindo ao paciente mastigar e retornar ao convívio social. Entre os requisitos básicos para sua implementação está um estudo criterioso de cada caso. Os pacientes são submetidos a uma avaliação cuidadosa de sua saúde sistêmica e oclusal e de seu volume ósseo e qualidade óssea, o que permite a fixação imediata do implante ao osso. Convencionalmente, o implante é fixado no leito ósseo e é submetido a uma segunda intervenção cirúrgica em 4 a 6 meses para expor a superfície de contato da prótese e colocar a prótese definitivamente. Na carga imediata, a fixação de titânio é fixada ao osso e a seguir a prótese fixa é instalada em uma única sessão. Nosso objetivo é realizar uma revisão da literatura sobre o estágio atual dos implantes com carga imediata na mandíbula e descrever um caso clínico de 1 ano que o acompanha. Com o atual levantamento do tema, observamos que a carga imediata na mandíbula ainda é uma alternativa viável para reabilitação em pacientes desdentados.

Palavras-chave: Mandíbula Edêntula; Carregamento de Implante Dentário, Imediato; Prótese Dentária Implanto Suportada.

Resumen

La odontología, como toda ciencia, está creciendo y mejorando sus técnicas. La carga inmediata es prueba de ello en el área de implantología. Los implantes se insertan en una sola sesión, y al cabo de unas horas se instala la prótesis sobre los implantes, lo que permite al paciente masticar y volver a la vida social. Entre los requisitos básicos para su implementación se encuentra un estudio juicioso de cada caso. Los pacientes son sometidos a una cuidadosa evaluación de su salud sistémica y oclusal y de su volumen óseo y calidad ósea, lo que permite la fijación inmediata del implante al hueso. De manera convencional, el implante se fija en el lecho óseo y se somete a una segunda intervención quirúrgica en el plazo de 4 a 6 meses para exponer la superficie de contacto protésica y colocar la prótesis definitivamente. En la carga inmediata se fija la fijación de titanio al hueso y luego se instala la prótesis fija en una sola sesión. Nuestro objetivo es realizar una revisión de la literatura sobre el estado actual de los implantes con carga inmediata en el maxilar y describir un caso clínico de 1 año acompañante. Con el relevamiento actual del tema, observamos que la carga inmediata en la mandíbula sigue siendo una alternativa viable a la rehabilitación en pacientes edéntulos.

Palabras clave: Mandíbula Edéntula; Carga de Implantes Dentales, Inmediata; Prótesis Dental Suportada por Implantes.

1. Introduction

Osseointegration, the direct anchorage of a bone to a titanium surface, can provide a foundation to support a prosthesis. According to HOB0 et al., (1997), this means that the implant must be made of inert material to directly contact the bone tissue without soft tissue interface. Oral rehabilitation of total or partial edentulous patients in the use of osseointegrated implants has demonstrated a high level of predictability and success (Bezerra, et al., 2003).

The control of the surgical technique as well as efficient planning produce biomechanical factors favorable to the distribution of functional loads. These factors determine the high percentage of success. Obtaining an osseointegrated interface depends fundamentally on the realization of an atraumatic surgical procedure, the submersion of the anchorages during the period of osseointegration, and the free healing of any type of direct load on the implants (Branemark, et al., 1977).

The treatment of total edentulous patients with implants can be made with fixed prostheses or removable prostheses. In both treatment models, the immediate load protocol has been applied. For this reason, it is recommended that the implants be joined by a metallic structure minimizing micro and macro movement. Obviously, other factors such as bone remodeling and the number and positioning of implants interfere with the selection of the treatment (Gatti, et al., 2000).

The installation of implants based on the concepts of Branemark is considered a reference for the various forms of rehabilitation. This technique consists of two surgical procedures (installation of the anchorages and connection of the intermediate pillars) and must respect a waiting period of 3 to 4 months in the lower jaw and 5 to 6 months in the upper jaw (Dinato & Polido, 2004).

The first work on immediate load in the Branemark system happened in a 1990 study with the purpose of developing a method to provide provisional fixed prostheses to patients at the time of implant installation (Schnitman, et al., 1990).

Currently, crosscutting and longitudinal studies have proposed using the immediate-load protocol function in selected cases within strict criteria in order to create a shorter, simpler rehabilitation period for dental implants with a lower final cost for the patient (Bezerra, et al., 2003; Horita, et al., 2017).

The immediate-load protocol was proposed with the implant to offer important advantages such as fewer surgical interventions, less time between the insertion of implants and the final prosthetic restoration, and consequently lower cost with greater patient satisfaction (Thomé et al., 2004). This introduced the concept of implants placed in 1 surgical procedure where the healer is installed at the time of the implant's implantation rather than waiting for the healing period to perform the second surgical stage (Bottino, et al., 2005; Lopez, 2005).

Several studies have shown that implants in the anterior region of the jaw immediately loaded with a preexisting prosthesis produce clinical results equal to immediate and late protocol in the first 5 years after implant surgery (Jokstad & Alkumru, 2014).

For the use of the immediate load, it is necessary to have prior experience and training in the area of implantology, to have carried out a thorough diagnosis with radiographic studies, to have information about the quality of the bone, and to have knowledge of the prosthesis and surgery. In addition, all cases that occur because of functions and habits should be eliminated. Patients with immunity deficits, coagulation problems, uncontrolled mellitus diabetes, and psychiatric illnesses should also be discarded. Our practical advice recommends not using this technique on smokers who consume more than 10 cigarettes a day because personal experience indicates that all failures occurred in such patients despite the magnificent general results (Lopez, 2005).

From the surgical point of view, the main objective is to achieve the primary stability of the implants, which is indispensable to an osseointegration of implants submitted to immediate load (Vasconcelos, et al., 2001). Several studies have shown that the success of long-term implants is linked to the fixation of a bicortical. There should be a good quantity of quality bone tissue that allows an insertion force of at least 32 N/cm using implants no less than 10 mm long with excellent primary stability (Lopez, 2005). Elements indispensable to the success of immediate load are well-adjusted prostheses, a rigid connection between the implants by means of a metallic infrastructure, a preference for fixed prostheses over removable, patient selection, surgical and prosthetic techniques, following preestablished protocols, and not removing the fixed prosthesis or splint from the implants for 4 months (Vasconcelos, et al., 2001).

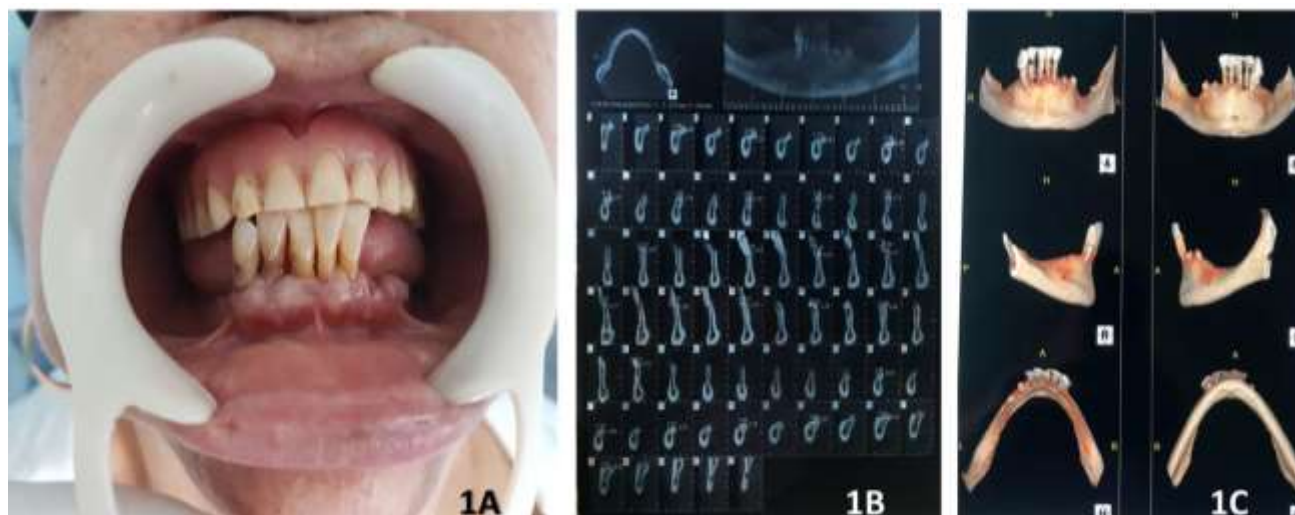
The main objective of this work is to carry out a review of literature on the current stage of implants with immediate load in the jaw with a description of an accompanying 1-year clinical case.

2. Methodology

Initially, the work was submitted to the research ethics committee. To participate in the research, the patient signed a free and informed consent form and all the ethical principles of the Declaration of Helsinque were respected.

A 63-year-old female patient attended the clinic of Prof. Javan Paiva with a total prosthesis in the upper jaw, a removable lower-jaw prosthesis with poor adaptation, and teeth compromised by periodontal problems (Figure 1a). The patient was recommended rehabilitation with osseointegrated implants, and thus preexaminations and an image examination were requested: computed jaw cone beam of the mandible (Figure 1b and 1c), plaster models, and laboratory tests (CBC, glucose, and coags).

Figure 1: 1a: Initial photo of the patient demonstrating the use of the superior total prosthesis and severe periodontal commitment of the lower elements; 1b and 1c: Computed tomography of the jaw beam.



Source: The authors.

The patient agreed to a new total prosthesis for the upper arch and removal of the teeth and lower root debris with a subsequent installation of an immediate-load prosthesis on implants in the mandible.

A preoperative corticosteroid medication, Diprosan®, was prescribed with in-musculature administration 24 hours before the procedure.

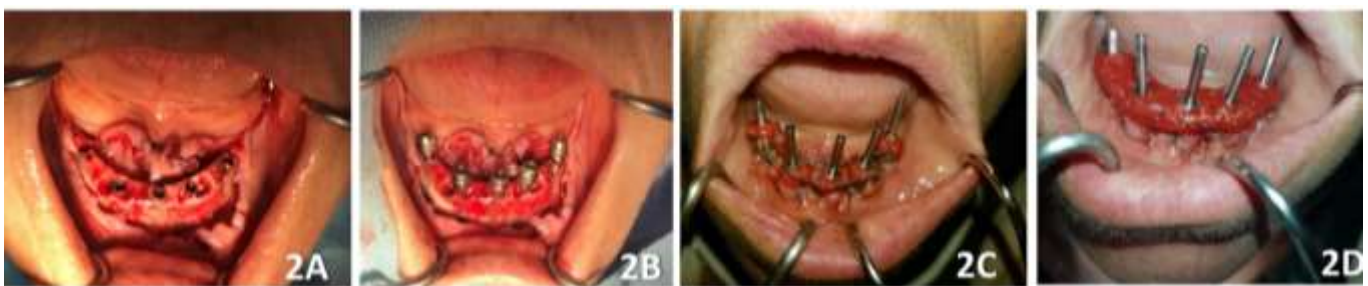After performing a chlorhexidine mouthwash at 0.12% for 1 minute, local anesthesia was performed with Prilocaine hydrochloride with Felipressina. The surgery started with the extraction of elements 32, 31, 41, 42, and 43 and the extraction of residual roots 33 and 34. After regularizing the bone edge with a maxcut drill, the drilling was initiated for the installation of the implants following the manufacturer's specifications. Accordingly, the implants of the Neodent® Cone Morse were installed with the following measurements: 3.5 mm by 17 mm in the 45 region, 3.5 mm by 15 mm in the 43 region, 3.75 mm by 13 mm in the 31 region, 3.5 mm by 15 mm in the 33 region, and 3.5 mm by 17 mm in the 35 region with a torque of 45 N, 20 N, and 60 N, respectively (Figure 2a).

The minipillars were selected with the following height: 2.5 mm in implants 45, 43, and 33 at 2.5 mm, implant 31 at 1.5 mm, and implant 35 at 2.5 mm and angled from 17° (Figure 2b). After placing the healers on the minipillars, the suture was wired with 4.0 monnylon wire.

The patient used an antibiotic once a day (875 mg of Velamox BD® for 7 days), an inflammatory once a day (60 mg of Arcoxia® for 5 days), and the analgesic Sonridor CAF® for 2 days (6/6 hours) as postoperative medication. The use of Periogard (12/12 hours for 7 days) and cryotherapy were also recommended. Recommendations also included eating cold foods (preferably ice cream), liquids, or blends; avoiding physical exertion; and using a pillow when laying down for height and absolute rest.

The next day, the molding began by placing the transferences and uniting them with Patern® resin and steel wires. Then the molding with open tray was performed using addition silicone. Analogues were placed in the odontological tray and joined with steel wires and Patern Resin® (Figure 2c and 2D), and then the plaster was leaked (TipoIV).

Figure 2: 2a-installed implants; 2b: Implants with their respective minipillars and protective cylinders; 2c and 2d: Open tray transfers united with metallic wire attached with resin.

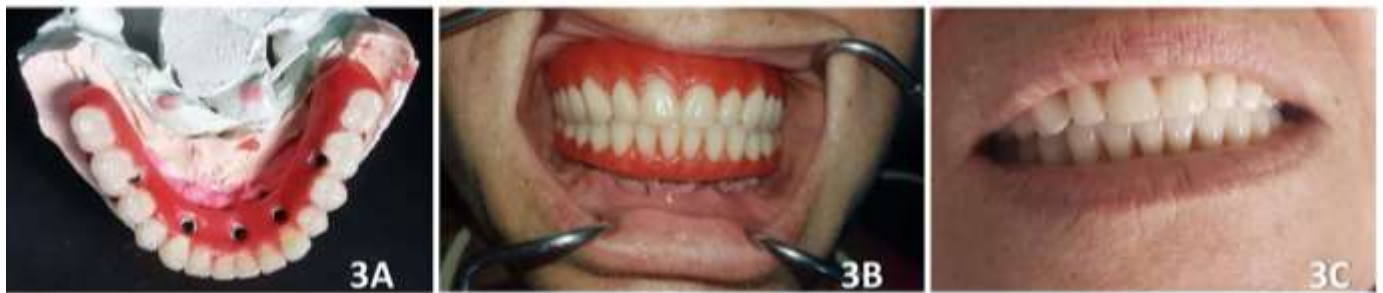

Source: The authors.

In the early afternoon, the metal structure was tested, the bite ratio was removed, and the teeth color was chosen. After this procedure and still on the same day, the proof of the teeth was mounted on wax and the selection of the gum color of the protocol and of the total prosthesis (Figure 3a and 3b) were sent to the laboratory for pressing.

The following day the protocol type prosthesis was installed and then the occlusal adjustment was performed (Figure 3c). The patient returned the following week for suture evaluation and removal.

Figure 3: 3a: wax-mounted teeth on the metallic structure; 3b: proof of wax-mounted teeth: superior total prosthesis and lower protocol; 3c: installation of upper total prosthesis and the lower protocol.



Source: The authors.

3. Discussion

For decades, the use of bone implants by Branemark has demonstrated high levels of predictability and clinical success through the protocol of two surgical stages separated by a period of scar formation responsible for stabilizing the bone/implant interface prior to conventional prosthetic loading for cases of total edentulism (Adel, et al., 1990; Branemark, et al., 1977) or partial dental losses (Bezerra, et al., 2003).

However, immediate functional load protocol with the prosthetic-installation rehabilitation immediately after the implant-installation surgery has been used increasingly steadily and frequently in specific publications (Lenharo & Cosso, 2002; Piatelli, et al., 1993; Schnitman, et al., 1990; Trento, et al., 2012; Vasconcelos, et al., 2001). They are seeking to simplify treatment with implants without compromising aesthetic and functional objectives while also achieving a level of predictability beyond that of treatment with the traditional late-load protocol (Bezerra, et al., 2003), thus conducting less exposure to surgical procedures and the return of aesthetic more quickly (Serson, 2001), as noted in the clinical case.

The control of the technique, efficient planning, favorable biomechanical factors, and the distribution of functional loads seem to determine the high level of success (Branemark, et al., 1977; Vasconcelos, et al., 2001). Other authors report that for success there may be no micromovations above 100 micrometers⁶ or greater than 150 micrometers (Grisi & Marcantonio, 2002; Soballe, et al., 1993; Thomé, et al., 2004; Uribe, et al., 2005). It is recommended that the implants be joined by a metallic structure minimizing micro and macromovations (Gatti, et al., 2000; Vasconcelos, et al., 2001).

The high level of security presented by several research centers monitored for decades encouraged Branemark to make modifications to the original protocol, including the installation of fixtures after extraction in a surgical stage and immediate charge. The main modifications refer to a rigid structure on four fixations installed between the mental foramen and the reduction of the conventional osseointegration period. This new system was named Branemark Novum (Branemark, et al., 1999). Others suggest the placement of three triangular-shaped implants (Schnitman, et al., 1990).

Five-year longitudinal studies demonstrated the same level of bone resorption compared to the original protocol (Ericsson, et al., 2000). In other studies, implants in immediate function are rigidly splinted (Lenharo & Cosso, 2002; Thomé, et al., 2006; Vieira, et al., 2006) with an overdenture and act similarly to implants restored in a conventional manner (Chiapasco, et al., 2001; Nishioka, et al., 2003; Piatelli, et al., 1993), which is confirmed when one of the factors of detection of the immediate load is the primary stability (Sakamoto, et al., 2012; Sendyk & Sendyk, 2002).

The Branemark system became a benchmark for immediate loading. They installed 5 to 6 fixations in the anterior region of the mandible and 1 distal to each protuberance. Protect pillars were connected during surgery to the 2 distal anchorages and to 1 in the previous region, and the remaining ones were controls. This particularity did not harm

osseointegration when compared to submerged anchorages (Schnitman, et al., 1990). A similar system verified that this option of 4 fixations in the anterior region of the jaw does not affect the process of osseointegration (Henry & Rosenberg, 1994). A rigid splinting, with minimal application of shear loads, is a proposed factor for osseointegration (Nishioka, et al., 2003; Pi-Urgell, et al., 2005; Tarnow, et al., 1997; Vasconcelos, et al., 2001). Reportedly, a rigid provisional restoration should be pursued so that no reflection forces are produced (Jreige, et al., 2010; Thomé, et al., 2006).

The patient should be analyzed in order to eliminate all cases with functions and habits that could cast shadows on a favorable prognosis (Sendyk & Sendyk, 2002). Patients with immunity deficits, clotting problems, uncontrolled mellitus diabetes, and psychiatric disorders should also be discarded. As practical advice, we recommend not using this technique in smokers consuming more than ten cigarettes a day because personal experience indicates that all failures occurred in such patients despite the magnificent overall results (Lopez, 2005). Bottino, et al., (2005) indicate factors that limit the realization of the immediate load: unfavorable conditions for rehabilitation, active infections in the regions envisaged for implant placement, systemic diseases that are not controlled and may compromise the osseointegration, patients who have undergone radiotherapy for the treatment of malignant tumors in the skull-facial region in the last 12 months, and smokers who do not temporarily quit smoking.

With the current survey of the *Journal of Literature* and with the clinical case, we can observe that the immediate load on the jaw still is a viable alternative to rehabilitation in edentulous patients.

4. Conclusion

As observed clinically and through a bibliographic survey, the immediate load on the lower jaw has been a viable alternative to rehabilitation with osseointegrated implants. My suggestion for future research would be the description of a clinical case of immediate load on the mandible through the digital protocol.

References

- Adel, R., Eriksson, B., Lekholm, U., Branemark, P-I., & Jemt, T. (1990). Long term follow-up study of Osseointegrated Implants in the Treatment of the Totally Edentulous jaw. *International Journal Oral Maxillofac Implants*, 5, 347-359.
- Bezerra, F., Souza, S. W., Duarte, L., & R. REGIS, M. B. (2003). Protocolo de Carga Imediata Funcional: Relato de Caso Clínico. *Innovations Journal*, 7(1), 6-13.
- Bottino, M. A., Klee-Vasconcelos, P., & Avelas, R. P. (2005). Implantes Odontológicos com Função Imediata em Edentulos Mandibulares. In: *Implantologia: Atuação Clínica Baseada em Evidências Científicas*. São Paulo: Artes Médicas, 131-159.
- Branemark, P-I., Hansson, B. O., Adell, R., Breine, O., Lindstrom, H., Hallen, O., & Oilman, A. (1977). Osseointegrated Implants in the Treatment of the edentulous jaw. Experience from a 10-year period. *Scan J Plast Reconstr Surg Hand Surg*, 11, 16.
- Branemark, P. I., Engstrand, P., Ohnell, L. O., Grondahl, K., Nilsson, P., & Hagberg, K. (1999). Branemark Novum: a new treatment concept for rehabilitation of the edentulous mandible. Preliminary results from a prospective clinical follow-up study. *Clin Implant dent Relat Res*, 1 (1), 2-16.
- Brunski, J. (1992). In Vivo Bone Response to Biomechanical Loading at The bone/dental Implantinterface. *Clin Materials*, 3, 153-201.
- Chiapasco, M., Abati, S., Romel, E., & Vogel, G. (2001). Implant-retained Mandibular Overdentures with Branemark System MKII Implants: a Prospective Comparative Study Between Delayed and Immediate Loading. In *J Oral Maxillofac Implants*, 6 (4), 537-546.
- Dinato, J. C., & Polido, W. D. (2004). Implantes Osseointegrados: Cirurgia e Prótese. *Artes Médicas: Divisão Odontológica*. 215-241.
- Ericsson, I., Randow, K., Nilner, K., & Peterson, A. (2000). Early Functional Loading of Branemark Dental Implants: 5 year Clinical Follow-up Study. *Clin Implant Dent Rel res*, 2 (2), 70-77. doi.10.1111/j.1708-8208.2000.tb00108.x
- Gatti, C., Haefliger, W., & Chiasco, M. (2000). Implant-retained Mandibular Over-dentury with Immediate Loading: a Prospective Sstudy of ITI Implants. *Int Oral J Maxillofac Implants*, 15, 383-388.
- Grisi, D. C., & Marcantonio JR, E. (2002). Aplicação de Carga Imediata em Implantes Dentais. *BCI*, 9 (34), 111-116.
- Henry, P.J., & Rosenberg, I. (1994). Single Stage Sugery for Rehabilitation of Edentulous Mandible: Preliminary results. *Pract Periodont Aesthetic dent*, 6, 1-9.

- Horita, S., Sugiura, T., Yamamoto, K., Murakami, K., Imai, Y., & Kirita, T. (2017). Análise biomecânica de implantes imediatamente carregados de acordo com o conceito "All-on-Four". *Journal of Prosthodontic Research*, 61 (2), 123-132. doi: 10.1016/j.jpor.2016.08.002
- Jokstad, A., & Alkumru, H. (2014). Immediate function on the day of surgery compared with a delayed implant loading process in the mandible: a randomized clinical trial over 5 years. *Clin. Oral Impl.* 25, 1325–1335. doi: 10.1111/clr.12279
- Jreige, A., Andrade, C.L., & Gebrim, L.T. (2010). Protocolo de Carga Imediata em região de Mandíbula. *Revista Odontológica do Planalto Central*, 1 (1), 28-34.
- Lenharo, A., & Cosso, F. (2002). Utilização dos Implants de um Único Tempo Cirúrgico como Opção de Tratamento: Relato de um Caso Clínico. *Innovations Journal*, 6 (1), 5-12.
- López, V. J. (2005). *Carga ou Função Imediata em Implantodontia.: Aspectos Cirúrgicos, Protéticos, Oclusais e de Laboratório*. São Paulo: Quintessence.
- Nishioka, R. S., Bottino, M. A., Souza, F. A., & Lopez, A. G. (2003). Carga Imediata e Restauração Protética Definitiva com Pilares Protéticos Personalizados. *RBP- Revista Brasileira de Implantodontia & Prótese sobre implantes*, 10 (38), 98-102.
- Piatelli, A., Ruggeri, A., Franchi, M., Romasco, N., & Trisi, P. (1993). An histologic and Histomorphometric Study Bone Reactions to Unloaded and Loaded Non-submerged Single Implants in Monkeys: a Pilot Study. *J Oral Implantol*, 19, 314-320.
- Piatelli, A., Paolantonio, M., Corigliano, M., & Scarano, A. (1997). Immediate loading of Titanium Plasma-sprayed screw-shaped implants in man: a clinical and histological report of two cases. *J. Periodontol*, 68 (6), 591-597. doi: 10.1902/jop.1997.68.6.591.
- Pi- Urgell, J., & Vericat-Queralt, J. A. (2002). Branemark Novum: Una Alternativa para la Rehabilitación del Maxilar Inferior Desdentado. *RCOE*. 10 de agosto de 2005, 7 (1). From <http://scielo.isciii.es/scieib>
- Sakamoto Junior, A. S., Martins, A. S., Verde, F. A. V., Santos, F. A., & Pilatti, G. L. (2012). Função Imediata em Implantes Unitários: Revisão de Literatura. *Braz J Periodontol*, 22, 17-22.
- Schnitman, P. A., Wohrl, P. S., & Rubenstein, J. E. (1990). Immediate Fixed Interim Prosthesis Supported by two-stage. Threaded Implants: Methodology and Results. *J Oral Implantol*, 16 (2), 96-105.
- Sendyk, W. R., & Sendyk, C. L. (2002). Carga Imediata em Implantodontia. In: *Periodontia, Cirurgia para Implantes, Cirurgia e Anestesia: 20º Arte, Ciência, técnica*. São Paulo: Artes Médicas, 5, 489-505.
- Serson, D. (2001). Nova Técnica para Instalação de Implantes Osseointegrados. *JADA- Brasil*, 4, 178-183.
- Soballe, K., Hansen, E. S., Brockstedt-Rasmussen, H., & Bunger, C. (1993). The Effects of Osteoporosis, Bone Deficiency, Bone Grafting and Micromotion on Fixation of Porous-coated Hydroxyapatite-coated Implants. In: Gesink, RGT e Manley MT eds. *Hydroxyapatite Coatings in Orthopedic Surgery*, 107-136.
- Tarnow, D. P., Emtiaz, S., & Classi, A. (1997). Immediate Loading of Threaded Implants at Stage 1 Surgery in Edentulous Arches: ten Consecutive Case Reports with 1 to 5 year data. *Int J Oral Maxillofac Implant*, 12, 319-324.
- Thomé, G., Hermann, C., Melo, A. C. M., Molinari, A. R. D. M., Vieira, R. A., & Ponzoni, D. (2006). Utilização da Técnica da Barra Distal em Mandíbulas Edêntulas com Carga Imediata. *RGO, P. Alegre*, 54 (2), 165-168.
- Thomé, G., Molinari, A. R. D. M., & Melo, A. C. M. (2004). Carga Imediata em Mandíbulas Edêntulas: Uma Alternativa Reabilitadora com Barras Pré-fabricadas. *Implant News*, 1 (4), 25-33.
- Trento, C. L., Moreschi, E., Zamponi, M., Zardeto Junior, R., Gottardo, V. D., & Costa, D. G. (2012). Implantes Cone Morse com Carga Imediata: Relato de Caso Clínico. *Odontol. Clin. Cient., Recife*, v. 11, n. 2, p. 159-164, abr./jun., 2012.
- Uribe, R., Peñarocha, M., Balaguer, J., & Fulgueiras, N. (2005). Carga Inmediata em Implantologia Oral: Situación Actual. *Méd Oral Patol Oral Cir. Bucal*, 10, 143-153.
- Vasconcelos, L. W., Francischone, C. E., Lima, E. G., & Takagui, R. M. (2001). Carga Imediata para reabilitação de mandíbulas desdentadas. In: Polido, W. D., & Dinato, J. C. *Implantes osseointegrados: cirurgia e prótese*. São Paulo: Artes Médicas, 1, 465-476.
- Vieira, R. A., Souza, J. R., Thomé, G., Melo, A. C. M., & Sartori, I. A. M. (2006) Neopronto: Reabilitação de Mandíbulas Edêntulas com Barras Pré-fabricadas. *RGO, Porto Alegre*, 54 (3), 254-260.