

Hair removal with High Power Light-Emitting Diode (LED) – Evaluation by Infra-red Thermography: a pilot study

Remoção de Pelos com LED de Alta Potência – Avaliação por Termografia Infravermelha: um estudo piloto

Depilación con Diodo Emisor de Luz (LED) de alta potencia - Evaluación por Termografía Infrarroja: un estudio piloto

Received: 09/09/2021 | Reviewed: 09/15/2021 | Accept: 09/17/2021 | Published: 09/26/2021

Rodrigo Alvaro Brandão Lopes-Martins

ORCID: <https://orcid.org/0000-0003-4942-988X>
Universidade Brasil, Brazil
E-mail: ralopesmartins@gmail.com

Débora Rodrigues de Moraes

ORCID: <https://orcid.org/0000-0002-4768-9330>
Instituto de Pesquisas e Desenvolvimento Adoxy, Brazil
E-mail: fisio.deborarodrigues@gmail.com

Felicia Cadenas de Paiva Bueno

ORCID: <https://orcid.org/0000-0003-1283-7628>
Instituto de Pesquisas e Desenvolvimento Adoxy, Brazil
E-mail: feliciabueno44@gmail.com

Mayara Oguri

ORCID: <https://orcid.org/0000-0001-7473-3125>
Instituto de Pesquisas e Desenvolvimento Adoxy, Brazil
E-mail: Mah_oguri@yahoo.com.br

Ingrid Batista de Souza Gallacci

ORCID: <https://orcid.org/0000-0001-7577-5271>
Instituto de Pesquisas e Desenvolvimento Adoxy, Brazil
E-mail: fisio.ingridsouza@outlook.com

Aline Cirino de Oliveira

ORCID: <https://orcid.org/0000-0002-5554-3198>
Instituto de Pesquisas e Desenvolvimento Adoxy, Brazil
E-mail: cirino_aline@hotmail.com

Patrícia Sardinha Leonardo

ORCID: <https://orcid.org/0000-0002-7662-7702>
Universidade do Vale do Paraíba, Brazil
E-mail: patyssardinha@gmail.com

Carlos Ruiz da Silva

ORCID: <https://orcid.org/0000-0002-6331-6032>
Universidade Brasil, Brazil
E-mail: fisiocarlosruiz@gmail.com

Abstract

Introduction. Photoepilation use different light sources to remove unwanted body hair. The most common light sources used for permanent hair removal are diode lasers and intense pulsed light. Light assisted hair removal is based on the destruction of the follicular unit. The ability to remove hair without damaging the surrounding skin is based on selective photothermolysis, however, occurrence of side-effects such as pain and skin burning is reported for lasers and intense pulsed light. **Objective.** Here we investigate in a pilot study of a newly approved technology of High power LED with cooled probe, possible changes in skin temperature evaluated by infra-red thermography as well as acute and 24h sensitivity and pain by Visual Analogue Scale. **Methods.** Five participants with no restrictions of skin phototype were included in the pilot study. Skin Temperature was monitored before and after (30s, 5 and 10 min) after LED photoepilation, besides instant and 24h pain. **Results.** Nor significant increases on skin temperature and no 24h pain or any side-effects were reported. Acute pain during procedure ranged from 2 – 4 (VAS). **Conclusion.** High power LED with cooled probe seems to be a safe and efficient technology for photoepilation.

Keywords: Photoepilation; LED; LASER; Hair Removal.

Resumo

Introdução. A fotoepilação usa diferentes fontes de luz para remover pelos indesejáveis. As fontes de luz mais comuns usadas para depilação permanente são os lasers de diodo e a luz pulsada intensa. A depilação com luz assistida baseia-se na destruição da unidade folicular. A capacidade de remover pelos sem danificar a pele ao redor é baseada na fototermólise seletiva, no entanto, a ocorrência de efeitos colaterais como dor e queimação na pele é relatada para lasers e luz intensa pulsada. **Objetivo.** Aqui nós investigamos em um estudo piloto de uma tecnologia recentemente aprovada de LED de alta potência com sonda resfriada, possíveis mudanças na temperatura da pele avaliadas por termografia infravermelha, bem como sensibilidade aguda e 24h e dor por Escala Visual Analógica. **Métodos.** Cinco participantes sem restrições de fototipo de pele foram incluídos no estudo piloto. A temperatura da pele foi monitorada antes e depois (30s, 5 e 10 min) após a fotoepilação com LED, além de dor instantânea e 24h. **Resultados.** Nem aumentos significativos na temperatura da pele e nenhuma dor 24 horas ou quaisquer efeitos colaterais foram relatados. A dor aguda durante o procedimento variou de 2 a 4 (VAS). **Conclusão.** LED de alta potência com sonda resfriada parece ser uma tecnologia segura e eficiente para fotoepilação.

Palavras-chave: Fotoepilação; LED; LASER; Remoção de Pelos.

Resumen

Introducción. La fotodepilación utiliza diferentes fuentes de luz para eliminar el vello corporal no deseado. Las fuentes de luz más comunes que se utilizan para la depilación permanente son los láseres de diodo y la luz pulsada intensa. La depilación asistida por luz se basa en la destrucción de la unidad folicular. La capacidad de eliminar el vello sin dañar la piel circundante se basa en la fototermólisis selectiva; sin embargo, se informa de la aparición de efectos secundarios como dolor y quemaduras en la piel para los láseres y la luz pulsada intensa. **Objetivo.** Aquí investigamos en un estudio piloto de una tecnología recientemente aprobada de LED de alta potencia con sonda enfriada, posibles cambios en la temperatura de la piel evaluados por termografía infrarroja, así como sensibilidad y dolor agudo y de 24 horas por escala analógica visual. **Métodos.** Se incluyeron en el estudio piloto cinco participantes sin restricciones de fototipo de piel. La temperatura de la piel se monitorizó antes y después (30s, 5 y 10 min) después de la fotodepilación con LED, además del dolor instantáneo y de 24h. **Resultados.** No se informaron aumentos significativos en la temperatura de la piel y no se informó dolor de 24 horas ni efectos secundarios. El dolor agudo durante el procedimiento varió de 2 a 4 (EVA). **Conclusión.** El LED de alta potencia con sonda refrigerada parece ser una tecnología segura y eficiente para la fotodepilación.

Palabras clave: Fotodepilación; LED; LASER; Depilación.

1. Introduction

Photoepilation is generic term currently employed to denominate a common method using different light sources to remove unwanted body hair including in androgenic hirsutism (Matheson & Bain, 2019). A hairless body is a modern tendency of both women and men in the present days. The most common light sources used for permanent hair removal are diode lasers, intense pulsed light (IPL) (Marijke et al, 2019; Zandi & Lui, 2013;) and more recently LEDs.

Laser-assisted photo epilation was originally described in 1996 and the proposed mechanism is based on the destruction of the follicular unit (Grossman et al, 1996). During the past decade, laser hair removal has become an accepted and popular means of achieving hair reduction (Aimonetti & Ribot-Ciscar, 2016; Ibrahim et al, 2011).

During photoepilation light is selectively absorbed by the melanin in the growing hair follicle (HF), resulting in a local temperature increase. The ability to remove hair without damaging the surrounding skin is based on selective photothermolysis (Anderson & Parrish 1983; Altshuler et al, 2001). This temperature increase depends on the parameters of the light source (wavelength, pulse duration, energy density) and on the hair Follicle properties (Ayatollahi et al, 2019).

Diode laser has been demonstrated to be an effective method for hair removal, however, the safety of patients with different skin types and colours is questionable due to thermal damage as the main side-effect. According to Cohen et al (2021), laser photoepilation is responsible for few side-effects. However, the authors mention that their results are limited by the small number of controlled and long-term clinical trials. Essentially, laser-induced hair removal depends on the effects of light interaction with the chromophore which can be found in the hair but also in skin in different amounts. Melanin contents are frequently related to photoepilation side-effects (Atta-Motte & Załęska 2020).

The literature reports on such adverse effects and complications resulting from photoepilation, including paradoxical

hyperkeratosis, post-inflammatory discoloration, aggravation of acne, rosacea-like rash, prolonged diffuse redness, burning skin sensation. Burned skin and others (Zaleska & Atta-Motte 2019; Honeybrook et al, 2018; Bibilash et al, 2017; Radmanesh, 2009; Radmanesh et al, 2008;). Practitioners rarely analyse the ethnic background of the patients what may result in several side-effects mostly caused by excessive temperature increases. Skin-types IV-V demands attention and special light parameters of photoepilation (Tahiliani & Tahiliani, 2016). Patients who undergo laser hair reduction procedures may expect skin irritation, erythema, edema, postoperative hypersensitivity and possible burns manifested by blisters and scabs. Atta-Motte and Zaleska (2020) reported that the occurrence of burns depended on ethnicity and on the number of treatments. Increases in skin temperature seems to be one of the most important factors responsible for burns and burn-related lesions. In this context, prevention of temperature increases in skin can be an effective strategy to prevent photoepilation-induced side effects.

Here we investigated in a pilot study, the effects of LED-induced hair removal of the legs on skin temperature using an infra-red thermography of the skin. We also analysed the immediate and 24h pain and discomfort of 6 female volunteers (12 legs).

2. Methodology

The study was designed and conducted in accordance with the Declaration of Helsinki, and principles of Good Clinical Practice (GCP). All subjects were completely informed about the procedure and its side effects and written informed consent to participate in the study was obtained from the subjects at baseline. This is a pilot study performed to evaluate possible temperature increases. The LED-based technology for hair removal (Holonick®) is approved for commercial use by the National Health Surveillance Agency of Brazil (ANVISA) and by the National Metrology Institute (INMETRO) for safety.

Participants

Six female participants (20 – 40 years old) were submitted to 6 monthly sessions of LED-induced hair removal. They were instructed to avoid any cosmetic products at least 24 hours before LED irradiation and to shave the legs 24 – 48h prior irradiation.

The volunteers upon arriving at the laboratory were accommodated on a hospital stretcher for a period of 15 minutes for acclimation to ambient conditions. The ambient temperature and relative humidity were recorded and entered in the thermographic camera software for automatic corrections and calibrations. Thermographic images of basal conditions after acclimation as well as an image after contact gel application and also after LED irradiation (30s, 5 min and 10 min) were recorded. A total of 5 images for each participant were then recorded for skin temperature analysis.

Inclusion criteria

Body Mass Index (BMI = Weight / Height²) up to 29.9 kg / m²; having regular menstrual cycles (between 26 and 30 days) and having used the same oral contraception in the last 3 months, stable weight for at least 3 months (less than 2.0 kg variation); sedentary and without the use of cosmetics that work in the local circulation. Participants were asked to refrain from using any cosmetic product with retinoids, Dimethylaminoethanol (DMAE), alpha-hydroxy acid (AHA) or beta-hydroxy acid (BHA) for 1 month before the start of the study.

Exclusion criteria

The following factors were considered exclusion criteria: a) pathology or injury at the legs; b) Possible or confirmed pregnancy; c) Metallic prosthesis close to the site of irradiation; d) Menopause; e) Any recent surgery on the area of LED application; f) Use of medications such as NSAIDs, corticosteroids or antibiotics during the study period; g) history of

photosensitivity; h) porphyria or any other hematological disease;

Thermographic Image acquisition

Image acquisition was performed with the S65 camera (FLIR system, Sweden). The FLIR S65 Camera has a measurement range of -20°C to 120°C , accurate to 1%, sensitivity of 0.05°C , infrared spectral band of 7.5 and 13 μm , refresh rate of 60 Hz, autofocus and a resolution of 320X240 pixels. The camera was mounted on a tripod and aligned perpendicular to the surface of interest. The distance to the site was adjusted to 50 cm, allowing you to see a wide field of view. The hip temperature was monitored before (basal temperature) and after irradiation at 3 different times (30s, 5 and 10 minutes).

Environmental conditions

All measurements were carried out in a controlled environment with a temperature adjusted to $21 \pm 2^{\circ}\text{C}$ and a relative humidity of $60 \pm 5\%$. The images of posterior lateral views of the lower limbs were taken in the morning period with the objective of physiological standardization.

The thermal images were analyzed one by one using the equipment's software. The average temperature and the maximum amplitude, corresponding to the difference between the extremes, were calculated from the original images. All the images were analysed by a blinded physiotherapist that was not informed about the time of the image. At the end of the analyses, the images were identified and values were reported in an excel file.

LED (Holoniak) Treatment

A High potency LED equipment (Holoniak® – Adoxy Equipments – Sorocaba – SP) was used. The LED allows the therapist to customize illumination parameters according to the sensitivity of the patients. Technical characteristics are described below in Table 1.

Table 1 – LED Parameters.

Light Source	NIR LED
Wavelength Band	780 – 850 nm
Peak Power	1200 W
Output Power	840 W
Operation modes	Scanning or Single shot
Pulse width	5 – 750 ms adjustable
Fluence	5 – 100 J/Cm ² adjustable
Spot Size	17 X 22 mm
Spot Cooling	10 to -15°C

Source: Authors.

All participants were submitted to an initial sensitivity test to the LED irradiation, in order to determine adequate parameters to each participant. Sensitivity test was performed in both stationary and scanning modes.

In scanning mode, the test started with the following parameters – temperature of the at 10°C , fluence of 5 J/Cm² and frequency 2 – 3 Hz. Applications were performed by the same physiotherapist in a constant scanning speed of 5 cm/s. Participants were instructed to report the moment they began to feel the LED trigger. Fluency was adjusted so as not to cause discomfort to the participant, considering that we can observe different sensitivities to the technique. To this end, fluency was

gradually increased to the tolerable limit, without too much discomfort for the participant. Immediately after application, the participant assessed the degree of pain or discomfort, using the visual analogue pain scale.

In stationary mode the sensitivity test started with temperature of the probe at 10 °C, fluence of 10 J/Cm² and frequency of 0.8 Hz. No phototype restrictions were applied. Fluency was gradually increased to the tolerable limit, without too much discomfort for the participant. Immediately after application, the participant assessed the degree of pain or discomfort, using the visual analogue pain scale.

Pain or discomfort assessment

Local pain or discomfort was assessed at the time of application of LED irradiation and also 24 hours after application. For this assessment, a visual analogue pain scale with values from 0 to 10 was used, where zero was no pain and 10 was unbearable pain.

Statistical analysis

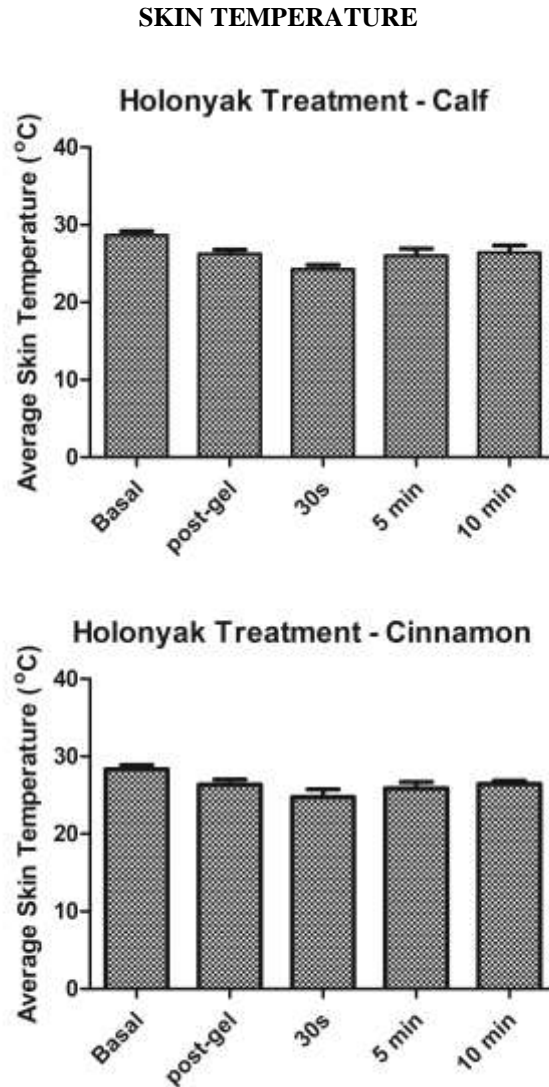
For repeatability, the mean and mean error were expressed in proportion to the mean for each thermal parameter and for each measurement. The ANOVA test was used to compare results between each measure.

3. Results

Infra-red Thermography

The photoepilation was performed in the lower limbs from the knee to the feet direction at the calf and cinnamon areas. In scanning mode a simple pass (once) in each direction was performed and the temperature changes can be observed in Figure 1. Average temperature was recorded as basal, post-gel, 30s, 5 and 10 min after LED irradiation. As we can observe, no significant changes in both calf and cinnamon were noted after LED photoepilation procedure even when analyzed immediately after irradiation (30s).

Figure 1: Average skin temperature of 05 individuals in lower legs, frontal and posterior surfaces in 05 different moments. Before (Basal and post-gel) and after LED irradiation (30s, 5 min and 10 min). Results are expressed as mean + Standard deviation. Significance was considered if $P < 0.05$.

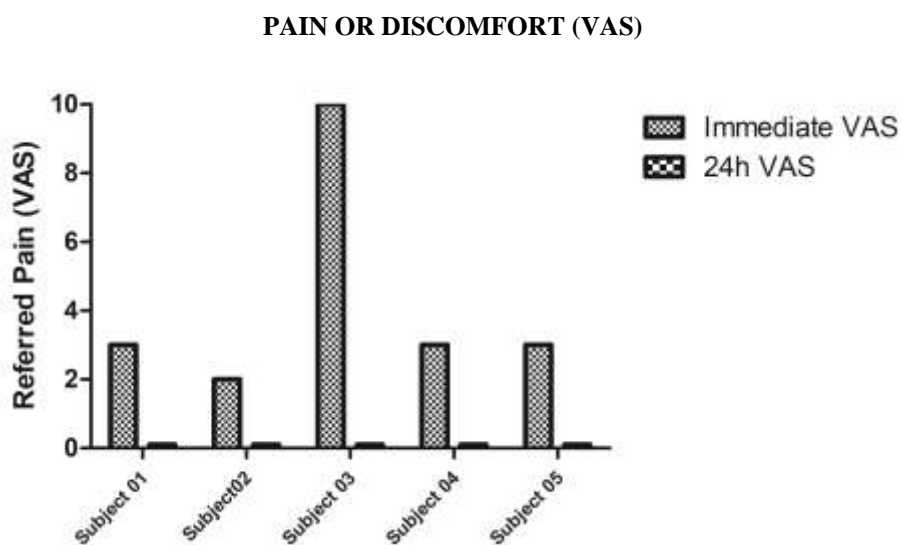


Source: Authors.

Pain (Visual Analog Scale)

Pain or discomfort were analysed as referred pain in Visual Analog Scale (VAS) during LED irradiation and 24 hours after procedure. Figure 2 demonstrate that in four out of five subjects the pain during procedure as mild (ranging from 2 – 3). With exception of one subject that presented extreme sensitivity due to pre-menstrual period. As we can observe in Figure 2, none of the participants referred any pain or discomfort 24 hours after procedure. The participants were also asked about any other symptoms but neither of participants reported any other possible discomfort after 24 or 48h.

Figure 2: Pain or discomfort immediately after LED irradiation and 24 hours after treatment analysed by Visual analogue scale (VAS).



Source: Authors.

4. Discussion

Laser-induced photoepilation has been used for many years as an alternative for permanent hair removal. Patients who undergo laser hair removal, in general expects skin irritation, erythema, edema in some extent and even possible burns depending on the phototype and irradiation techniques (Gan & Graber 2013). It were also reported pigmentary changes such as hyperpigmentation besides scarring, purpura, folliculitis, cyanobacteria, pruritus or urticaria (Royo et al, 2011; Gan & Graber, 2013; Agarwal et al, 2016;).

According to Atta-Motte & Zaleska (2020), 53% of the participants in Laser-induced photoepilation studies had side effects, 40.9% of the participants had single side effects and 12.10% had multiple side effects. According to the authors in this recent review, 44.1% of the patients presented sensitivity, 24.1% burns, 24.1% hyperpigmentation, and 14.5% erythema. Skin irritation only was observed in 2.8% of the patients. According to the authors, the severity of side effects occurrence consistently depends on the ethnicity of the participants, specially pain, sensitivity and burns. It was also noticed that severity of side-effects seems to be related to the number of sessions with most undesirable effects been reported after 5 or 6 sessions. In our pilot study, all five participants were submitted to at least 5 sessions up to 08 sessions with any reported side-effects.

Most of published studies were based on low skin phototypes and tends to exclude higher phototypes due to the obvious reason that coloured skin is more vulnerable to side-effects such as pain and burns. In our pilot study there were no restrictions concerning on skin phototype. However, only one phototype VI participant was included but no side-effects reported at all.

These data support the introduction of a new technology of LED-induced photoepilation based the present parameters. A broad band wavelength together with the possibility to customize pulse width and frequency, make possible to better adjust or customize treatment to each patient. Besides, the efficient cooling system with temperatures as low as -15oC prevents any kind of skin heating or burnings.

A long-term (10 sessions) double-blinded and randomized clinical trial with a larger sample of participants, comparing Laser X LED technologies is necessary, in order to establish the efficiency and side effects of each kind of treatment.

5. Conclusions

The present study, which was still initial in the format of a pilot study, was able to reveal that the photoepilation technique using LED with a cooled applicator did not show significant increases in the temperature of the participants' skin. Furthermore, no adverse effects such as pain, burns or hypersensitivity were reported 24 hours after treatment. The possibility to fully customize photoepilation with LED light points to the direction of decreasing the occurrence of side-effects.

In summary, the next step is to perform a controlled clinical trial specially designed to compare traditional High-power Laser photoepilation with High power LED new technology. Phototypes IV – VI are the priority of the future studies, in order to investigate possible side effects and advantages of High-Power LED – Holonyak.

References

- Agarwal, M., Velaskar, S. & Gold, M. H. (2016) Efficacy of a low fluence, high repetition rate 810nm diode laser for permanent hair reduction in indian patients with skin types IV-VI. *J Clin Aesthet Dermatol*. 9(11):29-33.
- Aimonetti, J. & Ribot-Ciscar, E. (2016) Pain management in photoepilation *J Cosmet Dermatol* 15(2):194-9.
- Altshuler, G. B., Anderson, R. R., Manstein, D., Zenzie, H. H. & Smirnov, M. Z. (2001) Extended theory of selective photothermolysis. *Lasers Surg Med* 29:416-432
- Anderson, R. R. & Parrish, J. A. (1983) Selective photothermolysis: precise microsurgery by selective absorption of pulsed radiation. *Science*. 220:524-527
- Atta-Motte, M. & Załęska, I. (2020) Diode Laser 805 Hair Removal Side Effects in Groups of Various Ethnicities – Cohort Study Results. *J Lasers Med Sci* 11(2):132-137
- Ayatollahi, A., Samadi, A., Rajabi-Estarabadi, A., Yadangi, S., Nouri, K. & Firooz, A. (2019) Comparison of efficacy and safety of a novel 755-nm diode laser with conventional 755-nm alexandrite laser in reduction of axillary hairs. *Lasers in Medical Science* <https://doi.org/10.1007/s10103-019-02829-x>.
- Bibilash, Bs., Chittoria, R. K., Thappa, D. M., Mohapatra, D. P., Friji, Mt., Dineshkumar, S., & Pandey, S. (2017) Are lasers superior to lights in the photoepilation of Fitzpatrick V and VI skin types? - A comparison between Nd:YAG laser and intense pulsed light. *J Cosmet Laser Ther*. 19(5):252-255.
- Cohen, M., Austin, E., Masub, N., Kurtti, A., George, C., & Jagdeo, J. (2021) Home-based devices in dermatology: a systematic review of safety and efficacy *Arch Dermatol Res* . 2021. 10.1007/s00403-021-02231-0.
- Gan, S. D., & Graber, E. M. (2013) Laser hair removal: a review. *Dermatol Surg*. 39(6):823-38. 10.1111/dsu.12116.
- Grossman, M. C., Dierickx, C., Farinelli, W., Flotte, T., & Anderson, R. R. (1996) Damage to hair follicles by normal-mode ruby laser pulses. *J Am Acad Dermatol* 35(6):889-894
- Honeybrook, A., Crossing, T., Bernstein, E., Bloom, J., & Woodward, J. (2018) Long-term outcome of a patient with paradoxical hypertrichosis after laser epilation. *J Cosmet Laser Ther*. 20(3):179-183.
- Ibrahimi, O. A., Avram, M. M., Hanke, C. W., Kilmer, S. L., & Anderson, R. R. (2011) Laser hair removal. *Dermatol Ther* 24:94-107
- Marijke, A. van Vlimmeren, A., Raafs, B., Westgate, G., Linda, Beijens, G. M. & Uzunbajakava, N. E. (2019) Dose-response of Human Follicles During Laser-Based Hair Removal: Ex Vivo Photoepilation Model With Classification System Embracing Morphological and histological Features. *Lasers Surg Med*. 51(8):735-741.
- Matheson, E., & Bain, J. (2019) Hirsutism in Women. *Am Fam Physician*. 1,100(3):168-175.
- Radmanesh, M. (2009) Paradoxical hypertrichosis and terminal hair change after intense pulsed light hair removal therapy. *J Dermatolog Treat*. 20(1):52-4.
- Radmanesh, M., Azar-Beig, M., Abtahian, A., & Naderi, A. H. (2008) Burning, paradoxical hypertrichosis, leukotrichia and folliculitis are four major complications of intense pulsed light hair removal therapy. *J Dermatolog Treat*. 19(6):360-3.
- Royo, J., Urdiales, F., Moreno, J., Al-Zarouni, M., Cornejo, P., & Trelles, M. A. (2011) Six-month follow-up multicenter prospective study of 368 patients, phototypes III to V, on epilation efficacy using an 810-nm diode laser at low fluence. *Lasers Med Sci*. 26(2):247-55.
- Tahiliani, S. T., & Tahiliani, H. S. (2016) Prospective Evaluation of the Safety and Efficacy of a 1060-nm Large Spot Size, Vacuum-Assisted Hair Removal Diode Laser System in Asian/Pacific Fitzpatrick's Skin Types IV-V Patients. *J Drugs Dermatol*. 15(11):1427-1434.
- Załęska, I., & Atta-Motte, M. (2019) Aspects of Diode Laser (805 nm) Hair Removal Safety in a Mixed-Race Group of Patients. *J Lasers Med Sci* 10(2):146-152
- Zandi, S., & Lui, H. (2013) Long-term removal of unwanted hair using light. *Dermatol Clin* 31(1):179-91.