

Three-dimensional biomodel in the treatment of bilateral mandibular fracture sequelae: a case report

Tratamento de seqüela de fratura mandibular bilateral com auxílio de prototipagem: relato de caso

Tratamiento de secuelas de fracturas mandibulares bilaterales con la ayuda de prototipos: reporte de un caso

Received: 09/13/2021 | Reviewed: 09/20/2021 | Accept: 10/31/2021 | Published: 11/01/2021

Emily Ricelly da Silva Oliveira

ORCID: <https://orcid.org/0000-0002-0920-8129>
Federal University of Rio Grande do Norte, Brazil
E-mail: oliveiraemily@outlook.com

José Wittor de Macêdo Santos

ORCID: <https://orcid.org/0000-0002-2584-2381>
Federal University of Rio Grande do Norte, Brazil
E-mail: josewittor@hotmail.com

Tainar Matos dos Santos

ORCID: <https://orcid.org/0000-0001-9816-3403>
Federal University of Rio Grande do Norte, Brazil
E-mail: tainarmatos.dsantos@outlook.com

Marcelo Leite Machado da Silveira

ORCID: <https://orcid.org/0000-0002-8628-0570>
Federal University of Rio Grande do Norte, Brazil
E-mail: marceints@hotmail.com

Humberto Pereira Chaves Neto

ORCID: <https://orcid.org/0000-0002-7556-536X>
Federal University of Rio Grande do Norte, Brazil
E-mail: humbertopchaves@gmail.com

Hugo José Correia Lopes

ORCID: <https://orcid.org/0000-0003-0918-0063>
Federal University of Rio Grande do Norte, Brazil
E-mail: hugojclopes@hotmail.com

Adriano Rocha Germano

ORCID: <https://orcid.org/0000-0002-1661-8038>
Federal University of Rio Grande do Norte, Brazil
E-mail: adrianagermanoufrn@yahoo.com.br

Abstract

Mandibular fractures lead to changes in occlusion, aesthetic deformities and functional alterations, when untreated, their sequelae may cause permanent problems, leading to a more complex treatment than the acute trauma. The treatment offers challenges that can be minimized with the aid of biomodels, printed by 3D technology. This article aims to report a biomodel-assisted surgical procedure for mandibular reconstruction, arguing how these prototypes may help to achieve better outcomes. The patient was involved in an automobile accident and sought treatment for the sequelae of mandibular fractures two years after the initial trauma. The biomodel printing of her mandible allowed for the execution of surgery on the model, reestablishing correct occlusion and facial aesthetics, and helping shorten the surgical time through the pre-bending of reconstruction plates. The patient improved uneventfully. The use of biomodels must be encouraged, especially in cases where the patient shows sequelae, when the anatomical landmarks are compromised, they offer more predictability for treatment outcomes, as described on this case report.

Keywords: Mandibular reconstruction; Surgery, oral; Printing, three-dimensional.

Resumo

As fraturas mandibulares levam a alterações da oclusão, deformidades estéticas e alterações funcionais, quando não tratadas, suas sequelas podem causar problemas permanentes, levando a um tratamento mais complexo do que o trauma agudo. O tratamento oferece desafios que podem ser minimizados com o auxílio de biomodelos, impressos pela tecnologia 3D. Este artigo tem como objetivo relatar um procedimento cirúrgico assistido por biomodelo para reconstrução mandibular, discutindo como esses protótipos podem auxiliar na obtenção de melhores resultados. A paciente sofreu acidente automobilístico e procurou tratamento para sequelas de fraturas mandibulares dois anos após o trauma inicial. A impressão do biomodelo de sua mandíbula permitiu a execução da cirurgia no modelo,

restabelecendo a oclusão correta e a estética facial, e ajudando a diminuir o tempo cirúrgico através da pré-flexão das placas de reconstrução. A paciente melhorou sem intercorrências. O uso de biomodelos deve ser incentivado, principalmente nos casos em que o paciente apresenta sequelas, quando os marcos anatômicos estão comprometidos, oferecem maior previsibilidade para os resultados do tratamento, conforme descrito neste relato de caso.

Palavras-chave: Reconstrução mandibular; Cirurgia bucal; Impressão tridimensional.

Resumen

Las fracturas mandibulares conllevan cambios en la oclusión, deformidades estéticas y alteraciones funcionales, si no se tratan, sus secuelas pueden ocasionar problemas permanentes, dando lugar a un tratamiento más complejo que el traumatismo agudo. El tratamiento ofrece desafíos que pueden minimizarse con la ayuda de biomodelos, impresos con tecnología 3D. Este artículo tiene como objetivo informar sobre un procedimiento quirúrgico asistido por biomodelo para la reconstrucción mandibular, argumentando cómo estos prototipos pueden ayudar a lograr mejores resultados. El paciente estuvo involucrado en un accidente automovilístico y buscó tratamiento por las secuelas de las fracturas mandibulares dos años después del trauma inicial. La impresión biomodelo de su mandíbula permitió la ejecución de la cirugía sobre el modelo, restableciendo la correcta oclusión y estética facial, y ayudando a acortar el tiempo quirúrgico mediante el predoblado de las placas de reconstrucción. El paciente mejoró sin problemas. Se debe fomentar el uso de biomodelos, especialmente en los casos en los que el paciente presenta secuelas, cuando los puntos de referencia anatómicos están comprometidos, ofrecen una mayor predictibilidad de los resultados del tratamiento, como se describe en este caso clínico.

Palabras clave: Reconstrucción mandibular; Cirugía bucal; Impresión tridimensional.

1. Introduction

Facial trauma is a common cause of attendance to emergency rooms worldwide. According to most epidemiological surveys, the mandible and nasal bones are the most affected (Miloro, et al. 2016; Ruela et al., 2018). Patients may report pain, functional limitation, dysphagia, occlusal changes and facial deformities, which is why, in most cases, surgical treatment is necessary (Pickrell & Hollier, 2017). Untreated mandibular fractures (MF) may result in trismus, malocclusion, infection and persistent pain; therefore, they must be addressed early to avoid complications, malunion and nonunion of bone fragments (Stone et al., 2018; Reddy et al., 2019).

The main goal is to reestablish the occlusion and mandibular contour through precise reduction of the bone segments. However, the ideal reduction may be difficult due to complex fracture patterns, muscle action that favors displacement and time elapsed between the trauma and the surgical procedure (Ramanathan et al., 2020). Currently, stable internal fixation is the technique of choice for simple fractures, while rigid internal fixation is indicated in cases of comminuted fractures or when segmental defects are present. The rigid fixation seeks to reestablish the original mandibular contour and serves as a frame for bone reconstruction (Zaylin et al. 2018; Wusiman, Tayie & Ling, 2019.).

In cases of comminuted fractures and segmental defects, which require the use of reconstruction plates, the transoperative bending of the plates can be difficult and considerably increase the surgical time. To optimize the procedure, offer greater postoperative comfort and technical precision, three-dimensional (3D) technology has been used in the printing of anatomical models that can assist in surgical planning. This technology also allows patient guidance, surgical simulation, reduction of fractures and bending of surgical plates in laboratory, minimizing the chances of unsuccessful transoperative bending, reducing surgical time and allowing an easier reduction of bone segments (Lucca et al., 2012; Lee et al., 2018).

Therefore, treating a bilateral mandible fracture sequelae two years after the initial trauma was a challenge minimized by the use of a 3D biomodel, printed with the help of computed tomography.

2. Methodology

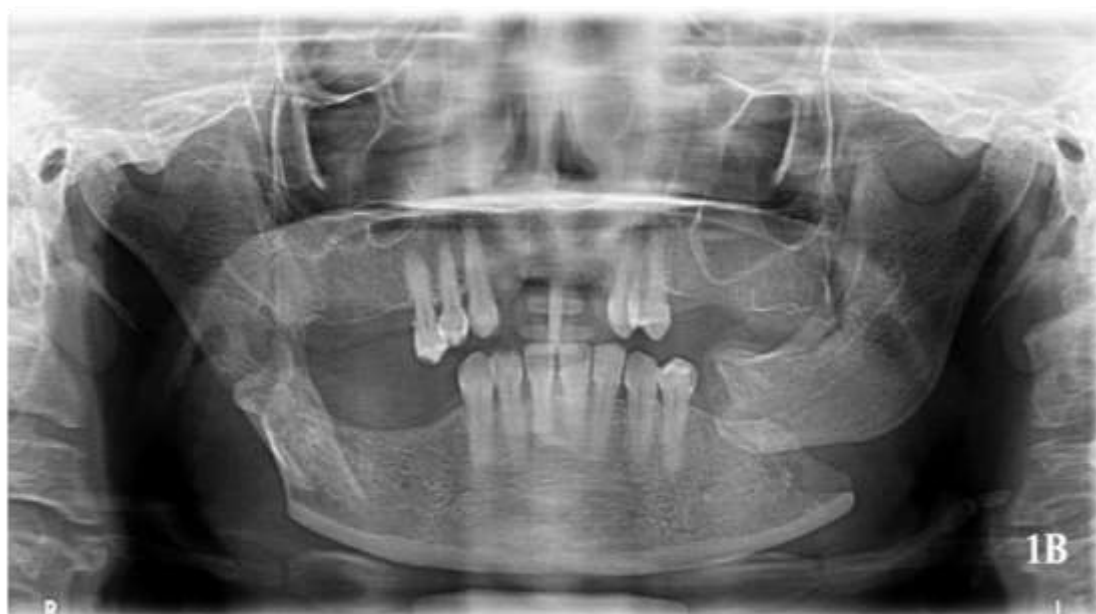This article is a case report, descriptive and qualitative, that details the case of a patient who underwent mandibular reconstruction with the aid of a 3D biomodel, as a consequence of bilateral mandibular fractures. Regarding ethical aspects, the

patient was provided an Informed Consent Form (ICF) and authorized the procedure and its publishing by signing the document.

3. Case Report

A 50 years old female patient, ASA I, sought the service of Maxillofacial Surgery at the Federal University of Rio Grande do Norte, with the complaint "My mouth hurts and I can't open it properly". During the anamnesis, the patient reported being victim to an automobile accident over two years prior to the examination, when she suffered bilateral mandibular fractures. She underwent multiple surgeries, followed by a long period of hospitalization and physiotherapy due to a hip fracture, which delayed the appointment at a specialized service of facial trauma. During the facial examination, it was noted that the patient had partially lost her teeth and didn't use any prosthetic replacement, severe limitation of the mouth opening was also present, as well as considerable restrictions of protrusive and lateral movements, which prevented her from speaking and eating properly. The panoramic radiograph showed that the fractures on the right side had signs of consolidation; on the left side, severe displacement and signs of pseudoarthrosis was observed (Figure 1). Despite the mild pain revealed by the patient, there was no sign of infection.

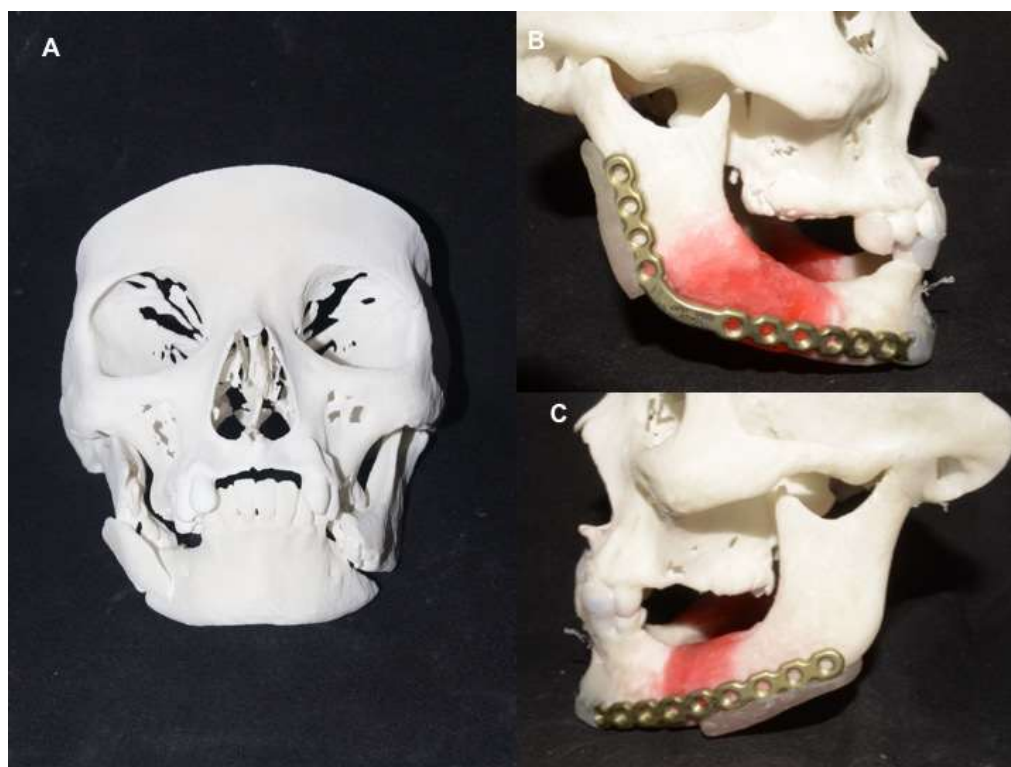Figure 1. Preoperative panoramic radiograph.



Preoperative panoramic radiograph showing a fracture in the region of the right mandibular angle and in the left mandibular body, severely displaced. Source: Authors.

Considering the functional impairment in mastication, phonation and occlusion, open surgical treatment was chosen to reestablish the correct positioning of the bone segments. Given the complexity of the sequelae and the need for detailed planning, a computed tomography was obtained and a 3D biomodel was requested (Figure 2). With the model in hand, it was possible to perform laboratorial surgery, simulating the bilateral mandibular reconstruction. Pre-bending of the 2.4 locking reconstruction plates was also performed (Figure 2), followed by preparation of templates in acrylic resin, to help positioning the plates on the mandibular bone segments.

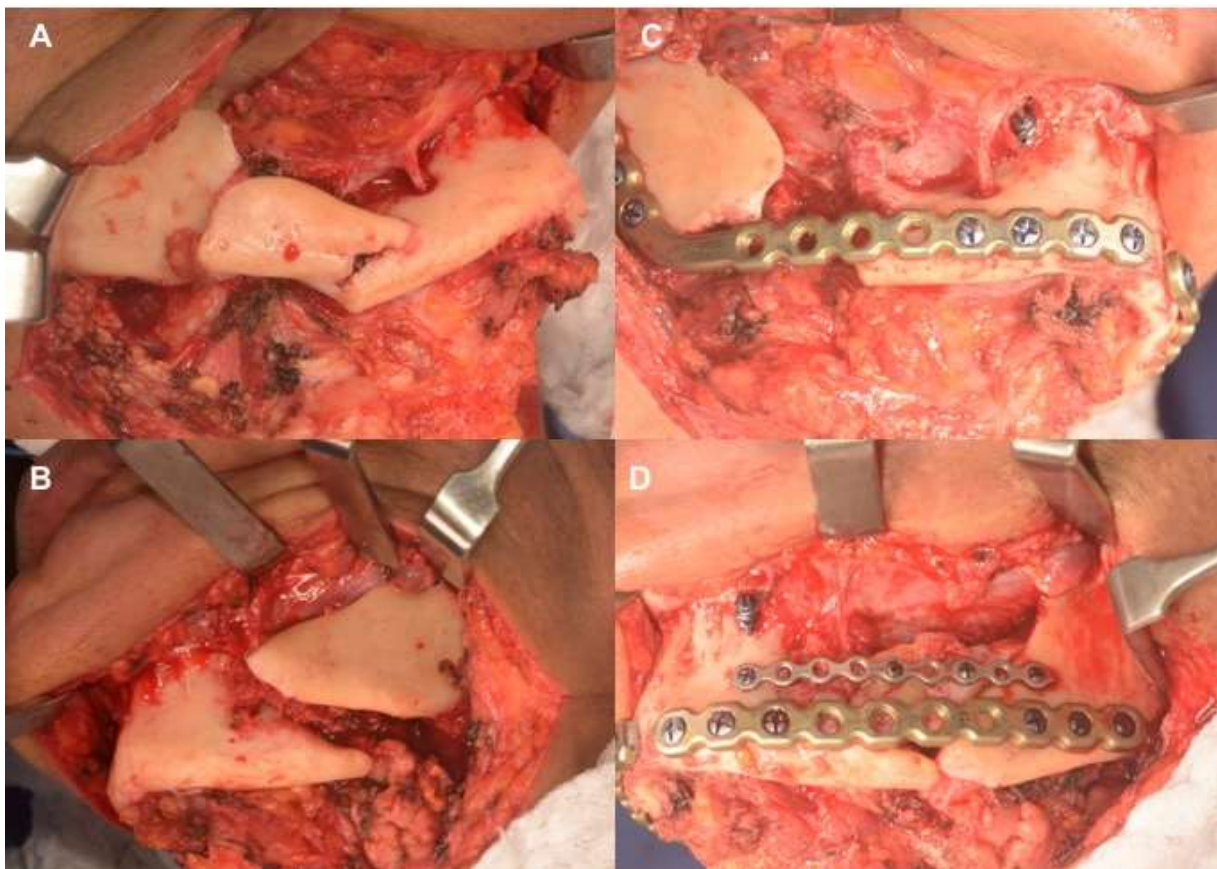
Figure 2. Full-size skull and mandible prototype.



(A) Full-size skull and mandible prototype, made of polyamide. (B/C) Pre-bending of the right and left reconstruction plates. Source: Authors.

The patient underwent surgical procedure under general anesthesia by nasotracheal intubation. The transcervical incision was performed for wide bilateral exposure of the fractures, to allow positioning of the fixation material (Figure 3). After complete exposure, the segments consolidated on the right side were mobilized with a surgical hammer and chisels. On the left side, debridement of the fibrous tissue placed between the fragments was performed. After mobilization of the bone segments, intermaxillary blocking screws were installed, followed by maxillomandibular immobilization with steel wire, with the aid of an occlusal template. After positioning the mandible to obtain the appropriate occlusion, the segments were reduced and stabilized with the 2.4 locking system pre-bend plates, that served as a reference for the final mandibular position. In addition to the two pre-bend reconstruction plates, a 2.0 plate was used on the left side (Figure 3). The remaining fragments were used as free graft on the left side, but on the right side a major remodeling had occurred, leaving a significant defect. The immobilization material was removed and the sutures were placed. The entire procedure took place without any intercurrence

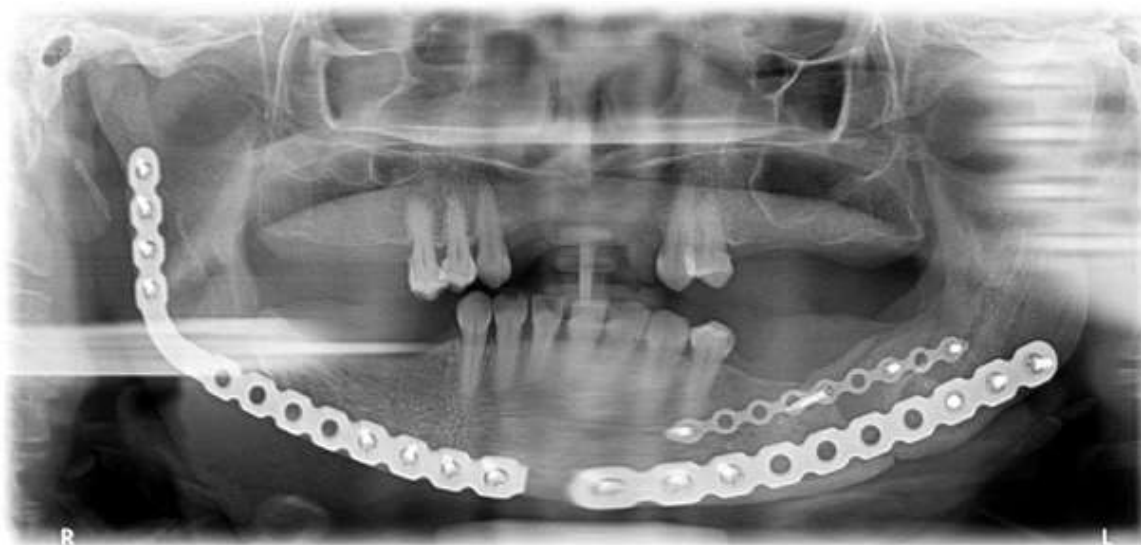Figure 3. Surgical procedure.



(A/B) Exposure of the fracture areas, through transcervical access. (C/D) Stabilization of the right and left fractures with plates and screws from the 2.4 locking system, and conventional 2.0 plate on the left side. Source: Authors.

The patient had no postoperative complications and a strict physiotherapy schedule for mouth opening and mandibular function was recommended. After 2 years of follow-up, the patient has no complaints and reports improvement of quality of life. She presents an adequate mandibular contour, wider interincisal opening and went through rehabilitation with removable partial dentures. In the postoperative radiographic evaluation, it is possible to observe a good positioning of the fixation plates and bone consolidation on the left side (Figure 4). The patient chose not to undergo a new surgical procedure to reconstruct the segmental defect remaining on the right side for now, due to the pandemic.

Figure 4. Postoperative panoramic radiograph.



Postoperative radiograph showing adequate bone contour, good positioning of the reconstruction plates and consolidation of the fractures on the left side. Source: Authors.

4. Discussion

The mandibular bone is commonly affected by facial trauma, accounting for 45 to 60% of all maxillofacial fractures (Ruela et al., 2018). The fractured regions vary according to the etiology of the trauma, with the most affected ones being: body (29.5%), angle (27.3%) and condyle (21.1%) (Miloro et al., 2016). The treatment goal is to reestablish the occlusion, therefore, determining the degree of occlusal alteration caused by trauma is a crucial step to choose the best therapeutical approach (Pickrell & Hollier, 2017; Reddy et al., 2019; Ramanathan et al., 2020).

It is consensus that MF should be addressed early, in general, treatment is performed as soon as possible, ideally in the first 72 hours after the traumatic event. However, this timing is at the mercy of many variables, such as urgency in addressing other injuries, age, comorbidities, mental disorders, non-cooperative patients, lack of specialized care, delayed communication and transfer between hospital units, and financial situation (Hurrell & Batstone, 2014; Stone et al., 2018; Kraeima et al., 2018; King et al., 2018).

In this case report, the patient underwent the whole treatment in the public health system, undergoing hospitalization, multiple surgeries and postoperative physiotherapy for a hip fracture correction, the whole treatment process postponed specialized care for the MF. The delay allowed for the development of functional impairment, pseudoarthrosis, trismus and occlusal changes, which offered greater complexity to the surgical procedure. One of the major problems was the lack of adequate mandibular function, leading to fibrosis, muscle and ligament atrophy that needed to be reversed with the help of postoperative physiotherapy, in addition to an extensive Bristow maneuver during the surgery.

For surgical planning, the location, size, number of fractured segments and difficulty in adapting the reconstruction plates were considered. Currently, locking and non-locking titanium plates are widely used to promote stable fixation of MF, allowing primary healing without callus formation and immediate return to function. Considering the sequelae exhibited by the patient, the locking plates were chosen, eliminating the need for perfect adaptation of the plates to the bone (Hermund et al., 2008; Wusiman et al., 2019). The plates were previously bended using the 3D biomodel, further favoring a stable union of the reconstruction material with the cortical bone. The 2.4mm plates allowed the use of the load-bearing philosophy, since there would be bone defects between the segments, due to the long remodeling and resorption time.

Commonly, reconstruction plates are bend during the surgery, leading to a longer surgical time, which results in higher hospital expenses and may impact the treatment outcomes (Lucca et. al., 2012, Lee et. al, 2018, Sinha et. al, 2018). Repeatedly bending the material also decrease its strength, making it more prone to fractures. However, some authors suggest that the folding of the plate should be performed prior to surgical management, as, in this way, it is possible to achieve a more accurate reconstruction procedure, in addition to obtaining less surgical time (Prisman et al., 2014; Velasco, Vahdani & Ramos, 2017; James et al., 2020).

Therefore, pre-bending the reconstruction plates offer numerous advantages and may be performed with the aid of medical biomodels, which are generated from the data obtained by computed tomography and manufactured by CAD/CAM. An important step for better precision of these models is that the spacing between the cuts is no bigger than 1mm, being, if possible, even smaller. The prototype used in this case was made of polyamide, a thermoplastic filament capable of faithfully reproducing the patient's anatomical features. The process involves melting the polymer, which is expelled by the extruder of a printer, copying a virtual anatomical model. Polyamide offers good quality and has a lower cost compared to other materials (Larry et al., 2005; Velasco, Vahdani & Ramos, 2017; Ghai et al., 2018).

3D biomodels have been used in reconstructive treatments, tumor resection, trauma reconstructions and osteotomies, being applicable in surgical planning, for studying, bending of plates and surgery on the model, allowing for a cheaper, faster and more accurate surgical procedure (Assis et al., 2010; Prisman et al., 2014; Fowell et al., 2015; Velasco, Vahdani & Ramos, 2017). Proper positioning and adaptation of plates reduces complications such as paresthesia, infection, malocclusion, pseudoarthrosis and fatigue of the fixation material. Anatomical models offer better control over surgical steps, facilitating diagnosis and improving surgical planning; therefore, their use should be encouraged.

The use of biomodels to treat trauma cases, especially complex ones, helps to obtain better outcomes. We believe that, with the popularization of 3D printers, these prototypes will soon become a reality in all facial trauma services.

5. Conclusion

The use of 3D technology in maxillofacial surgery has provided improvement over the time spent in the procedure, decision making and technical precision, allowing surgeons to have a higher level of control over the surgery's execution. Although the lack of adequate training, access to reliable printing services and inherent increase in costs might serve as obstacles to biomodels broad use, its advantages overcame the possible challenges, enhancing intraoperative efficiency. Thus, the use of biomodels to plan the approach to facial trauma should be encouraged, especially in sequelae, due to the compromise of anatomical landmarks. These models offer greater predictability to the outcomes, as described in this case.

References

- Assis, G. M., Silva, S. R. P, Moraes, P. H., Queiroz, J. I., & Silva, J. S. P. (2010). Auxílio de prototipagem na reconstrução mandibular: Caso clínico. *Rev. cir. traumatol. buco-maxilo-fac*, 10 (3), 013-018.
- Fowell, C., Edmondson, S., Martin, T., & Praveen, P. (2015). Rapid prototyping and patient-specific precontoured reconstruction plate for comminuted fractures of the mandible. *British Journal of Oral and Maxillofacial Surgery*, 53 (10), 1035–1037.
- Ghai, S., Sharma, Y., Jain, N., Satpathy, M., & Pillai, A. K. (2018). Use of 3-D printing technologies in craniomaxillofacial surgery: A review. *Oral and Maxillofacial Surgery*, 22 (3), 249–259.
- Hermund, N. U., Hillerup, S., Kofod, T., Schwartz, O., & Andreasen, J. O. (2008). Effect of early or delayed treatment upon healing of mandibular fractures: A systematic literature review. *Dental Traumatology*, 24 (1), 22–26.
- Hurrell, M. J. L., & Batstone, M. D. (2014). The effect of treatment timing on the management of facial fractures: A systematic review. *International Journal of Oral and Maxillofacial Surgery*, 43 (8), 944–950.
- James, J., Farrell, T., Stevens, M., Looney, S., Faigen, A., & Anderson, J. (2020). Time to open repair of mandibular fractures and associated complications. *Journal of Oral and Maxillofacial Surgery*, 78 (1), 101–107.

- King, B. J., Park, E. P., Christensen, B. J., & Danrad, R. (2018). On-Site 3-Dimensional printing and preoperative adaptation decrease operative time for mandibular fracture repair. *Journal of Oral and Maxillofacial Surgery*, 76 (9), 1950.e1-1950.e8.
- Kraeima, J., Glas, H. H., Witjes, M. J. H., & Schepman, K. P. (2018). Patient-specific pre-contouring of osteosynthesis plates for mandibular reconstruction: Using a three-dimensional key printed solution. *Journal of Cranio-Maxillofacial Surgery*, 46 (6), 1037–1040.
- Larry, L., Cunningham, Jr., Madsen, M.J., & Peterson, G. (2005). Stereolithographic modeling technology applied to tumor resection. *J Oral Maxillofac Surg*, 63, 873-878.
- Lee, U. K., Rojhani, A., Herford, A. S., & Thakker, J. S. (2016). Immediate versus delayed treatment of mandibular fractures: A stratified analysis of complications. *Journal of Oral and Maxillofacial Surgery*, 74 (6), 1186–1196.
- Lucca, M., Shastri, K., McKenzie, W., Kraus, J., Finkelman, M., & Wein, R. (2010). Comparison of treatment outcomes associated with early versus late treatment of mandible fractures: A retrospective chart review and analysis. *Journal of Oral and Maxillofacial Surgery*, 68 (10), 2484–2488.
- Miloro M., Ghali G. E., Larse P. E., & Waite P. D. *Tratamento contemporâneo das fraturas mandibulares in Princípios de Cirurgia Bucomaxilofacial de Peterson*.
- Pickrell, B. B., & Hollier, L. H. (2017). Evidence-based medicine: Mandible Fractures. *Plastic and Reconstructive Surgery*, 140, 192e-200e.
- Prisman, E., Haerle, S. K., Irish J. C., Daly M., Miles B., & Chan H. (2014). Value of preoperative mandibular plating in reconstruction of the mandible. *Head Neck*, 36 (6):828-33.
- Ramanathan, M., Panneerselvam, E., Krishna K., & Raja, V. B. (2020). 3D planning in mandibular fractures using CAD/CAM surgical splints — A prospective randomized controlled clinical trial. *Journal of Cranio-Maxillofacial Surgery*, 48 (4), 405–412.
- Reddy, L., Lee, D., Vincent, A., Shokri, T., Sokoya, M., & Ducic, Y. (2019). Secondary Management of Mandible Fractures. *Facial Plastic Surgery*, 35 (6), 627–632.
- Ruela, W. S., Almeida, V. L., & Lima-Rivera, L. M. (2018). Does an association exist between the presence of lower third molar and mandibular angle fractures? A meta-analysis. *Journal of Oral and Maxillofacial Surgery*, 76 (1), 34-45.
- Sinha, P., Skolnick, G., Patel, K. B., Branham, G. H., & Chi, J. J. (2018). A 3-dimensional–printed short-segment template prototype for mandibular fracture repair. *JAMA Facial Plastic Surgery*, 20 (5), 373–380.
- Stone, N., Corneman, A., Sandre, A. R., Farrokhyar, F., Thoma, A., & Cooper, M. J. (2018). Treatment delay impact on open reduction internal fixation of mandibular fractures: A systematic review. *Plastic and Reconstructive Surgery - Global Open*, 6 (6), 1–11.
- Velasco, I., Vahdani, S., & Ramos, H. (2017). Low-cost method for obtaining medical rapid prototyping using desktop 3D printing: A novel technique for mandibular reconstruction planning. *Journal of Clinical and Experimental Dentistry*, 9 (9), e1103–e1108.