

New insights on severe clinical manifestations and deaths from visceral leishmaniasis in free-living crab-eating foxes (*Cerdocyon thous*) in Brazil

Novos conhecimentos sobre manifestações clínicas graves e óbitos por leishmaniose visceral em cachorros-do-mato (*Cerdocyon thous*) no Brasil

Nuevos conocimientos sobre las manifestaciones clínicas graves y las muertes por leishmaniasis visceral en zorros cangrejeros de vida libre (*Cerdocyon thous*) en Brasil

Received: 11/05/2021 | Reviewed: 11/13/2021 | Accept: 11/25/2021 | Published: 12/07/2021

Mylena Adriele Dias da Silva

ORCID: <https://orcid.org/0000-0002-8286-3963>
Federal University of Sergipe, Brazil
E-mail: mylenadiasxx@gmail.com

Matheus Resende Oliveira

ORCID: <https://orcid.org/0000-0002-6535-1077>
Federal University of Sergipe, Brazil
E-mail: matheusrxoliveira@gmail.com

Sofia Cerqueira Schettino

ORCID: <https://orcid.org/0000-0001-9660-0921>
Federal University of Sergipe, Brazil
E-mail: kaouro4@hotmail.com

Igo Gonçalves dos Santos

ORCID: <https://orcid.org/0000-0003-2318-8053>
Federal University of Sergipe, Brazil
E-mail: gonalvesigo1267@gmail.com

Manuel Benicio Oliveira Neto

ORCID: <https://orcid.org/0000-0002-7499-4971>
Federal University of Sergipe, Brazil
E-mail: netooliveiraufs@gmail.com

Weslania Souza Inacio da Silva

ORCID: <https://orcid.org/0000-0003-4393-544X>
Federal University of Sergipe, Brazil
E-mail: weslaniainacio@hotmail.com

Aksa Ingrid Vieira Batista

ORCID: <https://orcid.org/0000-0003-0696-7194>
Universidade Federal Rural do Semi-Árido, Brazil
E-mail: aksaingridmv@gmail.com

Carlos Alberto do Nascimento Ramos

ORCID: <https://orcid.org/0000-0002-3084-172X>
Federal University of Mato Grosso do Sul, Brazil
E-mail: carlosanramos@yahoo.com.br

Rafael Antonio Nascimento Ramos

ORCID: <https://orcid.org/0000-0002-0347-9358>
Federal University of the Agreste of Pernambuco, Brazil
E-mail: rafaelanramos10@yahoo.com.br

Márcio Bezerra-Santos

ORCID: <https://orcid.org/0000-0001-9962-6537>
Federal University of Sergipe, Brazil
E-mail: bio_marcio2006@hotmail.com

Victor Fernando Santana Lima

ORCID: <https://orcid.org/0000-0002-7255-0664>
Federal University of Sergipe, Brazil
E-mail: victor.fslima@gmail.com

Abstract

Visceral leishmaniasis (VL) is a zoonotic and severe neglected tropical disease, with worldwide distribution, that still cause many deaths among dogs and humans. Brazil is the country responsible for about 97% of the cases of leishmaniasis in the Americas and the disease is still considered a serious public health concern. Among wild mammals, studies demonstrate the involvement of *Cerdocyon thous* in the biological cycle of *Leishmania*. Nevertheless, several authors consider the clinical manifestation of the disease to be rare or mild in free-living animals. Herein, we demonstrate the occurrence of severe clinical signs and deaths caused by VL in free-living crab-

eating foxes. Three specimens of foxes collected from periurban areas were diagnosed with VL. The animals presented cutaneous, ophthalmological, gastrointestinal, locomotor and hematological alterations, and died after clinical progression. We identified the presence of anti-*Leishmania* antibodies by immunochromatographic test in all specimens. We also observed intra and extracellular amastigotes in skin cytology and lymph node aspirate. Furthermore, *Leishmania infantum* DNA was identified in all samples by the polymer chain reaction technique. Additionally, we performed blood count and stool parasitological tests and observed hematological disorders common to VL, such as anemia and lymphopenia. Taken together, our data demonstrate that VL can induce clinical complications and even cause death in *C. thous* and corroborate that this crab-eating fox is an adequate host for *L. infantum*.

Keywords: Crab-eating fox; Leishmaniasis; Parasitic diseases; Neglected tropical disease; Brazil.

Resumo

A leishmaniose visceral (LV) é uma doença tropical zoonótica, grave e negligenciada, com distribuição mundial, que ainda causa muitas mortes entre cães e humanos. O Brasil é o país responsável por cerca de 97% dos casos de leishmaniose nas Américas e a doença ainda é considerada um grave problema de saúde pública. Em mamíferos silvestres, estudos demonstram o envolvimento de *Cerdocyon thous* no ciclo biológico de *Leishmania*. No entanto, vários autores consideram a manifestação clínica da doença rara ou leve em animais de vida livre. Aqui, demonstramos a ocorrência de sintomas clínicos graves e óbitos causados por LV em cachorros-do-mato de vida livre. Três espécimes de cachorros-do-mato coletados em áreas periurbanas foram diagnosticados com LV. Os animais apresentaram alterações cutâneas, oftalmológicas, gastrintestinais, locomotoras e hematológicas, e morreram após evolução clínica. Identificamos a presença de anticorpos anti-*Leishmania* por teste imunocromatográfico em todas as amostras. Também observamos formas amastigotas intra e extracelulares em citologia de pele e aspirado de linfonodo. Além disso, o DNA de *Leishmania infantum* foi identificado em todas as amostras pela técnica de reação em cadeia do polímero. Realizamos também hemograma e exames parasitológicos de fezes e observamos distúrbios hematológicos comuns à LV, como anemia e linfopenia. Em conjunto, nossos dados demonstram que a LV pode induzir complicações clínicas e até mesmo causar a morte em *C. thous* e corroborar que cachorros-do-mato são hospedeiros adequados para *L. infantum*.

Palavras-chave: Cachorro-do-mato; Leishmaniose; Doenças parasitárias; Doença tropical negligenciada; Brasil.

Resumen

La leishmaniasis visceral (LV) es una enfermedad tropical zoonótica y grave desatendida, con distribución mundial, que aún causa muchas muertes entre perros y humanos. Brasil es el país responsable de aproximadamente el 97% de los casos de leishmaniasis en las Américas y la enfermedad todavía se considera un problema de salud pública grave. Entre los mamíferos silvestres, los estudios demuestran la participación de *Cerdocyon thous* en el ciclo biológico de *Leishmania*. Sin embargo, varios autores consideran que la manifestación clínica de la enfermedad es rara o leve en animales de vida libre. En este documento, demostramos la aparición de síntomas clínicos graves y muertes causadas por LV en zorros cangrejeros que viven en libertad. Tres especímenes de zorros recolectados de áreas periurbanas fueron diagnosticados con LV. Los animales presentaron alteraciones cutáneas, oftalmológicas, gastrointestinales, locomotoras y hematológicas, y fallecieron tras progresión clínica. Identificamos la presencia de anticuerpos anti-*Leishmania* mediante prueba inmunocromatográfica en todas las muestras. También observamos amastigotes intra y extracelulares en citología cutánea y aspirado de ganglios linfáticos. Además, el ADN de *Leishmania infantum* se identificó en todas las muestras mediante la técnica de reacción en cadena del polímero. Adicionalmente, realizamos hemograma y pruebas parasitológicas de heces y observamos alteraciones hematológicas comunes a la LV, como anemia y linfopenia. Tomados en conjunto, nuestros datos demuestran que VL puede inducir complicaciones clínicas e incluso causar la muerte en *C. thous* y corroboran que este zorro cangrejero es un huésped adecuado para *L. infantum*.

Palabras clave: Zorro cangrejero; Leishmaniasis; Enfermedades parasitarias; Enfermedad tropical desatendida; Brasil.

1. Introduction

Leishmaniasis is a group of severe and neglected tropical parasitic diseases, caused by protozoa of the genus *Leishmania*, and transmitted by the bite of an infected female phlebotomine sandfly (WHO 2020). Clinically, leishmaniasis can present in three different forms: cutaneous leishmaniasis (CL) and mucocutaneous (MCL), which cause lesions especially in the skin and mucous membranes; and visceral leishmaniasis (VL), which affects mostly the liver, spleen, lymph nodes, and hematopoietic tissue. VL is the most severe form and can progress to death in 100% of cases within two years if left untreated (Dantas-Torres 2007; WHO 2020). Otherwise, animals affected by leishmaniasis can develop different clinical signs, not well

delimited by clinical form as in humans, such as asymptomatic to severe and lethal forms of the disease (Jorge et al. 2010; Souza et al. 2014).

Notably, several infectious and parasitic diseases can affect wild and domestic animals and have increasing interest of the scientific community in the last decades, especially the zoonoses, in virtue of their potential for transmission to humans and impact on public health. Among the zoonoses, visceral leishmaniasis (VL) deserves special attention due to its high rate of morbidity and mortality among dogs and humans. More importantly, is estimated that one billion people are living in VL-endemic regions and about 20,000 deaths annually due to the disease. In addition, Brazil is among the ten countries with the highest incidence of VL worldwide and, in 2018, registered about 97% of all cases in the Americas (Santos 2019; WHO 2020; Ribeiro 2021).

Although domestic dogs are the main reservoir of *Leishmania*, the parasitosis has already been described in different species of wild mammalians, especially in foxes of the species *Cerdocyon thous* (crab-eating). *C. thous* is widely distributed in Brazil and easily adaptable to several environments, including periurban areas (Lainson et al., 1990; Facure & Monteiro-Filho 1996; Travi et al. 1998; Dantas-Torres & Brandão-Filho 2006; Soares et al. 2017). Furthermore, *Leishmania* infection has been described in *C. thous* since 1954 and is considered a natural reservoir of the parasite by many authors. Despite this, there are still many lacks regarding the real importance of this specie into the epidemiological chain of the disease and the risk of transmission to humans and other animals (Deane & Deane 1954; Courtenay et al. 1996; Courtenay et al. 2002). Additionally, there are few reports in the scientific literature regarding to clinical complications of VL in specimens of crab-eating foxes in Brazil.

Importantly, regardless of being preventable and treatable, leishmaniasis still causes serious concerns in many regions, mainly in developing countries and areas of high social vulnerability (Ribeiro 2021). Considering the high significance of VL for public health, as well as its high incidence in a synanthropic species widely distributed in the Brazilian territory, we aimed herein to describe and present new insights about clinical aspects and complications of VL in free-living crab-eating foxes from Brazil.

2. Methodology

Study area, animal sampling, and design

This study was carried out with samples collected from three specimens of crab-eating foxes (*C. thous*), two females and one male, all adults, and already presenting clinical signs of leishmaniasis. The foxes (named as CF1, CF2, and CF3) were patients at the Wild Animal Screening Center (CTAS) and had been rescued in the metropolitan region of the capital of the state of Sergipe, city of Aracaju (21° 12' 41" S and 50° 25' 34" W), Northeastern Brazil.

The animals were clinically evaluated, following four steps: i) anamnesis and history; ii) general clinical examination; iii) assessment of the skin and cutaneous adnexa; and iv) collection of biological samples (blood and tissues) for the diagnosis of inflammatory processes, lesions, and confirmation of VL infection. In addition, complementary tests such as blood count (hemogram) and fecal parasitology (by Hoffman's spontaneous sedimentation method, 1934) were performed in all specimens. For the diagnosis of VL, we perform three types of tests: i) serological diagnosis; ii) parasitological examination; and iii) molecular diagnosis by polymerase chain reaction (PCR). The clinical signs were photographed, measured, and characterized (type, number, and body distribution of lesions) in individual files.

Serological diagnosis

For the diagnosis of leishmaniasis infection, we first perform a serological evaluation of the blood samples using the DPP immunochromatographic test (Dual Plate Platform – DPP ® Biomanguinhos/Fiocruz). This serological test aims to identify anti-*Leishmania* antibodies.

Parasitological examination

Initially, we conducted clinical evaluation to identify palpable lymph nodes in the popliteal region of the foxes. The lymph nodes that presented increased volume underwent fine needle aspiration puncture (FNAB). The material collected was deposited on microscope slides (in duplicate) and stained with fast panoptic. Subsequently, the slides were analyzed under an optical microscope to search amastigote forms of the parasite (at 400x and 1000x magnification). Similarly, the specimens that presented skin lesions were also submitted to amastigotes research in cells, through cytology analysis of the lesion edge. Likewise, the material collected from the lesions by scraping was deposited on slides (in duplicate), stained with fast panoptic, and evaluated under an optical microscope at 400x and 1000x magnification.

Molecular diagnosis by polymerase chain reaction

The polymerase chain reaction (PCR) was carried out with genomic DNA extracted from all samples and using a commercial kit (Kit Go Taq® Green Master Mix, Promega, Madison, WI, USA). We followed all the manufacturer's instructions. First, the fragment of 447 bp of *Leishmania infantum* was amplified using the primers (MC1: 5'-GTTAGCCGATGGTGGTCTTG-3' and MC2: 5'CACCCATTTCGATTTTG-3') (Cortes et al. 2004). Next, the amplified fragments were visualized in 1% agarose gel electrophoresis through the UV transilluminator. Afterwards, the amplified fragments were purified using ExoSAP-IT PCR Product Cleanup Reagent (Applied Biosystems) and sequenced in both directions using the Sanger method in automatic sequencer ABI 3130 (Applied Biosystems). The chromatograms were analyzed using BioEdit v.7.2.5 software (Hall 1999) and consensus sequences were submitted to BLASTn search (Altschul et al. 1990) to determine the sequence identity, based on comparisons with orthologous sequences available in the GenBank database.

Data analysis

Data were tabulated and stored in Microsoft Excel version 2017 spreadsheets. We calculated the absolute and relative frequencies of the results of the diagnostic tests and clinical signs observed in the foxes.

Search for manuscripts about leishmaniasis in foxes in Brazil

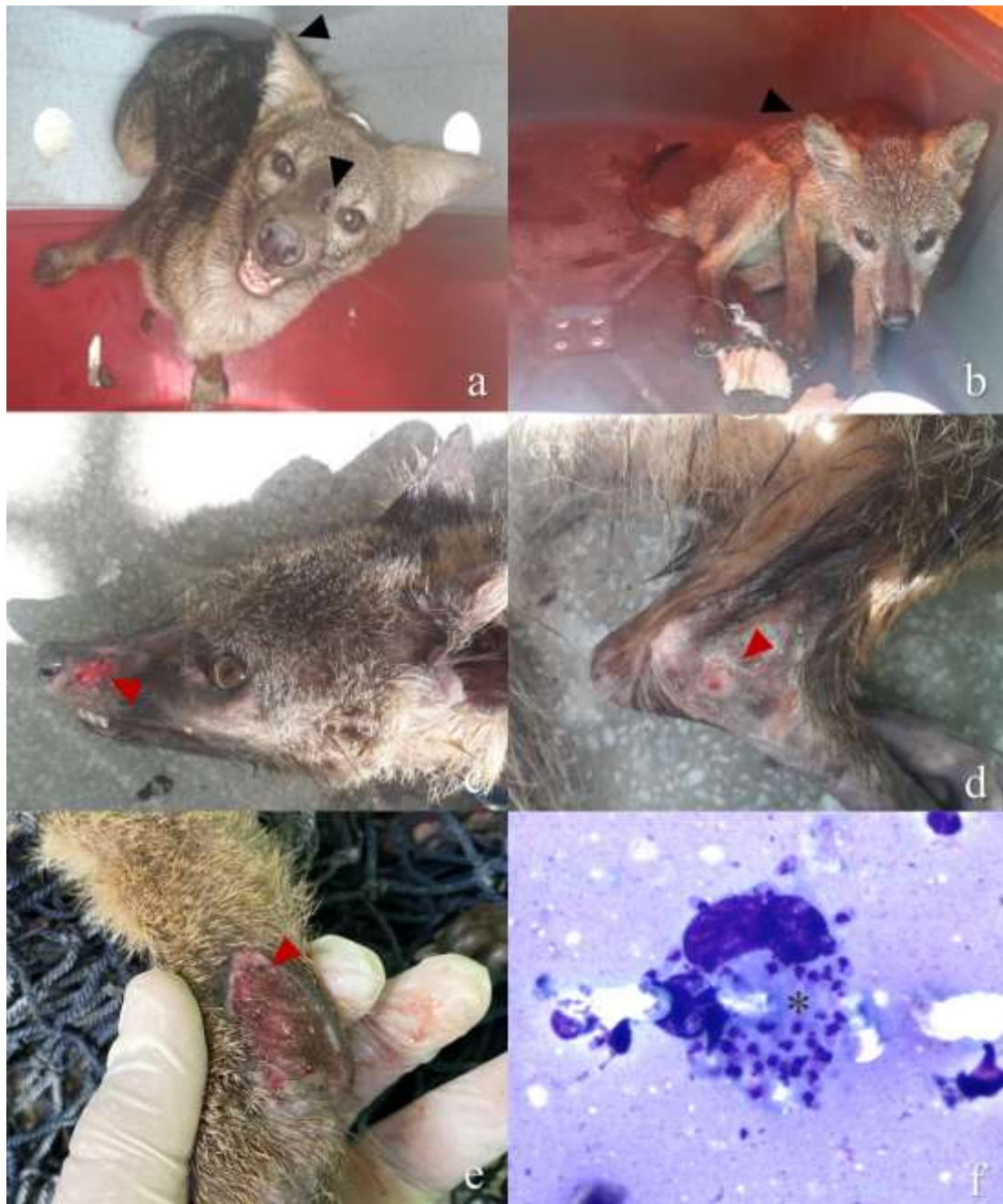The literature review was carried out by searching for scientific manuscripts on cases of leishmaniasis in foxes in Brazil, in the main scientific databases (Academic Google - Scholar, The Scientific Electronic Library Online (SciELO), ResearchGate e PubMed). The data search descriptors were: "crab-eating fox" and "leishmaniasis" and "Brazil". The studies were categorized by study area in Brazil, number of foxes assessed, and leishmaniasis diagnosis method.

3. Results

All crab-eating foxes assessed herein (100%; 3/3) were positive for anti-*Leishmania* antibodies (TR-DPP®). However, the presence of amastigotes (of *Leishmania*) was detected in only one (33.3%; 1/3) of them. In this sample, an average of 26 amastigotes/cell was observed (Figure 1). Furthermore, all samples submitted to the PCR were positive for *L. infantum* DNA, confirming the diagnosis of VL in the foxes. After sequencing and BLASTn search significant identity higher

than 99% was observed between the consensus sequence obtained in the present study and *L. infantum* sequence DNA available from Genbank database. The consensus sequence was deposited at Genbank under accession number MW959170.

Figure 1. Clinical signs and amastigote forms of *Leishmania infantum*. a) Alopecia and skin lesion on the ear and nose (CF1); b) Muscle atrophy and skin lesion on the ear (CF3); c) Alopecia and ulcerative skin lesion on the nose (CF2); d and e) Ulcerative skin lesion and dermatitis in limbs (CF2); f) Amastigote forms of *Leishmania infantum* in scrapping of *C. thous* (CF2).

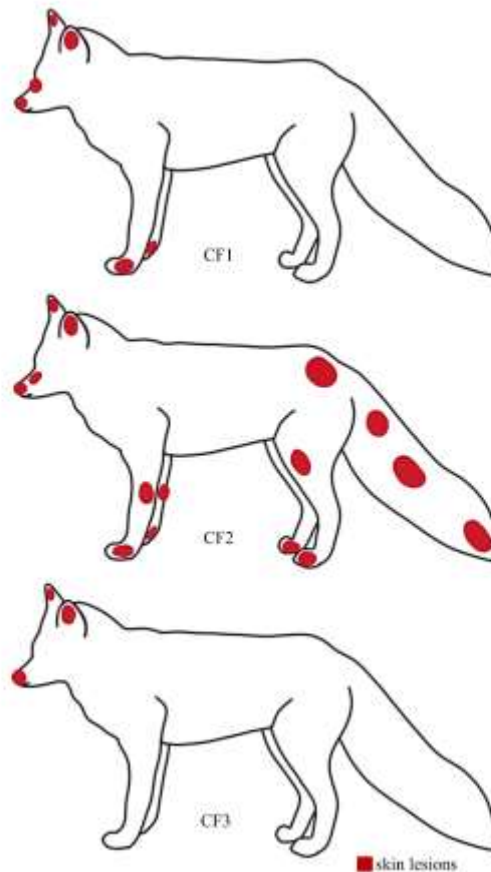


Source: Personal archive.

Interestingly, clinical manifestations compatible with leishmaniasis were observed in the animals, such as epithelial lesions (100%; 3/3), ophthalmological (66.6%; 2/3), musculoskeletal (66.6%; 2/3), gastrointestinal (33.3%; 1/3), and hematological disorders (100%; 3/3) (Figure 1). Among the dermatological signs, we identified ulcerative dermatitis (33.3%;

1/3), nodular lesions (33.3%; 1/3), moist lesions (66.6%; 2/3), seborrhea (100%; 3/3), and alopecia (100%; 3/3). These lesions were observed on the muzzle and ears of all animals; in the forepaws of the specimens CF1 and CF2; and the CF2 specimen had multiple additional lesions on the hind legs, dorsal-posterior region, and tail (Figure 2).

Figure 2. Anatomical distribution of skin lesions in free-living crab-eating foxes (*Cerdocyon thous*) with visceral leishmaniasis.



Source: Personal archive.

Regarding hematological parameters, all foxes had normal parameters in the count of monocytes, white blood cells (WBC) and total protein (Table 1). On the other hand, we observed lower than normal values in the count of red blood cells (RDB; $<3.4 \times 10^6/\mu\text{L}$), hemoglobin ($<9 \text{ g/dl}$), packed cell volume (PCV; $<26\%$) and eosinophil ($<1.507 \text{ n}^\circ/\mu\text{L}$) in all specimens. Additionally, the CF1 specimen showed an increase in the count of band and segmented neutrophils (1,080 and 13,140 $\text{n}^\circ/\mu\text{L}$, respectively), while the CF3 showed low values in the lymphocytes count (685/ μL). Importantly, all specimens were negative for intestinal parasites and died after progression of clinical signs.

Table 1. Hematological parameters in free-living crab-eating foxes (*Cerdocyon thous*) with visceral leishmaniasis from Brazil.

Hematological parameters	Animals			Reference parameters*
	CF1	CF2	CF3	
RBC (10 ⁶ /uL)	1.8	1.8	3.4	4.31 – 6.77
Hemoglobin (g/dℓ)	5.3	5.5	9	12.96 – 16.88
PCV (%)	20	15	26	38 – 49
MCV (fL)	111.11	-	79.47	68 – 95
MCHC (%)	26.5	-	34.62	31 – 38
Total protein (g/dℓ)	8.4	8	7.4	4.6 – 9.4
WBC (n ^o /uL)	18,000	15,500	13,700	3,400 – 23,200
Band neutrophils (n ^o /uL)	1,080	-	0	0 – 700
Segmented neutrophils (n ^o /uL)	13,140	10,850	11,234	1,460 – 12,990
Eosinophils (n ^o /uL)	360	930	1,507	2,700 – 3,940
Basophils (n ^o /uL)	0	0	0	0 – 520
Lymphocytes (n ^o /uL)	2,700	3,100	685	2,100 – 3,990
Monocytes (n ^o /uL)	720	310	274	40 – 2,550
Platelets (n ^o /uL)	440,000	492,000	228,000	18,000 – 636,000

Hematological parameters presented in the blood cells count of three crab-eating foxes, as well as the reference parameters, according to *Mattoso and colleagues (2012) - for adult crab-eating fox. RBC: red blood cells; PCV: packed cell volume or hematocrit; MCV: mean cell volume; MCHC: mean cell hemoglobin concentration; WBC: white blood cells.

Source: Personal archive.

Regarding the findings of the literature review, we identified 17 studies with data on leishmaniasis in foxes of the species *C. thous* in Brazil (Table 2). The oldest was conducted by Deane & Deane in 1954, in the city of Sobral, state of Ceará. The most recent was published in 2020, by Brandão and colleagues, and held in the city of Cumari, state of Goiás. Most studies (64.7%; 11/17) were carried out with only one fox specimen. Regarding the study area, most were carried out in the state of Pará (6/17; 35.3%), North region; four (23.5%) in the Northeast; four in the Southeast; and three (17.6%) in the Midwest of Brazil. The studies included several techniques for the diagnosis of leishmaniasis, such as inoculation in mice (23.5%), parasitological exam (17.6%), PCR (47.1%), ELISA (23.5%), rapid test (11.7%), and others.

Table 2. Cases of free-living foxes crab-eating of foxes (*Cerdocyon thous*) naturally infected by *Leishmania* in Brazil.

Occurrence area	Cases (n)	Method of diagnosis	Reference
Sobral, Ceará	4	Microscopy	Deane and Deane (1954); Courtenay et al. (1996)
Belém, Pará	1	Inoculation in mouse	Lainson et al. (1969)
Utinga, Belem, Pará	1	Inoculation in mouse	Miles et al. (1980)
Salvaterra, Ilha de Marajó, Pará	1	Inoculation in mouse	Silveira et al. (1982)
Cachoeira do Arari, Ilha do Marajó, Pará	11	Microscopy	Lainson et al. (1987)
Corumbá, Mato Grosso	1	Inoculation in mouse	Mello et al. (1988)
Vale do Jequitinhonha, Minas Gerais	1	Culture and PCR	Silva et al. (2000)
Salvaterra, Ilha de Marajó, Pará	29	ELISA and PCR	Courtenay et al. (2002)
Salvaterra, Ilha de Marajó, Pará	12	IFAT	Lainson et al. (1990)
Teresina, Piauí	3	Microscopy, PCR and Xenodiagnoses	Gomes et al. (2007)
Belo Horizonte, Minas Gerais	1	ELISA	Luppi et al. (2008)
Cuiabá, Mato Grosso	6	PCR-RFLP	Souza et al. (2010)
Ilha Solteira, São Paulo	1	ELISA and PCR	Jusi et al. (2011)
Ilha Solteira, São Paulo	1	IFAT, ELISA, Microscopy, Imunohistochemical, Histochemical and PCR	Tenório et al. (2011)
Bahia	1	Immunochromatographic	Almeida et al. (2018)
Aracaju, Sergipe	1	Immunochromatographic and PCR	Lima et al. (2018)
Cumari, Goiás	1	PCR	Brandão et al. (2020)

Source: Personal archive.

This study describes new insights on clinical manifestations of VL on *C. thous* naturally infected by *L. infantum* and rescued in a fragment of Atlantic Forest close to an urban area of Northeastern Brazil.

Leishmaniasis are a group of severe parasitic diseases that still represents a serious public health concern, mainly in low-income countries from Africa, Asia, and Latin America. Importantly, in 2018, about 83 countries or territories were considered endemic for, or had previously reported cases of VL. Currently, it is estimated about 30,000 new cases of VL and more than 1 million new cases of CL annually (WHO 2020). Remarkable, domestic dogs are important hosts of *Leishmania* species and can maintain the disease transmission cycle (Almeida et al. 2018). Despite several studies investigating the occurrence and clinical manifestations of leishmaniasis in dogs, there are few studies that describe the clinical evolution of the disease in other canids in Brazil (Oliveira 2012; Nicolato et al. 2013). Herein, we present new insights into clinical aspects and mortality caused by leishmaniasis in free-living crab-eating foxes.

Molecular diagnosis by PCR identified *L. infantum* DNA in the animals assessed in our study and therefore confirms the occurrence of VL in foxes (Gontijo and Melo 2004). Likewise, some studies have already demonstrated the existence of a wild VL cycle, and the species *C. thous* as a potential reservoir for the parasite (Kruse et al. 2004; Gomes et al. 2007; Luppi et al. 2008; Oliveira et al. 2012; Ferreira et al. 2013; Almeida et al. 2018). Several factors can be associated with the occurrence of *Leishmania* among foxes. These canids have a generalist feeding profile and the ability to walk long distances in search of prey. Furthermore, they can easily adapt to different environments. This behavior increases the risk of infection by the parasite, the transmission of the disease to other hosts, and may corroborate the relevance of this species in the epidemiology chain of the disease (Juarez & Marinho-filho 2002; Figueiredo et al. 2008; Santos 2013).

Interestingly, previous studies suggest that free-living crab-eating foxes infected with *Leishmania* rarely develop clinical symptoms and that, when they do, they have a milder clinical manifestation and, most of them, spontaneously heal (Fornazari & Langoni 2014; Santos 2015; Almeida et al. 2018; Lima et al. 2018). On the other hand, our findings demonstrate that the specimens evaluated herein developed VL severe form and evolved with death after progression of clinical signs. Considering this, we suggest that new studies should be carried out, assessing a larger sample, for a precise investigation about the impact of VL or wild canids.

Regarding the hematological findings, we observed a significant decrease in the components of the red series on the hemogram (RBC and hemoglobin) from all specimens assessed in the study. This data suggests the occurrence of anemia in foxes, that can be caused by leishmaniasis. According to Nicolato and colleagues (2013) anemia is a common clinical finding among symptomatic and VL-affected dogs. Similarly, some animals showed changes in white blood cell count, such as an increase in segmented and band neutrophils, and a decrease in the number of eosinophils and lymphocytes. These data may be associated with inflammatory or immunosuppressive conditions in foxes affected by VL.

Notably, domestic canids are important hosts in the VL transmission cycle. This is mainly justified due to the high parasite load that the dogs can have on the skin. Considering that superficial blood vessels are the main feeding site for sandflies – such as *Lutzomyia longipalpis*, the main vector of VL in Brazil – this consequently enables the infection of phlebotomine with amastigotes and the transmission of the parasite among mammalian hosts (Tafari et al. 2001; Porozzi et al. 2006). Likewise, and corroborating data from prior studies, we also identified amastigotes in the cytology of a skin lesion of one of the *C. thous*. Conversely, data based on the xenodiagnoses suggest that the transmission rate of *Leishmania* from *C. thous* to *L. longipalpis* is rare and, therefore, the species would not be a relevant reservoir for the parasite (Courtenay et al. 1996; Courtenay et al. 2002). Despite this, our results suggest that foxes may also be reservoirs at risk for *Leishmania* transmission to sandflies (Tenório et al. 2011; Roque & Jansen 2014).

According to Mana and colleagues (2009), the parasite load is an important factor associated with the severity of clinical presentation in canine VL. Moreover, we must highlight that due the increasing human exploratory activity, such as

urban expansion and destruction of forest areas, there is an invasion of the natural habitat of *C. thous* and hence a synanthropic behavior of the species. Considering that the foxes assessed herein were captured in periurban areas, and that in recent years there has been a process of urbanization of leishmaniasis, this species may be exposed to a greater parasite load in areas with many infected domestic dogs and sandflies (Cerqueira et al. 2000; Rodrigues & Daemon 2004; Gomes 2006; Santos 2015). Hereupon, high exposure to sandflies can result in an infection with a high parasite load and greater severity of the clinical manifestations of the disease in those animals, unlike the asymptomatic conditions observed in exclusively wild specimens.

4. Discussion

Researches carried out in several countries, including Brazil, have been carried out to determine the occurrence of parasitism in wild animals in zoos by means of coproparasitological analysis. In general, *Cystoisospora* sp., *Toxocara cati*, *Strongyloides stercoralis*, *Toxascaris leonina*, and hookworms are commonly reported for mammalian carnivores. In artiodactyls, protozoans such as *Eimeria* spp. and *Cryptosporidium* spp., as well as nematodes such as *Trichuris* sp., *Toxocara vitulorum*, *Strongyloides* sp., and parasites of the Paramphistomidae family have also been observed. Eggs of the Ancylostomatidae family, *Trichuris* sp., *Strongyloides* sp., *Prosthernorchis elegans*, and *Bertiella* spp. have been found in primates. In Brazil, *Capillaria* spp., *Ascaridia* sp., *Heterakis* sp., *Libyostrongylus* spp., *Raillietina* spp., *Eimeria* spp., and *Isoospora* spp. have already been reported in birds (Fagiolini et al., 2018, Marques et al., 2019).

Among the findings of this study, the first record of gastrointestinal endoparasites from *Tapirus terrestris* in Northeast Brazil stands out. This study reports the occurrence of non-sporulated oocysts of coccids, and cysts and trophozoites of *Balantidium*, both being reported for the first time in Brazil. Generally, infections by endoparasites in free-living tapirids are asymptomatic, but signs of parasitic disease have been observed in captive animals. We also highlight the first record of *Bertiella* spp. in *Alouatta caraya* in the Northeast, Brazil. Clinical signs of this parasitic disease have not been demonstrated for this primate species, but the importance of this zoonosis has been reported, which may occur mainly in patients with direct or indirect contact with these animals, resulting in abdominal discomfort, diarrhea, gastroenteritis, and anorexia (Oliveira et al., 2011; Fernandes-Santos et al., 2020).

Further, this is the first occurrence of *Hymenolepis* spp. and *Aspicularis* spp. as spurious parasites from reptiles in Brazil, exhibiting pseudoparasitism in these animals from the moment they ingest rodents, which are the definitive hosts. Although these pseudoparasites do not infect them, reptiles can be regarded as dispersers of viable parasitic forms that may cause infection in their respective hosts, such as rodents, non-human primates, and humans. In addition, this study also highlights the parasitism by *Entamoeba coli* and *Eimeria* spp. in *Iguana iguana*. Although infection by the latter is usually asymptomatic, generally when *Entamoeba coli* affects the gastrointestinal system, it may cause necrotic enteritis, hepatitis and liver abscesses, lethargy, diarrhea, regurgitation, convulsions, depression, hematochezia, and death in Squamata (Rinaldi et al., 2012; Lima et al., 2017; 2021).

Despite the great relevance of Zoological Parks and the struggle of these institutions to maintain the health of their animals, implementing prevention, diagnosis, and treatment programs, it is well known that many captive animals are housed close to each other, making parasitic infections inevitable. In addition, captive animals are often under considerable stress, which decreases their immunity and makes them more susceptible to infections. These parasites can pose a serious threat to the captive animals, occasionally causing fatalities. Many of these diseases, besides interfering with the welfare of the host species and affecting considerably their birth and mortality rates, may be zoonotic, posing a risk to animal handlers and animal care workers. In the present case, there was still the aggravating factor of the enclosures being within a forest reserve, which favors

a greater contact of the animals with the droppings of other individuals, or even with intermediate hosts (Fagiolini et al., 2010; Oliveira et al., 2011; Snak et al., 2014; Schieber, Štrkolcová, 2019; Dashe & Behanu, 2020; Patra et al., 2020).

The parasitological diagnosis of wild and exotic animals kept in captivity is essential to assist decisions related to their treatment, since they provide important information about the health of the herd and the immune resistance of the hosts. In addition, this information collaborates with the scientific community and contributes to provide ecological data for each of the species herein studied, favoring their conservation and preservation (Barros et al., 2017).

Although there are previous works that have carried out parasitological surveys in animals from zoos in Brazil, these studies, besides being very scarce, are much spaced. Typically, these investigations did not evaluate most of the animals kept at those zoobotanic parks. The present research was the pioneer, in Brazil, to perform the parasitological diagnosis of most of the vertebrate animals of the same zoobotanic park, with species from the Mammalia, Aves, Archelosauria, and Lepidosauria taxa.

5. Conclusions

Taken together, our data demonstrate the occurrence of severe clinical signs of VL in free-living crab-eating foxes, which died after the clinical course of the disease. Considering this, we concluded that leishmaniasis can also severely affect wild mammals of the species *C. thous*. Additionally, the presence of amastigotes in the skin lesions of them indicates a risk of transmission to sandflies and maintenance of the VL cycle. Importantly, the fox *C. thous* is one of the wild species susceptible to *Leishmania* in Brazil and that, despite the rarity of clinical manifestations in free-living specimens, our data demonstrate that in animals with synanthropic behavior, there is a higher risk of severe clinical forms and death. Regardless of our findings, the real role of these animals in the VL transmission cycle remains uncertain, and more studies are extremely required. Furthermore, understanding the biological, epidemiological, and social aspects involved in maintaining the transmission chain of leishmaniasis are necessary for the effective control of this still neglected zoonosis.

Acknowledgments

Authors would like thanking to whole team of *Administração Estadual do Meio Ambiente de Sergipe* for their support on fieldwork.

References

- Almeida, J. C., Melo, R. P. B., Kim, P. C. P. et al (2018) Molecular and serological investigation of infectious diseases in captive and free-range crab-eating fox (*Cerdocyon thous* - Linnaeus, 1776) from northeastern Brazil. *Acta Parasitol* 63:184–189
- Altschul, S. F., et al (1990) Basic local alignment search tool. *J Mol Biol* 215:403–410
- Brandão, E. M. V., et al (2020) Wild and Domestic Canids and Their Interactions in the Transmission Cycles of *Trypanosoma Cruzi* and *Leishmania* spp. in an Area of the Brazilian Cerrado. *Pathogens* 9:818
- Cerqueira, E. J. L., et al (2000) Considerações sobre pulgas (Siphonaptera) da raposa *Cerdocyon thous* (Canidae) da área endêmica de leishmaniose visceral de Jacobina, Bahia, Brasil. *Rev Soc Bras Med Trop* 33:91–93
- Cortes, S., et al (2004) PCR as a rapid and sensitive tool in the diagnosis of human and canine leishmaniasis using *Leishmania donovani* s.l.-specific kinetoplastid primers. *Trans R Soc Trop Med Hyg* 98:12–17
- Courtenary, O., et al (1996) Visceral leishmaniasis in the hoary zorro *Dusicyon vetulus*: a case of mistaken identity. *Trans R Soc Trop Med Hyg* 90:498–502
- Courtenay, O., et al (2002) Low infectiousness of a wildlife host of *Leishmania infantum*: the crab-eating fox is not important for transmission. *Parasitology* 125:407–414
- Dantas-Torres, F. (2007) The role of dogs as reservoirs of *Leishmania* parasites with emphasis on *Leishmania (Leishmania) infantum* and *Leishmania (Viannia) braziliensis*. *Vet Parasitol* 149:139–146
- Dantas-Torres, F., & Brandão-Filho, S. P. (2006) Visceral leishmaniasis in Brazil: revisiting paradigms of epidemiology and control. *Rev Inst Med Trop Sao Paulo* 48:151–156

- Deane, L. M., & Deane, M. P. (1954) Encontro de leishmanias nas vísceras e na pele de uma raposa, em zona endêmica de calazar, nos arredores de Sobral, Ceará. *Hospital* 45:419–421
- Facure, K. G., & Monteiro-Filho, E. L. A. (1996) Feedings habits of the crab-eating fox, *Cerdocyon thous* (Carnivora, Canidae), in a suburban área of southeastern Brazil. *Mammalia* 60:147–149
- Ferreira, P. R. B., et al (2013) Teste de ELISA indireto para diagnóstico sorológico de leishmaniose visceral em canídeos silvestres. *Pesq Vet Bras* 33:528–534
- Figueiredo, F. B., et al (2008). First report of natural infection of a bush dog (*Speothos venaticus*) with *Leishmania (Leishmania) chagasi* in Brasil. *Trans R Soc Trop Med Hyg* 102:200–201
- Fornazari F., & Langoni, H. (2014) Principais zoonoses em mamíferos selvagens. *Vet Zootec* 21: 10–24
- Gomes, M. S. (2006) Carnívora – *Canidae* (Lobo-guará, Cachorro-do-mato, Raposa-do-campo) In: Cubas ZC (ed) Tratado de Animais Selvagens – Medicina Veterinária. Roca, São Paulo, pp 492–504
- Gomes, R. B., et al (2007) Antibodies against *Lutzomyia longipalpis* saliva in the fox *Cerdocyon thous* and the sylvatic cycle of *Leishmania chagasi*. *Trans R Soc Trop Med Hyg* 101:127–133
- Gontijo, C. M. F., & Melo, M. N. (2004). Leishmaniose visceral no Brasil: quadro atual, desafios e perspectivas. *Rev Bras Epidemiol*. 7:338–349
- Hall, T. A. (1999) BioEdit: A User-Friendly Biological Sequence Alignment Editor and Analysis Program for Winows 95/98/NT. *Nucl Acid Symp Serie* 41:95–98
- Hoffman, W. A., Pons, J. A., & Janer, J. L. (1934) The sedimentation concentration methods in *Schistosomiasis mansoni*. *PR J Public Health Trop Med* 9:283-289
- Jorge, R. S. P., Rocha, F. L., May, J. A., & Morayo, R. G. (2010) Occurrence of pathogens in brazilian wild carnivores and its implications for conservation and public health. *Oecol Aust* 14: 686–710
- Juarez, K. M., & Marinho-Filho, J. (2002) Diet, habitat use, and home ranges of sympatric canids in Central Brazil. *J. Mammalogy* 83:925–933
- Jusi, M. M., et al (2011) Molecular and serological detection of *Leishmania* spp. in captive wild animals from Ilha Solteira, SP, Brazil. *Rev Bras Parasitol Vet* 20:219–222
- Kruse, H., Kirkemo, A., & Handeland, K. (2004) Wildlife as a source of zoonotic infections. *Emerg Infect Dis* 10:2067–2072
- Lainson, R., et al (1990) Amazonian visceral leishmaniasis: distribution of the vector *Lutzomyia longipalpis* (Lutz & Neiva) in relation to the fox *Cerdocyon thous* (Linn.) and the efficiency of this reservoir host as a source of infection. *Mem Inst Oswaldo Cruz* 85:135–137
- Lainson, R., & Shaw, J. J. (1987) Evolution, classification, and geographical distribution. In: Peters W (ed) *The Leishmaniasis in Biology and Medicine*. Academic Press, London, pp 1-120
- Lainson, R., Shaw, J. J., & Lins, Z. C. (1969) Leishmaniasis in Brazil: IV. The fox, *Cerdocyon thous* (L) as a reservoir of *Leishmania donovani* in Pará State, Brazil. *Trans R Soc Trop Med Hyg* 63:741–745
- Lima, V. F. S. (2018) Parasitic agents in wild, synanthropic and domestic animals: clinical epidemiological and public health aspects. Dissertation, Rural Federal University of Pernambuco
- Luppi, M. M., et al (2008) Visceral leishmaniasis in captive wild canids in Brazil. *Vet Parasitol* 155:146–151
- Manna, L., Reale, S., Vitale, F., & Gravino, A. E. (2009) Evidence for a relationship between *Leishmania* load and clinical manifestations. *Res Vet Sci* 87:76–78
- Mattoso, C. R. S., et al (2012) Hematologic, serum biochemistry and urinary values for captive Crab-eating Fox (*Cerdocyon thous*) in São Paulo state, Brazil. *Pesq Vet Bras* 32:559–566
- Mello, D. A., et al (1988) *Cerdocyon thous* (L.) (Carnívora, *Canidae*) naturally infected with *Leishmania donovani chagasi* (Cunha & Chagas, 1973) in Corumba (Mato Grosso do Sul State, Brazil). *Mem Inst Oswaldo Cruz* 83:259
- Miles, M. A., Povia, M. M., & Souxa, A. A. (1980) In: Lainson R, Shaw JJ (ed) Some methods for the enzyme characterization of Latin-American *Leishmania*, with particular reference to *Leishmania mexicana amazonensis* and subspecies of *Leishmania hertigi*. *Trans R Soc Trop Med Hyg* 74:243–252
- Nicolato, R. C., et al (2013) Clinical Forms of Canine Visceral Leishmaniasis in Naturally *Leishmania infantum*-Infected Dogs and Related Myelogram and Hemogram Changes. *PLoS ONE* 8:1–9
- Oliveira, R. L. (2012) Investigation of IgG anti-*Leishmania infantum* antibodies in free-living and captive foxes (*Cerdocyon thous*) and in domestic dogs (*Canis familiaris*) in Conservation Units of the State of Pernambuco. Dissertation, Rural Federal University of Pernambuco
- Reithinger, R., Lambson, B. E., Barker, D. C., & Davies, C. R. (2000) Use of PCR to detect *Leishmania (Viannia)* sp. in dog blood and bone marrow. *J Clin Microbiol* 38:748–751
- Ribeiro, C. J. N., et al (2021) Space-time risk cluster of visceral leishmaniasis in Brazilian endemic region with high social vulnerability: An ecological time series study. *PLoS Negl Trop Dis* 15:1–20

- Ribeiro, C. J. N., et al (2021) Space-time risk cluster of visceral leishmaniasis in Brazilian endemic region with high social vulnerability: An ecological time series study. *PLoS Negl Trop Dis* 15: 1–20
- Rodrigues, A. F. S. F., & Daemon, E. (2004) Ixodídeos e Sifonápteros em *Cerdocyon thous* (Carnivora, *Canidae*) procedentes da zona da mata mineira, Brasil. *Arq Inst Biol* 71:371–372
- Roque, A. L. R., & Jansen, A. M. (2014) Wild and synanthropic reservoirs of *Leishmania* species in the Americas. *Int J Parasitol Parasites Wild* 3:251–262
- Santos, E. F. M. (2019) Bionomy of *Migonemyia migonei* (Diptera, Psychodidae, Phlebotominae) under experimental conditions. Dissertation, Leonidas and Maria Deane Institute
- Santos, J. D. O. (2013) Diversity of intestinal helminths in domestic dogs (*Canis familiaris* Linnaeus, 1758) and foxes (*Cerdocyon thous* Linnaeus, 1766) in semi-arid northeastern Brazil and health implications. Dissertation, Fundação Oswaldo Cruz
- Silva, E. S., et al (2000) Visceral leishmaniasis in the crab-eating fox (*Cerdocyon thous*) in south-east Brazil. *Vet Rec* 147:421–422
- Silveira, F. T., et al (1982) Leishmaniasis in Brazil. XVIII. Further evidence incriminating the fox, *Cerdocyon thous* (L), as a reservoir of Amazonian visceral leishmaniasis. *Trans R Soc Trop Med Hyg* 76:830–832
- Soares, M. R. A., et al (2017) Occurrence of *Lutzomyia longipalpis* Lutz & Neiva 1912 and *Cerdocyon thous* Linnaeus 1977, in a visceral leishmaniasis endemic area in Brazil. *Acta Trop* 174:118–121
- Souza, N. P., et al (2010) *Leishmania (Leishmania) infantum chagasi* em canídeos silvestres mantidos em cativeiro, no Estado de Mato Grosso. *Rev Soc Bras Med Trop* 43:333–335
- Tafuri, W. L., Oliveira, M. R., Melo, M. N., & Tafuri, W. L. (2001) Canine visceral leishmaniasis: a remarkable histopathological picture of one case reported from Brazil. *Vet. Parasitol* 96: 203–212
- Tenório, M. S. (2015) Visceral evaluation of the serology technique for visceral leishmaniasis and Chagas disease in wild animals and molecular identification. Dissertation, State University of São Paulo Julio de Mesquita Filho
- Travi, B. L., et al (1998) *Leishmania (Leishmania) chagasi*: clinical and parasitological observations in experimentally infected *Didelphis marsupialis* reservoir of new world visceral leishmaniasis. *Exp Parasitol* 88:73–75
- WHO (2020) Leishmaniasis. IOP Publishing PhysicsWeb. https://www.who.int/health-topics/leishmaniasis#tab=tab_1.
- Willis, H. H. (1921) Simple levitation methods for direction of hookworm ova. *Med J Aust* 2:375–376.