

First report of fungal *Sporothrix schenckii* complex isolation from feline with possible zoonotic transmission in the city of Belém, Pará, Brazil: Case report

Primeiro relato de isolamento de fungo do complexo *Sporothrix schenckii* em felino com possível transmissão zoonótica no Município de Belém, Pará, Brasil: Relato de caso

Primer informe de aislamiento de los hongos del complejo *Sporothrix schenckii* de felino con posible transmisión zoonótica en la ciudad de Belém, Pará, Brasil: Reporte de caso

Received: 01/10/2022 | Reviewed: 01/17/2022 | Accept: 01/23/2022 | Published: 01/24/2022

Barbara Wilka Leal Silva

ORCID: <https://orcid.org/0000-0002-4055-4302>
Universidade Federal Rural da Amazônia, Brazil
E-mail: leal.barbara193@gmail.com

Marcelino Antônio Costa Maués

ORCID: <https://orcid.org/0000-0003-1532-4705>
Centro de Controle de Zoonoses, Brazil
E-mail: marcelinomaues@gmail.com

Pedro Henrique Marques Barrozo

ORCID: <https://orcid.org/0000-0002-0594-3150>
Universidade Federal Rural da Amazônia, Brazil
E-mail: pedro2011ph@hotmail.com

Jacqueline da Silva Brito

ORCID: <https://orcid.org/0000-0002-2699-8716>
Universidade Federal Rural da Amazônia, Brazil
E-mail: Jacquevet@bol.com.br

Caio Cezar Nogueira de Souza

ORCID: <https://orcid.org/0000-0003-3149-6662>
Universidade Federal Rural da Amazônia, Brazil
E-mail: caionnogueira@gmail.com

Marcely Karen Santos do Rosário

ORCID: <https://orcid.org/0000-0002-0532-9046>
Universidade Federal Rural da Amazônia, Brazil
E-mail: marcelysantosr@gmail.com

Caroliny do Socorro Brito Santos

ORCID: <https://orcid.org/0000-0002-7360-0563>
Universidade Federal Rural da Amazônia, Brazil
E-mail: caroliny.bsantos@gmail.com

Alzira Alcantara Mendes Queiroz Neta

ORCID: <https://orcid.org/0000-0003-0607-9277>
Universidade Federal Rural da Amazônia, Brazil
E-mail: mendesnetha@gmail.com

Fernanda Monik Silva Martins

ORCID: <https://orcid.org/0000-0003-4161-0027>
Universidade Federal Rural da Amazônia, Brazil
E-mail: fernanda.martins.ufra@gmail.com

Leonildo Bento Galiza da Silva

ORCID: <https://orcid.org/0000-0003-3857-095X>
Universidade Federal Rural da Amazônia, Brazil
E-mail: leongalizasilva@gmail.com

Lívia Medeiros Neves Casseb

ORCID: <https://orcid.org/0000-0001-8578-9984>
Instituto Evandro Chagas, Brazil
E-mail: liviacasseb@iec.pa.gov.br

Andréa Maria Góes Negrão

ORCID: <https://orcid.org/0000-0002-2064-0772>
Universidade Federal Rural da Amazônia, Brazil
E-mail: andreamariagn@gmail.com

Mylenna de Cássia Neves Guimarães

ORCID: <https://orcid.org/0000-0002-9978-3361>
Universidade Federal Rural da Amazônia, Brazil
E-mail: mylennaguimaraes@gmail.com

Andrea Viana da Cruz

ORCID: <https://orcid.org/0000-0002-6532-8424>

Universidade Federal do Pará, Brazil

E-mail: andrea.vianacruz@gmail.com

Alexandre do Rosário Casseb

ORCID: <https://orcid.org/0000-0001-5615-2423>

Universidade Federal Rural da Amazônia, Brazil

E-mail: alexcasseb@yahoo.com.br

Abstract

Feline sporotrichosis is a subcutaneous, infectious, and contagious mycosis, with zoonotic characteristics. Until now there are no reports on the isolation of *Sporothrix* sp. in cats in the state of Pará. The present work aimed to isolate *Sporothrix* spp. from a cat with possible zoonotic involvement in the city of Belém, Pará. Through the active search for suspected cases of sporotrichosis, carried out by members of the Center for the Control of Zoonoses of Belém (CCZ, Belém) the suspicion of the disease in a feline was reported, with probable transmission to its owner. Clinical evaluation was performed, and biological material was collected from the animal for identifying the agent. Microscopic evaluation of the collected sample and microbial culture confirmed the presence of *Sporothrix* sp. in the sample. This study is the first to report the microbiological isolation of *Sporothrix* sp. in a cat in the metropolitan region of Belém, Pará, with possible zoonotic transmission. This indicates a probable underreporting of cases, an unknowing regarding the reality of health conditions and the need for more accurate and comprehensive evaluation of sporotrichosis in this region.

Keywords: Sporotrichosis; Subcutaneous ringworm; Zoonosis.

Resumo

A esporotricose felina é uma micose subcutânea, infectocontagiosa, de caráter zoonótico. No estado do Pará, até o presente momento, não existem relatos de isolamento deste fungo em gatos, embora já tenham sido diagnosticados casos em humanos e a ocorrência de uma morte, o estado provavelmente possui a situação de subnotificação e desconhecimento do real panorama sanitário de esporotricose. Diante disto, o objetivo deste estudo foi relatar o isolamento de *Sporothrix* sp. em felino com possível envolvimento zoonótico na cidade de Belém, PA. Através da busca ativa de casos suspeitos de esporotricose, realizada por membros do Centro de Controle de Zoonoses de Belém (CCZ, Belém), foi relatada a suspeita da doença em um felino, com provável transmissão para o seu tutor, ambos provenientes do município de Belém, Pará. A partir da suspeita foram então realizadas a avaliação clínica e coleta de material biológico do animal para identificação do agente. A avaliação microscópica da amostra coletada e cultura microbiana confirmou a presença de *Sporothrix* sp. na amostra. Este estudo é o primeiro a relatar o isolamento microbiológico de *Sporothrix* sp. em um gato da região metropolitana de Belém, Pará, com possível transmissão zoonótica. Isso indica provável subnotificação de casos, desconhecimento da realidade das condições de saúde e necessidade de avaliação mais precisa e abrangente da esporotricose na região.

Palavras-chave: Esporotricose; Micose subcutânea; Zoonose.

Resumen

La esporotricosis felina es una micosis subcutánea, infecciosa y contagiosa, con características zoonóticas. Hasta ahora no hay informes sobre el aislamiento de *Sporothrix* sp. en gatos en el estado de Pará. El objetivo de este trabajo fue aislar *Sporothrix* sp. de un gato con posible afectación zoonótica en la ciudad de Belém, Pará. La búsqueda activa de casos sospechosos de esporotricosis, realizada por miembros del Centro de Control de Zoonosis de Belém (CCZ, Belém) se informó la sospecha de la enfermedad en un felino, con probable transmisión a su dueño. Se realizó una evaluación clínica y se recogió material biológico del animal para identificar el agente. La evaluación microscópica de la muestra recolectada y el cultivo micológico confirmaron la presencia de *Sporothrix* sp. en la muestra. Este estudio es el primer en reportar el aislamiento microbiológico de *Sporothrix* spp. en un gato de la región metropolitana de Belém, Pará, con posible transmisión zoonótica. Esto indica una probable subregistro de casos, un desconocimiento de la realidad de las condiciones de salud y la necesidad de una evaluación más precisa y completa de la esporotricosis en esta región.

Palabras clave: Esporotricosis; Micosis subcutánea; Zoonosis.

1. Introduction

Feline sporotrichosis is a subcutaneous, infectious, and contagious mycosis with a zoonotic characteristic. It is caused by a dimorphic fungus belonging to the *Sporothrix schenckii* complex, and each species differs with respect to their geographical distribution. *S. brasiliensis* is an emerging species that is restricted to Brazil and with high potential for zoonotic

transmission (Rodrigues et al., 2016). In cats and dogs, the clinical manifestations begin with a subclinical infection that can progress to multiple skin lesions and a disseminated systemic form (Gremião et al., 2017).

Epidemiological studies indicate that the endemic regions with the highest prevalence of sporotrichosis are Brazil (5,814 cases), China (3,299 cases), and South Africa (3,154 cases) (Zhang et al., 2015). *S. brasiliensis* is associated with cats infection, and its distribution in Brazil is restricted to the Southern and Southeastern states (Rodrigues et al., 2014). Since 2000, incidences of sporotrichosis have been increased exponentially in Rio de Janeiro, where the disease is endemic (Barros et al., 2008).

Although there are no reports on the isolation of this fungus from the cats in the state of Pará, cases have been diagnosed in humans, with one died (Falcão et al., 2019). Considering the climate of the Amazon region associated with the considerable of these animals (approximately 22,070,633.12), many have free access to the external environment or are in a situation of neglect, contributing to the possibilities of exposure of these animals to *Sporothrix* sp. and consequently the ability to spread and maintain this agent in the region in this region (Caldas, 2019).

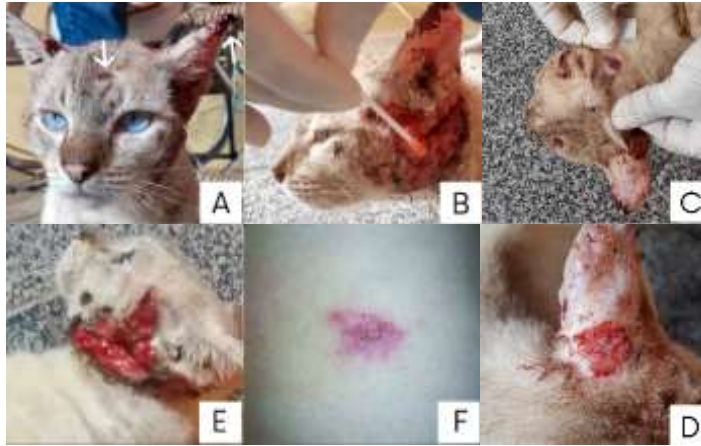According to Gutierrez-Galhardo et al., (2015), the probable reason underlying the increasing number of human cases is the increasing direct involvement with animals and is an extremely crucial factor. As required notification are occurs only in the state of Rio de Janeiro, and the cases in Pará are probably underreported and there is an unknowing regarding the actual situation of sporotrichosis. Therefore, studies on the occurrence of sporotrichosis in the human inhabitants and animals in Pará are essential. In this study aimed to isolate *Sporothrix* sp. in a cat with possible zoonotic involvement in the city of Belém, Pará.

2. Case report

Members of the Zoonoses Control Center of Belém (Centro de Controle de Zoonoses de Belém – CCZ, Belém) actively going in searched for the suspected cases of sporotrichosis and reported a case of feline sporotrichosis. The animal was an adult cat, male, non-neutered, immunized with rabies vaccine, and resident in the town of Belém, Pará (Figure 1A). The pet owner was requested to schedule a visit to the veterinarian for assessing condition and confirming the suspected disease. Clinical examination was performed and biological samples were collected.

For microbiological culture, samples were individually collected from the lesions by scarification with a swab (Figure. 1B) and slides were prepared using an imprint (Figure 1C) for cytological evaluation. The swabs were packed in sterile saline solution, and the temperature was maintained at 4°C during transportation. The materials were immediately sent to the Veterinary Microbiology Laboratory at UFRA for further processing.

Figure 1. Clinical aspects of animal with suspected sporotrichosis. (A) Cat with lesions on both face and ears (arrows). (B) Facial skin lesions with serosanguinous and ulcerated aspect, and also collection through. (C) Lesions in the skull and ears, with a crusty, ulcerated appearance and imprint collection. (D-E) Lesions had a circular and elevated appearance, however, most lesions had an erythematous, ulcerated, flaky, serosanguinous character, devoid of purulent and non-pruritic contents. (F) The owner reported that he too had lesions in the abdominal region that looked similar to those of the animal.



Source: Authors.

For fungal isolation and demonstration dimorphism, the samples were sown on Sabouraud dextrose agar with chloramphenicol and Mycosel® agar, and subsequently incubated at 25°C and 37°C for 15 days. The microorganisms obtained from the cultures were subjected to macromorphological and micromorphological examinations (Rudramurthy & Chakrabarti, 2017).

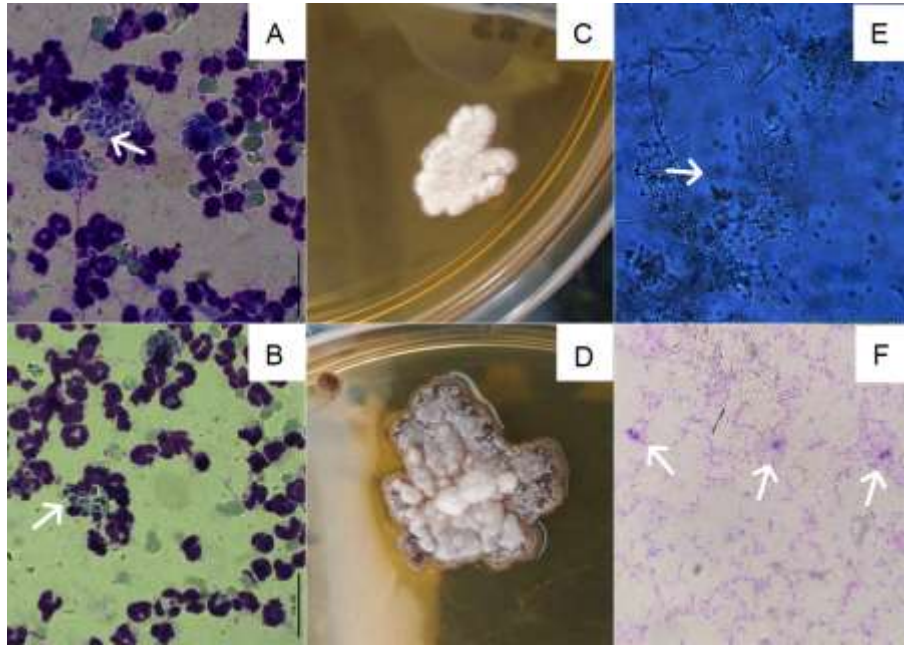
The anamnesis revealed the animal improperly accessed the streets, hunting habitats, and had hyporexia. The symptoms emerged approximately one month before reporting, and the cat was kept in isolation since symptom onset.

Clinical examination revealed cachexia, apathy, infarcted submandibular lymph nodes, and multiple skin lesions in the cephalic regions, on the face, ears, and left side. A few lesions had a circular and elevated appearance, however, most lesions had an erythematous, ulcerated, flaky, serosanguinous character, devoid of purulent and non-pruritic contents (Figure 1D-E). The owner had lesions in the abdominal region that looked similar to those of the animal (Figure 1F). The transmission possibly occurred through scratching while handling the cat approximately two weeks before symptom onset. The pet owner was advised to seek dermatological care due to a suspected zoonotic transmission, for better evaluation of his condition.

Biological material was collected from the cat for direct examination. Panoptic staining revealed the predominance of macrophages, lymphocytes, intermediate erythrocytes, and abundant rounded, oval, pleomorphic, cigar-shaped structures located intracellularly and extracellularly, with characteristics similar to the yeasts of the *S. schenckii* complex (Figure 2A-B). On slide stain by the Gram method, yeast cells with a morphological appearance similar to those described by Romanowsky were also observed, in addition to rare Gram positive cocci.

Microbial growth was assessed on a weekly basis for 15 days. The cultures showed cream-colored colonies, glabrous and creamy yeast at 37°C, and initially white-colored filamentous colonies with cottony texture at 25°C (Figure 2C-D) which turned brownish over time. The filamentous form demonstrated the presence of thin septate hyphae, hyaline, and branched with abundant conidia, and conidiophores with conidia at the end, arranged in the form of “daisies”, which confirmed the clinical diagnosis of sporotrichosis. The yeast colony revealed the presence of oval and elongated cells (Figure 2E-F).

Figure 2. Cytology photomicrograph (imprint) of cutaneous lesions, with abundant presence of rounded pleomorphic structures, cigar shaped, with intra and extracellular location (arrow) of characteristics compatible with *Sporothrix schenckii* yeasts (panoptic stain 1000x magnification) (A) (B). Macroscopic aspect of *Sporothrix* sp. colonies with 7 days of growth (C) and colonies with 15 days of growth (D). Microscopic aspect of the colonies, showing conidia in the shape of a daisy (arrow) (staining with lactophenol cotton blue, 400x magnification) (E). Yeast of *Sporothrix* sp. After reversal technique (arrow) (Gram stain, 1000x magnification) (F).

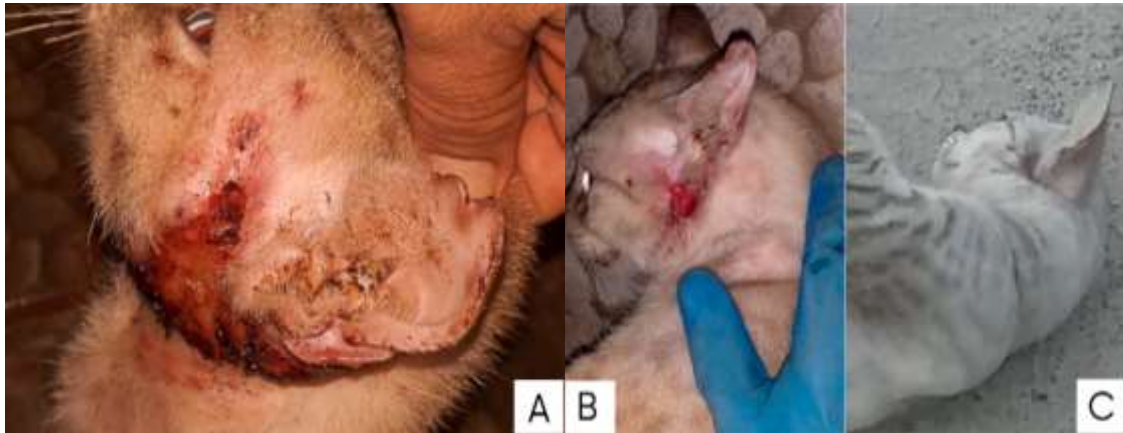

Source: Authors.

The clinical and histopathological evaluation of the lesions in the owner by a dermatologist, revealed sporotrichosis, confirming zoonotic transmission.

Based on the confirmatory diagnosis of sporotrichosis in the cat, a therapeutic protocol was instituted, comprising the oral administration of 15 mg/kg itraconazole, twice daily, until the remission of clinical signs, following the recommendations by Larsson (2011). Home visits were arranged for evaluating the development of the clinical presentation and therapeutic response. After one month, the animal showed clinical improvement and weight gain, suggesting treatment continuation (Figure 3A). At four months, the lesions persisted, but were significantly reduced (Figure 3B), and were clinically cured in the fifth month (Figure 3C).

Figure 3. (A) Remission of the lesions after one month of treatment. (B) Evolution of the treatment response after 4 months. (C) Animal after treatment, with complete remission of the lesions and weight gain.



Source: Authors.

Some measures were suggested to the owner for avoiding transmission to others hosts and preventing the environmental spread of the microorganism. The established criteria included patient handling during administration of the oral and topical drugs using thick gloves, avoiding direct contact with the lesions and secretions, and keeping the animal in an isolated environment, away from any animals of humans. Cleaning the environment with quaternary ammonia or sodium hypochlorite (chlorine bleach), put the animal on waterproof flooring, helping to create a sanitary and sterile environment.

3. Discussion

This study is the first to report a case of feline sporotrichosis in Belém do Pará (Brazil), adding to the other cases in Brazil. It highlights the contribution of domestic cats in transmitting skin sporotrichosis, which is frequently encountered in veterinary clinics. Finally, the care necessary for avoiding zoonotic transmission was established herein.

The widespread growth of *S. schenckii* lato sensu in the environment occurs in places with high relative humidity (above 80%), and temperatures of approximately 26-30°C (Carrada-bravo & Olvera-macías, 2013). According to the data obtained by the National Institute of Meteorology in the year 2020, the relative humidity of Belém was above 80%, and the average temperatures were 20-35°C. In addition, this climatic conditions of the municipality provided the ideal conditions for the growth and environmental maintenance of the fungus, and could contribute to the infection reported herein.

The presence of the etiological agents of sporotrichosis in the nature (surface of branches, soil, and tree barks) can induce fluctuations in the number of transmissions (Rodrigues et al., 2016). Cats have habits that make them more susceptible to sporotrichosis, including sharpening nails on trees and digging the soil for burying feces. This facilitates the sheltering of the fungus in the nail, causing illnesses or making them asymptomatic carriers (Rudramurthy & Chakrabarti, 2017). These were observed in the present case, increasing the reliability of clinical suspicion and prophylactic protocol.

Clinical suspicion based on clinical manifestations and epidemiological data is essential for the diagnosis of any disease. According to Barros et al., (2011), feline sporotrichosis primarily manifests as form of nodular or plaque, firm, alopecic, and painless skin lesions that fistulate or ulcerate, releasing serosanguineous fluid. The cat evaluated had the lesions described in literature. The presentation of nodules and ulcers is common to sporotrichosis, however, can be found in other infectious diseases that affect humans and animals, including leishmaniasis, cryptococcosis, histoplasmosis, and mycobacteriosis, requiring a differential laboratory diagnosis. Apart from neoplastic processes, feline eosinophilic granuloma, squamous cell carcinoma, and lymphomas should also be included in the differential diagnosis (Larsson, 2011).

Since 1993, sporotrichosis cases are treated with 10 mg/kg itraconazole, administered daily, for several months. In some cases, therapy may last for up to one year (Larsson, 2011). After complete remission of the signs, treatment should be extended for four weeks for avoiding relapse. The use of corticosteroids and other immunosuppressants should be avoided during treatment, owing to the risk of promoting fungal multiplication and worsening of the clinical situation (Larsson, 2011). Therapeutic procedures were prescribed to the owner as indicated in literature, and cure was assessed after administration of the correct treatment, which was established by considering the choice of medications and managing the health and environment of the animal.

4. Conclusion

This study is the first to report the microbiological isolation of *Sporothrix* sp. in a feline at the metropolitan region of Belém, Pará, with possible zoonotic profile. This indicates a probable underreporting of cases, unknowing regarding the reality of health conditions, and the need for more accurate and comprehensive evaluation of sporotrichosis in this region.

References

- Barros, M. B. d. L., et al. (2008). An epidemic of sporotrichosis in Rio de Janeiro, Brazil: Epidemiological aspects of a series of cases. *Epidemiology and Infection*, 136(9), 1192–1196. <https://doi.org/10.1017/S0950268807009727>
- Barros, M. B. L., Paes, R. A., & Schubach, A. O. (2011). *Sporothrix schenckii* and sporotrichosis. *Clinical Microbiology Reviews*, 24(4), 354–633. <https://doi.org/10.1128/CMR.00007-11>
- Carlos Eduardo Larsson. (2011). Esporotricosis. *Braz. J. Vet. Res. Anim. Sci.*, 48(3), 250–259. <https://doi.org/10.1016/j.medcli.2015.01.027>
- Carrada-bravo, T., & Olvera-macías, M. I. (2013). New observations on the ecology and epidemiology of *Sporothrix schenckii* and sporotrichosis2. Ecological niches of *S. schenckii* and zoonotic outbreaks. *Revista Latinoamericana de Patología Clínica y Medicina de Laboratorio*, 60(1), 5–24.
- Falcão, E. M. M., et al. (2019). Hospitalizations and deaths related to sporotrichosis in Brazil (1992-2015). *Cadernos de Saude Publica*, 35(4), 1–7. <https://doi.org/10.1590/0102-311X00109218>
- Gremião, I. D. F., et al. (2017). Zoonotic Epidemic of Sporotrichosis: Cat to Human Transmission. *PLoS Pathogens*, 13(1), 2–8. <https://doi.org/10.1371/journal.ppat.1006077>
- Gutierrez-Galhardo, M. C., et al. (2015). Epidemiological Aspects of Sporotrichosis Epidemic in Brazil. *Current Fungal Infection Reports*, 9(4), 238–245. <https://doi.org/10.1007/s12281-015-0237-y>
- Rodrigues, A. M., de Hoog, G. S., & de Camargo, Z. P. (2016). *Sporothrix* Species Causing Outbreaks in Animals and Humans Driven by Animal–Animal Transmission. *PLoS Pathogens*, 12(7), 1–7. <https://doi.org/10.1371/journal.ppat.1005638>
- Rodrigues, A. M., et al. (2014). Emerging sporotrichosis is driven by clonal and recombinant sporothrix species. *Emerging Microbes and Infections*, 3(000), 0. <https://doi.org/10.1038/emi.2014.33>
- Rudramurthy, S. M., & Chakrabarti, A. (2017). Sporotrichosis: Update on Diagnostic Techniques. *Current Fungal Infection Reports*, 11(3), 134–140. <https://doi.org/10.1007/s12281-017-0283-8>
- Zhang, Y., et al. (2015). Phylogeography and evolutionary patterns in *Sporothrix* spanning more than 14 000 human and animal case reports. *Persoonia: Molecular Phylogeny and Evolution of Fungi*, 35(1), 1–20. <https://doi.org/10.3767/003158515X687416>