

Effects of application of Kinesio Taping on the Tibialis Anterior muscle in Cerebral Palsy: case series

Efeitos da aplicação do Kinésio Taping no músculo Tibial Anterior na Paralisia Cerebral: série de casos

Efectos de la aplicación de Kinesio Taping sobre el músculo Tibial Anterior en Parálisis Cerebral: serie de casos

Received: 01/18/2022 | Reviewed: 01/23/2022 | Accept: 01/30/2022 | Published: 02/06/2022

Ana Karolina Almeida Pina

ORCID: <https://orcid.org/0000-0003-3689-3157>

Catholic University of Pernambuco, Brazil

E-mail: anakarolina.ap@hotmail.com

Ana Karolina Pontes de Lima

ORCID: <https://orcid.org/0000-0002-6972-1186>

Catholic University of Pernambuco, Brazil

E-mail: ana.karolina.pontes@gmail.com

Abstract

Justification: Cerebral palsy (CP) caused by injury to the immature Central Nervous System and causes repercussions as serious as the extent of the lesion. Equine foot is common in children with spastic CP, due to hyperactivity of the plantar flexors in relation to the main dorsoflexor, tibialis anterior. Treatment based on adaptations made to improve patients' quality of life. The Kinesio Taping® (KT®) method aims to maintain therapeutic results, being the functional correction technique widely used in neurological patients to limit unwanted or pathological movements. *Objective:* To observe the effects of KT® application on the tibialis anterior on spasticity levels and tibio-tarsal range of motion in CP. *Methods:* The descriptive observational study of the case series type, carried out from October 24th to November 31st 2014. Which seven children underwent assessment of spasticity of the right lower limb and of the right tibio-tarsal joint range of motion and intervention using the KT® method. *Results:* The final sample consisted of seven children aged between 7 and 14 years, one of which was female. Most children reduced or maintained the degree of spasticity, and increased plantar flexion at rest and ranges in dorsiflexion and plantar flexion. *Conclusion:* The results suggest that, although the participants did not demonstrate affinity with the technique, there was some interference of the Kinésio Taping® method in their spasticity and in their tibio-tarsal joint mobility.

Keywords: Bandages; Brain diseases; Equinus deformity.

Resumo

Justificativa: A paralisia cerebral (PC) é ocasionada por injúria ao Sistema Nervoso Central imaturo e causa repercussões tão graves quanto à extensão da lesão. O pé equino é comum em crianças com PC espástica, por hiperatividade dos flexores plantares em relação ao principal dorso-flexor, tibial anterior. O tratamento é baseado nas adaptações feitas para melhorar a qualidade de vida dos portadores. O método Kinesio Taping® (KT®) tem como objetivo de manter resultados terapêuticos, sendo a técnica de correção funcional muito utilizada em pacientes neurológicos para limitar movimentos indesejados ou patológicos. *Objetivo:* Observar os efeitos da aplicação do KT®, no tibial anterior, nos níveis de espasticidade e na amplitude de movimento túbio-társica na PC. *Métodos:* O estudo observacional descritivo do tipo série de casos, realizado no período de 24 de outubro a 31 de novembro de 2014, no qual sete crianças foram submetidas à avaliação da espasticidade do membro inferior direito e da amplitude de movimento articular túbio-társica direita e à intervenção através do método KT®. *Resultados:* A amostra final foi composta por sete crianças com idade entre 7 e 14 anos, sendo uma do sexo feminino. A maioria das crianças reduziu ou manteve o grau de espasticidade, e aumentou a planto-flexão no repouso e as amplitudes na dorsoflexão e flexão plantar. *Conclusão:* Os resultados sugerem que, apesar de os participantes não demonstrarem afinidade com a técnica, houve alguma interferência do método Kinésio Taping® na espasticidade e na mobilidade articular túbio-társica dos mesmos.

Palavras-chave: Encefalopatia; Bandagens; Pé equino.

Resumen

Justificación: La parálisis cerebral (PC) se produce por lesión del Sistema Nervoso Central inmaduro y provoca repercusiones tan graves como la extensión de la lesión. El pie equino es común en niños con parálisis cerebral

espástica, debido a la hiperactividad de los flexores plantares en relación con el dorsoflexor principal, el tibial anterior. El tratamiento se basa en las adaptaciones realizadas para mejorar la calidad de vida de los pacientes. El método Kinesio Taping® (KT®) tiene como objetivo mantener los resultados terapéuticos, siendo la técnica de corrección funcional muy utilizada en pacientes neurológicos para limitar los movimientos no deseados o patológicos. *Objetivo:* Observar los efectos de la aplicación de KT® en el tibial anterior, los niveles de espasticidad y el rango de movimiento tibio-tarsiano en PC. *Métodos:* Estudio observacional descriptivo del tipo serie de casos, realizado del 24 de octubre al 31 de noviembre de 2014, en el cual siete niños fueron sometidos a evaluación de espasticidad del miembro inferior derecho y del miembro inferior izquierdo. Amplitud de movimiento e intervención de la articulación tibio-tarsiana mediante el método KT®. *Resultados:* La muestra final estuvo constituida por siete niños con edades comprendidas entre los 7 y los 14 años, uno de ellos de sexo femenino. La mayoría de los niños redujeron o mantuvieron el grado de espasticidad y aumentaron la flexión plantar en reposo y los rangos en dorsiflexión y flexión plantar. *Conclusión:* Los resultados sugieren que, aunque los participantes no demostraron afinidad con la técnica, hubo alguna interferencia del método Kinésio Taping® en su espasticidad y en su movilidad articular tibio-tarsiana. **Palabras clave:** Encefalopatía; Vendajes; Pie equino.

1. Introduction

Cerebral palsy (CP), or chronic encephalopathy, affects from 2 to 3 live births per 1,000, and is described as a non-progressive pathological state caused by injury to the immature Central Nervous System (CNS), which may occur in the pre, peri and post birth periods. This early brain injury causes changes in posture and muscle tone, and its repercussions are as serious as the extent of the injury (Rotta, 2002; Hielkema, & 2016; Jonsson, & 2019).

When the lesion is in the pyramidal tract, in the motor part of the cortex, it is called spastic CP, which is mainly characterized by extensor and adductor muscle hypertonia of the lower limbs (LL), deep hyperreflexia, Babinski's sign and deficit of localized or generalized force. Involvement of the basal ganglia characterizes extrapyramidal, athetotic or dyskinetic CP, in which involuntary movements and fluctuating tone occur in movements or postural maintenance. Cerebellar damage determines ataxic CP, which presents with balance and coordination changes along with muscle hypotonia. Finally, mixed CP occurs when there are pyramidal-extrapyramidal, pyramidal-ataxic or pyramidal-extrapyramidal-ataxic motor disorders (Rotta, 2002; Tecklin &, 2006; Leite & 2004; Jonsson & 2019).

CP classifications include quadriplegia or spastic quadriplegia; hemiplegia, or spastic unilateral CP; and diplegia, or spastic bilateral CP. In spastic quadriplegia, there is body asymmetry with upper limbs impaired in a way greater than or equal to the lower limbs. In hemiplegia, only one hemibody is affected, and in diplegia, despite the involvement of the whole body, the lower limbs are more precarious than the upper limbs (Ferreira, 2006; Jonsson & 2019).

In general, the lower limbs are more affected than the upper limbs (MMSS). Within this group, the equine foot deformity is one of the most common in children with spastic CP. Spastic equinus foot is associated with exaggerated plantar cavus, forefoot supination, and hindfoot varus, and is characterized by tibiotarsal plantar flexion, which occurs due to a primary or secondary deformity. The primary deformity generates a fixed horse and is determined by hyperactivity of the plantar flexor muscles, gastrocnemius and soleus, in relation to the main dorsum flexor, tibialis anterior. While the secondary one comes from an equine attitude in the face of a previous structural alteration of flexion in the knee or hip joints (Fonseca &, 2014; Abdel Ghafar &, 2021).

CP has no defined cure, therefore, its treatment is based on adaptations that can be made to improve the quality of life of individuals with this pathology, optimizing their strength, flexibility, mobility and stability. Sensory experience is fundamental for learning new movements and actions (Abreu &, 2013; Zonta &, 2011; Abdel Ghafar &, 2021).

Dr. Kenzo Kase developed The Kinesio Taping® method in 1973 with the aim of maintaining the therapeutic results obtained from one chiropractic session to the next. The lack of suitable material made the creator of the method develop the Kinesio Tex Tape, a bandage that was stretchable in its length but not in its width (Dias &, 2013). Kinesio Taping® is applied directly to the desired musculature and its action is performed by correcting the function of weakened muscles, increasing

blood and lymphatic perfusion, in addition to sensorimotor stimulation through cutaneous receptors (Bittar &, 2009). Kinesio Taping® causes immediate sensorimotor feedback on functional abilities (Leitão &, 2006).

According to the situation presented regarding the tibialis anterior musculature in CP and the benefits that the Kinesio Taping® method can offer to the muscular system, the interest in researching the effects of this application arose.

2. Methodology

The study was associate to the Catholic University of Pernambuco (UNICAP), to the Center for Biological Sciences and Health and to the Physiotherapy course, as part of the research project “Physiotherapeutic intervention in neuropsychomotor development disorders”, with CAEE number 09972713.7. 0000.5206. And belonging to the research group “Evidence-based Physiotherapy” under the responsibility of Prof. Ana Karolina Pontes de Lima. This is a descriptive observational clinical study of the case series type, which transversally records data related to the clinical observation of the use of the Kinesio Taping method in individuals with CP, without using a placebo or control group (Hochman, &, 2005).

The study carried out at the Corpore Sano physiotherapy and occupational therapy laboratories at UNICAP, was a case series, carried out with 08 individuals diagnosed with CP, aged between 5 and 18 years, of both sexes, who underwent physiotherapy treatment at UNICAP. Children with any other pathology associated with CP, who had used medication to reduce spasticity in the last six months, as well as those who did not attend data collection assiduously were excluded. Contact was made with the patients' parents/guardians, with detailed explanations about the project signing of the Free and Informed Consent Term (ICF) and information that participation would be voluntary, with the right to withdraw at any time.

Initially, the clinical evaluation was carried out, which included the patient's personal data, possible cause of CP, information on the use of auxiliary devices (eg, orthosis), as well as their physical-functional diagnosis. In the second contact, the evaluation of the posture of LL was made with the children, through photographs. They were removed with the individuals in the sitting position, with the lower limbs free and without shoes, in the lateral (right and left) and anterior views. Then, the individuals were evaluated using the Modified Ashworth Scale (Leitão &, 2006; Bohannon &, 1987).

The goniometry of plantar flexion and dorsiflexion of the ankle joint was performed. In the ankle joint dorsiflexion goniometry, the child was in the supine position with the knee in 20 to 30 degrees of flexion and supported by a pillow or a folded towel and the ankle in an anatomical position. In alignment, the axis of the goniometer placed 2.5 cm distal to the lateral malleolus of the fibula, the fixed arm was placed parallel to the lateral midline of the fibula, projecting towards the fibular head, and the mobile arm was placed parallel to the midline lateral calcaneus with stabilization in the leg (Palmer &, 2000).

In the ankle joint plantar flexion goniometry, the supine position was adopted with the hip and knee joints in extension and the ankle in the anatomical position. The goniometric alignment and stabilization were the same as those adopted for ankle dorsiflexion (Palmer &, 2000).

After the evaluations, the individuals were submitted to the application of Kinesio Taping® in the tibialis anterior muscle, following the following principles:

a. Preparation for the application: Skin free of hair, skin lesions and moisturizing lotions or oils used prior to application (Dias &, 2013). To avoid skin irritation, local asepsis was performed with magnesium hydroxide. Because the study was carried out with children who usually have fragile and weak skin, magnesium hydroxide was used prior to the application of magnesium hydroxide to the site, to avoid possible skin irritations. The functional correction technique, widely applied in neurological patients with lesions in the nervous system, was used. The bandage was applied to stretch or stretch the skin and adjacent tissues with moderate to severe tension, as it is a corrective technique, and after application, the heat-sensitive glue was activated by manual friction (Dias &, 2013).

b. Characteristics of the bandage: The color used was black, due to the principle of chromotherapy that

theorizes better fixation to the tissue. The type of cut was in “I”. The measurement of the size of the musculature took as anatomical reference points the space between the fibular head and the base of the 1st metatarsal. The width used was 2.5 to 5.0 cm. The size of the anchor, or fixed point usually applied to the extremities with 0% tension, was equal to or greater than 5.0 cm, varying with the size of the child's limb. The therapeutic direction used was in favor of the movement, intensifying the preload for the musculature and the joint. Initial Anchor: patient positioned in a supine position with the leg and hip extended, the anchor was applied over the fibular head. Plantar flexion and foot inversion were performed to increase skin distension, the bandage was applied with tension of 75 - 100% in the therapeutic zone, part that influences the target tissue, directing it to the first metatarsal, passing through the dorsum. of the foot and by the tuberosity of the navicular bone, where the final anchor was positioned (Dias &, 2013).

c. Duration of applications: Subjects remained with the bandage for 3 days and performed two applications with an interval of 3 days between applications.

Measurements of spasticity and goniometry were performed immediately after the applications and only of goniometry with an interval of ten minutes, during the first and second week of intervention, and the reassessment, or final assessment, used the same parameters as the initial assessment.

3. Results

The sample consisted of seven children with a clinical diagnosis of CP, aged between 7 and 14 years, of which one was female. Regarding the possible etiologies of CP, four children were born preterm and had complications during delivery. Of these four, three suffered from hypoxia, and another had seizures. In addition to these, a term infant contracted cytomegalovirus infection after birth. In the evaluation of the physical-functional diagnosis and tone, three children had spastic diplegia and four had athetoid quadriplegia with a spastic component. Table 1 summarizes the individual characteristics of the sample.

Table 1 – General distribution of children with name, age, sex, possible CP, physical-functional diagnosis/tone, use of AFO orthosis, participation in the aquatic physical therapy protocol.

<i>Child</i>	<i>Age</i>	<i>Gender</i>	<i>Cause of PC</i>	<i>Physical-Functional Diagnosis / Tonus</i>	<i>AFO Orthosis</i>	<i>Physiotherapy Aquatic</i>
<i>A</i>	9	F	Athermo, Cytomegalovirus in the postpartum period.	Diplegia Spastic	Yes	Yes
<i>G</i>	13	M	Preterm, hypoxia during delivery.	Diplegia Spastic	Yes	Yes
<i>I</i>	14	M	Preterm, hypoxia during delivery.	Diplegia Spastic	Yes	Yes
<i>J</i>	7	M	Preterm, seizures during childbirth.	Quadriplegia Spastic	Yes	Yes
<i>M</i>	10	M	Idiopathic.	Quadriplegia Athetoid w/ sp	No	Yes
<i>R</i>	7	M	Idiopathic.	Quadriplegia Spastic	Yes	Yes
<i>W</i>	8	M	Preterm, hypoxia during delivery.	Quadriplegia Athetoid w/ sp	No	Yes

Source: Authors.

The degree of spasticity and the ROM of the tibiotarsal joint were measure at three moments. In the initial evaluation, one week before the application of the bandage to obtain the reference values of each individual; immediately after the first and second application of the bandage, to verify the instantaneous effect of KT®; and in the final evaluation, one week after the application of the bandage, by a second examiner.

In general, there was a change in the degree of spasticity in most patients after the use of KT®, especially for children

A, M and W. Child A reacted with absence of spasticity immediately after applications, a behavior similar to that of child W., which obtained the same immediate result, after having demonstrated a higher degree in the initial evaluation. Child I had no change in spasticity with the application of the bandage and child J did not respond during the applications, but in the final assessment. Child M was the only one who exhibited an inverse instantaneous effect, increasing the degree of spasticity in both applications. And the G and R children exhibited immediate random behavior. At the end of the study, two children (A and I) maintained the same degree of spasticity at the beginning, and of those who changed, three increased (G, R and J) and two decreased (M and W). Individual spasticity results are in Table 2 below.

Table 2 - Individual Results of Spasticity in the Right Lower Limb.

Child	Modified Ashworth Scale Degrees			
	Initial	SEA 1	SEA 2	Final
A	1	0	0	1
I	1+	1+	1+	1+
G	1	1	0	1+
M	2	3	3	1+
R	3	4	3	4
W	4	0	0	2
J	1+	1+	1+	2

Legend: Child: initial letter of each child's name; Initial: initial assessment; Final: final assessment; EAE 1: spasticity on the day of the first effective application; EAE 2: spasticity on the day of the second effective application. Source: Authors.

When considering the values of goniometry in the resting position, children A and W exhibited an increase in the flexed plant posture during applications, and obtained an increase of 15 degrees in the final assessment. Child I showed a similar characteristic with a variation of 11 degrees more in the last evaluation. And child G reacted in the same way during the applications, with an increase of 10 degrees, but in the final evaluation it showed a reduction of 4 degrees. Unlike these, children M and J showed a decrease in equine angulation during applications and, in the final assessment, child M showed a decrease of 15 degrees, and J of 19 degrees in relation to the initial assessment. The individual values of goniometry in the resting position are in Table 3 below.

Table 3 – Individual Values of Goniometry at Rest Position.

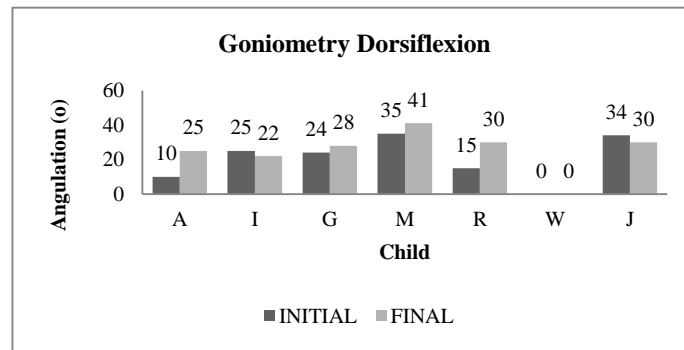
CHILD	INITIAL	AEA 1	AEA 2	FINAL
A	115°	130°	120°	130°
I	110°	115°	110°	121°
G	105°	115°	115°	101°
M	135°	120°	125°	120°
R	110°	100°	110°	110°
W	125°	125°	130°	140°
J	139°	125°	135°	120°

Legend: Initial: initial angulation; End: end angulation; AAE 1: angulation on the day of the first effective application. AAE 2: angulation on the day of the second effective application. Source: Authors.

Dorsiflexion results revealed that of the seven children, four reacted with an increase in ROM, of which R and A obtained the highest results, with a variation of 15 degrees more from the initial to the final assessment. In addition to these, children M and G increased by 6 and 4 degrees respectively. However, children I and J showed different results, with a

reduction in this range of 3 and 4 degrees. Child W was the only one who presented dorsiflexion deformity.

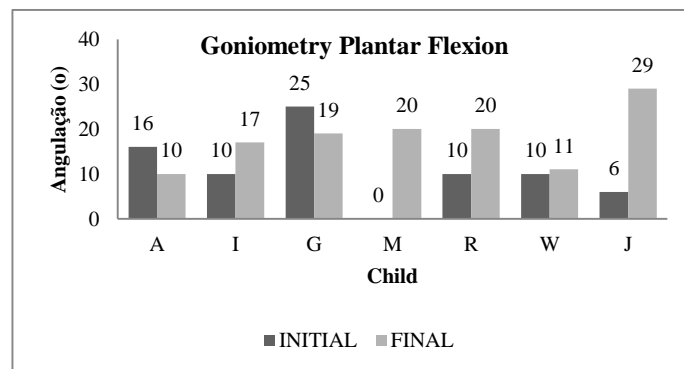
Figure 1 – Individual passive dorsiflexion goniometry values.



Source: Authors.

Regarding plantar flexion, five children showed an increase in ROM, especially children M and J. Child M stood out due to the change from a deformity in plantar flexion, demonstrated in the initial evaluation, to a movement of 20 degrees in final evaluation and child J, as he increased the amplitude by 23 degrees. Children W, I and R obtained similar results, varying respectively 1, 7 and 10 degrees. On the other hand, children A and G, reacted in an inverse way, both with a 6 degree reduction of this angle. Figure 2 shows the individual passive goniometry values in plantar flexion.

Figure 2 - Individual passive goniometry values in plantar flexion.



Source: Authors.

4. Discussion

Sample analysis showed that 57.1% (n = 4) of children had prematurity-related CP etiology, 28.5% (n = 2) were idiopathic and only 14% (n = 1) had postnatal infection., agreeing with the review by Zanini et al 14 which states that prenatal events are 70 to 80% prevalent. Considering the clinical picture of CP, the most frequent form is bilateral hemiplegia or quadriplegia, which occurs in about 9 to 43% of cases, followed by diplegia, 10 to 30%. In the present study, 57.1% (n = 4) of the children had quadriplegia and 42.8% (n = 3) diplegia and all children had a spastic component, which is understandable since spasticity occurs in 88% of the occurrences of PC3.

Regarding spasticity and angulation of the tibiotarsal joint at rest, six of the seven children participating in the research reacted with instantaneous changes to the application of the bandage, differing from the studies by Oliveira, et al. (2014) and Lins, et al. & (2014), who did not find immediate muscle changes with the use of KT®. The increase in muscle resistance to passive movement, or spasticity, is a characteristic that can lead to the emergence of joint deformities (Franco &, 2006). This occurs through alterations in the corticospinal pathways and in the reciprocal inhibition circuits, such as hypertonia

and alpha and gamma hyperreflexia in the musculature corresponding to the areas of the CNS that were injured (Alegre, & 2012).

In general, KT® can be recommended as a tool in the treatment of physical therapy (Unger, & 2018; Abdel Ghafar, & 2021). In the spastic equinus foot, the joint remains positioned in plantar-flexion due to the weakening and shortening of the spastic musculature, which causes a persistent joint retraction that culminates in the hypomobility of the adjacent tissues. (Zuardi, & 2010; Abdel Ghafar, & 2021). KT® can contribute to the control of spasticity in the equinus foot when applied to the spastic antagonist musculature, to balance the reciprocal innervation mechanism. The application on the muscle activates the cutaneous mechanoreceptors, which send a sensory “input” to the CNS, which stimulates muscle contraction with the recruitment of several motor units in the tibialis anterior and, when this is more activated, there is an increase in its tonus and the consequent reduction of exacerbated activity of the soleus and gastrocnemius. This set of reactions provides the perception of joint position and favors dorsiflexion movement (Zavarize, & 2014; Kahanov, & 2007; Tamburella, & 2014; Abdel Ghafar, & 2021).

Many functions performed by the CNS begin with sensory excitations captured by the cutaneous receptors of the sensorimotor system, which is impaired by spasticity. This information, when captured, can be stored to aid future tasks or cause an immediate reaction (Pompeu, & 2009). In this way, the excitation of sensory receptors generated by KT® enables the facilitation of motor learning, making it a coadjuvant in the neural plasticity process, as it provides new stimuli for the CNS to seek adaptations (Yasukawa, & 2006).

In the present study, most children reacted instantly, seeking to adjust their tone to the sensory stimulus offered, which caused a change in the degree of spasticity. When the resistance to movement decreased, the joint had more freedom in movement and this could be observed through changes in the angulation of the tibiotarsal joint at rest and in passive ROM of dorsiflexion and plantar flexion. This finding agrees with the study by Abdel Ghafar, et al. (2021), who demonstrated that KT® must be a technique that improves spatio-temporal parameters in children with spastic diplegia, when combined with conventional physical therapy methods, such as the use of ankle-foot orthoses (AFO).

In the assessment of passive dorsiflexion, the increase in ROM was provided by the flexibility of the plantar flexors and inhibition of spasticity after the use of KT®. In previous studies, its use has produced similar results in reducing spasticity and increasing the ROM of the tibiotarsal joint in dorsiflexion in a child with spastic CP (Kara, & 2014), as well as helping the stretching and functional movements of the extremities of the limbs.

Among the children who did not increase their ROM in dorsiflexion, one had a deformity that was not altered by KT® and the other two had a reduction in amplitude of less than 5 degrees, which may have occurred due to inter-evaluator differences in goniometry (Venturini, & 2006).

Regarding the passive plantar flexion response, almost all children had an increased range of motion, even in the presence of a deformity, which could mean once again a reduction in joint hypomobility. However, there were two cases of reduction of this amplitude, which are probably associated with the memory of the proprioceptive effect of the bandage on the tibialis anterior, making the musculature more activated, even without its use. This storage effect of motor learning is relative among learners, being achieved through constant practices that allow the acquisition and adaptation of movements through repetition, and thus can modify patterns and create, among other things, more complex neuromuscular synergies (Monteiro, & 2010; Cabral, & 2010; Abdel Ghafar & 2021).

The following are suggested as suggestions for future studies: the performance of a longitudinal cut, with robust samples, with a greater number of applications, and a shorter interval between applications, in order to evaluate the late effects of the use of KT®; as well as investigations that prove the physiological effects of the theories. It is important to mention that KT® should not be applied in isolation, but in association with other behaviors, and for this reason those responsible were

recommended not to interrupt other services such as conventional and aquatic physical therapy. This last one was carried out prior to the applications.

5. Conclusion

In the present study, it was possible to observe evidence that the application of KT® can help in physical therapy interventions in CP, interfering with spasticity and favoring tibio-tarsal joint mobility by reducing its hypomobility. The results obtained were diverse because the population was as heterogeneous as that found in clinical practice.

Regarding data collection, there was difficulty, as some children did not show affinity for KT®, expressing anxiety and nervousness before the applications, which increased voluntary and involuntary movements and in some cases this disfavors placement. In these cases, it is advisable to evaluate which method is most effective in achieving the expected objective. It is also important to emphasize that the instructions to those responsible must be constantly reinforced and emphasized, as the lack of attention on their part can compromise the action of the method.

The following suggestions for future studies: the performance of a longitudinal cut, with robust samples, with a greater number of applications, and a shorter interval between applications, in order to evaluate the late effects of the use of KT®; as well as investigations that prove the physiological effects of the theories. It is important to mention that KT® should not be applied in isolation, but in association with other behaviors, and for this reason those responsible were recommended not to interrupt other services such as conventional and aquatic physical therapy. This last one was carried out prior to the applications.

References

- Abdel Ghafar, M. A., Abdelraouf, O. R., Abdel-aziem, A. A., Mousa, G. S., Selim, A. O., & Mohamed, M. E. (2021). Combination taping technique versus ankle foot orthosis on improving gait parameters in spastic cerebral palsy: A controlled randomized study. *Journal of Rehabilitation Medicine*.
- Abreu, T. M. A., Oliveira, L. B., Dantas, A. C. L. M., Paiva, J. C., Leite, L. P., & Ferreira, P. H. L. (2013). Recursos Fisioterapêuticos Na Paralisia Cerebral Pediátrica. *Revista Científica da Escola da Saúde*, 2 (2), 25-37.
- Alegre, D. C. M., Almeida, J. F. S., Oliveira, T. V. C., & Cândido, E. A. F. (2012). Plasticidade muscular: do músculo sadio ao espástico. *Scire Salutis* 2 (1), 16-34.
- Artioli, D. P., & Bertolini, G. R. F. (2014). Kinesio taping: aplicação e seus resultados sobre a dor: revisão sistemática. *Rev. Fisioter Pesq.* 21 (1), 94-99.
- Bittar, D. P., Ribeiro, MO., Rahal, R. O., & Kokanj, A. S. (2009). O uso da bandagem elástica Kinesio no controle da sialorréia em crianças com paralisia cerebral. *Rev. Acta Fisiátr*, 16 (4), 168 – 172
- Bohannon, R.W., & Smith, M.B. (1987). Interrater reliability on a modified Ashworth scale of muscle spasticity. *Phys Therapy* 67 (2), 206-7.
- Cabral, A. S., Narumia, L. C., & Teixeira, L. A. (2010) Facilitação do planejamento e da aprendizagem por meio da prática mental na Paralisia Cerebral. *Rev Neurocienc*, 18 (2), 150-155.
- Dias, E. M., & Lemos, T. V. (2013). *Kinesio Taping® Introdução ao Método e Aplicações Musculares*. Andreli.
- Ferreira, A. A., & Paula, R. C. (2006). Abordagem fisioterapêutica em crianças com paralisia cerebral (Monografia). Centro Universitário Claretiano.
- Fonseca, L. F., & Lima, C. L. A. (2004). *Paralisia Cerebral*. Guanabarra Koogan
- Franco, C. B., Pires, L. C., Pontes, L. S., & Sousa, E. J. (2006) Avaliação da Amplitude Articular do Tornozelo em Crianças com Paralisia Cerebral após a Aplicação de Toxina Botulínica seguida de Fisioterapia. *Rev. Para. Med.* 20 (3), 43-49.
- Greve, P., Perez, V.J., Yoshizumi, L.M., Morini, N., Faria, T.C.C., & Bérzin, F. (2003) Effects of the bandage kinesio taping® in spasticity in cerebral palsy of diparetic - case report. *Proceedings of the 14th World Physical Therapy*, 7-12.
- Hielkema, T., & Hadders-Algra, M. (2016). Motor and cognitive outcome after specific early lesions of the brain—A systematic review. *Developmental Medicine & Child Neurology*, 58, 46–52.
- Hochman, B., Nahas, F. X., Oliveira Filho, R. S. de, & Ferreira, L. M. (2005). Desenhos de pesquisa. *Acta Cirúrgica Brasileira*, 20 (suppl 2), 2–9.
- Jonsson, U., Eek, M. N., Sunnerhagen, K. S., & Himmelmann, K. (2019). Cerebral palsy prevalence, subtypes, and associated impairments: A population-based comparison study of adults and children. *Developmental Medicine & Child Neurology*, 61(10), 1162–1167.

- Kahanov, L. (2007) Kinesio Taping, Part I: An overview of its use in athletes. *Athl Ther Today*. 12 (3), 17-8.
- Kara, O. K., Uysal, S. A., Turker, D., Karayazgan, S., Gunel, M. K., & Baltaci, G. (2014). The effects of Kinesio Taping on body functions and activity in unilateral spastic cerebral palsy: a single-blind randomized controlled trial. *Developmental Medicine & Child Neurology*, 57: 81–88.
- Leitão, A. V., Musse, C. A. I., Granero, L. H. M., Rossetto, R., Pavan, K., & Lianza, S. (2006) Espasticidade: Avaliação Clínica. Projeto Diretrizes. Associação Médica Brasileira e Conselho Federal de Medicina.
- Leite, J. M. R. S., & Prado, G. F. do. (2019). Paralisia cerebral Aspectos Fisioterapêuticos e Clínicos. *Revista Neurociências*, 12(1), 41–45.
- Lins, C. A. A., Macedo, L. B., Neto, F. L., Borges, D. T., Amorim, A. B. C., & Brasileiro, J. S. (2014). Efeitos imediatos do kinesio taping® na potência muscular do quadríceps femoral em sujeitos saudáveis: Ensaio clínico randomizado. *Rev. bras. ciênc. Saúde*.
- Monteiro, C. B. M., Jakabi, C. M., Palma, G. C. S., Torriani-Pasin, C., & Junior, C. M. M. (2010). Aprendizagem motora em crianças com paralisia cerebral. *Rev. Bras. Cresc. e Desenv. Hum.* 20 (2), 250-262.
- Oliveira, A. K. A., Lins, C. A. A., Borges, D. T., Macedo, L. B., Cavalcanti, R. L., & Brasileiro, J. S. (2014). Influência do Kinesiotaping® na Atividade Eletromiográfica do Vasto Lateral em Sujeitos Submetidos a Reconstrução do Lca: Ensaio Clínico Randomizado. *Rev. bras. ciênc. saúde* [suplemento].
- Palmer, M. L., & Epler, M. E. (2000) *Fundamentos das Técnicas de Avaliação Musculoesquelética*. Guanabara Koogan.
- Pompeu, J. E., Mattos, E. C. T., & Kohn, A. F. (2009) Avaliação da inibição recíproca em humanos durante contrações isométricas dos músculos tibial anterior e sóleo. *Fisioter. Pesqui.* 16 (3), 258-62.
- Rotta, N. T. (2002). Paralisia cerebral, novas perspectivas terapêuticas. *Jornal de Pediatria*, 78, S48–S54.
- Souza, C. A. B., Aquino, F. A. O., Barbosa, M. L. C., Alvarez, R. B. P., & Turienzo, T.T. (2013) Influência da neuroplasticidade no controle motor. *RUEP*. 10 (19), 5-11.
- Tamburella, F., Scivolettoand, G., & Molinari, M. (2014) Somatosensory inputs by application of Kinesio Taping: effects on spasticity, balance, and gait in chronic spinal cord injury. *Front. Hum. Neurosci.* 8 (367), 1-9.
- Tecklin, J. S., & Alves, A. M. B. (2006). *Fisioterapia pediátrica*. Artmed.
- Unger, M., Carstens, J. P., Fernandes, N., Pretorius, R., Pronk, S., Robinson, A. C., & Scheepers, K. (2018). The efficacy of kinesiology taping for improving gross motor function in children with cerebral palsy: A systematic review. *South African Journal of Physiotherapy*, 74(1).
- Venturini, C., Ituassú, N.T., Teixeira, L.M., & Deus, C.V.O. (2006) Confiabilidade Intra e Interexaminadores de dois Métodos de Medida da Amplitude Ativa de Dorsiflexão do Tornozelo em Indivíduos Saudáveis. *Rev. Bras. Fisioter.* 10 (4), 407-411.
- Yasukawa, A., Patel, P., Sisung, C. (2006) Pilot study: investigating the effects of Kinesio Taping in an acute pediatric rehabilitation setting. *Am J Occup Ther.* 60 (1): 104-110.
- Zanini, G., Cemin, N. F., & Peralles, S. N. (2009) Paralisia Cerebral: causas e prevalências. *Rev. Fisioter. Mov.* 22 (3), 375-381.
- Zavarize, S. F., & Martelli, A. (2014) Mecanismos neurofisiológicos da aplicação da bandagem funcional no estímulo somatossensorial. *Rev. Saúde Desenvolv. Hum.* 2 (2), 39-49.
- Zonta, M. B., Júnior, A. R., & Santos, L. H. C. (2011). Avaliação funcional na Paralisia Cerebral. *Rev. Acta Pediatr Port*, 42 (1):27-32.
- Zuardi, M. C., Amaral, V. A., Borges, H. C., Chamlian, T. R., Monteiro, V. C., & Prado, G. F. (2010) Eletroestimulação e mobilização articular em crianças com paralisia cerebral e pés equinos. *Rev. Neurociênc.* 18 (3), 328-334.