

## **Adenosquamous inflammatory mammary carcinoma in bitch: Can CA 15-3, CRP and LDH improve prognosis?**

**Carcinoma inflamatório adenoescamoso mamário em cadela: O CA 15-3, PCR e LDH podem melhorar o prognóstico?**

**Carcinoma mamario inflamatorio adenoescamoso en una perra: ¿Pueden el CA 15-3, la PCR y el LDH mejorar el pronóstico?**

Received: 02/01/2022 | Reviewed: 02/09/2022 | Accept: 02/13/2022 | Published: 02/20/2022

### **Breno Queiroz Pinheiro**

ORCID: <https://orcid.org/0000-0001-6363-6952>  
Universidade Estadual do Ceará, Brasil  
E-mail: [breno.queiroz@uece.br](mailto:breno.queiroz@uece.br)

### **Hélida Tainan Silva Barbosa**

ORCID: <https://orcid.org/0000-0002-0516-2426>  
Universidade Estadual do Ceará, Brasil  
E-mail: [helida.tainan@aluno.uece.br](mailto:helida.tainan@aluno.uece.br)

### **Manoel Wanamark David Ferreira Filho**

ORCID: <https://orcid.org/0000-0003-1078-3777>  
Universidade Estadual do Ceará, Brasil  
E-mail: [m.wanamark@hotmail.com](mailto:m.wanamark@hotmail.com)

### **Gabriel Rocha Gurgel**

ORCID: <https://orcid.org/0000-0002-2664-9487>  
Universidade Estadual do Ceará, Brasil  
E-mail: [gabriel.gurgel@aluno.uece.br](mailto:gabriel.gurgel@aluno.uece.br)

### **Francisco Wesley da Silva Alves**

ORCID: <https://orcid.org/0000-0003-0015-8206>  
Universidade Estadual do Ceará, Brasil  
E-mail: [wesleydsa@live.com](mailto:wesleydsa@live.com)

### **Isaac Neto Goes da Silva**

ORCID: <https://orcid.org/0000-0002-6055-1790>  
Universidade Estadual do Ceará, Brasil  
E-mail: [isaac.neto@uece.br](mailto:isaac.neto@uece.br)

### **Lúcia Daniel Machado da Silva**

ORCID: <https://orcid.org/0000-0001-9793-1968>  
Universidade Estadual do Ceará, Brasil  
E-mail: [lucia.daniel.machado@hotmail.com](mailto:lucia.daniel.machado@hotmail.com)

### **Abstract**

Inflammatory mammary carcinoma (IMC) is characterized by the presence of any subtype of aggressive carcinoma in association with an intense inflammatory reaction, in addition to the presence of tumor emboli. Considering IMC as a type of cancer with chronic inflammation, the complex relationship between inflammation, and alterations in cellular metabolism have highlighted the rationale assessment of cancer antigen 15-3 (CA 15-3), c-reactive protein (CRP), and lactate dehydrogenase (LDH). The present report had the objective to describe a rare case of adenosquamous carcinoma in mammary gland of a 10-year-old bitch, 7 kg, sexually intact, mixed-breed and how CA 15-3, CRP and LHD helped to determinate the clinical presentation of inflammatory carcinoma and the prognosis. Complete clinical staging, cell blood count and renal, and hepatic biochemistry was performed and did not reveal any significant abnormalities. CA 15-3 (9.46 IU/mL), CRP (5.3 mg/L), and LDH (287 U/L) were all above the references values reported by the literature. Although adenosquamous carcinoma of the mammary gland with inflammatory presentation in dogs is rare, the association of serum biomarkers could improve the patient's prognosis evaluation.

**Keywords:** Canine mammary tumor; Serum biomarkers; Prognosis.

### **Resumo**

O carcinoma mamário inflamatório (CMI) é caracterizado pela presença de qualquer subtipo de carcinoma agressivo associado a uma reação inflamatória intensa, além da presença de êmbolos tumorais. Considerando o CMI como um tipo de câncer com inflamação crônica, a complexa relação entre inflamação e alterações no metabolismo celular, leva à possibilidade das dosagens do antígeno de câncer 15-3 (CA 15-3), proteína c-reativa (PCR) e do lactato desidrogenase (LDH). O presente relato teve como objetivo descrever um caso raro de carcinoma adenoescamoso em

glândula mamária de uma cadela de 10 anos, 7 kg, sexualmente intacta, sem raça definida e como o CA 15-3, CRP e LHD ajudaram a determinar a apresentação clínica do carcinoma inflamatório e o prognóstico. Realizou-se o estadiamento clínico completo, hemograma e bioquímica renal e hepática não sendo observados anormalidades significativas. As dosagens do CA 15-3 (9,46 IU/mL), PCR (5,3 mg/L) e LDH (287 U/L) estavam todas acima dos valores de referência relatados pela literatura. Embora o carcinoma adenoescamoso da glândula mamária com apresentação inflamatória em cães seja raro, a associação de biomarcadores séricos pode melhorar a avaliação prognóstica da paciente.

**Palavras-chave:** Tumor mamário canino; Biomarcador sérico; Prognóstico.

### Resumen

El carcinoma inflamatorio de mama (CIM) se caracteriza por la presencia de cualquier subtipo de carcinoma agresivo asociado a una intensa reacción inflamatoria, además de la presencia de émbolos tumorales. Considerando el CIM como un tipo de cáncer con inflamación crónica, la compleja relación entre la inflamación y las alteraciones en el metabolismo celular, lleva a la posibilidad de realizar ensayos de antígeno canceroso 15-3 (CA 15-3), proteína c reactiva (PCR) y de lactato deshidrogenasa (LDH). El presente informe tuvo como objetivo describir un caso raro de carcinoma adenoescamoso en la glándula mamaria de una perra mestiza de 10 años, 7 kg, sexualmente intacta y cómo CA 15-3, CRP y LHD ayudaron a determinar la presentación clínica de la enfermedad carcinoma inflamatorio y el pronóstico. Se realizó estadificación clínica completa, hemograma y bioquímica renal y hepática, sin observarse alteraciones significativas. Los niveles de CA 15-3 (9,46 UI/mL), PCR (5,3 mg/L) y LDH (287 U/L) estuvieron todos por encima de los valores de referencia informados en la literatura. Aunque el carcinoma adenoescamoso de glándula mamaria con presentación inflamatoria en perros es raro, la asociación de biomarcadores séricos puede mejorar la evaluación pronóstica del paciente.

**Palabras clave:** Tumor mamario canino; Biomarcador sérico; Pronóstico.

## 1. Introduction

Canine mammary tumors (CMTs) are the most common neoplasms in female dogs and inflammatory mammary carcinoma (IMC) is the most aggressive form of mammary neoplasia (Ribeiro et al., 2020; Soremo, 2020; Vascellari et al., 2016). Clinically, patients with IMC present with the rapid appearance of inflammatory signs including erythema, edema, firmness, pain, and warmth of the mammary skin, with or without a defined mass. It is locally aggressive and highly metastatic that is poorly responsive to treatment, resulting in a poor prognosis, with invariably short survival times after diagnosis (Cassali et al., 2020; Souza et al., 2009).

In 2011, a new detailed histologic classification of subtypes of CMTs was published by Goldschmidt *et al.* (2011) and described the adenosquamous carcinoma, that is composed of areas of carcinoma of any type admixed with foci where the neoplastic cells exhibit squamous differentiation and features of malignancy. Islands and cords of epithelial cells are seen with the formation of keratin pearls. Cells and nuclei are large; the cells produce intracytoplasmic keratin tonofilaments; and intercellular bridges may be found. A marked secondary acute and chronic inflammatory cell infiltrate often occurs in these neoplasms. The neoplasm has its origin either from squamous cells of the teat duct or from ductal epithelial cells that had undergone squamous metaplasia and neoplastic transformation (Goldschmidt et al., 2011).

Histopathologically, IMC is characterized by the presence of any subtype of aggressive carcinoma in association with an intense inflammatory reaction, in addition to the presence of tumor emboli within dermal lymphatic vessels, resulting in profuse oedema, because of the obstruction of lymph drainage (Cassali et al., 2014; Goldschmidt et al., 2011).

Considering IMC as a type of cancer with chronic inflammation, expression of diverse inflammatory mediators has been explored in search for an explanation for the severe aggressiveness of the disease. Few biomarkers are specific for a single tumor, but their association can increase diagnostic accuracy (Kabel, 2017). The complex relationship recently described between mammary tumor, inflammation, and alterations in cellular metabolism have highlighted the rationale for combined assessment of cancer antigen 15-3 (CA 15-3), C-reactive protein (CRP), and lactate dehydrogenase (LDH) (Hanahan & Weinberg, 2011). In CMTs, CA 15-3 (Campos et al., 2012; Campos et al., 2015; Manuali et al., 2012; Valencakova-

Agyagosova et al., 2014), CRP (Planellas et al., 2009; Tecles et al., 2009; Szczubiał et al., 2018), and LDH (Campos et al., 2012) have been suggested as good biomarkers.

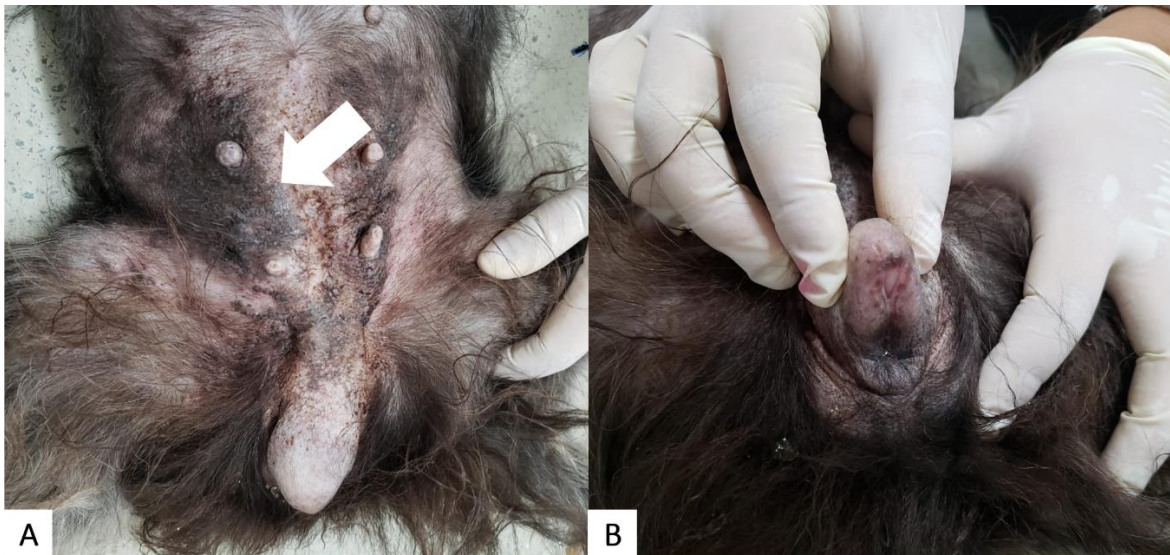The present report had the objective to describe a rare case of adenosquamous carcinoma in mammary gland of female dog, and how CA 15-3, CRP and LHD helped to determinate the clinical presentation of inflammatory carcinoma.

## 2. Case report

A 10-year-old, 7kg, sexually intact, female, mixed-breed dog was presented to the veterinary hospital reporting 30 days of erythematous skin on the last two mammary glands (M4 and M5) of the right chain, sized 8.0x3.0x0.5cm, with pain on palpation, and limb edema, with lameness, and vulvar edema in association (Figure 1).

The superficial inguinal lymph nodes were enlarged by palpation. The patient's heart rate, respiratory rate, and rectal temperature measured within normal limits. The patient's food and water intake were reportedly normal.

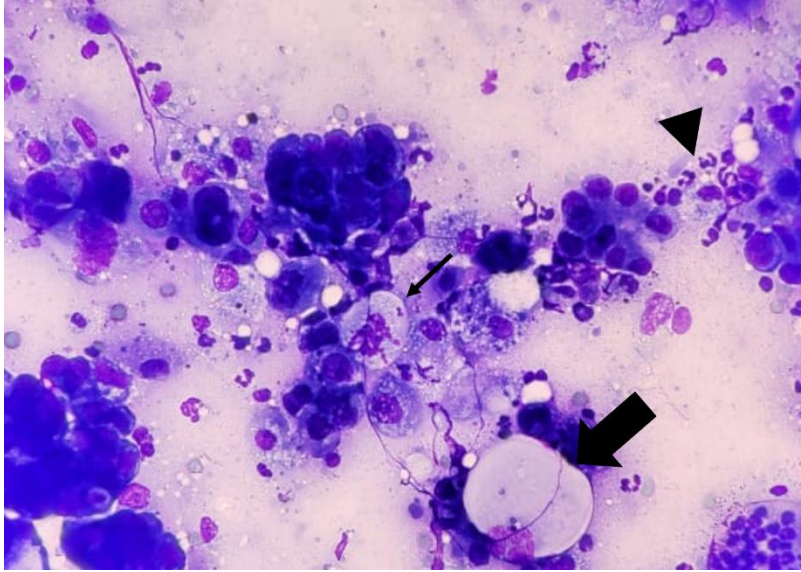
**Figure 1.** Inflammatory mammary carcinoma affecting the caudal mammary glands in a female dog. Note the lesion in M4 and M5 right (arrow) (A) and the vulvar edema (B).



Source: Authors.

Cytologic examination of the mammary gland by a fine needle aspirate was suggestive of a malignant epithelial tumor (Figure 2).

**Figure 2.** Female dog, mammary gland, cytology. Neoplastic epithelial proliferation exhibiting high pleomorphism (big arrow), vacuolization (thin arrow), and an intense inflammatory infiltrate (arrowhead). Diff-Quik stain, 400X.



Source: Authors.

Considering the clinical presentation and in view of the elucidate the suspicion case of IMC, the complete clinical staging, cell blood count, renal, and hepatic biochemistry as well as the serum biomarkers CA 15-3 (BR-MA, Simens®, Munich, Germany), CRP (PCR Turbiquest, Labtest®, Vista Alegre, Brazil) and LDH (LDH Liquiform, Labtest®, Vista Alegre, Brazil) were performed to help determine the prognosis of patient.

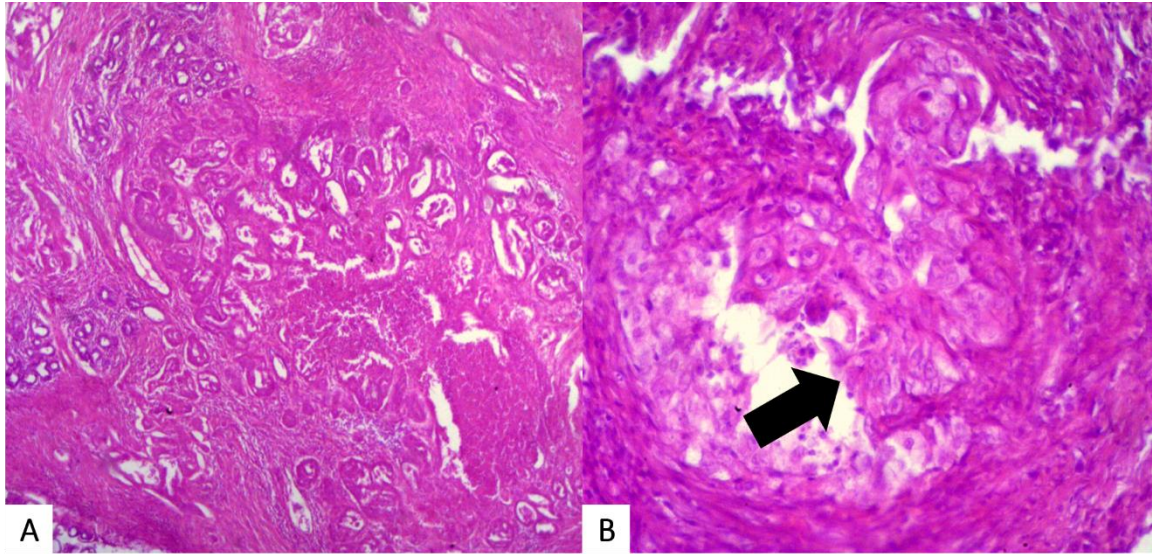
Metastatic disease was not detected on lateral (right and left) and ventrodorsal thoracic radiographs obtained at presentation. Abdominal ultrasonography, complete blood count, renal and hepatic serum biochemistry analysis did not reveal any significant abnormalities. The serum biomarkers CA 15-3 (9.46 IU/mL, Ref.: < 5.0 to 7.0 IU/mL), CRP (5.3 mg/L, Ref.: < 5 mg/L), and LDH (287 U/L, Ref.: 45 to 233 U/L) were all above the values reported by the literature (Carney et al., 2011; Kaneko et al., 2008; Valencakova-Agyagosova et al., 2014).

Based on clinical and laboratory findings, palliative treatment with piroxicam (0.3 mg/kg PO, SID) and tramadol (3mg/kg PO, TID) was recommended (Gregghi et al., 2021; Souza et al., 2009). 15 days after, the owner came back reported partial resolution of the left hind limb edema, lameness, and pain and erythema. However, the patient developed evidence of systemic disease (anorexia and lethargy) coupled with progressive deterioration of the clinical status. Given the clinical conditions of the patient, the owners opted for euthanasia.

A necropsy was performed and reveal thickening of the bilateral mammary gland, enlargement of bilateral inguinal lymph nodes, severe infiltration of fat and muscle tissue, and subcutaneous edema. Samples were collected and then fixed in 10% buffered formalin and cross-sections of the fragments were taken and routinely processed for histopathology. Histopathologic evaluation form mammary gland and regional lymph node indicated the presence of neoplastic proliferation consisting of tubular structures coated by malignant glandular epithelium with areas of malignant squamous differentiation, as well marked fibrous stroma that support an intense infiltrate of lymphocytes, plasmocytes and hemosiderophages, and foci of necrosis. Neoplastic emboli were observed in several dermal lymphatic vessels. Neoplastic cells were present in lymph nodes. The histopathologic results were consistent with a high grade adenosquamous carcinoma of the mammary gland with clinicopathologic presentation of IMC (Figure 3).



**Figure 3.** Female dog, mammary gland, histopathology. Neoplastic proliferation consisting of tubular structures coated by malignant glandular epithelium with areas of malignant squamous differentiation (arrow). H&E, 40X (A), 400X (B).



Source: Authors.

### 3. Discussion

Although the clinical signs in this patient were consistent with IMC, a definitive diagnosis was required. Cytologic examination performed on abnormal tissue confirmed the epithelial origin of the neoplasm, and histopathology showed the presence of tumor emboli in the dermal lymphatic vessels (Goldschmidt et al., 2011).

Based in the values of serum biomarkers, it was possible to infer that the case was a CMT with a poor prognosis. Few biomarkers are specific for a single tumor, but their association can increase diagnostic accuracy (Kabel, 2017). Ryuet al. (2019) suggest that the combined dosage of CRP with other serum biomarkers can increased the diagnostic accuracy for detecting cancer. Despite that work indicate the association of more than one biomarker in cases of cancer in dogs, there are no works evaluating CA 15-3, CRP and LDH simultaneously in cases of CMT.

Valencakova-Agyagosova et al. (2014) proposed a cut-off value of 5.0 to 7.0 IU/mL, with 100% sensitivity and 95.0% specificity, and suggested the application of CA 15-3 as a biomarker of first choice with high sensitivity and specificity for CMT. Until now, there have been non consensus for reference intervals indicated for CA 15-3. Largest tumors with lymph node metastasis (Campos et al., 2012; Campos et al., 2015) and higher grades based on histopathological analysis (Manuali et al., 2015) exhibit significantly higher concentration of CA 15-3.

Since CRP and LDH exhibit non-specific increase in various situations (Kaneko *et al.*, 2008; Carney et al., 2011), they could not be applied individually as the biomarkers for CMT. Although elevated CRP and LDH are not the biomarkers of cancer, they may serve as the cofactors that increase the diagnostic accuracy to detect CMT. Female dogs that exhibited larger nodules (Szczubiał et al., 2018), ulcerated skin (Planellas et al., 2009; Szczubiał et al., 2018), distant metastasis (Szczubiał et al., 2018), and high clinical stages (Tecles et al., 2009) exhibited higher concentrations of CRP. Campos et al. (2012) demonstrated a positive correlation between LDH concentration and clinical staging.

The patient in the present case received piroxicam as a palliative treatment. The use of a COX inhibitor as palliative therapy in cases of canine IMC has shown encouraging results and should be considered as a single agent for the treatment of this tumor type, this therapy significantly increased survival time in dogs than in those treated with traditional chemotherapy

protocols (Souza et al., 2009). In the present case, a brief clinical improvement was reported by the owner after treatment with piroxicam was begun.

Rasotto et al. (2017) reported that adenosquamous carcinoma present a slower disease progression (18 months), distant metastases were common, and that was the CMT that most commonly recurred. This tendency for local relapse might be attributable to the squamous component of the tumor, and the risks of dying from tumor-related causes was high. Adenosquamous carcinoma were usually grade III, the histologic grade was significantly associated with tumor-specific overall survival, local recurrence, and distant metastases (Goldschmidt et al., 2011; Peña et al., 2014; Rasotto et al., 2017). In the present report most of these facts were found except for the time of progression, that was much shorter than reported, probably because of high grade and IMC association.

#### 4. Conclusion

The association of serum biomarkers CA 15-3, PCR and LDH can improve the prognosis of the dog affected by adenosquamous carcinoma of the mammary gland with inflammatory presentation.

#### Acknowledgments

This work was financially supported by the National Council for Scientific and Technological Development (CNPq), process number 305420/2013-5. The authors are also grateful to the School of Veterinary Medicine and the Veterinary Hospital Dr. Sylvio Barbosa Cardoso in the State University of Ceará, Fortaleza, CE.

#### References

- Campos, L. C., Lavallo, G. E., Estrela-Lima, A., Melgaço de Faria, J. C., Guimarães, J. E., Dutra, Á. P., Ferreira, E., de Sousa, L. P., Rabelo, É. M. L., Vieira da Costa, A. F. D., & Cassali, G. D. (2012). CA15.3, CEA and LDH in Dogs with Malignant Mammary Tumors. *Journal of Veterinary Internal Medicine*, 26(6), 1383–1388.
- Campos, L. C., Silva, J. O., Santos, F. S., Araújo, M. R., Lavallo, G. E., Ferreira, E., & Cassali, G. D. (2015). Prognostic significance of tissue and serum HER2 and MUC1 in canine mammary cancer. *Journal of Veterinary Diagnostic Investigation*, 27(4), 531–535.
- Carney, P. C., Ruaux, C. G., Suchodolski, J. S., Steiner, J. M. (2011). Biological variability of C-reactive protein and specific canine pancreatic lipase immunoreactivity in apparently healthy dogs. *Journal of Veterinary Internal Medicine*, 25(4), 825-30.
- Cassali, G. D., Jark, P. C., Gamba, C., Damasceno, K. A., Estrela-Lima, A., De Nardi, A. B., Ferreira, E., Horta, R. S., Firmo, B. F., Sueiro, F. A. R., Rodrigues, L. C. S., & Nakagaki, K. Y. R. (2020). Consensus regarding the diagnosis, prognosis and treatment of canine and feline mammary tumors-2019. *Brazilian Journal of Veterinary Pathology*, 13(3), 555–574.
- Cassali, G. D., Lavallo, G. E., Ferreira, E., Estrela-Lima, A., de Nardi, A. B., Ghever, C., Sobral, R. A., Amorim, R. L., Oliveira, L. O., Sueiro, F. A. R., Beserra, H. E. O., Bertagnolli, A. C., Gamba, C. O., Damasceno, K. A., Campos, C. B., Araujo, M. R., Campos, L. C., Monteiro, L. N., Nunes, F. C., ... Torres, R. (2014). Consensus for the diagnosis, prognosis and treatment of canine mammary tumors-2013. *Brazilian Journal of Veterinary Pathology*, 7(2), 38–69.
- Goldschmidt, M. H., Peña, L., Rasotto, R., & Zappulli, V. (2011). Classification and grading of canine mammary tumors. *Veterinary Pathology*, 48(1), 117–131.
- Greggi, J. R., Fernandes, M. P., Groth, A., Silva, L. A. S., Schnitzer, J. F., Di Santis, G. W., Martins, M. I. M. (2021). Thermographic evaluation of piroxicam's effect as an adjuvant treatment in canine mammary tumors. *Research, Society and Development*, 10(2), e18710212236.
- Hanahan, D., & Weinberg, R. A. (2011). Hallmarks of cancer: The next generation. *Cell*, 144(5), 646–674.
- Kabel, A. M. (2017). Tumor markers of breast cancer: New prospectives. *Journal of Oncological Sciences*, 3(1), 5–11.
- Kaneko, J. J., Harvey, J. W., Bruss, M. L. (2008). *Clinical Biochemistry of Domestic Animals*. 6th ed. San Diego: Academic Press.
- Manuali, E., De Giuseppe, A., Feliziani, F., Forti, K., Casciari, C., Marchesi, M. C., Pacifico, E., Pawłowski, K. M., Majchrzak, K., & Król, M. (2012). CA 15-3 cell lines and tissue expression in canine mammary cancer and the correlation between serum levels and tumour histological grade. *BMC Veterinary Research*, 22(8), 86.
- Peña, L., Gama, A., Goldschmidt, M. H., Abadie, J., Benazzi, C., Castagnaro, M., Díez, L., Gärtner, F., Hellmén, E., Kiupel, M., Millán, Y., Miller, M. A., Nguyen, F., Poli, A., Sarli, G., Zappulli, V., & de las Mulas, J. M. (2014). Canine Mammary Tumors: A Review and Consensus of Standard Guidelines on

- Epithelial and Myoepithelial Phenotype Markers, HER2, and Hormone Receptor Assessment Using Immunohistochemistry. *Veterinary Pathology*, 51(1), 127–145.
- Planellas, M., Bassols, A., Siracusa, C., Saco, Y., Giménez, M., Pato, R., & Pastor, J. (2009). Evaluation of serum haptoglobin and C-reactive protein in dogs with mammary tumors. *Veterinary Clinical Pathology*, 38(3), 348–352.
- Rasotto, R., Berlato, D., Goldschmidt, M. H., & Zappulli, V. (2017). Prognostic Significance of Canine Mammary Tumor Histologic Subtypes: An Observational Cohort Study of 229 Cases. *Veterinary Pathology*, 54(4), 571–578.
- Ribeiro, T. A., Ferreira, V. R. F., Mondêgo-Oliveira, R., Andrade, F. H. E., Abreu-Silva, A. L., Oliveira, I. S., Melo, S. A., Teófilo, T. S., Torres, M. A. O. (2020). Epidemiological profile of canine neoplasms in São Luís/MA: a retrospective study (2008-2015). *Research, Society and Development*, 9(12), e8291210496.
- Ryu, M. O., Kim, B. G., Choi, U. S., Baek, K. H., Song, Y. K., Li, Q., Seo, K. W., Ryeom, S., Youn, H. Y., & Bhang, D. H. (2019). Extracellular cyclic adenosine monophosphate-dependent protein kinase A autoantibody and C-reactive protein as serum biomarkers for diagnosis of cancer in dogs. *Veterinary and Comparative Oncology*, 17(1), 99–106.
- Sorenmo, K. U., Worley, D. R., Zappulli, V. (2020). Tumors of the Mammary Gland. In: Vail DM, Thamm DH, Liptak JM, *Small Animal Clinical Oncology*. 6th ed. St. Louis: Elsevier.
- Souza, C. H. M., Toledo-Piza, E., Amorin, R., Barboza, A., & Tobias, K. M. (2009). Inflammatory mammary carcinoma in 12 dogs: Clinical features, cyclooxygenase-2 expression, and response to piroxicam treatment. *Canadian Veterinary Journal*, 50(5), 506–510.
- Szczubiał, M., Dabrowski, R., Łopuszyński, W., Bochniarz, M., & Krawczyk, M. (2018). Changes in serum neopterin and C-reactive protein concentrations in female dogs with mammary gland tumours. *Polish Journal of Veterinary Sciences*, 21(4), 691–696.
- Tecles F., Caldín M., Zanella A., Membiela F., Tvarijonavičiute A., Subiela S. M., & Cerón J. J. (2009). Serum acute phase protein concentrations in female dogs with mammary tumors. *Journal of Veterinary Internal Medicine*, 21(2), 214-219.
- Valencakova-Agyagosova, A., Frischova, Z., Sevcikova, Z., Hajurka, J., Lepej, J., Szakalova, I., Kredatusova, G., Nagy, V., & Ledecy, V. (2014). Determination of carcinoembryonic antigen and cancer antigen (CA 15-3) in bitches with tumours on mammary gland: Preliminary report. *Veterinary and Comparative Oncology*, 12(3), 205–214.
- Vascellari, M., Capello, K., Carminato, A., Zanardello, C., Baioni, E., & Mutinelli, F. (2016). Incidence of mammary tumors in the canine population living in the Veneto region (Northeastern Italy): Risk factors and similarities to human breast cancer. *Preventive Veterinary Medicine*, 126, 183–189.