

## Canine atopic dermatitis: report of ten cases

Dermatite atópica canina: relato de dez casos

Dermatitis atópica canina: reporte de diez casos

Received: 02/21/2022 | Reviewed: 03/01/2022 | Accept: 03/06/2022 | Published: 03/13/2022

**Tiago Cunha Ferreira**

ORCID: <https://orcid.org/0000-0002-0130-022X>  
Ceara State University, Brazil  
E-mail: [tiago.cunha@uece.br](mailto:tiago.cunha@uece.br)

**Victor Machado de Carvalho**

ORCID: <https://orcid.org/0000-0001-5937-112X>  
Ceara State University, Brazil  
E-mail: [victormachado02@hotmail.com](mailto:victormachado02@hotmail.com)

**Marina Gabriela Monteiro Carvalho Mori da Cunha**

ORCID: <https://orcid.org/0000-0001-6658-7797>  
Laboratory for Translational Genetics, Belgium  
E-mail: [biamori@gmail.com](mailto:biamori@gmail.com)

**Diana Célia Sousa Nunes Pinheiro**

ORCID: <https://orcid.org/0000-0002-4505-9941>  
Ceara State University, Brazil  
E-mail: [diana.pinheiro@uece.br](mailto:diana.pinheiro@uece.br)

### Abstract

Canine atopic dermatitis (cAD) is a multifactorial allergic disease associated with immune dysfunction and an abnormal skin barrier. Together, these factors result in cutaneous inflammatory and infectious processes with different injury patterns. The clinical understanding and diagnosis of these patterns are crucial for the best clinical management of the atopic patient. As it is often a clinical challenge for the veterinarian, the objective of the present study was to describe the follow-up of ten cases of canine atopic dermatitis. Therefore, a retrospective analysis of ten dogs diagnosed with cAD was performed, from crisis control therapy to maintenance therapy. Dogs received an individualized treatment approach based on their different clinical manifestations. All selected dogs showed an adequate response to the proposed treatments, which provided control of the inflammatory and pruritic stimulus. From the above, it was concluded that canine atopic dermatitis has different clinical patterns and, therefore, individualized therapeutic strategies should be adopted for a better clinical resolution.

**Keywords:** Inflammatory response; Allergic skin disease; Skin hypersensitivity.

### Resumo

A dermatite atópica canina (DAC) é uma doença alérgica multifatorial associada a disfunção imunológica e barreira cutânea anormal. Em conjunto, esses fatores resultam em processos inflamatórios e infecciosos cutâneos com diferentes padrões de lesão. O entendimento clínico e diagnóstico desses padrões são cruciais para o melhor manejo clínico do paciente atópico. Por tratar-se, frequentemente, de um desafio clínico ao médico veterinário, o objetivo do presente trabalho foi descrever o acompanhamento de dez casos de dermatite atópica canina. Para tanto, foi realizada uma análise retrospectiva de dez atendimentos de cães diagnosticados com DAC, desde a terapia de controle de crise até a terapia de manutenção. Os animais do trabalho apresentaram diferentes alterações clínicas, assim como diferentes pontos corpóreos afetados, de modo que o tratamento foi individualizado de acordo com cada animal. Todos os cães selecionados apresentaram adequada resposta aos tratamentos propostos, os quais proporcionaram controle de resposta inflamatória e pruriginosa. A partir do exposto, concluiu-se que a dermatite atópica canina possui diferentes padrões clínicos e, portanto, estratégias terapêuticas individualizadas devem ser adotadas para uma melhor resolução clínica.

**Palavras-chave:** Resposta inflamatória; Dermatopatia alérgica; Hipersensibilidade cutânea.

### Resumen

La dermatitis atópica canina (DAC) es una enfermedad alérgica multifactorial asociada con una disfunción inmunitaria y una barrera cutánea anormal. Juntos, estos factores dan como resultado procesos inflamatorios e infecciosos cutáneos con diferentes patrones de lesiones. La comprensión clínica y el diagnóstico de estos patrones son cruciales para el mejor manejo clínico del paciente atópico. Como suele ser un reto clínico para el veterinario, el objetivo del presente estudio fue describir el seguimiento de diez casos de dermatitis atópica canina. Por lo tanto, se realizó un análisis retrospectivo de diez visitas de perros diagnosticados con DAC, desde la terapia de control de crisis hasta la terapia de mantenimiento. Los animales del trabajo presentaban diferentes alteraciones clínicas, así como

diferentes puntos corporales afectados, por lo que se individualizó el tratamiento según cada animal. Todos los perros seleccionados mostraron una respuesta adecuada a los tratamientos propuestos, lo que permitió controlar la respuesta inflamatoria y pruriginosa. De lo anterior se concluyó que la dermatitis atópica canina tiene diferentes patrones clínicos y, por lo tanto, se deben adoptar estrategias terapéuticas individualizadas para una mejor resolución clínica.

**Palabras clave:** Respuesta inflamatoria; Enfermedad alérgica de la piel; Hipersensibilidad de la piel.

## 1. Introduction

Canine atopic dermatitis (cAD) is characterized as a clinical inflammatory syndrome whose development involves the interaction between genetic and environmental factors (Marsella, 2021). Together, these factors are able to influence the skin immune response to a pro-inflammatory state, which ultimately leads to microbiome imbalance and cutaneous injuries (Stefanovic et al., 2021).

Pruritus is the main clinical manifestation of cAD, which precedes other clinical signs. The body points commonly affected are distal extremities and areas of limb flexures, face, abdomen and ears (Favrot et al., 2010). Atopic dogs may also present with a variety of lesions, such as erythema, alopecia, excoriations, hyperpigmentation and lichenification (Eisenschenk, 2020). Bacterial infections, most commonly by *Staphylococcus pseudintermedius*, and fungal, most commonly by *Malassezia spp.*, are common in cAD (Nutall et al., 2019), since the failure of the epidermal barrier favors the exacerbated proliferation of microorganisms residing in the integument. These infections result in a worsening of skin lesions with progression of pruritus and the inflammatory process (Rodrigues-Hoffman et al., 2014).

There are no diagnostic tests for cAD (Marsella, 2021), being it dependent on clinical analysis and sequential exclusion of other pruritic skin diseases (Nutall et al., 2019). Differential diagnoses, ranging from ectoparasites to neoplasms, should be excluded based on anamnesis data, clinical and laboratory findings (Hensel et al., 2015). The first step involves eliminating fleas and ticks, which may be causing the allergic process. In addition, attention should be drawn to other possible ectoparasites, such as some mites, which may be triggering pruritus (Nutall et al., 2019). The next step involves food restriction, with changing of the diet protein source for at least eight weeks (Olivry et al., 2015). If pruritus is still present, even after completion of all steps, the possibility of canine atopic dermatitis can be considered as a definitive diagnosis (Hensel et al., 2015).

After diagnosis, an adequate therapeutic plan should be established, since cAD has no cure (Marsella, 2021). The treatment aims to improve the quality of life of the animal, as well as the tutor, by minimizing the frequency and intensity of allergic crises (Nutall et al., 2019). Because it is a disease with a complex involvement of the immune system, the treatment must be individualized and based on the dog clinical profile (Eisenschenk, 2020) and, often, it becomes a clinical challenge for the veterinarian. Thus, the objective of the present study is to describe the follow-up of ten cases of atopic dermatitis with varying lesion patterns.

## 2. Methodology

The present study comes from a retrospective analysis of cases treated at a private clinic in Fortaleza/CE in the year 2021. Ten patients with a definitive diagnosis of cAD were selected, who were able to follow all stages of care, from suspicion to the diagnostic conclusion. All dogs underwent clinical and dermatological evaluation and the diagnosis of cAD was established after screening and exclusion of other pruritic skin diseases (Nutall et al., 2019). In addition, animals with pruritus without lesions and clinical lesions suggestive of Superficial Pyoderma, Otitis Externa and/or Skin Malasseziosis were included in the present study. Such dogs were submitted, during the clinical-dermatological evaluation, to cutaneous and auricular parasitological and cytological exams in order to confirm and/or exclude skin infections.

### **2.1 Diagnosis of Canine Atopic Dermatitis**

Dogs were diagnosed with cAD based on compatible clinical history and exclusion of other pruritic skin diseases. The dogs were also submitted to an elimination diet to evaluate food hypersensitivity and adequate control of ectoparasites to eliminate allergy to flea and tick bites. In addition, parasitological tests were carried out to identify mites, and skin cytological tests to analyze the presence of cutaneous infection at the time of consultation.

### **2.2 Cutaneous and auricular parasitological analysis**

The cutaneous parasitological analysis was performed with skin scraping using a scalpel blade. Five random lesions were chosen and, from these lesions, skin material was collected to exclude parasitic diseases. Regarding the auricular parasitological evaluation, this was performed using a swab, which was introduced into the vertical canal in order to collect auricular secretion. This material was placed on a glass slide and evaluated under an optical microscope to exclude ear mites.

### **2.3 Cutaneous and auricular cytological analysis**

Aiming at characterizing the cutaneous and otological infectious processes, biological samples from these sites were collected at the time of the clinical consultation. Skin samples were collected from epidermal collars, pustules or skin secretions by scarification and imprinting, while ear secretion samples were collected with a swab. These materials were fixed on microscope slides, stained with Quick-Diff and evaluated with the aid of optical microscopy to identify the microorganisms associated with cAD.

### **2.4 Treatments and clinical follow-up**

The animals were initially treated according to clinical-dermatological evaluation. When necessary, immunomodulators, skin barrier replenishers and oral/topical antimicrobials were used, according to previously published studies (Olivry et al., 2015). Therapy was divided into two stages: flare treatment (day 0) and maintenance treatment (day 30). The used drugs in each animal are shown in Table 1.

**Table 1.** Therapeutic approach of dogs with cAD. Flare treatment was established at D0 while maintenance treatment was proposed at D30.

Case	Flare treatment (D0)	Maintenance Treatment (D30)
1	Prednisolone (VO) and bathing with Hexadene Shampoo® (2x/week).	Bathing with Allermyl Glyco Shampoo® (2x/week), Hidrapet® (SID) and Cortavance® (2x/week).
2	Apoquel® (VO) and bathing with Allermyl Glyco Shampoo® (2x/week).	Apoquel® (VO), bathing with Allermyl Glyco Shampoo® (2x/week) and Episoothe Conditioner® (2x/week).
3	Cephalexin (VO), Prednisolone (VO), bathing with Hexadene Shampoo® (2x/week) and Easotic ear solution® .	Cyclavance® (VO), bathing with Hexadene Shampoo® (2x/week) and Episoothe Conditioner® (2x/week) and PhisioAntiodor ear solution® (2x/week).
4	Prednisolone (VO), bathing with Sebolytic Shampoo® (2x/week) and Posatex® ear solution.	Cyclavance® (VO), bathing with Sebolytic Shampoo® (2x/week), Douxo Seb Spray® (SID) and 0.02% Fluocinolone and Tris EDTA compounded ear solution (2x/week).
5	Prednisolone (VO), bathing with Hexadene Shampoo® (2x/week) and Easotic ear solution®.	Bathing with Allermyl Glyco Shampoo® (2x/week), Hidrapet® (SID), Cortavance® (2x/week) and PhisioAntiodor ear solution® (2x/week).
6	Apoquel® (VO) and bathing with Episoothe Shampoo® (2x/week).	Apoquel® (VO) and bathing with Episoothe Shampoo® (2x/week) and Episoothe Conditioner® (2x/week).
7	Prednisolone (VO), bathing with 2.5% Selenium sulphide compounded shampoo (2x/week) and Posatex ear solution®.	Cyclavance® (VO), bathing with 2.5% Selenium sulphide compounded shampoo (2x/week), Douxo Seb Spray® (SID), Easotic ear solution® (1x/week)
8	Cytopoint® (SC) and bathing with Allermyl Glyco Shampoo® (2x/week).	Cytopoint® (SC), bathing with Allermyl Glyco Shampoo® (2x/week) and Hidrapet® (SID).
9	Prednisolone (VO), bathing with Hexadene Shampoo® (2x/week) and Easotic ear solution®.	Bathing with Allermyl Glyco Shampoo® (2x/week), Hidrapet® (SID), Cortavance® (2x/week) and 0.02% Fluocinolone and Tris EDTA compounded ear solution (2x/week).
10	Prednisolone (VO), Cyclavance® (VO), bathing with Sebolytic shampoo® (2x/week) and Dermotrat Cream® (BID).	Cyclavance® (VO), bathing with Sebolytic shampoo® (2x/week), Douxo Seb Spray® (SID).

Source: Authors.

### 3. Results

The individual data of dogs, as well as the lesion distribution are described in table 2. In the evaluated atopic animals, inflammatory and/or infectious alterations were observed in the ears, limbs, axillae/thorax, groin/abdomen, chin/neck, dorsum, periocular and flank. It is noteworthy that some animals had more than one affected site simultaneously.

Fifty percent (n=5/10) of the dogs were diagnosed with concomitant superficial pyoderma (Figure 1), while 30% (n=3/10) were diagnosed with cutaneous Malasseziosis (Figure 2). Otitis externa (Figure 3) was diagnosed in 50% (n=5/10) of the dogs affected with cAD. Yeasts were the microorganisms most frequently identified on cytological examination (three dogs), followed by coccoid bacteria (two dogs) and rods (one dog). The results are described in Table 2 and the cytological images are shown in Figure 4. Some dogs presented only an inflammatory process, without associated infection.

Regarding the treatment, good clinical resolution of the inflammatory and pruritic process was observed in all animals within a period of 30 days of therapy. After the initial approach, maintenance treatment was carried out, consisting of moisturizing products and skin barrier replenishers, as well as immunomodulators. The individual therapeutic approach is

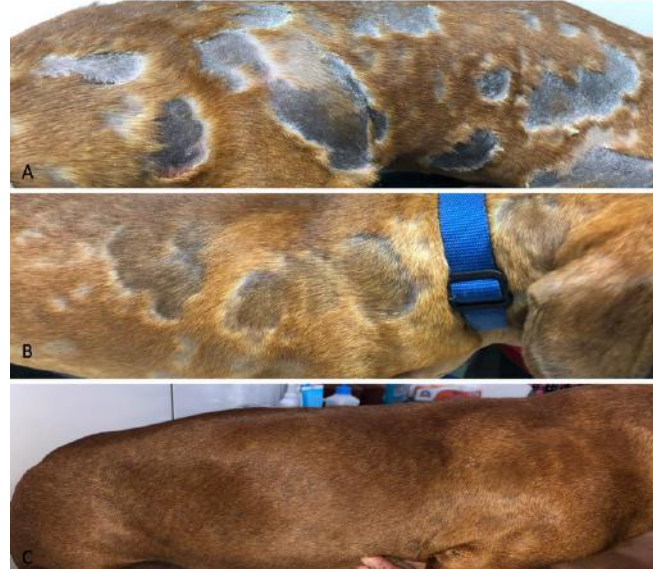shown in Table 1, and the results of the therapies are shown in Figures 1, 2 and 3.

**Table 2.** Clinical data, clinical signs and secondary infections of dogs with cAD.

Case	Breed	Age	Sex	Clinical Signs	Location	Cutaneous/ Ear Infections
1	Mixed Breed	2 years	Male	Pustules, alopecia and epidermal collars	Abdomen, axillae	Superficial pyoderma
2	Poodle	3 years	Male	Erythema and hypotrichosis	Axillae and limbs	No infection
3	Dachshund	2 years	Female	Alopecia, meliceric crusts, epidermal collars	Dorsum and ears	Superficial pyoderma and otitis externa
4	Shih-Tzu	5 years	Male	Alopecia, scaling, erythema, hyperpigmentation	Ventral neck, abdomen and ears	Malasseziosis and otitis externa
5	Shih-Tzu	4 years	Female	Pustules, scaling, epidermal collars	Abdomen, ear	Superficial pyoderma and otitis externa
6	Yorkshire Terrier	7 years	Female	Erythema	Abdomen and limbs	No infection
7	Golden Retriever	1 year	Female	Alopecia, erythema, hyperpigmentation and lichenification	Axillae, abdomen, ventral neck and limbs	Malasseziosis and otitis externa
8	Mixed Breed	2 years	Male	Erythema	Axillae and abdomen	No infection
9	Poodle	2 years	Female	Scaling, epidermal collars and alopecia	Abdomen, limbs and ears	Superficial pyoderma and otitis externa
10	Schnauzer	4 years	Male	Alopecia, erythema, hyperpigmentation and lichenification	Ventral neck, axillae, abdomen and limbs	Superficial pyoderma and Malasseziosis

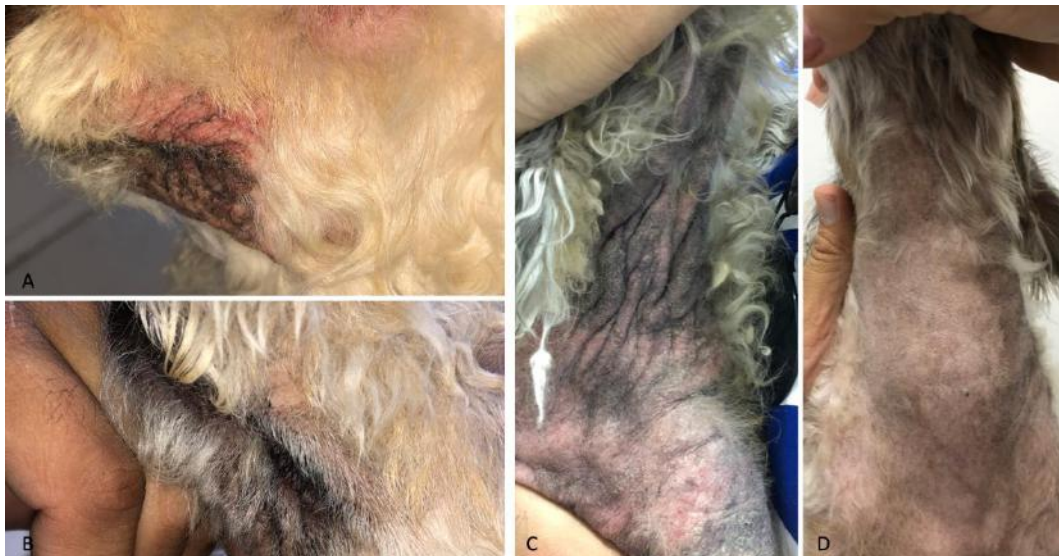Source: Authors.

**Figure 1.** Superficial bacterial pyoderma lesion pattern before and after treatment. (A) Initial appearance of the lesion, with the presence of large alopecic areas and diffuse epidermal collar lesions throughout the body. (B) Lesion appearance 30 days after the start of therapy, with reduction of the inflammatory and scaling process, and beginning of repilation. (C) Lesion appearance after 60 days of therapy.



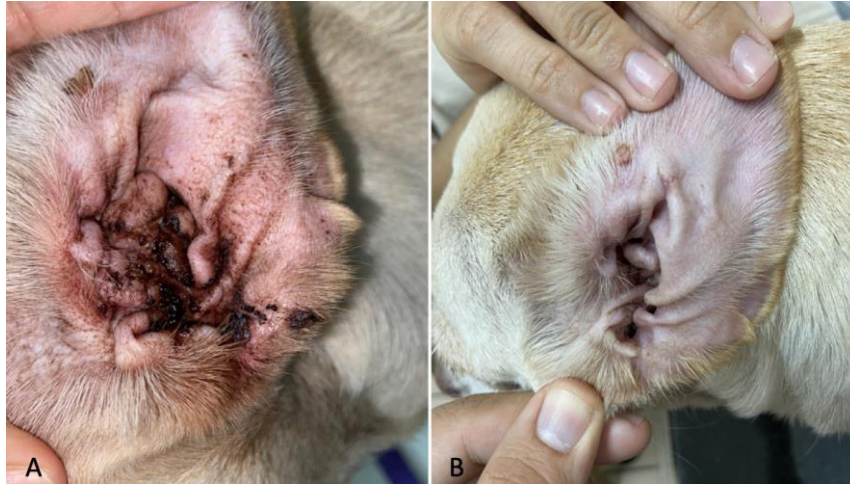Source: Authors.

**Figure 2.** Clinical appearance of cutaneous lesions associated with cutaneous Malasseziosis. Erythema, hyperpigmentation and lichenification are observed in the perilabial (A) and cervicothoracic (C) regions. (B) and (D) Clinical aspect of the lesion after 30 days of therapy, with reduction of the inflammatory and scaling process, as well as the beginning of hair growth.



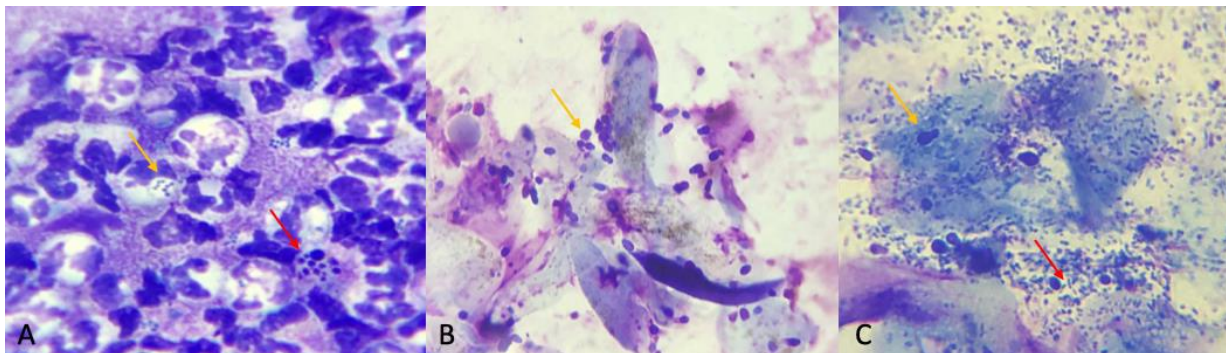
Source: Authors.

**Figure 3.** Clinical appearance of a canine ear with otitis externa secondary to canine atopic dermatitis. (A) An erythematous lesion is observed, with discrete hematic crusts, erythema and lichenification of the ear pinna. (B) Clinical appearance of the pinna after 30 days of infection and inflammatory control therapy.



Source: Authors.

**Figure 4.** Cytology of lesions in canine atopic dermatitis. (A) Pyogranulomatous inflammatory infiltrate and presence of degenerated cells (red arrow) and coccoid bacteria inside phagocytes (yellow arrow). (B) Presence of a moderate amount of yeast cells compatible with *Malassezia spp.* (yellow arrow). (C) Cytology of ear secretion with an intense amount of yeasts (yellow arrow) and bacterial (red arrow) microorganisms. Diff-Quick stain, 1000x.



Source: Authors.

#### 4. Discussion

The present study brings a contribution about the clinical follow-up of dogs affected by atopic dermatitis in a private clinic in Fortaleza, with ten different cases of cAD with different clinical presentations. Dogs affected by the disease were mostly adult animals, which is the most common age at which signs associated with cAD appear (Favrot et al., 2010). Regarding the lesion sites, these are compatible with the disease pattern, being the abdomen, limbs and ears the most affected sites (Favrot et al., 2019). However, lesion sites can also vary according to secondary infections (Bloom, 2014) and to the breeds, a fact that can be attributed to the racial phenotype (Wilhem et al., 2011).

It is also known that in observed lesions there may be disordered growth of microorganisms, since the skin microbiota of atopic animals is altered (Rodrigues-Hoffman et al., 2014). This dysbiosis predisposes to cutaneous infections and triggers abnormal inflammatory responses involved in pathogenesis of atopic dermatitis (Gallo & Nakatsuji, 2011). Such infections can affect both the skin and the ears, being manifestations that make it difficult to resolve the cutaneous inflammation associated

with cAD, as they promote an immune polarization towards the Th2 pathway with consequent production of pro-inflammatory cytokines (Pucheu-Haston et al., 2015). In the described animals, the presence of infectious processes in skin and ears was observed, which, when controlled, resulted in the reduction of the cutaneous inflammatory process. It is also noteworthy that such infections are sometimes recurrent, due to the complexity of the relationships between microorganisms and the host (Rodrigues-Hoffmann et al., 2014), and control strategies are needed in order to delay their appearance.

The therapy of cAD involves the combination of several treatments, since it is a pathology of multifactorial etiology and complex pathogenesis, still to be fully understood (Marsella, 2021). Interventions with oral glucocorticoids, oclacitinib, lokivetmab or cyclosporine are part of the therapeutic protocol to promote pruritus relief (Olivry & Banovic, 2019; Marques et al., 2021). Corticosteroids are the first line of widespread antipruritic and anti-inflammatory drugs to control the disease, due to their low cost and high efficacy (Olivry et al., 2015). After this initial period of therapy, it is recommended to reduce the dose and frequency of drug administration, as well as replacement with therapies with less potential for side effects (Olivry et al., 2015; Olivry & Banovic, 2019). As recommended for human atopic dermatitis (Wollenberg et al., 2018), the drugs were chosen based on the lesion type and intensity.

In infection cases, topical and/or systemic antimicrobials (antibiotics and/or antifungals) should also be used (Olivry et al., 2015). For the control of bacterial infections, the use of topical antiseptics, such as chlorhexidine, is recommended, and, in refractory cases, the use of systemic drugs, such as beta-lactams and quinolones (Bloom, 2014). Chlorhexidine is an antiseptic that has action against fungi, viruses and most bacteria that cause skin infection, in addition to having residual activity by adherence to the surface of the skin and hair (Ferreira et al., 2019; Larsson & Lucas, 2020). Aiming at the control of fungal infections by yeasts, the use of sulfur, salicylic acid, coal tar or azoles derivatives is recommended (Larsson & Lucas, 2020). In the animals of the present study, topical antimicrobial strategies were adopted, and the use of oral drugs was recommended only in situations of greater lesion severity. This decision was adopted due to the secondary characteristic of infectious processes in cAD (Bloom, 2014), so that oral antimicrobials could potentially destabilize the general microbiota, without guarantees that there will be no recurrence of skin lesions.

With regard to maintenance therapy, the importance of preventing or delaying the onset of the skin inflammatory process is highlighted (Olivry & Banovic, 2019). Therefore, a multimodal therapeutic approach is necessary (Olivry et al., 2015; Bensignor & Videmont, 2022) and, considering the individuality of each patient, the combined use of drugs can be evaluated. It is noteworthy that, as it is a chronic disease (Marsella, 2021), affected dogs undergo long-term treatments (Olivry et al., 2015) and, therefore, organic monitoring is recommended in order to avoid serious side effects associated with the systemic drugs. In the described cases, different strategies with and without the use of systemic immunomodulators were proposed, based on the intensity of the lesions and pruritic crises of the patients. We also emphasize the importance of therapies aimed at improving the quality of the skin, with the use of moisturizing and skin repair products, so that their use may reduce the severity of subsequent inflammatory crisis.

Auricular therapy involved controlling the infectious and inflammatory process with the use of topical antimicrobials and anti-inflammatory drugs associated with Tris-EDTA. This compound is capable of damaging the cell wall of bacteria, is well tolerated and non-ototoxic (Boyd et al., 2019). As maintenance, neutral cerumenolytic solutions or those incorporated into topical corticosteroids were chosen, in order to constantly control the inflammatory process and, therefore, avoid changes related to chronic inflammation (Huang et al., 2009). Only one out of ten patients had to opt for the continuous use of auricular antimicrobials, since only the control with the previously used topical corticosteroid was not enough for the adequate maintenance of otitis externa crisis.

In this study, all patients presented excellent therapeutic results in the control phase of the pruritic crisis and in the maintenance phase of the treatment, with an improvement in their quality of life, as well as that of their owners. In patients



with greater intensity of injury, follow-up was recommended every three months for monitoring and treatment adjustments, and for the others, a visit between four to six months was recommended. The maintenance period of therapy is essential to avoid severe itching (Olivry & Banovic, 2019). However, the difficulty reported by tutors to create and maintain the product administration routine and reassessment consultations is known (Spitznagel et al., 2021). As strategies to improve the adherence of tutors to treatments in the reported animals, the importance of each drug was demonstrated, as well as the correct use of otologic drugs. In addition, it was decided to minimize the number of used drugs, making the routine of drug administration less complex.

## 5. Conclusion

From the above, it is concluded that canine atopic dermatitis has different clinical presentations and, thus, different therapies can be adopted in order to culminate in pruritus and inflammation control. It is also important to identify the lesion patterns of this disease, aiming at a more accurate diagnosis, since other differential diagnosis can mimic atopic dermatitis clinical signs.

## References

- Bensignor, E., & Videmont, E. (2022). Weekly topical therapy based on plant extracts combined with lokivetmab in canine atopic dermatitis. *Veterinary Dermatology*, 33, 68-e22.
- Bloom, P. (2014). Canine superficial bacterial folliculitis: Current understanding of its etiology, diagnosis and treatment. *The Veterinary Journal*, 199, 217-222.
- Boyd, M., Santoro, D., & Gram, D. (2019). In vitro antimicrobial activity of topical otological antimicrobials and Tris-EDTA against resistant *Staphylococcus pseudintermedius* and *Pseudomonas aeruginosa* isolates from dogs. *Veterinary Dermatology*, 30, 139-e40.
- Eisenschenk, M. (2020). Phenotypes of Canine Atopic Dermatitis. *Current Dermatology Reports*, 9, 1-6.
- Favrot, C., Steffan, J., Seewald, W., & Picco, F. (2010). A prospective study on the clinical features of chronic canine atopic dermatitis and its diagnosis. *Veterinary Dermatology*, 21, 23-31.
- Favrot C., Fischer N., Olivry T., Zwickl L., Audergon S., & Rostaer A. (2019). Atopic dermatitis in West Highland white terriers – part I: natural history of atopic dermatitis in the first three years of life. *Veterinary Dermatology*, 31, 106-e16.
- Ferreira, T. C., Guedes, R. F. M., Bezerra, B. M. O., & Nunes-Pinheiro, D. C. S. (2019). Mupirocin Pemphigus-Like Drug Reaction in a Dog. *Acta Scientiae Veterinariae*, 47, 1-6.
- Gallo, R. L., & Nakatsuji, T. (2011). Microbial Symbiosis with the Innate Immune Defense System of the Skin. *Journal of Investigative Dermatology*, 131, 1974-1980.
- Hensel, P., Santoro, D., Favrot, C., Hill, P., & Griffin, C. (2015). Canine atopic dermatitis: detailed guidelines for diagnosis and allergen identification. *BMC Veterinary Research*, 11, 1-13.
- Huang, H. P., Little, C. J. L., & McNeil, P. E. (2009). Histological changes in the external ear canal of dogs with otitis externa. *Veterinary Dermatology*, 20, 422-428.
- Larsson, C. E., & Lucas, R. (2020). *Tratado de medicina externa: dermatologia veterinária*. (2a ed.), Interbook.
- Marques, V. S., Calessio, J. R., & Bicalho, A. P. C. V. (2021). Evaluation of quality of life in dogs with atopic dermatitis and their owners after lokivetmab therapy. *Research, Society and Development*, 10, 1-8.
- Marsella, R. (2021). Advances in our understanding of canine atopic dermatitis. *Veterinary Dermatology*, 32, 547-e151.
- Nutall, T. J., Marsella, R., Rosenbaum, M. R., Gonzales, A. J., & Fadok, V. A. (2019). Update on pathogenesis, diagnosis, and treatment of atopic dermatitis in dogs. *Journal of American Veterinary Medical Association*, 254, 1291-1300.
- Olivry, T., & Banovic, F. (2019). Treatment of canine atopic dermatitis: time to revise our strategy? *Veterinary Dermatology*, 30, 87-90.
- Olivry, T., Deboer, D., Favrot, C., Jackson, H. A., Mueller, R.S., Nutall, T., & Prélaud, P., International Committee on Allergic Diseases of Animals. (2015). Treatment of canine atopic dermatitis: 2015 updated guidelines from the International Committee on Allergic Diseases of Animals (ICADA). *BMC Veterinary Research*, 11, 210.
- Olivry, T., Mueller, R. S., & Prélaud, P. (2015). Critically appraised topic on adverse food reactions of companion animals (1): duration of elimination diets. *BMC Veterinary Research*, 11, 1-3.

- Pucheu-Haston, C. M., Bizikova, P., Marsella, R., Santoro, D., Nuttall, T., & Eisenschenk, M. N. C. (2015). Review: Lymphocytes, cytokines, chemokines and the T-helper 1-T-helper 2 balance in canine atopic dermatitis. *Veterinary Dermatology*, 26, 124-e32.
- Rodrigues-Hoffmann, A., Patterson, A. P., Diesel, A., Lawhon, S. D., Ly, H. J., Stephenson, C. E., Mansell, J., Steiner, J. M., Dowd, S. E., Olivry, T., & Suchodolski, J. S. (2014). The Skin Microbiome in Healthy and Allergic Dogs. *Plos One*, 9, e83197.
- Stefanovic, N., Irvine, A. D., & Flohr, C. (2021). The role of environment and exposome in atopic dermatitis. *Current Treatment Options in Allergy*, 8, 222-241.
- Spitznagel, M. B., Hillier, A., Gober, M., & Carlson, M. D. (2021). Treatment complexity and caregiver burden are linked in owners of dogs with allergic/atopic dermatitis. *Veterinary Dermatology*, v. 32, p. 192-e50.
- Wilhem, S., Kovalik M., & Favrot C. (2011). Breed-associated phenotypes in canine atopic dermatitis. *Veterinary Dermatology*, 22, 143-149.
- Wollenberg, A., Barbarot, S., Bieber, T., Christen-Zaech, S., Deleuran, M., Fink-Wagner, A., Gieler, U., Girolomoni, G., Lau, S., Muraro, A., Czarnecka-Operacz, M., Schafer, T., Schmid-Grandelmeier, P., Simon, D., Szalai, Z., Szepletowski, J. C., Taieb, A., Torrelo, A., Werfel, T., & Ring, J. (2018). Consensus-based European guidelines for treatment of atopic eczema (atopic dermatitis) in adults and children: part I. *Journal of the European Academy of Dermatology and Venereology*, 32, 657-682.