

Postmortem findings in non-human primates from Pernambuco, Brazil

Achados postmortem de primatas não-humanos em Pernambuco, Brasil

Hallazgos post mortem en primates no humanos de Pernambuco, Brasil

Received: 02/22/2022 | Reviewed: 03/04/2022 | Accept: 03/06/2022 | Published: 03/13/2022

Rômulo Freitas Francelino Dias

ORCID: <https://orcid.org/0000-0002-9887-8414>
Rural Federal University of Pernambuco, Brazil
E-mail: romuloffdias@gmail.com

Saulo Romero Felix Gonçalves

ORCID: <https://orcid.org/0000-0002-9254-4675>
Rural Federal University of Pernambuco, Brazil
E-mail: saulofelix.vet@gmail.com

Mariana Lumack do Monte Barretto

ORCID: <https://orcid.org/0000-0002-5454-3962>
Rural Federal University of Pernambuco, Brazil
E-mail: mariana.lumack@gmail.com

Pedro Paulo Feitosa de Albuquerque

ORCID: <https://orcid.org/0000-0002-6879-0876>
Rural Federal University of Pernambuco, Brazil
E-mail: ppfalbuquerque@gmail.com

Valdemiro Amaro da Silva Junior

ORCID: <https://orcid.org/0000-0002-1894-7337>
Rural Federal University of Pernambuco, Brazil
E-mail: valdemiroamaro@gmail.com

Mércia Rodrigues Barros

ORCID: <https://orcid.org/0000-0003-3449-9164>
Rural Federal University of Pernambuco, Brazil
E-mail: mercia.barros@ufrpe.br

Jaqueline Bianque Oliveira

ORCID: <https://orcid.org/0000-0002-6120-7895>
Rural Federal University of Pernambuco, Brazil
E-mail: bianque01@yahoo.com.br

Silvana Gomes Leal

ORCID: <https://orcid.org/0000-0002-1387-8790>
Pernambuco Health Department, Brazil
E-mail: silvanaleal383@gmail.com

Andrea Alive da Fonseca Oliveira

ORCID: <https://orcid.org/0000-0002-3728-177X>
Rural Federal University of Pernambuco, Brazil
E-mail: andreaafo@hotmail.com

Abstract

This study analyzed necropsy reports and photographic records of non-human primates from the Pathology Division of the Department of Veterinary Medicine at the Federal Rural University of Pernambuco (UFRPE), Brazil. Pathological data of 60 non-human primates (NHP) necropsied between January 2017 and December 2018 were analyzed based on the following criteria: city and zone (urban, peri-urban, and rural), origin (free-living and captivity), history and suspected clinical diagnosis, sex, species, age, corpse's conservation status, and macroscopic anatomopathological findings. The anatomopathological findings of viable necropsied animals (53.33%) were statistically analyzed for absolute and relative values. The primary causes of death were trauma injury (42%), parasitism (5%), pneumonia (3%), and fetal dystocia (3%). Trauma, possibly caused by anthropization, was the most prevalent cause of the primates' death. This conclusion presents an important differential diagnosis in primate death evolution during the epizootic period.

Keywords: Neotropical primates; Epizootic; Anatomopathological; Cause of death.

Resumo

Este estudo analisou laudos de necropsia e registros fotográficos de primatas não humanos da Divisão de Patologia do Departamento de Medicina Veterinária da Universidade Federal Rural de Pernambuco (UFRPE), Brasil. Os dados patológicos de 60 primatas não humanos (PNH) necropsiados entre janeiro de 2017 e dezembro de 2018 foram analisados com base nos seguintes critérios: cidade e zona (urbana, periurbana e rural), origem (livre e cativo),

história e suspeita de diagnóstico clínico, sexo, espécie, idade, estado de conservação do cadáver e achados anatomopatológicos macroscópicos. Os achados anatomopatológicos dos animais viáveis necropsiados (53,33%) foram analisados estatisticamente para valores absolutos e relativos. As principais causas de morte foram traumatismo (42%), parasitismo (5%), pneumonia (3%) e distocia fetal (3%). O trauma, possivelmente causado pela antropização, foi a causa mais prevalente da morte dos primatas. Esta conclusão apresenta um importante diagnóstico diferencial na evolução da morte de primatas durante o período epizootico.

Palavras-chave: Primatas neotropicais; Epizootia; Anatomopatológico; Causa de morte.

Resumen

Este estudio analizó laudos de necropsia y registros fotográficos de primatas no humanos de la División de Patología del Departamento de Medicina Veterinaria de la Universidad Federal Rural de Pernambuco (UFRPE), Brasil. Os dados patológicos de 60 primatas não humanos (PNH) necropsiados entre enero de 2017 y diciembre de 2018 foram analisados com base nos seguintes critérios: cidade e zona (urbana, periurbana e rural), origem (livre e cativo), história e suspeita de diagnóstico clínico, sexo, espécie, idade, estado de conservação del cadáver y achados anatomopatológicos macroscópicos. Os achados anatomopatológicos dos animais viáveis necropsiados (53,33%) foram analisados estadísticamente para valores absolutos y relativos. Como principales causas de muerte por traumatismo (42%), parasitismo (5%), neumonía (3%) y distocia fetal (3%). O trauma, possivelmente causado pela antropização, foi a causa mais prevalente da morte dos primatas. Esta conclusão presenta un importante diagnóstico diferencial de la evolución de la muerte de primatas durante el período epizootico.

Palabras clave: Primatas neotropicais; epizootia; anatomopatológico; causa de muerte.

1. Introduction

Primate studies are fundamental due to the phylogenetic, anatomical, physiological, and ethological similarities of non-human primates (NHP) to humans. These studies serve as a model that correlates with human conditions and provides valuable information on animal health, public health, and environmental surveillance. Brazil has the largest primate diversity globally, with 139 identified taxons (species and subspecies) and a taxonomic order that is continuously changing (Rylands, 2012; Silcox, 2007).

The etiology of NHP diseases can vary depending on whether the animals are free-living or captive. Due to better sanitary conditions, captive animals are less susceptible to some agents, although they can be exposed to others. Several infectious agents may cause disease in primates, such as the rabies virus, yellow fever virus, and human herpes simplex virus (Lopes et al., 2010). Studies have also shown that NHP have an essential role in public health as sentinel animals for yellow fever surveillance, aiding in disease prevention and control strategies (BRASIL, 2014). The few studies about descriptive necropsy findings on free-living NHP in Brazil describe either isolated or disease-specific cases (Oliveira et al., 2017; Laroque et al., 2014).

This study analyzed the main causes of death of NHP sent by the State Department of Health (SES) of Pernambuco, Brazil, to the Pathology Division from the Department of Veterinary Medicine at the Federal Rural University of Pernambuco (UFRPE).

2. Methodology

We performed a survey of NHP necropsies based on macroscopic reports and photographic records of the Pathology Division from the Department of Veterinary Medicine, UFRPE, Pernambuco, Brazil. We surveyed data regarding the origin, history, suspected clinical diagnosis, sex, species, age, corpse's conservation status, and anatomopathological findings of 60 NHP necropsied between January 2017 and December 2018. The data were stratified by the cities and regions where the corpses were found (urban, peri-urban, or rural), their origin (free-living or captive), sex, and species. The corpses were classified as viable or unfeasible (when presenting advanced autolysis and putrefaction). The NHP were divided into the following categories based on age: cub, young, and adult. The causes of death and descriptive necropsy findings were analyzed and characterized qualitatively. All macroscopic data, including repetitions, were considered. The absolute and relative

frequencies were evaluated using Microsoft Office® Excel 2007 software. The material collected and analyzed for yellow fever and rabies – through immunohistochemistry and direct immunofluorescence assays, respectively – was obtained according to a methodology described by the Ministry of Health (BRASIL, 2014).

This study did not collect, capture, or euthanize animals. Thus, it was exempt from submission to the UFRPE's institutional ethics committee, as determined by the ethical precept of the Normative Instruction No. 03, from September 1st, 2014, of the Brazilian Ministry of Environment (Silva et al., 2011). The data that supports this manuscript were obtained from the UFRPE Pathology Division's collection of necroscopic reports and images.

3. Results

The 60 necropsied primates were collected at the state of Pernambuco, Brazil, in 23 different cities : Caruaru (25%), Jaboatão dos Guararapes (6.7%), two cities accounting 10% each (Camaragibe and Recife), ten cities at 3.3% each (Arcoverde, Cabo de Santo Agostinho, Garanhuns, Igarassu, Itapissuma, Limoeiro, Olinda, Paulista, Sirinhaém and Timbaúba), and nine cities accounting for 1.7% each (Bezerros, Bonito, Feira Nova, Goiana, Itamaracá, Lagoa do Itaenga , Nazaré da Mata, São Caetano and Surubim). Of these, ten municipalities belong to Recife's metropolitan area (Camaragibe, Cabo de Santo Agostinho, Goiana, Jaboatão dos Guararapes, Igarassu, Itamaracá, Itapissuma, Olinda, Paulista, and Recife).

The reports did not specify the precise locations where the animals were found. However, we were able to classify the locations into rural (41.7%), urban (41.7%), and peri-urban (16.6%). Regarding the animals' origin, 59 (99.33%) were free-living, and only one animal (0.77%) was captive. The free-living primates' precedent history was unknown, and all of them were found dead. The captive animal reportedly presented a history of apathy, lethargy, and diarrhea. The suspected causes of death were yellow fever, rabies, or both, except for one possible poisoning case. In compliance with the protocol established by the Pernambuco SES, all NHP found dead and collected for the necroscopic examination were included in yellow fever and rabies surveillance.

The sex was not identified or reported for 22 (36.7%) of the 60 NHP. For the remaining 38 animals, 20 (33.30%) were male, and 18 (30%) were female. The approximate age documented showed 54 (90%) adults, 3 (5%) juveniles, and 3 (5%) cubs. Regarding species, 56 (93.34%) were *Callithrix jacchus*, two (3.34%) were *Saimiri* sp., one (1.66%) was *Sapajus libidinosus*, and one (1.66%) was *Sapajus flavius*.

The accounted causes of death were trauma injury (42%), parasitism (5%), pneumonia (3%), and fetal dystocia (3%) (Table 1).

Table 1. Distribution of causes of death in non-human primates in the state of Pernambuco, Brazil.

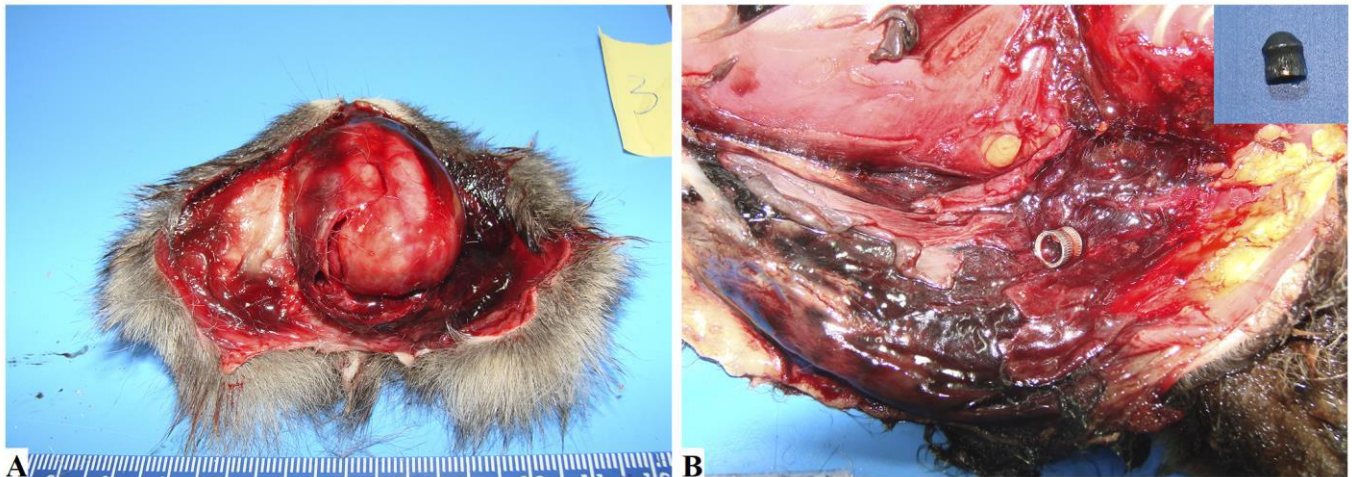
Diagnoses□	Absolute frequency□	Relative frequency (%)□
Injury-trauma□	25/60□	42.00□
Parasitism□	3/60□	5.00□
Pneumonia□	2/60□	3.00□
Fetal dystocia□	2/60□	3.00□
Inconclusive*□	28/60□	46.67□

*Advanced decay stage. Source: Authors.

Due to their advanced state of decomposition, 28 (47%) specimens had no conclusive diagnosis. All viable samples were submitted to the national reference laboratory (Evandro Chagas Institute, Belém, PA, Brazil) for yellow fever and rabies diagnosis, being negative for both. The most frequent anatomopathological findings – described for 32 (53.33%) viable animals

- were ecchymoses or subcutaneous hematomas (78.12%), rib or skull fracture (50%), edema or pulmonary congestion (35%), parasitic enteritis (15.62%), and pulmonary hemorrhage (12.5%) (Figure 1).

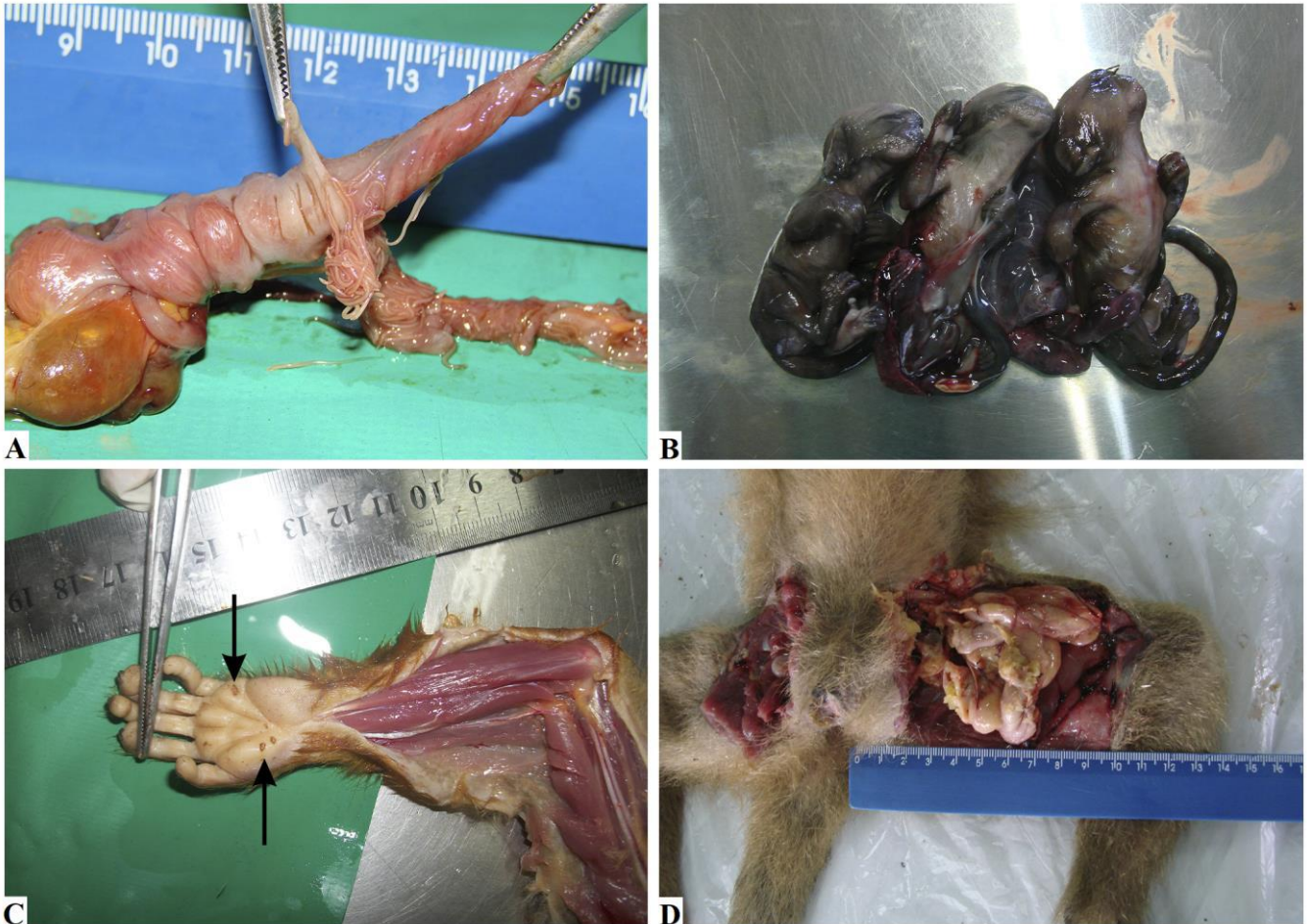Figure 1. Macroscopic view of blunt lesions in neotropical primates. **A)** Skull injury in *C. jacchus* with extensive left side occipital and parietal bone fractures. **B)** Ballistic projectile lesion in *C. jacchus* and blood collection throughout the left thoracic and abdominal region due to gunshot wound. Inset: Air gun ballistic projectile measuring approximately 0.4×0.6 cm.



Source: Authors.

According to the necropsy reports, the endoparasites identified at the UFRPE's Parasitology Laboratory were *Trypanoxyuris callithricis* and *Prosthenorchis elegans*. Other significant anatomopathological findings were fetal dystocia in two (6.25%) cases, and individual cases of gunshot injury, ocular proptosis, electrocution injury, gastric dilatation, traumatic diaphragmatic hernia, and traumatic femoral hernia (accounting for 3.12% each) (Figure 2 and Table 2).

Figure 2. Different macroscopic conditions in neotropical primates. **A)** Intussusception in the cecum of free-living *C. jacchus*. Visualization of the intussusception and samples of *Trypanoxyuris callithricis* after longitudinal sectioning of the intestinal loop. **B)** Visualization of three well-formed *C. jacchus* fetuses that caused maternal death by dystocia. **C)** Electrocution injury in *Saimiri* sp. with isolated left-hand circular lesions compatible with Jellinek's marks (arrows). **D)** Acquired femoral hernia in *Sapajus flavius*. Intestinal loop protrusion of the small intestine portion through the femoral canal and loop segment rupture.



Source: Authors.

Table 2. Frequency of anatomopathological findings in non-human primates in the state of Pernambuco, Brazil.

Anatomopathological findings	Absolute frequency	Relative frequency (%)
Ecchymoses and/or subcutaneous hematomas	25/32	78.12
Rib bone and/or skull fracture	16/32	50.00
Edema and/or pulmonary congestion	8/32	35.00
Parasitic enteritis	5/32	15.62
Pulmonary hemorrhage	4/32	12.50
Fetal dystocia	2/32	6.25
Gunshot wound injury	1/32	3.12
Ocular proptosis	1/32	3.12
Electrocution injury	1/32	3.12
Gastric dilatation	1/32	3.12
Traumatic diaphragmatic hernia	1/32	3.12
Traumatic femoral hernia	1/32	3.12

Source: Authors.

4. Discussion

This retrospective study investigated the leading causes of NHP death in Pernambuco, Brazil. Free-living NHP were the most prevalent in the necropsy survey. However, a significant number of the animals were unsuitable for proper macroscopic evaluation and sample collection due to their advanced state of decomposition, given most animals were found postmortem. Moreover, 13 of the 23 municipalities with reported NHP deaths are located outside of Recife's metropolitan region. Difficulty in access in some locations, low circulation of people in others, and the considerable distance between Recife and some municipalities are the main reasons for delayed necropsy examination. According to the employed protocol, primates should be necropsied up to eight hours post-death, after which corpse collection should only occur when the animal is not in an advanced state of decomposition (Brasil, 2014).

The significant amount of *C. jacchus* specimens (93.34%) may be associated with the successful adaptation of this species to urban centers, with food availability being an important factor for its prevalence (Leão et al., 2011). Although *Saimiri* sp. is considered an endemic primate of the Amazon region, some specimens seized during anti-trafficking operations were released into the Pernambuco Atlantic Forest, around the cities of Tamandaré and Rio Formoso (Maders, 2016).

NHP population surveys and necropsies were performed at the Federal University of Rio Grande do Sul (Porto Alegre, RS, Brazil), University of Sorocaba (Sorocaba, SP, Brazil), and at the Municipal Zoo Park *Quinzinho de Barros* (Sorocaba, SP, Brazil). These surveys demonstrated that the *Alouatta guariba clamitans* subspecies was the most prevalent, corresponding to 76.50 and 49.15%, respectively (Teixeira et al., 2018; Fragaszy et al., 2004). Thus, the biome influences species' distribution, given the neotropical primates found in the Brazil's Southern and Southeastern regions are different from those in the Northeastern region, where this study was carried out (Teixeira et al., 2018; Fragaszy et al., 2004).

Considering that primates are highly skilled at climbing trees, the lesions evidenced in this study may not be directly related to falls (wall, trees, roof) or territorial disputes (França, 2015; Rangol et al., 2013). Instead, they may be associated with pre-existing traumas due to anthropic action, given the injuries' location and severity (multiple complete fractures and abrasion wounds). However, there is no way to confirm this hypothesis.

It is noteworthy that *C. jacchus* is well-adapted to the urban and peri-urban environments, where natural predators are absent (Shkrum & Ransay, 2007). In their habitats, raptors and snakes are the main predators for Callitrichidae primates (Magalhães, 2005). However, we found no lesions that could suggest any form of predatory attack.

Our results showed that a sudden force may have produced the determining lesions for the animals' death. The multiple cranial fractures were characterized by their irregular orientation, and the bruises indicate that the direct force applied to the animal demonstrates continuity between external mechanical trauma and the internal tissue (Corrêa et al.; Ramos et al., 2016). From a medico-legal point of view, trauma is conceptualized as an unforeseen event beyond the victim's control, directly or indirectly threatening their physical and mental well-being (Amato, 2002).

Electrocution injuries should be carefully evaluated and identified through electrical marks and pulmonary, cardiac, and encephalic changes (Corrêa et al., 2016). The Jellinek's electrical mark, present in one of the analyzed cases, differs from an electrical burn, which was not detected in this study. This mark (Figure 2C) depicts the entrance of the electric current into the organism, while the burn represents the heat generated from the electric current's passage (Corrêa et al., 2016). In this case the most probable cause was the power lines.

In addition to NHP deaths attributed to trauma, other causes, such as parasitic diseases, are often concurrent. A large quantity of helminths infests neotropical primates, and these parasites are well-adapted to their hosts (Cogswell, 2007; Valença et al., 2000). However, some parasites are responsible for considerable infection and even fatal debilitation. Although *Trypanoxyuris* sp. may contribute to the death of *Alouatta guariba clamitans*, and rectal prolapse in free-living marmoset, this is the first report of *C. jacchus*' death by *T. callithricis*' parasitic intussusception (Marini, 2019; Oliveira et al., 2017; Auricchio, 1995). The cause of intussusception is generally unknown, but it can be associated with intestinal irritability and hypermotility caused by enteritis, an irritation caused by parasites or a foreign body (Verona & Pissinatte, 2014).

Trypanoxyuris callithricis and *Prosthenorchis elegans* were only identified in *C. jacchus*, although *P. elegans* was not related to the cause of death in the specimen. The occurrence of pathological injury by parasitism is less frequent in captive primates than in free-living due to the widespread use of anthelmintics in colonies (Lopes et al., 2010).

Gestational disorders are reported more often in captive animals, with unknown occurrence in free-living animals. However, in this study, two cases of death by fetal dystocia were observed in two free-living *C. jacchus*. In one case, the female had two disproportionately sized fetuses, and the uterus occupied the entire abdominal cavity, pressing the thoracic cavity through the diaphragm. In the second case of dystocia, triplet fetuses were present, which, although previously reported, is rare when compared to twin pregnancies (Teixeira et al., 2018; Verona & Pissinatte, 2014). Other factors that point to dystocia development include primiparous gestations, uterine atonia, fetal oversize, fetal death, and maternal exhaustion (Corrêa et al., 2016; França, 2015).

5. Conclusion

The results obtained in this work should support the conservation of neotropical NHP. Most of the studied NHP specimens were free-living adult *C. jacchus*, originating from the city of Caruaru (Pernambuco, Brazil). Males (33.30%) and females (30%) presented similar frequencies. The frequency of the corpse location was also similar for urban and rural areas. We infer that mechanical traumatic injuries, possibly caused by anthropization, have a significant impact on the conservation of primate populations in the State of Pernambuco, Brazil. Lastly, we reported the first case of *T. callithricis* parasitic intussusception in *C. jacchus*. We emphasize the need for further research and work aimed at the impact of man on the natural habitat of these non-human primates.

References

- Amato J. F. R. (2002). *Trypanoxyuris (Trypanoxyuris) minutus* associated with the death of a wild southern brown howler monkey *Alouatta guariba clamitans*, in Rio Grande do Sul, Brazil. *Arq Inst Biol São Paulo*, 69: 99-102.
- Auricchio P. (1995). Primatas do Brasil. In: *Primatas do Brasil*. Terra Brasilis, 57-60.
- Brasil M. S. (2014). *Guia de Vigilância de Epizootias em Primatas Não Humanos e Entomologia Aplicada à Vigilância da Febre Amarela*. (2nd ed.), (Brasil M da S, ed). Brasília: Ministério da Saúde.
- Cogswell F. (2007). Parasites of non-human primates. In: David G.B., ed. *Flynn's Parasites of Laboratory Animals*. (2nd ed.), Ames: Blackwell Publishing, 693-743.
- Corrêa P., Bueno C., Soares R., Vieira F.M. & Muniz-Pereira L.C. (2016). Checklist of helminth parasites of wild primates from Brazil. *Rev Mex Biodivers*, 87(3): 908-918.
- Ferrari S.F. & Beltrao-Mendes R. (2011). Do snakes represent the principal predatory threat to callitrichids? Fatal attack of a viper (*Bothrops leucurus*) on a common marmoset (*Callithrix jacchus*) in the Atlantic Forest of the Brazilian Northeast. *Primates*, 52(3): 207.
- Fragaszy D., Izar P., Visalberghi E., Ottoni E.B. & Oliveira M.G. (2004). Wild capuchin monkeys (*Cebus libidinosus*) use anvils and stone pounding tools. *Am J Primatol Off J Am Soc Primatol*, 64(4): 359-366.
- França G.V. (2015). Traumatologia Médico Legal. In: França GV de, ed. *Medicina Legal*. (10nd ed.), Guanabara Koogan, 95-222.
- Gelberg H.B. (2017). Alimentary system and the peritoneum, omentum, mesentery and peritoneal cavity. In: *Pathologic Basis of Veterinary Disease*. Elsevier, 324-411.
- ICMBio – Instituto Chico Mendes de Conservação da Biodiversidade. (2014). Instrução Normativa Nº 3, de 1 de setembro de 2014. *Publicação – Diário Of da União*. 2012. https://www.icmbio.gov.br/sisbio/images/stories/instrucoes_normativas/INSTRUÇÃO_NORMATIVA_ICMBio_Nº_3_DE_2014_com_retificação_do_DOU18062015.pdf.
- Laroque P. O., Valença-Montenegro M. M., Ferreira D. R. A., Chiang J. O., Cordeiro M. T., Vasconcelos P. F. C. & Silva J. C. R. (2014). Epidemiologic survey for arbovirus in Galician capuchin monkeys (*Cebus flavius*) free living in Paraíba and captive capuchin monkey (*Cebus libidinosus*) from Northeast Brazil. *Pesqui Veterinária Bras*, 34(5): 462-468.
- Leão T. C. C., Almeida W. R., Dechoum M. S. & Ziller S. R. (2011) Animais Exóticos Invasores. In: Leão, Tarciso Cotrim Carneiro; Almeida, Walkira Rejane de; Dechoum, Michele de Sá; Ziller SR, ed. *Espécies Exóticas Invasoras no Nordeste do Brasil. Contextualização, Manejo e Políticas Públicas. Recife: CEPAN*, 23-51.
- Lopes C. A. A., Cysne L. B., Andrade M. C. R. & Lisboa A. O. (2010). Agentes Infecciosos. In: Andrade A., Andrade M. C. R., Marinho A. M. & Filho J. F., eds. *Biologia Manejo e Medicina de Primatas Não Humanos na Pesquisa Biomédica*. FIOCRUZ, 207-258.
- Maders P. R. (2016). Estudo retrospectivo dos casos de primatas neotropicais atendidos no Preservas-UFRGS.
- Magalhães T. (2005). A vítima como objeto da intervenção médico-legal. *Acta Med Port*, 18: 453-458.
- Marini R. P. (2019). Diseases of the Urogenital System. In: Marini R.P., Wachtman L.M., Tardif S.D., Mansfield K. & Fox J.G., eds. *The Common Marmoset in Captivity and Biomedical Research*. San Diego: Academic Press, 195-212.
- Oliveira A. R., Hiura E., Guião-Leite F. L., Flecher M. C., Braga F. R., Silva L. P. C., Sena T. & Souza T. D. (2017). Pathological and parasitological characterization of *Prosthenocheilus elegans* in a free-ranging marmoset *Callithrix geoffroyi* from Brazilian Atlantic Forest. *Pesqui Veterinária Bras*, 37(12): 1514-1518.
- Ramos D. G. S., Santos A., Freitas L. C., Correa S. H. R., Kempe G. V., Morgado T. O., Aguiar D. M., Wolf R. W., Rossi R. V., Sinkoc A. L. & Pacheco R. C. (2016). Endoparasites of wild animals from three biomes in the State of Mato Grosso, Brazil. *Arq Bras Med Veterinária e Zootec*, 68(3): 571-578.
- Rangel C. H., Adler J. G. V., Heliodor G. C., Santos Jr A. & Verona C. E. (2013). Relato de caso de morte por agressão entre macacos prego *Sapajus nigritus (Primates: Cebidae)* no Jardim Botânico do Rio de Janeiro. *Neotrop Primates*, 20(1): 48-52.
- Rylands A. B., Mittermeier R. A. & Silva Jr J. S. (2012). Neotropical primates: taxonomy and recently described species and subspecies. *Int Zoo Yearb*, 46(1): 11-24.
- Shkrum M. J. & Ramsay D. A. (2007). Blunt Trauma. In: Shkrum MJ, Ramsay DA, eds. *Forensic Pathology of Trauma: Common Problems for the Pathologist*. Totowa: Humana Press, 405-518.
- Silcox M. T. (2007). Primate taxonomym plesiadapiforms, and approaches to primate origins. In: Ravosa M.J. & Dagosto M., eds. *Primate Origins: Adaptations and Evolution*. Springer, 143-178.
- Silva G. M. M., Veríssimo K. C. S. & Oliveira M. A. B. (2011). Orçamento das atividades diárias de dois grupos de *Callithrix jacchus* em área urbana. *Ver Etol*, 10(2): 57-63.
- Teixeira R. H. F., Buti T. E. M. & Costa A. L. M. (2018). Exames post mortem em primatas não humanos durante epizootia de febre amarela na região metropolitana de Sorocaba, SP, Brasil. *Clin Vet*, 32-42.
- Traad R. M. & Weckerlin P. (2012). Introdução das espécies exóticas *Callithrix penicillata* (Geoffroy, 1812) e *Callithrix jacchus* (Linnaeus, 1758) em ambientes urbanos (Primates: Callitrichidae). *Rev Meio Ambient e Sustentabilidade*, 2(1): 9-23.

Valença M. M., Oliveira J. B., Cruz M. A. O. M., Cavalcanti M. D. & Pinheiro de Sá M. E. (2000). *Trypanoxyuris (Hapaloxuyris) callithricis (Oxyurida, Oxyuridae)* in Wild *Callithrix jacchus* (Linnaeus, 1758), in Northeast Brazil. *Lab Primate Newsl*, 39(2): 4.

Verona C. E. & Pissinatti A. (2014). Primates: primatas do novo mundo (Sagui, Macaco-Prego, Macaco-Aranha, Bugio e Muriqui). In: Cubas Z.S., Silva J.C.R. & Catão-Dias J.L., eds. *Tratado de Animais Selvagens*. (2nd ed.), ROCA, 723-743.