

## Effects of COVID-19 on child neurodevelopment – An integrative review

Efeitos da COVID-19 no neurodesenvolvimento da criança – Uma revisão integrativa

Efectos del COVID-19 en el neurodesarrollo infantil – Una revisión integradora

Received: 03/14/2022 | Reviewed: 03/21/2022 | Accept: 03/26/2022 | Published: 04/03/2022

**Lucas Teixeira de Castro**

ORCID: <https://orcid.org/0000-0002-7287-4378>  
Universidade Federal do Triângulo Mineiro, Brazil  
E-mail: [lucascastro664@gmail.com](mailto:lucascastro664@gmail.com)

**Leticia Fernandes Teixeira**

ORCID: <https://orcid.org/0000-0002-1067-4864>  
Universidade Federal do Triângulo Mineiro, Brazil  
E-mail: [leticiafeteixeira81@gmail.com](mailto:leticiafeteixeira81@gmail.com)

**Giselda Tavares de Araújo**

ORCID: <https://orcid.org/0000-0002-5101-5750>  
Universidade Federal do Triângulo Mineiro, Brazil  
E-mail: [giseldatavares05@gmail.com](mailto:giseldatavares05@gmail.com)

**Elaine Leonezi Guimarães**

ORCID: <https://orcid.org/0000.0002-8450-1261>  
Universidade Federal do Triângulo Mineiro, Brazil  
E-mail: [elaine.guimaraes@uftm.edu.br](mailto:elaine.guimaraes@uftm.edu.br)

### Abstract

The effects of COVID-19 on children are still poorly understood. Considering the progressive increase in pediatric cases, we sought to gather evidence of the disease in children, to better understand its evolution, possible complications, and favor clinical practice. This is a review, whose search was carried out in the National Library of Medicine, Latin American & Caribbean Health Sciences Literature (LILACS), Medical Literature Analysis and Retrieval System Online, Virtual Health Library (BVS), PAHO and Cochrane Library. Eight articles were included, and the most common symptoms described were: cold-like symptoms, dry cough, respiratory difficulty, mild throat infection, loss of muscle strength, tonic and reflex changes in the lower limbs. However, there is still no clarity about the disease in children, requiring further research.

**Keywords:** COVID-19; SARS-CoV-2; Children; Neurodevelopment; Newborn; Review.

### Resumo

Os efeitos da COVID-19 na criança ainda são pouco conhecidos. Considerando o aumento progressivo de casos pediátricos, buscou-se reunir evidências da doença na criança, para entender melhor sua evolução, as possíveis complicações, e, favorecer a prática clínica. Trata-se de uma revisão, cuja busca foi realizada nas bases National Library of Medicine, Literatura Latino-Americana e do Caribe em Ciências da Saúde, Medical Literature Analysis and Retrieval System Online, Biblioteca Virtual em Saúde, PAHO e Cochrane Library. Oito artigos foram incluídos, e, os sintomas mais comuns descritos foram: resfriado, tosse seca, dificuldade respiratória, infecção de garganta leve, perda de força muscular, alteração tônica e de reflexos em membros inferiores. Contudo, ainda não há clareza sobre a doença na criança, necessitando mais pesquisas.

**Palavras-chave:** COVID-19; SARS-CoV-2; Crianças; Neurodesenvolvimento; Recém-nascido; Revisão.

### Resumen

Los efectos de COVID-19 en los niños aún no se conocen bien. Teniendo en cuenta el aumento progresivo de casos pediátricos, se buscó recopilar evidencias de la enfermedad en niños para conocer mejor su evolución, posibles complicaciones y favorecer la práctica clínica. Se trata de una revisión, cuya búsqueda se realizó en la Biblioteca Nacional de Medicina, Literatura Latinoamericana y del Caribe en Ciencias de la Salud, Sistema de Análisis y Recuperación de Literatura Médica en Línea, Biblioteca Virtual en Salud, OPS y Cochrane Library. Se incluyeron ocho artículos, y los síntomas más comunes descritos fueron: gripe, tos seca, dificultad respiratoria, infección leve de garganta, disminución de la fuerza muscular, cambios en el tono muscular y en los reflejos de las extremidades inferiores. Sin embargo, aún no hay claridad sobre la enfermedad en niños, lo que requiere más investigación.

**Palabras clave:** COVID-19; SARS-CoV-2; Niños; Neurodesarrollo; Recién nacido; Revision.

## 1. Introduction

Since 2020, the world has been facing serious difficulties due to the pandemic caused by the novel coronavirus (SARS-CoV-2), leading to Severe Acute Respiratory Syndrome 2 (Wang, et al., 2020). Most of those infected by the virus are asymptomatic or have mild symptoms, such as: dry cough, fever and tiredness, however, they can be aggravated by other factors, leading to respiratory problems, chest pain, loss of speech or movement (Iser, et al., 2020). It is known that the transmission of the virus occurs by inhalation or direct contact with infected droplets; however, there are still few studies on vertical contamination during pregnancy. Some evidence indicates that the disease in pregnant women may contribute to problems in the neurodevelopment of the baby (Martins-Filho & Tanajura, 2020).

Considering the process of development of the nervous system in children, the infectious and post-infectious mechanisms of COVID-19 can lead to neurological problems and compromise neurodevelopment (Lin, et al., 2021). Image analysis studies demonstrate an immune response to the virus, contributing to the severe course of the disease with harmful effects on the Central Nervous System (CNS) (Lindan, et al., 2021)).

The expansion of the pandemic increased the hospitalization of children in Intensive Care Units, demanding resources for their care (Pathak, et al., 2020). Some children with pre-existing comorbidities had respiratory symptoms, requiring invasive ventilation, and the involvement of two or more organ systems (Shekerdeman, et al., 2020). The development of syndromes with inflammatory patterns similar to Multisystem Inflammatory Syndrome, Kawasaki Syndrome and Guillain-Barré Syndrome has been observed in children positive for COVID-19, according to Uchiya (2020). Thus, it becomes necessary to investigate whether children infected with SARS-CoV-2 have neurological complications, since there is an increase in inflammatory reactions during the acute phase of the disease, causing a dysregulated response, and also to observe if COVID-19 can act as an activator for the Syndromes (Chen, 2020; Mccrindle, 2020).

The few studies indicate a variety of symptoms in children with COVID-19, the main ones being fever and respiratory symptoms. However, there are reports of symptoms related to the inflammatory syndrome, such as cardiac dysfunction, gastrointestinal symptoms, septic shock, liver and kidney dysfunction, different from the common symptoms presented in the virus infection (Uchiya, 2020; García-Salido, 2020). Encephalopathy has also been observed in infants and children with COVID-19, associated with symptoms such as axial hypotonia, drowsiness and groaning (Mendes, 2008). (Lin, et al., 2021).

Considering the importance of the topic in the current scenario of urgency in public health, the present study is justified given the need to understand the influence of COVID-19 on child neurodevelopment, understand its possible complications and contribute to evidence-based care.

## 2. Methodology

This is an integrative literature review, whose objective was to seek and analyze relevant and current research, with evidence for clinical practice and early intervention, seeking to contribute to the basis of decision-making (Ursi & Gavão, 2005; Mendes, et al., 2008).

Initially, the following question was defined for the study: “What is the influence of COVID-19 on child neurodevelopment?”. Then, the inclusion criteria for the selection of articles in the research were defined: experimental, quasi-experimental and non-experimental articles, which presented data on the effects of COVID-19 in children, published between 2019 and 2021, in Spanish, English or Portuguese, in journals with an impact factor greater than or equal to one. Studies that presented COVID-19 only in adults, study duplication in the databases, and those that did not meet the inclusion criteria were excluded. The descriptors chosen and used were “COVID-19”, “children”, “Sars-Cov-2”, “neurodevelopment” and “newborn”.

The selection of studies was carried out in the following databases: National Library of Medicine (PubMed), Latin

American & Caribbean Health Sciences Literature (LILACS), Medical Literature Analysis and Retrieval System Online (Medline), Virtual Health Library (BVS), PAHO and COCHRANE Library, following a set of combinations of descriptors to facilitate the location of studies.

From the descriptors, the following combinations were used: “covid-19” AND “Children”; “SARS-COV-2” AND “Children”; “COVID-19” AND “Children” AND “Neurodevelopment”; “COVID-19” AND “Newborn”; “SARS-COV-2” AND “Newborn”. In addition, manual searches and reference-based selection of selected studies were performed.

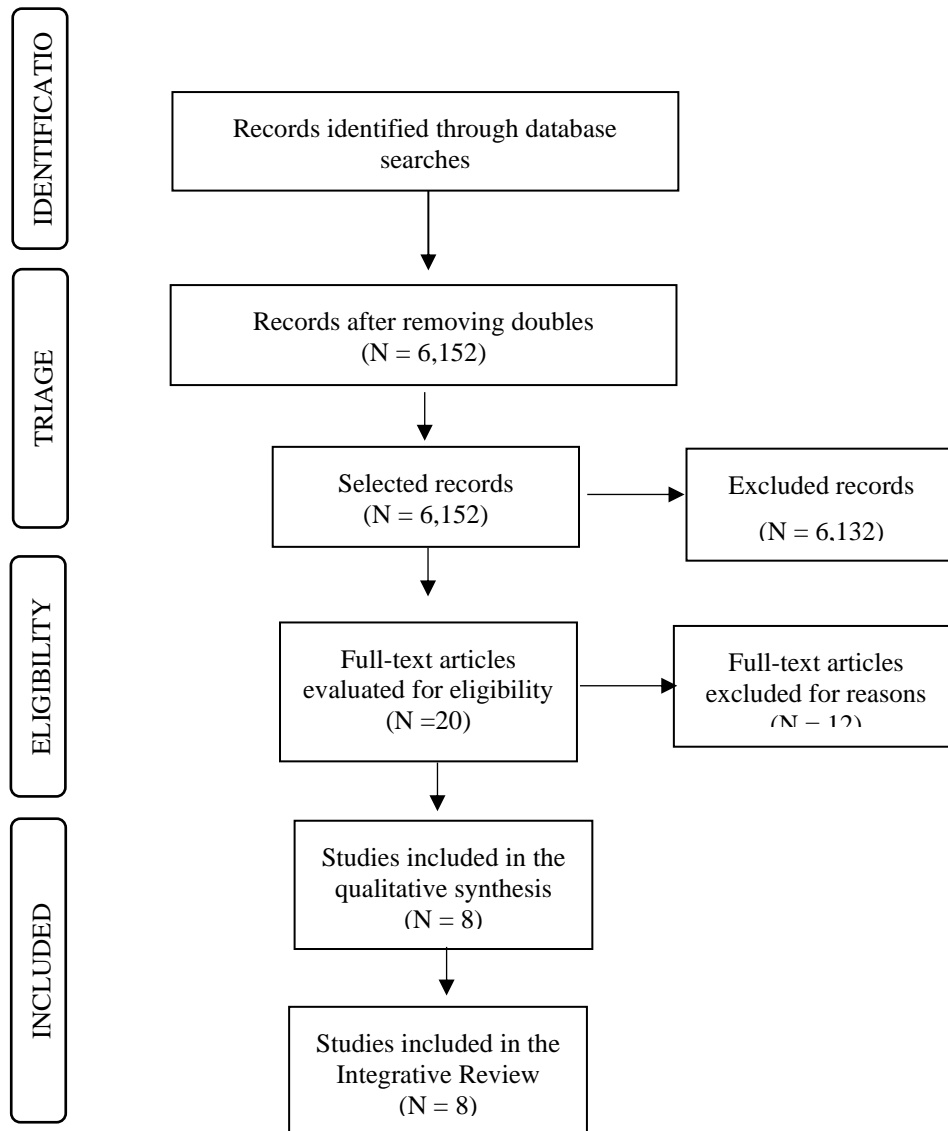
After searching the databases, the references were exported to the online application Rayyan QCRI of the Qatar Computing Research Institute, used by Ouzzani (2016), for the detection of duplicates and selection through title and abstract. The selection took place independently and blindly, carried out by two researchers and confirmed by two other researchers according to the eligibility criteria. Then, the full text was read for analysis of studies and confirmation of studies for review.

The methodological evaluation of the studies was performed using the Critical Review Form - Quantitative studies (Law et al., 1998), using the criteria: study objective, literature review, methodology adequacy, intervention, results, conclusions and clinical implications. If the article met the criteria for each item evaluated, a score of one was assigned; zero, when the criterion was not met; NA when the criterion was not applied to the research; the question mark symbol (?), when the item was not clearly described. Article with a score greater than or equal to 12 is considered low risk for bias; and less than or equal to 7 high risk for bias.

### **3. Results**

After reading and analyzing the articles, eight articles were included in the review. The initial search resulted in 22,284 articles, of which 16,132 were excluded after reading the titles and observing duplication in the databases. Of the remaining 6,152 studies, 6,132 articles were excluded because they did not answer the research question and/or did not meet the inclusion criteria. Thus, 20 studies were read in their entirety and discussed among the researchers, 4 of which were excluded because they were opinion pieces and editorials, 6 because they did not answer the proposed question, and 2 because the journals had a low impact factor.

**Figure 1.** Flowchart referring to the search and selection of studies included in the integrative review.



Source: Authors (2021).

Of the included studies, it was observed that two were developed in the USA, one in Saudi Arabia, one in the United Kingdom, one in Spain, one in England, one in Chile and one in Mexico, all published in journals with an impact factor above 1. Table 1 presents the identification of articles, considering title, author, study location, journal and impact factor.

**Table 1.** Identification of selected articles.

<b>Title</b>	<b>Author</b>	<b>Study location</b>	<b>Journal/ Impact factor</b>
Guillain-Barré Syndrome Associated With Severe Acute Respiratory Syndrome Coronavirus 2 Detection and Coronavirus Disease 2019 in a Child (17)	Khalifa, et al. (2020)	Saudi Arabia	Journal of the Pediatric Infectious Diseases Society/ 2.21
Neurological issues in children with COVID-19 (20)	Lin, et al. (2021)	USA	Neuroscience Letters/ 2.27
Neuroimaging manifestations in children with SARS-CoV-2 infection: a multinational, multicentre collaborative study (22)	Lindan, et al. (2021)	UK	The Lancet Child & Adolescent Health/ 8.84
COVID-19: Neurological Considerations in Neonates and Children (23)	Stafstrom; Jantzie (2020)	USA	Children/ 2.85
Neurologic Care of COVID-19 in Children (24)	Boronat (2020)	Spain	Frontiers in Neurology/ 2.88
Neurologic and Radiographic Findings Associated With COVID-19 Infection in Children (25)	Abdel-Mannan, et al. (2020)	England	JAMA Neurology/ 18.302
Neurologic Features Associated With SARS-CoV-2 Infection in Children: A Case Series Report (21)	Sandoval, et al. (2020)	Chile	Journal of Child Neurology/ 1.98
Neurological manifestations temporally associated with SARS-CoV-2 infection in pediatric patients in Mexico (26)	Sánchez-Morales, et al. (2021)	Mexico	Child's Nervous System/ 1.47

Source: Authors (2021).

Regarding the design of the studies, two were narrative reviews, one case report, three case series studies, one descriptive study, and one international multicenter clinical trial. The common results observed in the articles were the neurological effects of the disease in children, in which six addressed Guillain-Barré Syndrome, five the Multisystem Inflammatory Syndrome, and six compared some symptoms with Kawasaki Syndrome (Table 2).

**Table 2.** Presentation of the synthesis of articles included in the integrative review.

Title	Objective	Study Design	Population/Study characteristics	Results
Guillain-Barré Syndrome Associated With Severe Acute Respiratory Syndrome Coronavirus 2 Detection and Coronavirus Disease 2019 in a Child (17)	To present a case with an association of infection between Guillain-Barré Syndrome and SARS-CoV-2 in children.	Case report	An 11-year-old boy who presented a typical clinical picture of Guillain-Barré Syndrome, and, after 5 days, a morbilliform rash on the palms of the hands and a confirmed diagnosis of SARS-CoV-2 infection.	A possible association of COVID-19 with Guillain-Barré Syndrome was verified. Cold-like symptoms and throat infection with mild fever were initially observed. It evolved to loss of muscle strength, tonic, sensitivity and reflex alterations in the lower limbs. Two days after the onset of neurological symptoms, he tested positive for COVID-19. He remained hospitalized for 14 days, and, at discharge, there was an improvement in respiratory function, muscle strength, with balanced gait, and decreased numbness. Thus, neuromuscular changes in children can be considered a clinical picture of COVID-19.
Neurological issues in children with COVID-19 (20)	To present neurological conditions and their implications in children diagnosed with COVID-19.	Descriptive study	We analyzed 82 medical records of children aged 5 to 18 years, median age 9 years, confirmed for COVID-19, at the New York-Presbyterian Morgan Stanley Children's Hospital, who presented neurological alterations during and after the hospitalization period.	The presence of several central and peripheral neurological alterations was observed, ranging from mild symptoms, such as headache and anosmia, to severe manifestations such as stroke, seizures and encephalopathy, characterizing a possible clinical picture of COVID-19. Considering the ongoing development of the child's nervous system, with differential expression of cellular receptor targets over time, it is possible that windows of susceptibility to various infectious diseases and post-infectious mechanisms of COVID-19-related neurological injury exist.
Neuroimaging manifestations in children with SARS-CoV-2 infection: a multinational, multicentre collaborative study (22)	Identify cases to better understand the manifestations of COVID-19 in the pediatric population through the analysis of neuroimaging exams.	International Multicenter Clinical Trial	Thirty-eight children participated in the study, 13 from France, 8 from the UK, 5 from the USA, 4 from Brazil, 4 from Argentina, 2 from India, 1 from Peru and 1 from Saudi Arabia. The children presented with encephalopathy related to SARS-CoV-2 severe acute respiratory syndrome infection, and abnormal neuroimaging findings. Clinical history and associated plasma and cerebrospinal fluid data were observed.	Acute and late phase SARS-CoV-2-related central nervous system abnormalities and recurrent disease patterns and atypical neuroimaging manifestations were found. Cerebral manifestations were most commonly similar to acute disseminated encephalomyelitis, with irregular or confluent areas of T2 hyperintensity in the gray and white matter, with or without reduced diffusion or enhancement, the exact pathophysiology of which remains to be clarified. Neuritis in cranial and spinal or cauda equina nerves. The taste and smell dysfunction described in adults with COVID-19 has also been observed in children.

COVID-19: Neurological Considerations in Neonates and Children (23)	To discuss the data described in the literature on COVID-19 infection in neonates and children, and to relate possible neurological involvement with development in COVID-19 positive children.	Narrative review	Initially, 34,310 studies with the descriptor COVID-19 were found in the PubMed database. Of these, 10 articles were included in the present study, indicating a paucity of studies relating COVID-19 and children.	The association of COVID-19 with multisystem inflammatory syndrome (MIS-C) manifests itself with the presence of neurological symptoms such as encephalopathy, headaches, weakness, ataxia, causing impacts on the immature central nervous system and the developing immune system, can cause long-term problems in the child's development. The observed data show that symptoms are less frequent, and generally less severe, in children, especially newborns.
Neurologic Care of COVID-19 in Children (24)	To review aspects of neurological involvement in COVID-19 positive children. And discuss the impact of COVID-19 on the health system in some countries	Narrative review	Clinical findings obtained in published studies were narrated, observing the involvement and neurological manifestations in children positive for COVID-19	From the point of view of the child's involvement, it was observed that the multisystem inflammatory syndrome caused by COVID-19 presents greater risks of neurological complications. Among these, encephalopathy was the most frequent and may be related to other manifestations such as weakness, seizures and mild neuropathies. In addition, other abnormalities such as hyposmia and hypogeusia, muscle involvement, and the inflammatory Guillain-Barré Syndrome may be present.
Neurologic and Radiographic Findings Associated With COVID-19 Infection in Children (25)	To report the neurological manifestations in children positive for SARS-CoV-2	Case series	Four children were followed up who showed confirmation of SARS-CoV-2 infection in a polymerase chain reaction test, and a positive test for IgG, in addition to neurological symptoms.	In the follow-up cases, the presence of encephalopathy, headache, dysarthria, dysphagia, meningitis, cerebellar ataxia, muscle weakness and reduced reflexes were observed. As systemic manifestations, fever, cardiovascular shock, skin rashes and dyspnea were observed. Patients required, on average, 6.5 days of hospitalization in the intensive care unit for the treatment of the pediatric multisystem inflammatory syndrome related to COVID-19. Neurological improvement was observed in all patients, after 18 days of hospitalization, two were discharged, and the other two remained hospitalized.
Neurologic Features Associated With SARS-CoV-2 Infection in Children: A Case Series Report (21)	To describe the neurological manifestations in children positive for COVID-19	Case series	In a cohort of 90 patients under 18 years of age diagnosed with COVID-19, 13 children were found, aged between 15 months and 17 years and a median age of 6.5 years.	Central and peripheral nervous system symptoms were seen in 7 of the 13 children. The most relevant neurological manifestations observed were encephalopathy, seizures and muscle weakness, corroborating previously published data. Laboratory results showed elevation of inflammatory markers  The cohort showed fewer cases of hypogeusia and hyposmia and no acute disseminated encephalomyelitis or vascular events when compared to adult studies. And, some cases showed alterations compatible with Guillain-Barré Syndrome and demyelinating diseases.
Neurological manifestations temporally associated with SARS-CoV-2 infection in pediatric patients in Mexico (26)	To describe the neurological manifestations associated with COVID-19 in the pediatric population.	Case series	23 patients with neurological symptoms, including 10 patients with a mean age of 11.8 years, who met the clinical criteria for suspected SARS-CoV-2 infection, and who had neurological symptoms.	Despite scant evidence in children, the neurological effects appear to be increasing. The main reported cases are in older children and adolescents. Guillain-Barré Syndrome had a higher prevalence associated with COVID-19 among other inflammatory diseases. Data indicate that SARS-CoV-2 infection in children increased the incidence of neurological symptoms. However, little is known about the mechanisms and evolution of SARS-CoV-2 infection in children and its neurological effects.

Source: Authors (2021).

The evaluation of selected articles using the Critical Review Form - Quantitative Studies, indicated good quality of studies, with low risk of bias (Chart 1).

**Chart 1.** Qualitative evaluation of articles found on COVID-19 in children using the Critical Review Form – Quantitative Studies.

Authors	Questions																Total
	1	2	3	4	5	6	7	8	9	10	11	12	13	14	15	16	
Khalifa, et al., 2020	1	1	1	0	1	1	0	0	0	1	1	1	1	1	1	0	11
Lin, et al., 2021	1	1	1	0	1	1	0	1	1	1	1	1	1	1	1	1	14
Lindan, et al., 2021	1	1	1	0	1	1	1	1	1	1	1	1	1	1	1	1	15
Stafstrom; Jantzie, 2020	1	1	1	0	NA	NA	NA	1	1	NA	0	1	1	1	1	1	10
Boronat, 2020	1	1	1	0	NA	NA	NA	1	1	NA	1	1	1	1	1	1	11
Abdel-Mannan, et al., 2020	1	1	1	0	0	1	1	1	1	0	1	1	1	1	1	1	13
Sandoval, et al., 2020	1	1	1	0	1	1	1	1	1	1	1	1	1	1	1	1	15
Sánchez-Morales, et al., 2021	1	1	1	0	1	1	0	1	1	1	0	1	1	1	1	1	13

Legend: 1 = was the objective clear?; 2 = was a review of the relevant literature on this topic carried out?; 3 = was the design adequate for the study question?; 4 = was there any errors that may have influenced the results of the study?; 5 = was the sample described in detail?; 6 = was there a justification for the sample size?; 7 = did the subjects sign the consent form? (if not described, assume not); 8 = were the outcome measures reliable? (if not described, assume not); 9 = were the outcome measures valid? (if not described, assume not); 10 = was the intervention described in detail?; 11 = were the results reported in terms of statistical significance?; 12 = were the analysis methods adequate?; 13 = was clinical importance reported?; 14 = were the conclusions consistent with the study methods and results? 15 = Are there implications for clinical practice given the research results? 16 = were the study limitations recognized and described by the authors?

Item scores: 0 = does not meet the criterion; 1 = met the criterion; ? = not clearly described; NA = not applicable. Scores greater than 12 indicate low bias, and scores lower than 7 indicate high bias.

Source: Authors (2021).

## 4. Discussion

The present study aimed to gather evidence on the effect of COVID-19 on children, in order to understand the course of the disease and the possible complications in motor neurodevelopment, through an integrative literature review, which allows a broad approach to the topic, through experimental and non-experimental studies (Gallo, et al., 2020). The studies found indicate that despite the potential multisystem involvement caused by COVID-19, many complications are still a major challenge for health professionals.

The case study published by Khalifa, et al. (2020) of an 11-year-old child infected with SARS-CoV-2, has findings on lung CT scan indicating mild symptomatic respiratory disease in addition to low-grade fever and moderate, persistent dry cough. After three weeks, the child evolved with loss of muscle strength, tonic and reflex changes in the lower limbs, clinical signs suggestive of Guillain-Barré Syndrome (GBS), later confirmed by magnetic resonance imaging, which showed thickening of the nerve roots of the cauda equina. According to the authors, neuromuscular signs in children may be a directional factor for early detection of infection, with a possible association between Guillain-Barré Syndrome and SARS-CoV-2. However, the study of one case limits the confirmation of the relationship, and randomized studies are needed to better understand the association between the diseases. Guillain-Barré Syndrome (GBS) is considered a rare syndrome with low frequency in the child population, however, it has an important influence on children's neurodevelopment, since the neurological and musculoskeletal impairment caused by GBS is currently the main cause of acute and subacute flaccid paralysis (Gallo, et al., 2020). The results observed in



this study corroborate the data observed in the study by Frank, et al. (2021) with a 15-year-old patient, positive for COVID-19, presenting several clinical signs of Guillain-Barré Syndrome, and also diagnosed with the syndrome. The authors emphasize that the evidence on the infection caused by Sars-Cov-2 is not limited only to the involvement of the respiratory tract, but also to the neurological manifestations resulting from the neurotropism of the virus. However, studies with randomized clinical trials are still needed to understand the possible relationship between Guillain-Barré Syndrome and COVID-19 in children.

In the study by Lin, et al. (2021) the probable mechanisms of neurological damage caused by COVID-19 in children are observed, such as endothelial damage, which can cause thrombotic events, release of cytokines due to the infectious process, neurological sequelae, and post-COVID inflammation, which can lead to autoimmune conditions such as demyelinating disease and encephalopathy. In this study, they also found that, although respiratory symptoms and multisystem inflammatory syndrome are predominant in the literature, neurological conditions are present during and after the hospitalization period for COVID-19, corroborating the report by Khalifa, et al. (2020) and Frank, et al. (2021).

In the case study by Sandoval (2020), with 90 children, 13 had neurological manifestations associated with the infection, five of them with predominant involvement of the central nervous system, manifesting symptoms such as fever, encephalopathy, headache, blurred vision, seizures and diseases. demyelinating, and eight had manifestations of the peripheral nervous system, with a clinical picture of muscle weakness and symptoms of GBS. This denotes how the child's immature nervous system is susceptible to the various mechanisms of neurological injury, which can cause changes in child neurodevelopment, and this can worsen with COVID-19. It is worth mentioning that the study was not a population-based analysis, the selection of cases was restricted to hospitalized patients, and therefore there may be mild neurological manifestations that were not reported. Thus, the importance of clinical and prospective studies is noted, to confirm the observations and to assess the neurological and functional impact of the infection in children.

The multicenter clinical trial by Lindan, et al. (2021) analyzed neuroimaging exams of children contaminated by Sars-CoV-2, who had post-COVID-19 encephalopathy. In 38 children from different countries, recurrent features were observed, with encephalomyelitis (16 patients), myelitis (8 patients), splenic lesions (7 patients), myositis (4 patients), neuritis (12 patients) and 7 children had findings that could be characterized as thromboembolic. Thus, recognizing neuroimaging patterns in children with COVID-19 is important for the identification of neurological abnormalities, and for the early follow-up of multisystem disease caused by SARS-CoV-2.

Although the manifestations in newborns and children affected by COVID-19 are yet to be fully understood, the possible neurological effects have been increasingly described in the scientific literature. There are indications that immunological factors may justify the lower involvement of children, as well as the lower evolution to severe cases, however, symptoms such as encephalopathy, headaches and inflammatory lesions of the central nervous system, such as Multisystem Inflammatory Syndrome and inflammatory patterns that resembling Kawasaki disease are frequently reported, as presented and discussed in the studies by Stafstrom and Jantzie (2020) and Boronat (2020).

In the case series study with four children, median age of 12 years, positive for COVID-19 and neurological symptoms, according to Abdel-Mannan, et al. (2020), all showed signs of alteration in the splenium of the corpus callosum, detected in the examination of neuroimaging, and were admitted to the Intensive Care Unit for the treatment of Multisystem Inflammatory Syndrome. Neuroimaging findings indicate that children who are positive for COVID-19 may present neurological symptoms involving the central and peripheral nervous system, such as splenic changes in the image, even without respiratory symptoms, and should be followed up. Such findings corroborate those also observed in the study by Sánchez-Morales, et al. (2021), a case series with 10 children, mean age 11.8 years, diagnosed with COVID-19, who presented early onset neurological symptoms, between a few hours and two weeks after diagnosis, demyelinating diseases, encephalitis and GBS cases. However, considering

the size of the population of the studies, there are still limitations for inferences, and further research is needed to observe and identify the mechanism of infection of the disease and its possible complications.

In view of the findings, it is possible to believe that children with COVID-19 may present clinical manifestations, including neurological manifestations, similar to Multisystem Inflammatory Syndrome, Guillain-Barré and Kawasaki Syndrome. However, it is not yet known for sure which mechanisms are triggered by the virus in children, especially younger ones.

Based on the studies included in the review, it is observed that in addition to the scarcity of studies with children and the absence of studies with infants, the few found discuss their findings with those found in affected adults, which may not be so reliable considering the different neurophysiological and maturational processes in children. Despite being scarce, studies indicate possible clinical conditions related to neurodevelopment, still with inconclusive evidence on the course of the disease and the effective complications in the short, medium and long term in the child, which reinforces the importance of a multidisciplinary follow-up and the need of further research.

## 5. Conclusion

The study, although with limitations, allowed to gather evidence about the manifestations of COVID-19 in children, and indicate some effects on motor neurodevelopment, allowing a direction for the understanding of the clinical and functional aspects of important neurological complications, in some children infected by SARS-CoV-2. However, there is still no clarity about the course of the disease and its complications in this specific population, especially in infants. This reinforces the need for continuous monitoring of children infected with the virus, with or without manifestations, the importance of constant testing, and the continuity of research, for a better understanding and scientific support for the clinical practice of health teams, allowing care evidence based.

## Acknowledgments

The authors would like to thank the Nucleus of Studies in Motor Neurodevelopment and Early Intervention at the Federal University of Triângulo Mineiro – NENEIP/UFTM, and the Scientific Initiation Program at the Federal University of Triângulo Mineiro for their support.

## References

- Abdel-Mannan, O., Hacohen, Y., Eyre, M., Löbel, U., Bamford, A., Eltze, C., Hameed, B., & Hemingway, C. (2020). Neurologic and Radiographic Findings Associated With COVID-19 Infection in Children. *JAMA Neurology*, 77(11), 1440–1445. <https://doi.org/10.1001/JAMANEUROL.2020.2687>
- Boronat, S. (2021). Neurologic Care of COVID-19 in Children. *Frontiers in Neurology*, 11. <https://doi.org/10.3389/FNEUR.2020.613832>
- Chen, T. H. (2020). Neurological involvement associated with COVID-19 infection in children. In *Journal of the Neurological Sciences* (Vol. 418, p. 117096). Elsevier B.V. <https://doi.org/10.1016/j.jns.2020.117096>
- Frank, C. H. M., Almeida, T. V. R., Marques, E. A., De Sousa Monteiro, Q., Feitoza, P. V. S., Borba, M. G. S., Vasconcelos, H. L., De Souza Bastos, M. & Lacerda, M. V. G. (2021). Guillain-Barré Syndrome Associated with SARS-CoV-2 Infection in a Pediatric Patient. *Journal of Tropical Pediatrics*, 67(3). <https://doi.org/10.1093/TROPEJ/FMAA0447>
- Gallo, L. G., De Moraes Oliveira, A., De Matos, L. M., Abrahão, A. A., De Assis Silva, F., Mendes, J. P., Pereira, C. M., Franco Molinari, A. S. & Maciel, E. P. (2020). A case report on rapid clinical recovery and satisfactory outcome of a toddler with probable Guillain-Barré Syndrome. *Journal of Human Growth and Development*, 30(3), 472–479. <https://doi.org/10.7322/JHGD.V30.11116>
- García-Salido, A., De Carlos Vicente, J. C., Belda Hofheina, S., Ramírez, J., Slöcker Barrio, M., Leóz Gordillo, I., ... González Cortés, R. (2020). Severe manifestations of SARS-CoV-2 in children and adolescents: from COVID-19 pneumonia to multisystem inflammatory syndrome: a multicentre study in pediatric intensive care units in Spain. *Critical Care (London, England)*, 24(1), 666. <https://doi.org/10.1186/S13054-020-03332-4>
- Iser, B. P. M., Sliva, I., Raymundo, V. T., Poletto, M. B., Schuelter-Trevisol, F. & Bobinski, F. (2020). Definição de caso suspeito da COVID-19: uma revisão narrativa dos sinais e sintomas mais frequentes entre os casos confirmados. *Epidemiologia e Serviços de Saúde*, 29(3), e2020233. <https://doi.org/10.5123/S1679-49742020000300018>

- Khalifa, M., Zakaria, F., Ragab, Y., Saad, A., Bamaga, A., Emad, Y. & Rasker, J. J. (2020). Guillain-Barré Syndrome Associated With Severe Acute Respiratory Syndrome Coronavirus 2 Detection and Coronavirus Disease 2019 in a Child. *Journal of the Pediatric Infectious Diseases Society*, 9(4), 510–513. <https://doi.org/10.1093/JPIDS/PIAA086>
- Lindan, C. E., Mankad, K., Ram, D., Kociolek, L. K., Silvera, V. M., Boddaert, N.,... Vézina, G (2021). Neuroimaging manifestations in children with SARS-CoV-2 infection: a multinational, multicentre collaborative study. *The Lancet Child and Adolescent Health*, 5(3), 167–177. [https://doi.org/10.1016/S2352-4642\(20\)30362-X](https://doi.org/10.1016/S2352-4642(20)30362-X)
- Lin, J. E., Asfour, A., Sewell, T. B., Hooe, B., Pryce, P., Earley, C.,... & Geneslaw, A. S. (2021). Neurological issues in children with COVID-19. *Neuroscience Letters*, 743, 135567. <https://doi.org/10.1016/j.neulet.2020.135567>
- Martins-Filho, P. R., Tanajura, D. M., Santos, H. P. & Santos, V. S. (2020). COVID-19 during pregnancy: Potential risk for neurodevelopmental disorders in neonates? *European Journal of Obstetrics, Gynecology, and Reproductive Biology*, 250, 255. <https://doi.org/10.1016/J.EJOGRB.2020.05.015>
- McCrinkle, B. W. & Manlhiot, C. (2020). SARS-CoV-2–Related Inflammatory Multisystem Syndrome in Children: Different or Shared Etiology and Pathophysiology as Kawasaki Disease? *JAMA*, 324(3), 246–248. <https://doi.org/10.1001/JAMA.2020.10370>
- Mendes, K. D. S., Silveira, R. C. C. P., & Galvão, C. M. (2008). Revisão integrativa: método de pesquisa para a incorporação de evidências na saúde e na enfermagem. *Texto & Contexto - Enfermagem*, 17(4), 758–764. <https://doi.org/10.1590/S0104-07072008000400018>
- Ouzzani, M., Hammady, H., Fedorowicz, Z., & Elmagarmid, A. (2016). Rayyan-a web and mobile app for systematic reviews. *Systematic Reviews*, 5(1), 1–10. <https://doi.org/10.1186/S13643-016-0384-4/FIGURES/6>
- Pathak, E. B., Salemi, J. L., Sobers, N., Menard, J., & Hambleton, I. R. (2020). COVID-19 in Children in the United States: Intensive Care Admissions, Estimated Total Infected, and Projected Numbers of Severe Pediatric Cases in 2020. *Journal of Public Health Management and Practice*, 26(4), 325–333. <https://doi.org/10.1097/PHH.0000000000001190>
- Sánchez-Morales, A. E., Urrutia-Osorio, M., Camacho-Mendoza, E., Rosales-Pedraza, G., Dávila-Maldonado, L., González-Duarte, A., Herrera-Mora, P., & Ruiz-García, M. (2021). Neurological manifestations temporally associated with SARS-CoV-2 infection in pediatric patients in Mexico. *Child's Nervous System: ChNS: Official Journal of the International Society for Pediatric Neurosurgery*, 37(7), 2305–2312. <https://doi.org/10.1007/S00381-021-05104-Z>
- Sandoval, F., Julio, K., Méndez, G., Valderas, C., Echeverría, A. C., Perinetti, M. J.,... & Izquierdo, G. (2021). Neurologic Features Associated With SARS-CoV-2 Infection in Children: A Case Series Report. *Journal of Child Neurology*, 36(10), 853–866. <https://doi.org/10.1177/0883073821989164>
- Shekerdemian, L. S., Mahmood, N. R., Wolfe, K. K., Riggs, B. J., Ross, C. E., McKiernan, C. A.,... & Burns, JP (2020). Characteristics and Outcomes of Children With Coronavirus Disease 2019 (COVID-19) Infection Admitted to US and Canadian Pediatric Intensive Care Units. *JAMA Pediatrics*, 174(9), 868–873. <https://doi.org/10.1001/JAMAPEDIATRICS.2020.1948>
- Souza, M. T., Silva, M. D., & Carvalho, R. (2010). Integrative review: what is it? How to do it? *Einstein (São Paulo)*, 8(1), 102–106. <https://doi.org/10.1590/S1679-45082010RW1134>
- Stafstrom, C. E., & Jantzie, L. L. (2020). COVID-19: Neurological Considerations in Neonates and Children. *Children (Basel, Switzerland)*, 7(9). <https://doi.org/10.3390/CHILDREN7090133>
- Uchiya, E. H. (2020). Síndrome Inflamatória Pediátrica Multissistêmica (PIMS) e a associação com a SARS-CoV-2. *Temas em Educação e Saúde*, 16(1), 9–20. <https://doi.org/10.26673/TES.V16I1.13759>
- Ursi, E. S., & Galvão, C. M. (2006). Prevenção de lesões de pele no perioperatório: revisão integrativa da literatura. *Revista Latino Americana de Enfermagem*, 14(1), 124-31. <https://doi.org/10.1590/S0104-11692006000100017>
- Wang, Y., Zhu, F., Wang, C., Wu, J., Liu, J., Chen, X.,... & Sun, D. (2020). Children Hospitalized with Severe COVID-19 in Wuhan. *The Pediatric Infectious Disease Journal*, 39(7), E91–E94. <https://doi.org/10.1097/INF.0000000000002739>