

Evaluation of postoperative pain after endodontic treatment under irrigation with 2.5% or 5.25% Sodium Hypochlorite

Avaliação da dor pós-operatória após tratamento endodôntico sob irrigação com Hipoclorito de Sódio a 2.5% ou 5.25%

Evaluación del dolor postoperatorio tras un tratamiento endodóntico bajo irrigación con hipoclorito de sodio al 2,5% o al 5,25%

Received: 04/30/2022 | Reviewed: 05/08/2022 | Accept: 05/13/2022 | Published: 05/19/2022

Gardênia Souza Santos Rodrigues

ORCID: <https://orcid.org/0000-0002-8921-6080>
Faculdade São Leopoldo Mandic, Brazil
E-mail: gardeniaibotirama@gmail.com

Carlos Eduardo da Silveira Bueno

ORCID: <https://orcid.org/0000-0002-2675-0884>
Faculdade São Leopoldo Mandic, Brazil
E-mail: carlosesbueno@terra.com.br

Alexandre Sigrist De Martin

ORCID: <https://orcid.org/0000-0002-3320-9172>
Faculdade São Leopoldo Mandic, Brazil
Email: a-sigrist@uol.com.br

Carlos Eduardo Fontana

ORCID: <https://orcid.org/0000-0002-2868-6839>
Pontificia Universidade Católica de Campinas, Brazil
E-mail: ceffontana@hotmail.com

Sérgio Luiz Pinheiro

ORCID: <https://orcid.org/0000-0001-7157-4923>
Pontificia Universidade Católica de Campinas, Brazil
E-mail: slpinho@hotmail.com

Rina Andrea Pelegrine

ORCID: <https://orcid.org/0000-0003-4175-2121>
Faculdade São Leopoldo Mandic, Brazil
E-mail: rinapelegrine@terra.com.br

Daniel Guimarães Pedro Rocha

ORCID: <https://orcid.org/0000-0001-9792-2260>
Faculdade São Leopoldo Mandic, Brazil
E-mail: dnlrocha@uol.com.br

Abstract

Objective: to evaluate pain symptoms in patients after endodontic treatment of teeth with pulp necrosis under irrigation with 2.5% or 5.25% sodium hypochlorite. **Methods:** 50 single-rooted maxillary anterior teeth were divided into two groups (n=25). Group HS2: teeth with pulp necrosis rinsed with 2.5% sodium hypochlorite, Group HS5: teeth with pulp necrosis rinsed with 5.25% sodium hypochlorite. All canals were instrumented with Reciproc R25 or R40 or R50 files, depending on the initial diameter, according to the manufacturer's instructions, and rinsed with 10 mL of solution in each third. At the end, the Easy Clean tip was used, performing 03 cycles of 20s each with 1 mL of 17% EDTA, then 2 mL of 2.5% NaOCl for group HS2 and 5.25% for group HS5, shaking for 3 cycles of 20s. The canals were dried and filled using the single cone technique with AH Plus endodontic cement and sealed with provisional material and glass ionomer. After treatment, patients answered a questionnaire at 24h, 48h, 72h and 07 days post-treatment using the VAS pain scale, which ranks pain intensity from 0 to 10. Data were analyzed using the Biotest 5.0 program and subjected to the Shapiro-Wilk normality test. The sample showed non-parametric behavior and the Kruskal-Wallis test was used with a significance level of 5%. **Results:** There was no statistically significant difference regarding postoperative pain in the scores of VAS scale at 24h, 48h, 72h and 7 days after treatment with sodium hypochlorite at 2.5% and 5.25% ($p > 0.05$). Pain was mild in both groups. **Conclusion:** We conclude that 2.5% and 5.25% sodium hypochlorite solutions did not affect the pain level after endodontic treatments.

Keywords: Irrigation; Postoperative pain; Pulp necrosis; Solution concentration.

Resumo

Objetivo: avaliar sintomas de dor em pacientes após tratamento endodôntico de dentes com necrose pulpar sob irrigação com 2,5% ou 5,25% de hipoclorito de sódio. **Métodos:** 50 dentes anteriores superiores uniradiculares foram divididos

em dois grupos (n=25). Grupo HS2: dentes com necrose pulpar lavados com hipoclorito de sódio 2,5%, Grupo HS5: dentes com necrose pulpar lavados com hipoclorito de sódio 5,25%. Todos os canais foram instrumentados com limas Reciproc R25 ou R40 ou R50, dependendo do diâmetro inicial, de acordo com as instruções do fabricante, e enxaguados com 10 mL de solução em cada terço. Ao final, foi utilizada a ponta Easy Clean, realizando 03 ciclos de 20s cada com 1 mL de EDTA 17%, depois 2 mL de NaOCl 2,5% para o grupo HS2 e 5,25% para o grupo HS5, agitando por 3 ciclos de 20s. Os canais foram secos e obturados pela técnica de cone único com cimento endodôntico AH Plus e selados com material provisório e ionômero de vidro. Após o tratamento, os pacientes responderam a um questionário às 24h, 48h, 72h e 07 dias pós-tratamento utilizando a escala de dor VAS, que classifica a intensidade da dor de 0 a 10. Os dados foram analisados pelo programa Biotest 5.0 e submetidos à normalidade Shapiro-Wilk teste. A amostra apresentou comportamento não paramétrico e foi utilizado o teste de Kruskal-Walis com nível de significância de 5%. Resultados: Não houve diferença estatisticamente significativa em relação à dor pós-operatória nos escores da escala VAS às 24h, 48h, 72h e 7 dias após o tratamento com hipoclorito de sódio a 2,5% e 5,25% ($p > 0,05$). A dor foi leve em ambos os grupos. Conclusão: Concluímos que as soluções de hipoclorito de sódio 2,5% e 5,25% não afetaram o nível de dor após tratamentos endodônticos.

Palavras-chave: Irrigação; Dor pós-operatória; Necrose pulpar; Concentração da solução.

Resumen

Objetivo: evaluar los síntomas de dolor en pacientes tras el tratamiento endodóntico de dientes con necrosis pulpar bajo irrigación con hipoclorito de sodio al 2,5% o al 5,25%. Métodos: 50 dientes anteriores maxilares de una sola raíz se dividieron en dos grupos (n=25). Grupo HS2: dientes con necrosis pulpar enjuagados con hipoclorito de sodio al 2,5%, Grupo HS5: dientes con necrosis pulpar enjuagados con hipoclorito de sodio al 5,25%. Todos los conductos se instrumentaron con limas Reciproc R25 o R40 o R50, según el diámetro inicial, según las instrucciones del fabricante, y se enjuagaron con 10 mL de solución en cada tercio. Al final, se utilizó la punta Easy Clean, realizando 03 ciclos de 20 s cada uno con 1 mL de EDTA al 17 %, luego 2 mL de NaOCl al 2,5 % para el grupo HS2 y al 5,25 % para el grupo HS5, agitando durante 3 ciclos de 20 s. Los conductos se secaron y obturaron con la técnica de cono único con cemento endodóntico AH Plus y se sellaron con material provisional e ionómero de vidrio. Después del tratamiento, los pacientes respondieron un cuestionario a las 24h, 48h, 72h y 07 días después del tratamiento usando la escala de dolor VAS, que clasifica la intensidad del dolor de 0 a 10. Los datos fueron analizados usando el programa Biotest 5.0 y sometidos a la normalidad de Shapiro-Wilk prueba. La muestra mostró un comportamiento no paramétrico y se utilizó la prueba de Kruskal-Walis con un nivel de significancia del 5%. Resultados: No hubo diferencia estadísticamente significativa en cuanto al dolor postoperatorio en las puntuaciones de la escala EVA a las 24h, 48h, 72h y 7 días después del tratamiento con hipoclorito de sodio al 2,5% y al 5,25% ($p > 0,05$). El dolor fue leve en ambos os grupos. Conclusión: Concluimos que las soluciones de hipoclorito de sodio al 2,5% y al 5,25% no afectaron el nivel de dolor después de los tratamientos de endodoncia.

Palabras clave: Riego; Dolor posoperatorio; Necrosis pulpar; Concentración de la solución.

1. Introduction

Pain after endodontic treatment can be caused by mechanical, chemical, and/or microbial damage to the pulp or periradicular tissues, but microorganisms are considered the most important and common causes of postoperative pain (Jayakodi et al. 2012). During treatment, some patients experience a flare-up, which can be defined as pain and/or swelling of the soft tissue that occurs within a few hours or days after root canal treatment (Sipaviciute & Maneliene, 2014).

The mechanical nickel-titanium instrumentation systems have a shorter instrumentation time, less canal transport, and less debris extrusion than manually instrumented stainless steel K-files (Vaudt et al. 2009). In combination with abundant irrigation, the risk of postoperative discomfort can be reduced, contributing to the success of endodontic therapy (Madhusudhana, 2010). Reciprocal motion was introduced with the concept of preparing the canal with a single instrument. In this way, resistance to cyclic fatigue was increased, flexibility was improved, cross-infection was reduced, and stress on the instruments due to repetitive strain was decreased (Yared 2008).

The most used irrigant in endodontics is sodium hypochlorite (NaOCl) due to its antimicrobial activity and ability to dissolve tissue. Apical irrigation presents a particular challenge in terms of efficacy and safety (Haapasalo et al. 2014). The 5.25% and 2.5% sodium hypochlorite concentrations promoted complete removal of pulp debris on surfaces and cleaned areas that were difficult for endodontic instruments to access (Baumgartner & Cuenin, 1992). The 2.5% sodium hypochlorite rinsing

solution is considered the first choice for use in root canal systems (Lopes et al. 1999). The lower its concentration, the lower the chlorine loss, so it is naturally more stable (Camões et al. 2012).

In pain assessment, scores are considered the most accurate and reliable (Farzaneh et al. 2018). The visual analog scale (VAS) is the most used tool to assess the severity and extent of pain relief. Pain can affect the quality of life of patients after endodontic treatment and even affect their mood and performance of daily activities (Lopes et al. 2018).

The aim of this study was to evaluate the pain symptomatology in patients after endodontic treatment of teeth with pulp necrosis by comparing irrigation solutions with different concentrations. The null hypothesis was that the use of different concentrations of sodium hypochlorite would have no effect on postoperative pain and that the results would be equivalent.

2. Methodology

This study was approved by the Ethics Committee of the São Leopoldo Mandic School - CAAE number 38846520.4.0000.5374. This was an experimental, *in vivo* clinical study of fifty maxillary anterior teeth. The number of 25 teeth per group was based on the statistical test ANOVA with a minimum difference between treatment means of 0.08, a standard deviation of 0.073, a number of treatments of 8, a test power of 0.80, and an alpha of 0.05. The selected patients were fully informed about the purpose of this clinical study and signed the informed consent form.

Selection of patients

Patients who did not respond to the pulp vitality test, without painful symptoms, age between 18 and 70 years, unirradicular maxillary anterior teeth, dental crown in favorable conditions for the use of absolute isolation, fully formed roots and foramen, absence of external/internal resorption, absence of calcification of the canals were included in this study.

Patients taking analgesic/anti-inflammatory, antibiotic and immunosuppressive medications, children, pregnant and lactating women, teeth with advanced periodontal disease, teeth with calcification, external or internal resorption, dental perforations, fractures, teeth not treated in a single session, patients who did not report postoperative pain, allergies to medications, teeth with prosthetic crowns, were excluded from this study.

Treatment protocol

Once the patients were selected based on the inclusion and exclusion criteria, the percentage of sodium hypochlorite to be used for each tooth was determined by drawing cards. Endodontic treatments were performed as described below:

After history taking, clinical examination, and radiographic examination, the teeth were subjected to a thermal test with a cooling gas (EndoFrost; Coltene-Whaledent, Langenau-Germany) to test for and obtain an adverse reaction to cold. The procedures were performed with the anesthetic lidocaine 2% with epinephrine 1:100.000 (Alphacaine; DFL Indústria e Comércio Ltda, Rio de Janeiro, Brazil) by blocking the anterior superior alveolar nerve with a Unoject gingival needle (Nova DFL, Rio de Janeiro-Brazil).

After anesthesia, the teeth were isolated with a rubber dam (Madeitex, São José dos Campos-Brazil) together with a JON folding archwire (Vila Esperança - Brazil) and clamps for isolation (Hu-friedy, Rio de Janeiro-Brazil) according to the tooth anatomy. Top Dam gingival barrier (FGM Joinville - Brazil) was used for better sealing during absolute isolation. Surgical access was performed with spherical diamond drills 1013/1015 and drills 3082 (KG sorensen, Cotia - Brazil).

The Reciproc instrument (VDW, Munich, Germany) was selected according to the canal anatomy with the following parameters: R25 - indicated for narrow and curved canals; R40 file - for round canals where a #20 hand file has previously reached the working length (WL); R50 file - indicated for wide canals where a #30 hand file has previously reached the WL. The motor used to reproduce reciprocal motion was the VDW Silver.

All root canals were instrumented at the WL determined with the apical locator Romiapex A15 Romidan (Kiryat Ono, Israel) and confirmed by radiographic examination. C-Pilot hand files (#10) 21 and 25 mm and R- Pilot reciprocal files (VDW) were used to perform the glide path.

Rinsing was performed with NaOCl 2.5% or 5.25% (Asfer, São Caetano do Sul - Brazil) at each file change, depending on the previously established group. Group SH2 with sodium hypochlorite 2.5% and group SH5 with sodium hypochlorite 5.25%. All canals were instrumented with VDW Reciproc R25, R40 and R50 files of 21 or 25 millimeters according to the manufacturer's protocol. At the end, the Easy Clean plastic tip (Bassi/Easy, Belo Horizonte - Brazil) was used on the VDW SILVER motor (Munich Germany) in Reciproc All mode to activate the rinsing liquid. This action was performed during the rinse with 17% of EDTA (Formula & Action - São Paulo - Brazil) and during the final rinse with NaOCl. The Easy Clean plastic tip was used for 3 cycles of 20s each with 1 mL of EDTA 17% followed by 2 mL of NaOCl 2.5% for SH2 and 5.25% for SH5, shaking for 3 cycles of 20s and repeatedly aspirating and renewing the solution. Reciproc paper tips (VDW, Munich, Germany) were used to dry the canal.

For obturation, we used the endodontic obturation sealer AH Plus - (Dentsply Maillefer; Baillagues, Switzerland). The cones used were guttapercha Reciproc (VDW, Munich - Germany) according to the diameter of the file used. After obturation, the cones were cut with a Paiva tamper (Paiva, RJ, Brazil), followed by cleaning of the cavity with a sterile cotton swab soaked in alcohol. Sealing was done with Coltosol (Coltene Rio de Janeiro - Brazil) in a thickness of 1 to 2 mm and was completed with restorative glass Ionomer maxxion R - (FGM São Paulo - Brazil).

The patient could contact the researcher at any time in case of doubt. In case of severe pain, patients were instructed to take the analgesic ibuprofen 400mg for 8/8 hours.

VAS SCALE

Pain assessment was performed at intervals of 24 h, 48 h, 72 h, and 7 days after endodontic treatment. The patient answered a questionnaire followed by a VAS according to the literature (Barciela et al. 2019). A telephone call was made to assess pain after treatment. Patients had a copy of the VAS scale with them to guide their questioning about pain levels.

3. Results

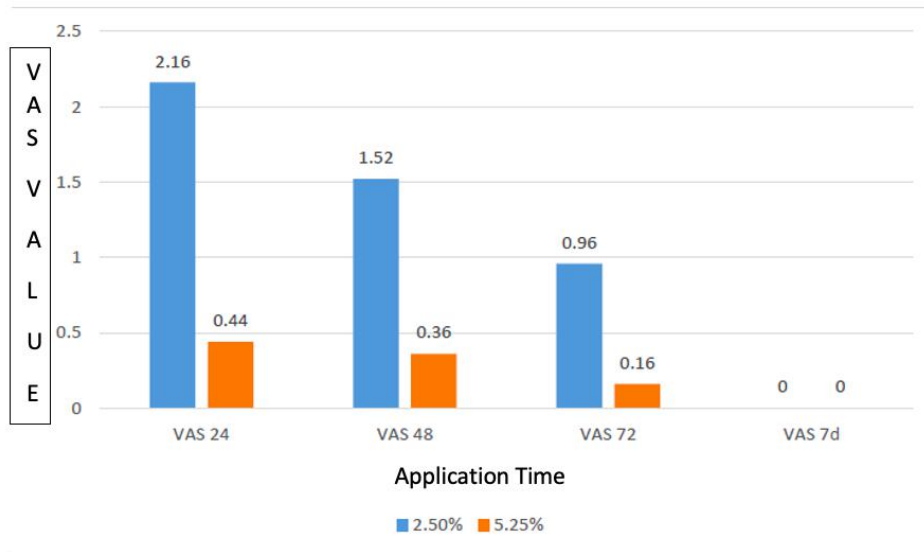
The results were analyzed in the Biotest 5.0 program and submitted to the Shapiro Wilk normality test. The sample presented nonparametric behavior and the Kruskal-Wallis test was used with a 5% significance level. There was no statistically significant difference regarding postoperative pain in the values obtained from the VAS scale after 24, 48, 72 hours and 7 days after treatment using 2.5% and 5.25% hypochlorite ($p>0.05$). The pain present in both groups was mild. (Table 1 and Graph 1).

Table 1. Medians, interquartile deviations and Kruskal-Wallis (Dunn) statistical analysis of the VAS scale results after 24, 48, 72 hours and 7 days in the experimental groups.

	VAS 24	VAS 48	VAS 72	VAS 7d	(p)
2.5%	0.00 (6.00) ^A	0.00 (2.00) ^A	0.00 (0.00) ^A	0.00 (0.00) ^A	0.2543
5.25%	0.00 (0.00) ^A	0.00 (0.00) ^A	0.00 (0.00) ^A	0.00 (0.00) ^A	0.8195
(p)	0.1805	0.3667	0.5736	1.00	

VAS 24: VAS scale result 24 hours after treatment; VAS 48: VAS scale result 48 hours after treatment; VAS 72: VAS scale result 72 hours after treatment; VAS 7d: VAS scale result 7 days after treatment. Different capital letters in the horizontal and vertical directions: statistically significant differences. Source: Authors.

Graph 1. Arithmetic averages of the VAS scale result after 24, 48, 72 hours, and 7 days in the experimental groups.



VAS 24: VAS scale result after 24 hours of treatment; VAS 48: VAS scale result after 48 hours of treatment; VAS 72: VAS scale result after 72 hours of treatment VAS 7d: VAS scale result after 7 days of treatment. Source: Authors.

4. Discussion

This study investigated whether different hypochlorite concentrations could cause pain after endodontic treatment. The two groups showed equivalent results in terms of postoperative pain at 24 h, 48 h, 72 h, and 7 days. Thus, the null hypothesis was accepted.

After obturation of root canals, mild discomfort can be observed, symptoms occur in the first 24h in most cases, and after 7 days 92% of patients are asymptomatic (Harrison et al. 1983) and in this study it was no different. Sodium hypochlorite may be cytotoxic to periradicular tissues, especially at high concentrations (Demenech et al. 2021). In this study, there were no reports beyond mild postoperative pain, and no patient reported other symptoms or complications such as swelling or paresthesia. Therefore, postoperative pain is a concern when sodium hypochlorite solutions are used in the treatment of nonvital teeth in a single session because of the risk of extravasation of the irrigation solution into these tissues (Jeansonne & White, 1994).

Endodontic treatment was performed using a single file with reciprocal instrumentation and a single cone technique, which simplified endodontic treatment (Figueiredo et al. 2020). This choice reduced cross-contamination, the use of a smaller number of instruments, shorter working time during endodontic treatment, and reduced instrument fatigue (Gavini et al. 2012). In this study, no fracture occurred in any of the Reciproc instruments.

Sodium hypochlorite is the most used chemical solution for root canal irrigation worldwide (Rosenfeld et al. 1978). The 2.5% sodium hypochlorite irrigation solution is considered the first choice for use in root canal systems (Siqueira et al. 2000) because it is also inherently more stable and has less chloride loss (Milano et al. 1991). Even when two different concentrations of irrigation solutions were used, the results showed equivalence in terms of pain symptomatology.

The irrigation is an extremely important and necessary step in endodontic procedures (Karcioglu et al. 2018). The canals were passively irrigated in an in-and-out motion without applying too much pressure on the syringe plunger (Bueno et al. 2017). It is likely that this approach minimized the potential risk of extravasation of sodium hypochlorite into the periapical tissue. Easy Clean tips were used for mechanical agitation of the irrigants, activated in a reciprocal motion with a volume of 2 mL in each canal, with 3 cycles of 20 seconds (Kato et al.2016).

There was no difference in the pain level when rated on the VAS scale compared to the other irrigation solutions at the 2.5% and 5.25% concentrations used in this study (Demenech et al. 2021). The VAS analog scale was used to analyze pain intensity in this study. It represents a numerical gradation from 0 to 10, where 0 means that there is no pain and 10 represents the maximum pain intensity that the patient can bear (Tavares et al. 2020).

5. Conclusion

We conclude that 2.5% and 5.25% sodium hypochlorite solutions do not affect pain levels after endodontic treatment.

Conflict of interest

All authors declare no conflict of interest.

References

- Barciela, B., da Silva Limoeiro, A. G., Bueno, C. E., Fernandes, S. L., Mandarini, D. R., Boer, N. C., & Rocha, D. G. (2019). In vivo evaluation of painful symptomatology after endodontic treatment with or without the use of photodynamic therapy. *Journal of Conservative Dentistry: JCD*, 22(4), 332.
- Baumgartner, J. C., & Cuenin, P. R. (1992). Efficacy of several concentrations of sodium hypochlorite for root canal irrigation. *Journal of endodontics*, 18(12), 605-612.
- Bueno, C. S. P., de Oliveira, D. P., Pelegrine, R. A., Fontana, C. E., Rocha, D. G. P., & da Silveira Bueno, C. E. (2017). Fracture incidence of WaveOne and Reciproc files during root canal preparation of up to 3 posterior teeth: a prospective clinical study. *Journal of endodontics*, 43(5), 705-708.
- Camões I, Freitas L, Santiago C, Gomes C, Menezes F. (2012) Analysis of concentration and ph of various trademarks of sodium hypochlorite.1(24): 15-8.
- de-Figueiredo, F. E. D., Lima, L. F., Lima, G. S., Oliveira, L. S., Ribeiro, M. A., Brito-Junior, M., & Faria e Silva, A. L. (2020). Apical periodontitis healing and postoperative pain following endodontic treatment with a reciprocating single-file, single-cone approach: a randomized controlled pragmatic clinical trial. *Plos one*, 15(2), e0227347.
- Demenech, L. S., de Freitas, J. V., Tomazinho, F. S. F., Baratto-Filho, F., & Gabardo, M. C. L. (2021). Postoperative pain after endodontic treatment under irrigation with 8.25% sodium hypochlorite and other solutions: a randomized clinical trial. *Journal of Endodontics*, 47(5), 696-704.
- Farzaneh, S., Parirokh, M., Nakhaee, N., & Abbott, P. V. (2018). Effect of two different concentrations of sodium hypochlorite on postoperative pain following single-visit root canal treatment: a triple-blind randomized clinical trial. *International endodontic journal*, 51, e2-e11.
- Gavini, G., Caldeira, C. L., Akisue, E., de Miranda Candeiro, G. T., & Kawakami, D. A. S. (2012). Resistance to flexural fatigue of Reciproc R25 files under continuous rotation and reciprocating movement. *Journal of Endodontics*, 38(5), 684-687.
- Haapasalo, M., Shen, Y., Wang, Z., & Gao, Y. (2014). Irrigation in endodontics. *British dental journal*, 216(6), 299-303.
- Harrison, J. W., Baumgartner, I. C., & Zielke, D. R. (1981). Analysis of interappointment pain associated with the combined use of endodontic irrigants and medicaments. *Journal of endodontics*, 7(6), 272-276.
- Jayakodi, H., Kailasam, S., Kumaravadivel, K., Thangavelu, B., & Mathew, S. (2012). Clinical and pharmacological management of endodontic flare-up. *Journal of pharmacy & bioallied sciences*, 4(Suppl 2), S294.
- Jeansonne, M. J., & White, R. R. (1994). A comparison of 2.0% chlorhexidine gluconate and 5.25% sodium hypochlorite as antimicrobial endodontic irrigants. *Journal of endodontics*, 20(6), 276-278.
- Karcioglu, O., Topacoglu, H., Dikme, O., & Dikme, O. (2018). A systematic review of the pain scales in adults: which to use? *The American journal of emergency medicine*, 36(4), 707-714.
- Kato, A. S., Cunha, R. S., da Silveira Bueno, C. E., Pelegrine, R. A., Fontana, C. E., & de Martin, A. S. (2016). Investigation of the efficacy of passive ultrasonic irrigation versus irrigation with reciprocating activation: an environmental scanning electron microscopic study. *Journal of endodontics*, 42(4), 659-663.
- Lopes, H. P., Martins, C. M., Carvalho, R. D. M., Siqueira Júnior, J. F., & Cabreira, M. S. (1999). Análise de diversas marcas de água sanitária: confiabilidade e segurança para uso como solução química auxiliar em endodontia. *Rev. bras. odontol*, 319-22.
- Lopes, L. P. B., Herkrath, F. J., Vianna, E. C. B., Gualberto Júnior, E. C., Marques, A. A. F., & Sponchiado Júnior, E. C. (2019). Effect of photobiomodulation therapy on postoperative pain after endodontic treatment: a randomized, controlled, clinical study. *Clinical oral investigations*, 23(1), 285-292.
- Madhusudhana, K., Mathew, V. B., & Reddy, N. M. (2010). Apical extrusion of debris and irrigants using hand and three rotary instrumentation systems—An in vitro study. *Contemporary clinical dentistry*, 1(4), 234.
- Milano, N. F., Girardi, V., Bergold, A. M., & Chiapini, L. G. (1991). Alguns aspectos do uso do hipoclorito de sódio em Endodontia. *Revista da Faculdade de Odontologia de Porto Alegre*. 32(1), 7-10.

Rosenfeld, E. F., James, G. A., & Burch, B. S. (1978). Vital pulp tissue response to sodium hypochlorite. *Journal of endodontics*, 4(5), 140-146.

Sipavičiūtė, E., & Manelienė, R. (2014). Pain and flare-up after endodontic treatment procedures. *Stomatologija*, 16(1), 25-30.

Siqueira Jr, J. F., Rôças, I. N., Favieri, A., & Lima, K. C. (2000). Chemomechanical reduction of the bacterial population in the root canal after instrumentation and irrigation with 1%, 2.5%, and 5.25% sodium hypochlorite. *Journal of endodontics*, 26(6), 331-334.

Tavares, S. G., Fontana, C. E., De Martin, A. S., Pinheiro, S. L., Pelegrine, R. A., & Rocha, D. G. P. (2020). In vivo evaluation of painful symptomatology after endodontic treatment performed using two different irrigation needle insertion depths. *European Journal of Dentistry*, 14(02), 274-280.

Tomazinho L, Da Silva D, Fagundes S, Tomazinho P. (2007) In vitro study of antimicrobial activity of irrigating solutions in the elimination of *Enterococcus faecalis*. *Revista Sul Brasileira de Odontologia*; 4(1): 12-16.

Vaudt, J., Bitter, K., Neumann, K., & Kielbassa, A. M. (2009). Ex vivo study on root canal instrumentation of two rotary nickel–titanium systems in comparison to stainless steel hand instruments. *International endodontic journal*, 42(1), 22-33.

Yared, G. (2008). Canal preparation using only one Ni-Ti rotary instrument: preliminary observations. *International endodontic journal*, 41(4), 339-344.