

Effects of ozone therapy on hematological and serum biochemical parameters in dogs affected by visceral leishmaniasis

Efeitos da ozonioterapia sobre os parâmetros hematológicos e bioquímico sérico de cães acometidos por leishmaniose visceral

Efectos de la ozonoterapia sobre parámetros hematológicos y bioquímicos séricos en perros afectados por leishmaniosis visceral

Received: 05/03/2022 | Reviewed: 05/12/2022 | Accept: 05/13/2022 | Published: 05/19/2022

Tiago Fávero Moda

ORCID: <https://orcid.org/0000-0002-2769-6680>
Centro de Inovação, Tecnologia e Educação, Brazil
E-mail: tiagomoda@hotmail.com

Carlos José de Lima

ORCID: <https://orcid.org/0000-0001-6736-2100>
Centro de Inovação, Tecnologia e Educação, Brazil
Universidade Anhembi Morumbi, Brazil
E-mail: cdcfdlima@gmail.com

Henrique Cunha Carvalho

ORCID: <https://orcid.org/0000-0003-0806-4132>
Centro de Inovação, Tecnologia e Educação, Brazil
E-mail: hccarvalho.engbio@gmail.com

Miguel Angel Castillo Salgado

ORCID: <https://orcid.org/0000-0001-5793-4013>
Universidade Estadual Paulista, Brazil
E-mail: miguel@fosjc.unesp.br

Adriana Barrinha Fernandes

ORCID: <https://orcid.org/0000-0002-1794-0790>
Centro de Inovação, Tecnologia e Educação, Brazil
Universidade Anhembi Morumbi, Brazil
E-mail: fernandesabm@gmail.com

Renato Amaro Zângaro

ORCID: <https://orcid.org/0000-0001-6962-3001>
Centro de Inovação, Tecnologia e Educação, Brazil
Universidade Anhembi Morumbi, Brazil
E-mail: razangaro@gmail.com

Lívia Helena Moreira

ORCID: <https://orcid.org/0000-0001-6432-7596>
Centro de Inovação, Tecnologia e Educação, Brazil
Universidade Anhembi Morumbi, Brazil
E-mail: lh.medicinaveterinaria@gmail.com

Abstract

Visceral leishmaniasis (VL) is a zoonosis and chronic disease caused by the protozoan *Leishmania* spp. which is of great concern to public health. Currently, the drugs used to treat the disease are costly and present undesirable side effects. The use of ozone to treat chronic diseases in both humans and dogs has shown satisfactory results. The aim of this study was to evaluate the ozone therapy in dogs with VL (n=6), administered by intra-abdominal application (IAA), to evaluate hematological and serum biochemical parameters. The protocol involves one gas dose per week for four consecutive weeks. The immunomodulatory action of ozone was determined in the laboratory analyses, confirmed by the increase trend in the white series and maintenance of the renal and hepatic function. Ozone therapy was found to be well tolerated and no adverse effects were observed. Further studies are required to elucidate the mechanisms of action on the infected host.

Keywords: Dog; Leishmaniasis; Ozone; Haematological; Serum biochemistry.

Resumo

A Leishmaniose Visceral (LV) é uma zoonose e doença crônica causada pelo protozoário *Leishmania* spp. que apresenta grande importância em saúde pública. Atualmente, os fármacos utilizados em seu tratamento estão associados ao alto custo e a efeitos colaterais indesejáveis. A utilização do ozônio no tratamento de doenças crônicas tanto em humanos quanto em cães têm mostrado resultados satisfatórios. O objetivo deste estudo foi de avaliar o uso

da ozonioterapia em cães com LV (n=6), através da aplicação por via intra-abdominal (IAA), para avaliação dos parâmetros hematológicos e bioquímico sérico. O protocolo consistia de uma aplicação por semana durante quatro semanas. Nas análises laboratoriais foi identificada uma ação imunomoduladora pelo ozônio, verificada pela tendência de aumento da série branca e manutenção da função renal e hepática. A ozonioterapia também se mostrou bem tolerável e não foram observados efeitos colaterais, futuros estudos serão necessários para elucidar os mecanismos de ação sobre o hospedeiro infectado.

Palavras-chave: Cão; Leishmaniose; Ozônio; Hematológico; Bioquímico sérico.

Resumen

La Leishmaniosis Visceral (LV) es una zoonosis y enfermedad crónica causada por el protozoo *Leishmania* spp. lo cual es de gran preocupación para la salud pública. Actualmente, los medicamentos utilizados para tratar la enfermedad son costosos y presentan efectos secundarios indeseables. El uso de ozono para el tratamiento de enfermedades crónicas tanto en humanos como en perros ha mostrado resultados satisfactorios. El objetivo de este estudio fue evaluar la ozonoterapia en perros con LV (n=6), administrada por aplicación intraabdominal (IAA), para evaluar parámetros hematológicos y bioquímicos séricos. En los análisis de laboratorio se determinó la acción inmunomoduladora del ozono, confirmada por la tendencia al aumento de la serie blanca y el mantenimiento de la función renal y hepática. Ozonoterapia fue bien tolerada y no se observaron efectos adversos. Se requieren más estudios futuros para dilucidar los mecanismos de acción sobre el huésped infectado.

Palabras clave: Perro; Leishmaniosis; Ozono; Hematológico; Bioquímico sérico.

1. Introduction

Leishmaniasis is a disease caused by protozoa of the genus *Leishmania* spp. In the interest of Brazilian Public Health, the two outstanding groups of leishmaniasis are: American cutaneous leishmaniasis, whose etiological agent is *Leishmania brasiliense*, and the second type that preferentially attacks the visceral organs, called Visceral Leishmaniasis (VL), whose etiological agent is *Leishmania donovani* (Gontijo & Carvalho, 2003; Baneth et al., 2008).

This disease occurs in tropical and subtropical areas (Gontijo & Melo, 2004) and it is among the six most significant endemics in the world with approximately 90% of the world cases occurring in India, Bangladesh, Nepal, Sudan and Brazil (Brasil, 2014; Gontijo & Melo, 2004).

In dogs, VL causes the development of a chronic systemic disease, which may cause the death of the animal (Baneth et al., 2008; Melo & Machado, 2009). Although some infected dogs may be asymptomatic (Alves et al., 1998), it is believed that these animals play an important role in the transmission of VL by harbouring the parasite (Gontijo and Melo, 2004).

The drugs that are currently indicated and used to treat Leishmaniasis in humans and dogs are costly, toxic, and cause several side effects. In addition, they are related to parasite resistance and parasite eradication failure (Murray et al., 2005; Sundar & Chatterjee, 2006).

Ozone therapy, in turn, is a low-cost treatment that has been widely used in humans and animals (Ogata and Nagahata, 2000; Ikeda et al., 2003; Haddad et al., 2009). The therapy is mainly used for the inhibition of oxidative stress in the treatment of degenerative diseases (Bocci, 1996; Haddad et al., 2009), as it presents bactericidal, fungicidal, viricidal and antialgic and anti-inflammatory effects (Giunta et al., 2001; Ikeda et al., 2003).

Currently, ozone therapy has been applied in veterinary science and is still in an emergent stage (Orlandin et al., 2021), and it has been associated with satisfactory responses in the treatment of various conditions, both in large and small animals (Alves et al., 2004; Haddad et al., 2009). The aim of this study was to assess the haematological and biochemical parameters of dogs affected by VL submitted to ozone treatment for 30 days.

2. Methodology

This study was approved by the institutional review board (Animal Care and Use Committee) of the University Camilo Castelo Branco (process #1-00037/2012).

Six dogs (n=6) infected with VL were diagnosed during the routine check-up at the Veterinary Hospital Domingos

Alves at Fernandópolis-SP, Brazil. The definitive diagnosis of VL was based on the serological results of Indirect Immunofluorescence Reaction, Enzyme-Linked Immunosorbent Assay and direct parasitological examination through fine-needle aspiration cytology of peripheral lymph nodes, and skin and/or bone marrow lesions to identify the protozoan.

Positive dogs were admitted to the Veterinary Hospital and were kept in a kennel with mosquito screens throughout the treatment period. The dogs wore Deltametrina collars (Scalibor, Intervet/MSD Inc., Brazil) for protection against sandflies. For the ozone treatment, the animals were anesthetized with propofol (5 mg/kg) intravenously to induce anesthesia and, if anesthetic maintenance when required. All dogs were submitted to trichotomy and anterior asepsis of the ventral abdominal area. After the procedure, all animals were monitored until complete anesthetic recovery time.

In order to perform ozone therapy, the ozone generator (MS3G, MS Instrum. Ltda, Brazil) using electrical corona arc discharge was coupled to a medical-grade oxygen cylinder. Ozone generator calibration were photometric determined with an ozone analyzer (BMT 964 ST, BMT GmbH, Germany) at the reactor outlet in real time, the output concentration was 66 mg/L of the O₂ + O₃ gas mixture with a valve oxygen gas flow on 0.5 L/min into the equipment, which resulted in value of ozone feed rate of 33 mg/min.

The intra-abdominal application (IAA) of the O₂ + O₃ gas mixture corresponded to 2.6 mg/kg body weight. The protocol treatment consisted of administering one gas dose per week for four consecutive weeks.

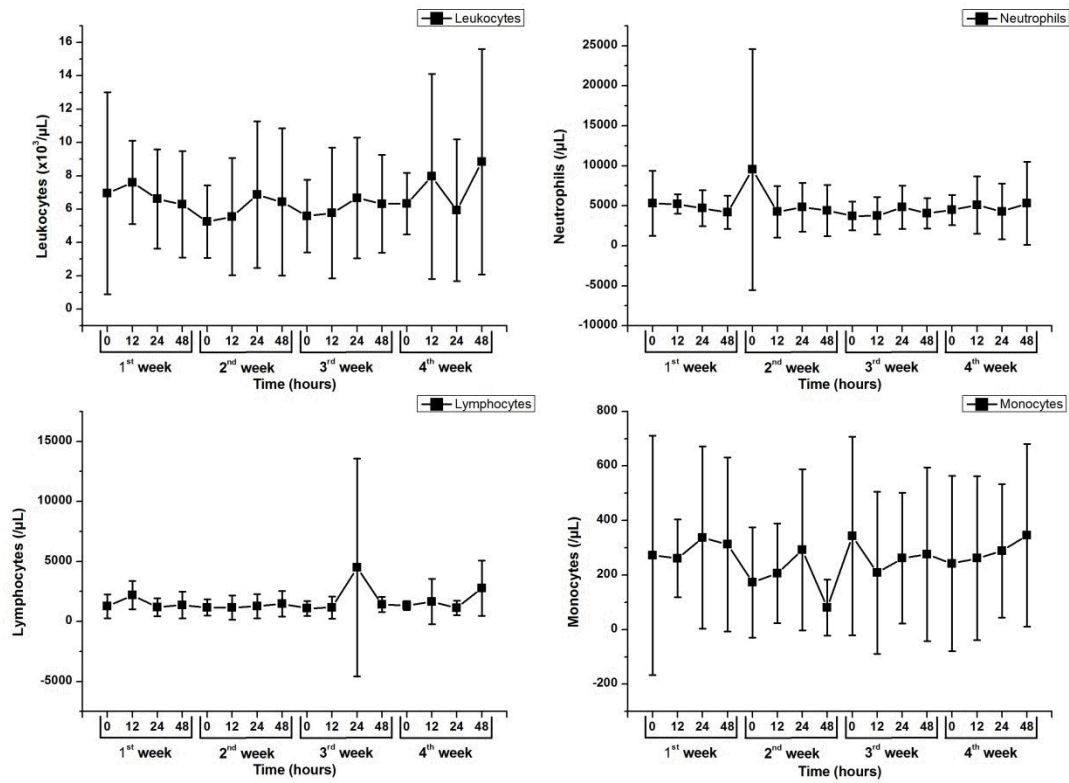
Blood samples were collected for hematological and serum biochemical parameters before treatment (0 - baseline) and 12, 24 and 48 hours after treatment. The serum values of leukocytes, neutrophils, lymphocytes, monocytes and the serum biochemical values of creatinine, urea, alanine aminotransferase (ALT), alkaline phosphatase (AP) were weekly measured during treatment.

Statistical analyses were performed via InStat software (v3.0, GraphPad Inc., San Diego, CA, USA) to assess all laboratory variables through comparative analyses at baseline (beginning of treatment = 0 hours) using Student's t test. The results were considered statistically significant at $p < 0.05$.

3. Results and Discussion

The evaluation of the white series revealed that the leukocyte levels showed a tendency to increase in relation to baseline. Leukocytes, neutrophils, lymphocytes and monocytes showed a tendency to increase, but this increase was not statistically significant ($p > 0.05$) (Figure 1), corroborating the results found by Haddad (2006) and, Pereira and Garcia (2006), possibly due to the immunomodulatory response of ozone. Cabral et al. (2020) used aqueous ozone therapy as an adjuvant to the standard treatment of cutaneous lesions caused by *Leishmania amazonensis* in mice, and have found enhancing leishmanicidal and wound healing activity of standard treatment when ozone was also applied. Gonçalves et al. (2020) in a canine VL case report, showed that ozone administrated rectal and within autohemotherapy in various sessions improved some dog clinical VL symptoms. No studies related to ozone therapy, administrated the direct ozone gas IAA in human or canine patients with VL were found, thus, this is an innovative research.

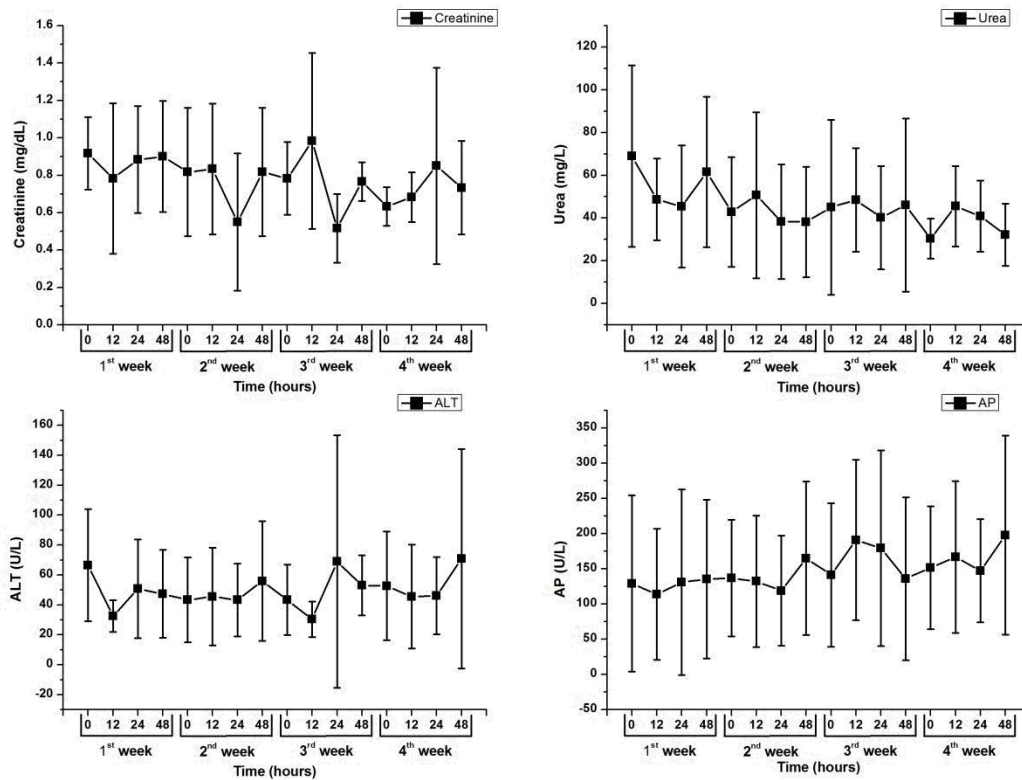
Figure 1. Analysis of the hematological parameters at baseline, 12, 24 and 48 hours after intra-abdominal application (IAA) of ozone for four consecutive weeks, showing a variation trend during the application of the gas. A) Leukocytes. B) Neutrophils. C) Lymphocytes and D) Monocytes.



Source: Authors.

The evaluation of renal function by the creatinine analysis showed a decrease at the beginning of the treatment, then remaining stable, while the urea levels showed a tendency to increase, remaining, however, within the normality values for the species ($p > 0.05$). In the analysis of the hepatic function an increase trend in ALT levels AP levels was observed and a decrease trend occurred during the third week of treatment. However, no statistically significant differences were found ($p > 0.05$) (Figure 2).

Figure 2. Analysis of the serum biochemical parameters of dogs with VL at baseline, 12, 24 and 48 hours after intra-abdominal application (IAA) of ozone for four consecutive weeks, showing a variation trend during the application of ozone. A) Creatinine. B) Urea. C) ALT and D) AP.



Source: Authors.

Biochemical analyses showed that the immunomodulatory dose of ozone did not affect renal and hepatic functions of the animals in the study, which remained within the reference values for canine specie, suggesting that there was no renal and hepatic lesion due to the $O_2 + O_3$ gas mixture. The intra-abdominal application of ozone was found to be well tolerated and no adverse effects were observed.

4. Conclusion

Ozone therapy has shown to be a safe technique for maintaining renal and hepatic functions in the possible treatment of dogs infected with VL, but further studies are required to elucidate the mechanisms of action on the infected host.

Acknowledgments

The authors thank the Anhembi Morumbi University for its support and encouragement.

References

- Alves, A. L., Bevilaqua, C. M. L., Moraes, N. B., & Franco, S.O. (1998). Levantamento epidemiológico da leishmaniose visceral em cães vadios da cidade de Fortaleza, Ceará. *Ciência Animal*, 8 (2), 63-68.
- Alves, G. E. S., Abreu, J. M. G., & Ribeiro Filho, J. D. et al. (2004). Efeitos do ozônio nas lesões de reperusão do jejuno em equinos. *Arquivo Brasileiro de Medicina Veterinária e Zootecnia*, 56 (4), 433-437. <https://doi.org/10.1590/S0102-09352004000400002>
- Baneth, G., Koutinas, A. F., & Solano-Gallego, L. et al. (2008). Canine leishmaniasis – new concepts and insights on an expanding zoonosis: part one. *Trends in Parasitology*, 24 (7), 324-330. [10.1016/j.pt.2008.04.001](https://doi.org/10.1016/j.pt.2008.04.001). <https://doi.org/10.1016/j.pt.2008.04.001>

- Bocci, V. (1996). Ozone as a bioregulator. Pharmacology and toxicology of ozone therapy today. *Journal of Biological Regulators and Homeostatic Agents*, 10 (2-3), 31-53.
- Brasil. Ministério da Saúde. Departamento de Vigilância Epidemiológica. (2014). Manual de vigilância e controle da leishmaniose visceral, Brasília: Ministério da Saúde – Secretaria de Vigilância em Saúde.
- Cabral, I. L., Utzig, S. L., & Banhuk, F. W. et al. (2020). Aqueous ozone therapy improves the standard treatment of leishmaniasis lesions in animals leading to local and systemic alterations. *Parasitology Research*, 119 (12), 4243-4253. <https://doi.org/10.1007/s00436-020-06925-8>
- Giunta, R., Coppola, A., & Sammartino, A. et al. (2001). Ozonized autohemotransfusion improves hemorheological parameters and oxygen delivery to tissues in patients with peripheral occlusive arterial disease. *Annals of Hematology*, 80 (12), 745-748. <https://doi.org/10.1007/s002770100377>
- Gonçalves, J. O. S., Paiva, P. O., & Oliveira, L. B. G. (2020). Uso da ozonioterapia como auxiliar no tratamento de cão portador de leishmaniose: relato de caso. *Pubvet*, 14 (1), 1-5. <https://doi.org/10.31533/pubvet.v14n1a495.1-4>
- Gontijo, B., & Carvalho, M. L. R. (2003). Leishmaniose tegumentar americana. *Revista da Sociedade Brasileira de Medicina Tropical*, 36 (1), 71-80. <https://doi.org/10.1590/S0037-86822003000100011>
- Gontijo, C. M. F., & Melo, M. N. (2004). Leishmaniose visceral no Brasil: quadro atual, desafios e perspectivas. *Revista Brasileira de Epidemiologia*, 7 (3), 338-349. <https://doi.org/10.1590/S1415-790X2004000300011>
- Haddad, M. A. (2006). Efeitos da ozonioterapia sobre parâmetros clínicos, hematológicos e da bioquímica sanguínea de equinos. 2006. 138f. Dissertação (Mestrado em Ciências), Universidade Federal de Viçosa, Viçosa.
- Haddad, M. A., Souza, M. V., & Hincapie, J. J. et al. (2009). Comportamento de componentes bioquímicos do sangue em equinos submetidos à ozonioterapia. *Arquivo Brasileiro de Medicina Veterinária e Zootecnia*, 61(3), 539-546. <https://doi.org/10.1590/S0102-09352009000300003>
- Ikeda, F. A., Luvizotto, M. C. R., & Gonçalves, M. E. et al. (2003). Perfil hematológico de cães naturalmente infectados por *Leishmania chagasi* no município de Araçatuba, São Paulo (Brasil): um estudo retrospectivo de 191 casos. *La Clínica Veterinária*, 47, 42-48.
- Melo, G. D., & Machado, G. F. (2009). Choroid plexus involvement in dogs with spontaneous visceral leishmaniasis: a histopathological investigation. *Brazilian Journal of Veterinary Pathology*, 2(2), 69-74.
- Murray, H. W., Berman, J. D., Davies, C. R., & Saravia, N. G. (2005). Advances in leishmaniasis. *Lancet*, 366(9496), 1561-1577. [https://doi.org/10.1016/S0140-6736\(05\)67629-5](https://doi.org/10.1016/S0140-6736(05)67629-5)
- Ogata, A., & Nagahata, H. (2000). Intramammary application of ozone therapy to acute clinical mastitis in dairy cows. *The Journal of Veterinary Medical Science*, 62(7), 681-686. <https://doi.org/10.1292/jvms.62.681>.
- Orlandin, J. R., Machado, L. C., Ambrósio, C. E., & Travagli, V. (2021). Ozone and its derivatives in veterinary medicine: a careful appraisal. *Veterinary and Animal Science*, 13, 100191. <https://doi.org/10.1016/j.vas.2021.100191>
- Pereira, M. T. C., & Garcia, C. A. (2006). Eficácia da ozonioterapia no tratamento de mastite subclínica de vacas em lactação. *Veterinária Notícias*, 12(2), 109-115.
- Sundar, S., & Chaterjee, M. (2006). Visceral leishmaniasis – current therapeutic modalities. *The Indian Journal of Medical Research*, 123(3), 345-352.