

## Ultrasound wave transports apitoxin in arthritic joint. - Experimental study

A onda de ultra-som transporta apitoxina na articulação artrítica. - Estudo experimental

La onda ultrasónica transporta la apitoxina en la articulación artrítica. - Estudio experimental

Received: 05/15/2022 | Reviewed: 05/24/2022 | Accept: 05/27/2022 | Published: 06/03/2022

### Felipe Misael da Silva Morsoleto

ORCID: <https://orcid.org/0000-0002-4802-0399>  
University of Western Paraná, Brazil  
E-mail: [felipe\\_morsoleto@yahoo.com.br](mailto:felipe_morsoleto@yahoo.com.br)

### Pedro Rondon Werneck

ORCID: <https://orcid.org/0000-0001-8729-5259>  
University of Western Paraná, Brazil  
E-mail: [prondonwerneck@gmail.com](mailto:prondonwerneck@gmail.com)

### Fernando Russo Costa do Bomfim

ORCID: <https://orcid.org/0000-0002-2614-3603>  
Herminio Ometto Foundation, Brazil  
E-mail: [fernando\\_bomfim@live.com](mailto:fernando_bomfim@live.com)

### Maria Jose Misael da Silva Morsoleto

ORCID: <https://orcid.org/0000-0001-7544-6224>  
University of Aveiro, Portugal  
E-mail: [mjmorsoleto@yahoo.com.br](mailto:mjmorsoleto@yahoo.com.br)

### Abstract

Man, in his common lore started using the toxin produced by bees, apitoxin, as a topical medication for rheumatoid arthritis in time immemorial. Systematically subjecting themselves to bee stings. In this study, we sought to use this substance, apitoxin, in an experimental model of induced arthritis. In order for the substance to be introduced through the tissue, ultrasound was used as a vehicle, this action is called phonophoresis. So that the apitoxin would reach the arthritic joint. Wistar rats were used in a model where arthritis was induced by inoculation into the knee joint with zymosan. The animals were divided into groups: GI (positive control), GII (negative control), GIII (topical apitoxin-treated group), GIV (ultrasound-treated group) and GV (phonophoresis-treated group). Inducing arthritis, once established, treatment of the groups was initiated. After 21 days of treatment, the animals were anesthetized with ketamine and xylazine, their knees were submitted to radiographic images, temperatures were collected and euthanized. The RX films were processed by Image J software to collect the intra-articular distance of the femur and tibia. The temperature of each individual in the group was collected. Space and temperature averages: Group I (0.15 mm and 35.7°C), group II (0.03 mm and 38.2°C), group III, (0.4 mm and 37.8°C), group IV (0.6 mm and 36.7°C) to group V (0.78 mm and 36.2°C). We conclude that ultrasound combined with apitoxin via phonophoresis was efficient in tissue repair and subsequent regeneration of joint contours when compared with ultrasound or topical apitoxin alone.

**Keywords:** Arthritis induced; Apitoxin; Phonophoresis; Rattus wistar.

### Resumo

O homem em seu saber comum começou a utilizar a toxina produzida pelas abelhas, a apitoxina, como medicação tópica para artrite reumatóide em tempos imemoriais. Submetendo-se sistematicamente á picadas de abelhas. Neste estudo, buscou-se utilizar esta substância a apitoxina, em um modelo experimental de artrite induzida. Para que a substancia fosse introduzida através dos tecido, utilizou-se o ultra som como veículo, esta ação é denominada fonoforese. Para que a apitoxina atingisse a articulação artrítica. Foram utilizados ratos Wistar, em um modelo onde a artrite foi induzida por inoculação na articulação do joelho com zymosan. Os animais foram divididos em grupos: GI (controle positivo), GII (controle negativo), GIII (grupo tratado com apitoxina tópica), GIV (grupo tratado com ultra som) e GV (grupo tratado com fonoforese). Induzindo a artrite, assimque estabelecida, foi iniciado o tratamento dos grupos. Com 21 dias de tratamento os animais foram anestesiados com ketamina e xilazina, seus joelhos foram submetidos a imagens radiográficas, as temperaturas coletadas e eutanasiados. Os filmes de RX foram processados pelo software Image J para coletar a distância intra-articular do fêmur e da tibia. A temperatura de cada indivíduo do grupo foi coletado. As médias do espaço e temperatura: Grupo I (0,15 mm e 35,7°C), grupo II (0,03 mm e 38,2°C), grupoIII, (0,4 mm e 37,8° C), grupo IV (0,6 mm e 36,7°C) para o grupo V (0,78 mm e 36,2°C). Concluimos que o ultrassom combinado com apitoxina via fonoforese, foi eficiente na reparo tecidual e posterior regeneração dos contornos articulares quando comparado apenas com a aplicação de ultra som ou apitoxina tópica.

**Palavras-chave:** Artrite induzida; Apitoxina; Fonoforese; Rattus wistar.

## Resumen

El hombre en su tradición común comenzó a usar la toxina producida por las abejas, la apitoxina, como medicamento tópico para la artritis reumatoide en tiempos inmemoriales. Someterse sistemáticamente a las picaduras de abejas. En este estudio buscamos utilizar esta sustancia, la apitoxina, en un modelo experimental de artritis inducida. Para que la sustancia fuera introducida a través del tejido se utilizó como vehículo el ultrasonido, esta acción se denomina fonoforesis. Para que la apitoxina llegara a la articulación artrítica. Se usaron ratas Wistar en un modelo en el que se indujo artritis mediante la inoculación en la articulación de la rodilla con zymosan. Los animales se dividieron en grupos: GI (control positivo), GII (control negativo), GIII (grupo tratado con apitoxina tópica), GIV (grupo tratado con ultrasonido) y GV (grupo tratado con fonoforesis). Induciendo la artritis, una vez establecida, se inició el tratamiento de los grupos. Después de 21 días de tratamiento, los animales fueron anestesiados con ketamina y xilazina, sus rodillas fueron sometidas a imágenes radiográficas, se tomó la temperatura y se sacrificaron. Las películas RX fueron procesadas por el software Image J para recopilar la distancia intraarticular del fémur y la tibia. Se recogió la temperatura de cada individuo del grupo. Promedios espaciales y de temperatura: Grupo I (0,15 mm y 35,7°C), grupo II (0,03 mm y 38,2°C), grupo III, (0,4 mm y 37,8°C), grupo IV (0,6 mm y 36,7°C) a grupo V (0,78 mm y 36,2°C). Concluimos que el ultrasonido combinado con apitoxina a través de fonoforesis fue eficaz en la reparación de tejidos y la posterior regeneración de los contornos de las articulaciones en comparación con el ultrasonido o la apitoxina tópica sola.

**Palabras clave:** Artritis inducida; Apitoxina; Fonoforesis; Rattus wistar.

## 1. Introduction

Rheumatoid arthritis (RA) is a chronic systemic disease, with a predominance of joints, characterized by chronic inflammation of the synovial membrane. It is a disease influenced by hormonal factors, environmental factors and genetics combined lead to the development of an autoimmune process where the antibodies produced are directed to the organism itself that visualizes the joint targets. Often affecting hands, wrists, elbows, shoulders, feet, ankles, knees. When the process takes on a systemic character, extra-articular manifestations such as subcutaneous rheumatoid nodules, vasculitis, pericarditis, pleurisy and pulmonary fibrosis develop. The chronic inflammatory process results in changes in cell composition and gene expression in the synovium (Fraenkel, 2021).

Occurring in the proliferation of synovial tissue, with production of intra-articular pannus with expansion with consequent structural damage to cartilage, bone and ligaments. It is a systemic disease of unknown etiology, evidenced by a persistent polyarticular synovitis, symmetrically distributed with great deforming potential. (Fraenkl *et al.* 2021; Orr *et al.*, 2017). It is estimated that it affects 1% of the Brazilian population, with a large burden on social security. The changes lead to more severe deformities that cause disability in a predominant age group between 30 and 50 years. AR usually manifests after age 30 years and was higher in women. Men and women over 65 appear to be affected by the same percentage. Although the high prevalence of the etiology of RA remains unknown, it is believed to be related to genetic factors. The RA patient places a great burden on social security (Shinjo & Moreira, 2021). Knowledge of AR in animals and the appropriate modes of treatment can be very helpful in patients with this disease, (Morsoleto, 2007). To study various animal models of RA have been established and staff must be accepted and must provide information on the histopathological and molecular genetics of autoimmunity. They should emphasize the following features, (Oliver and Brahne, 1996) Clinical, pathological and radiological findings similar to those of RA with few systemic manifestations: some non-rheumatoid arthritis findings; induction in animals of easy handling with low operational cost, reliability of results in short experimental time. Response to therapeutic agents, measurable. Experimental arthritis can be induced by various agents.

From this universe of inducing agents, zymosan-induced arthritis arises. Polysaccharide derived from the wall of the yeast *Saccharomyces cerevisiae*, a substance that induces systemic inflammatory phenomena in the joints of rats, mice and rabbits with persistent proliferation of the synovium and cartilage degradation, accounting for most of the findings of RA. Developing joint manifestations that is associated with a prostaglandin-dependent process 2 (pain, swelling, fever) with increased aggression to articular cartilage and IL-1 production (Morsoleto *et al.*, 2015). Traditional therapies to treat the arthritic patient, using gold salts, NSAIDs, drugs that modify the course of the disease and biological agents. These therapies have long-term side

effects that are accentuated by prolonged use of permanent treatment (Moreira et al, 2001). Use of alternative medicine among agents to treat rheumatoid arthritis, *Apis mellifera* bee venom. The property has echoes of this poison in ancient Egypt, when many ailments were treated with ointments made from bees. Hippocrates (450BC, Galen 130AD, Charlemagne received bee stings on the body for the treatment of arthritic joints (Maia, 2002). The first publications of clinical studies with bee venom applications occurred in 1864 in Likomskiy, Tere in 1888 described by Beck in 1997. Bee Venom (Veno Been Therapy) has been traditionally used in Eastern medicine and Eastern European countries to relieve pain and treat inflammatory diseases such as rheumatoid arthritis (RA). Allergic and Toxic Effects Apitoxin is a neurotoxin, composed of 88% water, amino acids, enzymes, peptides, bioactive amines, sugars and other volatile components in small amounts. Below lethal doses these toxins can have therapeutic physiological actions. (Leão *et.al.*,2005) Apitoxin is composed of a mixture of nitrogen components, which make up about 90% of its dry weight.

A chronic and systemic disease, rheumatoid arthritis (RA) is predominant in the joints and is characterized by chronic inflammation of the synovial membrane (Moreira & Carvalho, 2001). Influenced by combined hormonal, environmental and genetic factors (Fraenkel *et.al.*, 2021). RA promotes the development of an autoimmune process. The antibodies produced in this process are directed to the body itself, targeting the joints and joints. Causing affections in the hands, wrists, elbows, shoulders, feet, ankles, knees. When the autoimmune process has a systemic character, the manifestations are extra-articular. Forming subcutaneous rheumatoid nodules, developing vasculitis, pericarditis, pleuritis and triggering pulmonary fibrosis. The autoimmune response can trigger a chronic inflammatory process that results in changes in cell composition and gene expression (Fraenkl *et al.*, 2021; Orr *et al.*, 2017). In the synovium, the chronic inflammatory process produces a response resulting in the proliferation of synovial tissue, with the production of intra-articular pannus with expansion with consequent structural damage to cartilage, bone and ligaments (Lipowitz *et al.*, 1985; Morsoleto *et al.*, 2015). This systemic disease of unknown etiology, evidenced by a persistent polyarticular synovitis, symmetrically distributed with great deforming potential, affects 1% of the Brazilian population and is responsible for 20% of the Ministry of Health's expenditure on high-cost medications and with a great burden on social security. Social. The changes lead to more severe deformities that cause disability in a predominant age group between 30 and 50 years. Rheumatoid arthritis usually manifests after age 30 years and was higher in women. Men and women over 65 appear to be affected by the same percentage. Although the high prevalence of the etiology of RA remains unknown, it is believed to be related to genetic factors (Kurkó *et al.*, 2013).

Knowledge of arthritis in animals and appropriate modes of treatment can be very helpful in patients with this disease. Morsoleto (2007). To study various animal models of RA, standards and precepts were established in order to provide information on the histopathological and molecular genetics of autoimmunity. According to Oliver & Brahne (1996) the following characteristics should be emphasized: clinical, pathological and radiological findings similar to those of RA. With few systemic manifestations and some findings of non-rheumatoid arthritis. Induction should advocate animals that are easy to handle and have low operating costs, reliability of results in a short experimental time. In addition to including response to therapeutic agents, measurable. Experimental arthritis can be induced by various agents. In this universe of inducing agents, zymosan-induced arthritis appears (Keystone *et al.*, 1977; Di Carlo *et al.*, 1981). Which is a polysaccharide derived from the wall of the yeast *Saccharomyces cerevisiae*, a substance that induces systemic inflammatory phenomena in the joints of rats, mice and rabbits with persistent proliferation of the synovium and cartilage degradation, developing most of the findings of RA. These are joint manifestations that are associated with a prostaglandin-dependent process 2 (pain, swelling, fever) with increased aggression to the articular cartilage, Morsoleto *et al.*, (2007).

Traditional therapies to treat arthritic patients, using gold salts, NSAIDs, drugs that modify the course of the disease and biological agents, produce long-term side effects in the body of the RA carrier. Symptoms that are accentuated by prolonged use of permanent treatment (Moreira *et al.*, 2001; Gabay *et al.*, 2014; Nader *et al.*, 2021). Use of alternative medicine among

agents to treat rheumatoid arthritis, *Apis mellifera* bee venom. Apitoxin is composed of a complex mixture of enzymes. Among its components we find substances with pharmacological principles and also with toxic effects for the organism. Consisting of eighteen active components, the main ones being apamin, histamine, hyaluronidase, catecholamines, dopamine, serotonin, melittin and phospholipase (Lee *et al.*, 2020). As a powerful non-steroidal anti-inflammatory and has been used in clinical conditions such as arthritis, rheumatism and other autoimmune diseases (El Mehdi *et al.*, 2021) It has economic potential, considering the prominent position occupied by Brazilian beekeeping in the world. world market (Silvano *et al.*, 2020). Its pharmacological properties have echoes in ancient Egypt, when many ailments were treated with ointments made from bees. Hippocrates (450BC, Galen 130AD, Charlemagne received bee stings on the body for treatment of arthritic joints (Maia, 2002) The first publications of clinical studies with bee venom applications occurred in 1864 with Likomskiy and Tere in 1888 reported in their article by Beck 1997.

The therapy has traditionally been used in Eastern medicine and Eastern European countries to relieve pain and treat inflammatory diseases such as rheumatoid arthritis (RA) (Moreno & Giralt, 2015). Apitoxin is the use of Western medicine, prejudices about the risk of allergic reactions and toxic effects Apitoxin is a neurotoxin, composed of 88% water, amino acids, enzymes, peptides, bioactive amines, sugars and other volatile components in small amounts. Below lethal doses of these toxins may have therapeutic physiological actions. (Maia, 2002; Silvano *et al.*, 2020). Apitoxin is composed of a mixture of nitrogen components, which make up about 90% of its dry weight. According to Morsoleto (2015), ultrasound is a mechanical wave). inaudible longitudinal, often above 20 KHz that carries energy through vibrations of the particles of the medium through which the wave is propagating, and do not propagate in a vacuum, cause expansions and compressions of the environment each half-wavelength of energy that carries the wave decreases with the distance traveled by the vibrating beam and this phenomenon is known as attenuation (Sato *et al.*, 2014; Watanabe *et al.*, 2017). Attenuation is a result of energy absorption by tissues and wave dispersion away from the main beam. This phenomenon, attenuation, causes physical effects on tissues that can cause biological changes (Acheta *et al.*, 2022). In 1990, William defined phonophoresis as the movement of drugs through the skin into the skin tissues under the influence of ultrasound.

These drugs are pharmacodynamically active (Saliba *et al.*, 2007; Baranowski *et al.*, 2018) It is an efficient alternative for the transport of substances in addition to the use of oral drugs or intradermal injections. There are several advantages in using this type of treatment, among them the localized action of the drug with consequent absence of side effects due to systemic actions if the drug has this type of action (Silva *et al.*, 2021; Sun *et al.*, 2021).

Another advantage of this form of treatment is the sum of the inherent effects of ultrasound associated with the effects of the drug. Various types of drugs, such as steroids and anti-inflammatories, have been administered via phonophoresis (Madzia *et al.*, 2020). The aim of this study was to induce rheumatoid arthritis in the knees of rats and to evaluate the performance of aptotoxin via phonophoresis, used as a drug coupler.

**Table 1.** Main components of apitoxin (been venom).

	Molecular Weight (D)	Component	% dry basis	Observations
	<b>&lt; 1000</b>	Peptides	15	Chains of up 9 amino acids
		Monoamines	3	Histamine, dopamine, norepinephrine...
		Others	6	Isoleted amino acids, carbohydrates, phospholipids...
	<b>Polypeptides</b> <b>1000 a 10.000</b>	Melittin	50	Anti-inflammatory
		Apamin	2	Anti-inflammatory
		Peptide MCD	2	Anti-inflammatory
Others		3	Tertiapin, secapin	
<b>Enzymes</b> <b>&gt; 10.000</b>	Phospholipase A2	12	Prime allergen	
	Hiauronidase	2	Secondary allergen	
	Others	3	Acid phosphatase, glucosidase, esterase	
<b>Others substances</b>		2	Adolapin, protease inhibitor	

Source: Fractionation and characterization of apitoxin, Maia *et al.* (2002).

## 2. Methodology

The ethics committee under number 876/2007 approved the methodology (Morsoleto protocol, 2007). Twenty female Wistar rats with an average weight of 170 g, 60 days old, were divided into five (5) groups of four (4) animals, which were maintained with balanced diet and water ad libitum, during light/dark periods for 12 hours, heated to an average ambient temperature of 25°C. To implement the induced arthritis, the groups were divided into: I (negative control). The animals were anesthetized with an intraperitoneal injection of 0.3 mL of ketamine and 0.1 mL of xylazine for each 200g of body weight of the animal and subjected to injection of zymosan (1 mg) diluted in 50µl of 0.9% saline. on the right knee. The apitoxin was used Apitox cream (Apifarma) with the active ingredient apisinum, 21g (6mg/kg) of homogenized water-soluble gel was administered 1ml in each animal in the topical treatment or phonophoresis.

The entire experiment was carried out on the premises of the vivarium of Fundação Hermínio Ometto/ Araras -SP. After a period of 7 days, the animals in group II did not receive any treatment (positive control). Group III animals were treated with topical apitoxin in circular motions for 1 minute. Those in group IV were treated with the use of therapeutic ultrasound, through circular movement, at a 90° angle and continuous pulse regimen, with a frequency of 1 MHz for one minute, with a daily frequency and intensity of 0.2 W/cm<sup>2</sup>. Those in group V were treated with carbopol gel apitoxin via phonophoresis through a circular movement, at a 90° angle and continuous pulse regimen, with a frequency of 1 MHz for one minute, with a daily frequency and intensity of 0.2 W/ cm<sup>2</sup>. All animals underwent intervention for 21 days. In their water were added 10 drops of Dipyron monohydrate per liter. The animals were euthanized according to the days of confinement, since the beginning of the experiment, which are 3, 7, 14 and 21.

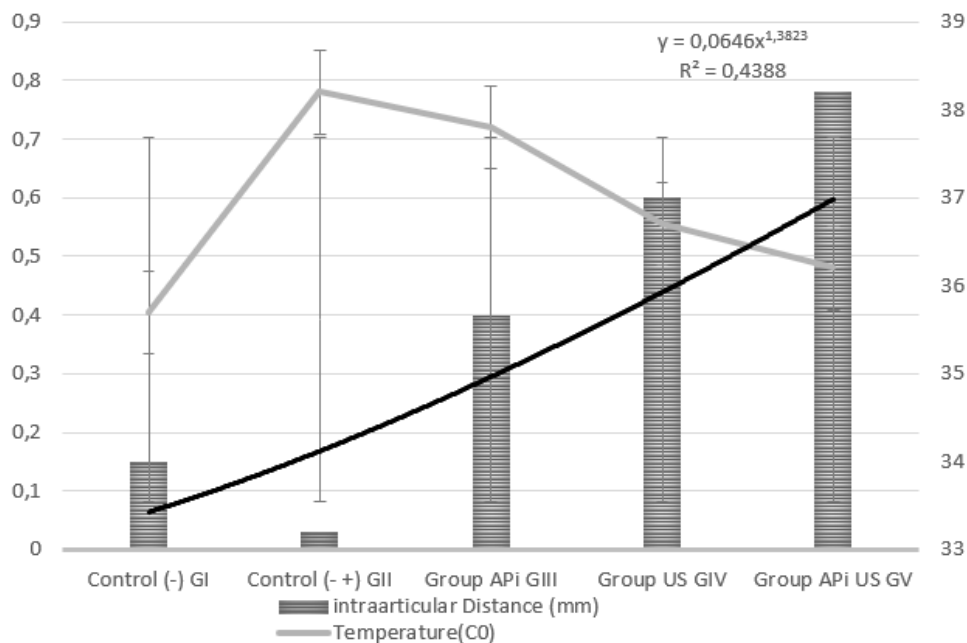
The radiographs were obtained by periapical dental film of the X-ray machine, following the protocol: Distance to the focal area of the film 20 cm, exposure time of 0.1 seconds of play was, the film development time for 30 seconds. It was quickly washed for 10 seconds, then it remained in the liquid fixative for 10 minutes and washed again for 10 minutes. Both the developer and the fixative used were from the Kodak brand. Intra-articular spaces were measured on a millimeter scale using a free Java-based Image J image processor software that displays, edits, analyzes, processes, saves and prints 8-bit, 16-bit images. The temperature was collected from the animals of the groups during the treatment.

### 3. Results

With the radiographs developed, the images revealed: In group I, intact contours, joint structures and interarticular spaces preserved. Group II with 3 days, there is the presence of thickening of the synovial membrane; at 7 days, early bone demineralization, with femoral patella collapsed on the surface, at 14 days, knee demineralization, the tibial plateau lost its morphological limit, there was intra-articular soft tissue calcification, at twenty-one (21) days, image radiography showed osteoporosis, visible trabeculae without patella and femur space. Group III presented 3 days with decreased intra and periarticular edema, the contours at 7 days began to become clearer, at fourteen (14) days it presented different contours in the joint region with signs of bone regeneration at Twenty-one (21) days and observed an increase in the space between the patella and the femur. Group IV had three days for intra- and periarticular edema to decrease. Seven (7) days with the contours become clearer, while at fourteen (14) days they showed signs of bone regeneration. At twenty-one (21) days, Group IV images revealed an increase in the space between the patellar patella and the femur. The animals in Group V at three (3) days showed disappearance of synovial thickening at seven (7) days and the contour of the distal femur began to emerge, at 14 days the images reveal the delineated, more mineralized distal femur and more visible popliteal groove. At twenty-one (21) days, it was possible to visualize the clearest popliteal fossa, with no signs of arthrosis or thickening.

Measurement of body temperature in an arthritis induction experiment is an important clinical parameter. In rats and mice, it has been measured by rectal probe. (Reitman, 2018). As shown in figure 1, the animals in the control group had an average interarticular space of 0.15 mm and a temperature of 35.7°C. After 21 days of inoculation with zymosan, group II had an average space of 0.03 mm and an intra-articular temperature of 38.2, III, a distance of 0.4 mm and an average temperature of 37.8 °. In group IV, the means of joint distance and temperature were 0.6 mm and 36.7°C for group V, mean values of intra-articular space of 0.78 mm and temperature of 36.2°C were observed as showed in figure 2. Values considered for n equal to 10. As shown in Table (2).

**Figure 1.** It may be noted that a decrease in temperature articulate, when increasing the intraarticular space.  $p < 0.05$ , paired Wilcoxon.



Source: Authors.

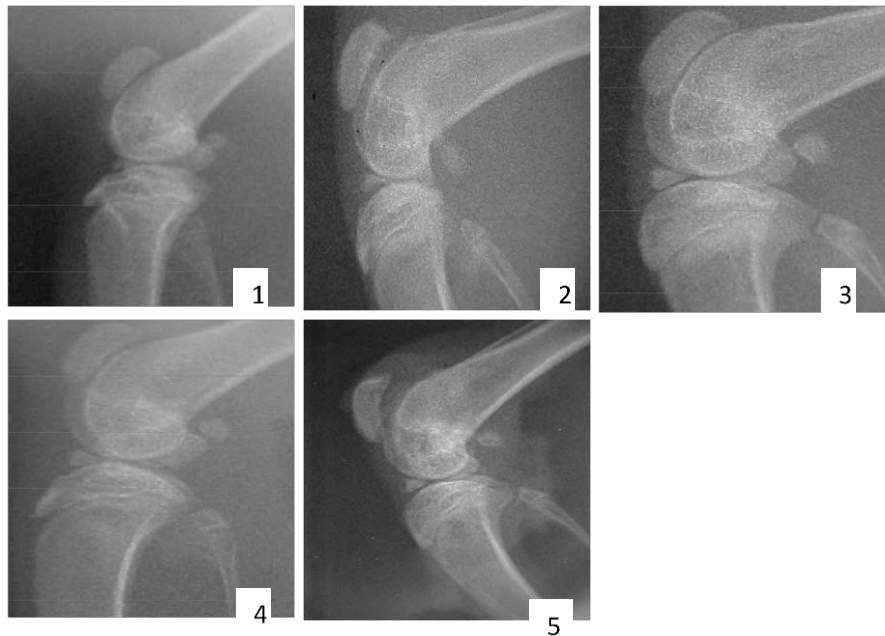Table 2 shows numerically that as the temperature increases, the joint value decreases the intra-articular space between the groups when compared to the negative control group I.

**Table 2.** Relationship between numerical values of temperature and intra-articular space between groups.

Groups	Intraarticular Distance (mm)	Temperature (C <sup>0</sup> )
Control (-) GI	0,15	35,7
Control (+) GII	0,03	38,2
Group APi GIII	0,4	37,8
Group US GIV	0,6	36,7
Group APi US GV	0,78	36,2

Source: Authors.

**Figure 2** Periapical radiography of the knee joints of the animals in the experiment. Profile images of the radiographed parts. Fig. 1 control group (I G.) Fig 2 (IIG.) (ARI), with 21 days. Fig 3 (IIIG.) (ARI + Apitoxin) with 21 days. Fig 4 (IV G.) (ARI + US), animals with 21 days. Fig 5 (V G.) treated by phonoforesis (ARI US+) Apitoxin; animal with 21 days.



Source: Authors.

As shown in table 3, the authors gathered the results observed in the X-ray examination during the experiment. We can observe that the inducer of arthritis through the provoked synovial inflammation led to a thickening of the intra-articular membrane. This inflammatory thickening promotes chondrocyte death and consequent reactive action to the thickening and disorganization of bone trabeculae, decreasing joint space. The temperature rises during the inflammatory process. And, probably the action of ultrasound interferes with the development of the arthritic process. As well as the apitoxin used topically. But, when we numerically analyze this process, the apitoxin transmitted through ultrasound numerically appears to present more relevant results. Although the joint spaces are enlarged in relation to the negative control.

**Table 3.** Summary of explanatory figures 1 and 2.

DAYS	GROUP I	GROUP II	GROUP III	GROUP IV	GROUP V
3 days	Contours intact, preserved joint structures	Thickening of the synovial membrane	Intra-periarticular had decreased;	A decreased in intra-periarticular edema;	Had complete resolution of synovitis
7 days		Early demineralization with collapsed patella in the femoral space	Contours become to get clearer;	Contours become sharper;	Contour of the distal fêmur began to take shape;
14 days		Tibial plateau loses contour, calcification of soft tissue intra-articular;	Diferent contours in the joint region with signs of bone regeneration	Showed signs of bone regeneration.;	Distal fêmur delineated, more mineralized
21 days		Osteoporosis image, visible trabeculae, without patella fêmur space (Figure 2).	Increasing space between patella and femur (Figura 3).	Increasing space between patella and femur (Figure 4).	No signs of arthrosis or thickening (Figure 5).

Source: Authors.

#### 4. Discussion

In this study, we investigated the effects of ultrasound-borne arthritis-induced apitoxin. The association was assessed using an experimental model of arthritis. After several trials, testing an ideal induction agent, we chose an arthritis-induced Wistar rat model that we used for its ease of acquisition and management. And from this demand, the authors became aware of the experimental arthritis-inducing agent, zymosan.

Polysaccharide derived from the yeast *Saccharomyces cerevisiae*, whose administration into tissues promotes an intense inflammatory reaction. This model is widely used to test the effectiveness of drugs. (Di Carlo *et al.*, 1981). One of the first signs of the appearance of a lesion caused by joint inflammation induced by Zymosan is the depletion of PGs in the cartilaginous matrix, which induces a progressive and irreversible damage of the affected joint, confirmed by X-ray images (Moreira & Carvalho, 2001). Researchers working with zymosan-induced arthritis observed (presence of osteophytes on radiographic examination, and desquamation, ulceration and cartilaginous cleft, disorganization of columns and chondrocyte niches on histological examination were consistent with osteoarthritis or degenerative joint disease, as verified by Marshall, (1969); Pond & Nuki, (1973); Lipowitz *et al.*, (1985); Altman *et al.*, (1989a and b); Biasi *et al.*, (2004).

Radiological manifestations of rheumatoid arthritis indicate soft tissue thickening with periarticular involvement, osteopenia, osteoporosis in more advanced stages, reduction of joint spaces, subchondral erosion, bone cyst represented by translucent subchondral areas and if the invasion of the rheumatoid pannus (Moreira, 2001; Cohen *et al.*, 2015). Joint destruction and interference in the inflammatory process were followed by the authors (Keystone *et al.*, 1997; Gegout *et al.*, 1995; Lee, 2004) through the different mediators involved in these events. In cartilage injury by zymosan, there are histopathological, immunohistochemical and biochemical changes that apply to the experimental study of RA and, in part, meet the minimum requirements proposed by Oliver and Brahne in 1996 for the study of human disease models. in animals.

The study of these mechanisms can contribute to an approach with physiotherapeutic resources and an effective alternative way to ensure success in choosing the treatment protocol. (Gegot *et al.*, 1995). In this study, when analyzing the radiographic images, the authors observed that the control group presented clear and distinct contours of joint prehension, with preserved structures. Radiographic images of the induced group (Azy) were found, erosion of the surfaces suggesting cartilage destruction followed by bone resorption. Several authors who also worked with these models were able to demonstrate the



induction of these radiological findings in their studies (Bradshaw *et al.*, 1994; Biasi *et al.*, 2004; Morsoleto *et al.*, 2007). In the face of these destructive inflammatory episodes, researchers strive to study the mechanisms that may influence the course of autoimmune diseases (Van den Berg, 2005). Following the methodological design of this study, a group of animals was treated with topical and apitoxin doses via phonophoresis (Williams, 1990), ultrasound drug placement (Morsoleto, 2003). The aim was to produce primary or immediate effects on the joint, increasing cellular metabolism, endorphin synthesis and decreasing the release of nociceptive transmitters (bradykinin and serotonin). objective remission of the inflammatory state, thereby reducing pain and job performance (Kwon Young-bae, 2001).

At the apitoxin doses observed in this work, the rapid regression of the inflammatory signs of inflammation, which are compatible with the aspects present in the healthy control group (Zhang *et al.*, 2018). In 1979, studies conducted by Chang & Bliven observed that bee venom reduced inflammation in arthritic rats and, in another experiment, prevented the development of arthritis when administered a single dose of an apitoxin subcutaneously 24 hours before of the introduction of the substance that induces arthritis (Cerqueira *et al.*, 2021) Also in the study carried out by Broadman and Beck 1997; Lorenzetti, & Busby, 1972; Lee *et al.*, 2004, apitoxin effectively suppressed the arthritis development. Leading researchers to conclude that substances such as histamine, lecithinase, hyaluronidase, exerted therapeutic action, although all the mechanisms of this action are not yet known (Wehbe, 2019). These compounds have the action of nonspecific proteins that alter the sensitivity and the body's immunological mechanisms are also present in melittin with high anti-inflammatory action. The peptides responsible for the degranulation of mast cells (the body's immune cells). Apamine which blocks Ca<sup>2+</sup>/K during synaptic transmission channels in nerves (Sokol *et al.*, 1994; Wadsworth *et al.*, 1994; Xu, & Nelson, 1994) Hyaluronidase, Adopamine a neurotransmitter that increases motor activity and Adolapine (neurotransmitter) with analgesic effect (Simic, 2005; Jang, 2020; Weis, 2022).

## 5. Conclusion

Zymosan caused an intra-articular inflammatory process observed by the reduction of the intra-articular space and synovial thickening through radiographic images. Ultrasound combined with apitoxin via phonophoresis was efficient in tissue repair and subsequent regeneration of joint contours when compared only with the application of topical apitoxin ultrasound. More research should be performed for further clarification.

The authors hope that future research can be developed so that the material conveyed to the interior of the joint through the ultrasonic waves can be analyzed biochemically.

## Acknowledgments

We thank Prof. Dr. Maria José M. S. Morsoleto for guiding this project. We also thank the Herminio Ometto Foundation for supporting the research as well as the use of its facilities.

## References

- Acheta, J., Stephens, S. B. Z., Belin, S., & Poitelon, Y. (2022). Therapeutic Low-Intensity Ultrasound for Peripheral Nerve Regeneration - A Schwann Cell Perspective. *Front Cell Neurosci.* 15:812588. [10.3389/fncel.2021.812588](https://doi.org/10.3389/fncel.2021.812588).
- Altman, R. D., Dean, D. D., Muniz, O. E., & Howell, D. S. (1989). Prophylactic treatment of canine osteoarthritis with glycosaminoglycan polysulfuric acid ester. *Arthritis & Rheumatism*, 32, 759-66, 1989a.
- Altman, R. D., Dean, D. D., Muniz, O. E., & Howell, D. S. (1989). Therapeutic treatment of canine osteoarthritis with glycosaminoglycan polysulfuric acid ester. *Arthritis & Rheumatism*, 32, 1300-7, 1989b.
- Baranowski, D. C., Buchanan, B., Dwyer, H. C., Gabriele, J. P., Kelly, S., & Araujo, J. A. (2018). Penetration and efficacy of transdermal NSAIDs in a model of acute joint inflammation. *Journal of pain research*, 11, 2809–2819. <https://doi.org/10.2147/JPR.S177967>
- Beck, B. F. (1997). *The bible of bee venom therapy: bee venom, its nature, and its effect on arthritic and rheumatoid conditions*. Health Resources Press, 260p.

- Bradshaw, J. P., Dempsey, C. E., & Watts, A. (1994). A combined X-ray and neutron diffraction study of selective deuterated melittin in phospholipid bilayers: Effect of pH. *Molecular Membrane Biology*, 11(1), 79-86
- Broadman, J. Bee venom (1997): the natural curative for arthritis and rheumatism. *Health Resources Press*, 220p.
- Cerqueira, R. G. M., Ibiapina, S. I. O., Moreira, M. C., Pereira, L. V. A. C., Silva, L. C., Sá, M. C., Rocha, I. M., Reis, L. C. M., Sousa, M. A. A., Monteiro, A. L., Castro, S. A. D., Rodrigues, A. C. E., & Silva, F. L. (2021). Apitoxin as an auxiliary tool in prophylaxis of infection against SARS-CoV-2. *Research, Society and Development*, 10(16), e248101623803. <https://doi.org/10.33448/rsd-v10i16.23803>
- Chang, Y.H., & Bliven, M.L. (1979). Anti-arthritis effect of bee venom. *Agents Actions* 9:205- 211.
- Cohen, G., Natsheh, H., Sunny, Y., Bawiec, C. R., Touitou, E., Lerman, M. A., Lazarovici, P., & Lewin, P. A. (2015). Enhanced therapeutic anti-inflammatory effect of betamethasone on topical administration with low-frequency, low-intensity (20 kHz, 100 mW/cm<sup>2</sup>) ultrasound exposure on carrageenan-induced arthritis in a mouse model. *Ultrasound in medicine & biology*, 41(9), 2449–2457. <https://doi.org/10.1016/j.ultrasmedbio.2015.04.009>
- Di Carlo F. J., & Fiore J. V. (1958).; *In Zymosan Composition*.Sci. 1958, 127:756-757.11. Fleiss, J.L. (1981). *Statistical Methods for Rates and Proportions*.2<sup>nd</sup> ed. John Wiley & Sons Inc. Nova Iorque.
- El Mehdi, I., Falcão, S. I., Harandou, M., Boujraf, S., Calhella, R. C., Ferreira, I., Anjos, O., Campos, M. G., & Vilas-Boas, M. (2021). Chemical, Cytotoxic, and Anti-Inflammatory Assessment of Honey Bee Venom from *Apis mellifera intermissa*. *Antibiotics (Basel, Switzerland)*, 10(12), 1514. <https://doi.org/10.3390/antibiotics10121514>
- F. De Biasi., S. C. Rahal., R. dos S. Volpi., M. J. Mamprim., J. L. Sequeira., F. M. M. Bergamo. (2004). Utilização do sulfato de condroitina no tratamento de osteoartrite induzida experimentalmente em Joelho de cães. *ARS VETERINARIA*, Jaboticabal, SP, Vol. 20, nº 2, 219-227
- Fraenkel, L., Bathon, J. M., England, B. R., St Clair, E. W., Arayssi, T., Carandang, K., Deane, K. D., Genovese, M., Huston, K. K., Kerr, G., Kremer, J., Nakamura, M. C., Russell, L. A., Singh, J. A., Smith, B. J., Sparks, J. A., Venkatachalam, S., Weinblatt, M. E., Al-Gibbawi, M., Baker, J. F., & Akl, E. A. (2021). 2021 American College of Rheumatology Guideline for the Treatment of Rheumatoid Arthritis. *Arthritis & rheumatology (Hoboken, N.J.)*, 73(7), 1108–1123. <https://doi.org/10.1002/art.41752>
- Gabay, C., Hasler, P., Kyburz, D., So, A., Villiger, P., von Kempis, J., & Walker, U. (2014). Biological agents in monotherapy for the treatment of rheumatoid arthritis. *Swiss Med. Wkly.* 4, 144, w13950.
- Gegout P., Gillet, P., Terlain, B., & Netter, P.(1995): Zymosan induced arthritis in rats II. Effects of antiinflammatory drugs. *Life Sci* 56: 389-394, 1995
- Jang, S., & Kim, K. H. (2020). Clinical Effectiveness and Adverse Events of Bee Venom Therapy: A Systematic Review of Randomized Controlled Trials. *Toxins*, 12(9), 558. <https://doi.org/10.3390/toxins12090558>
- Keystone, E. C., Schorlemmer, H. U., Pope, C., & Allison, A. C.(1977). Zymosan induced arthritis: a model of chronic proliferative arthritis following activation of the alternative pathway of complement. *Arthritis Rheum* 20: 1397-1401
- Kurkó, J., Besenyei, T., Laki, J., Glant, T. T., Mikecz, K & Szekanecz, Z. (2013). Genetics of rheumatoid arthritis - a comprehensive review. *Clinical reviews in allergy & immunology*, 45(2), 170–179. <https://doi.org/10.1007/s12016-012-8346-7>
- Leão G, Leite D, & Rocha L. S.(2005) Apitoxina. *Unimontes Montes Claros*, 7(1)
- Lee, Y. M., Cho, S. N., Son, E., Song, C. H., & Kim, D. S. (2020). Apamin from bee venom suppresses inflammation in a murine model of gouty arthritis, *Journal of Ethnopharmacology*, 257, 112860, <https://doi.org/10.1016/j.jep.2020.112860>
- Lee, J. D., Kim, S. Y., Kim, T. W., Lee, S. H., Yang, H. L., Lee, D. L., & Lee, Y. H. (2004). Anti-inflammatory effect of bee venom on type II collagen-induced arthritis. *American Journal of Chinese Medicine*, 32(3), 361-367
- Lipowitz, A. J., Wong, P. L., & Stevens, J. B. (1985). Synovial membrane changes after experimental transection of the cranial cruciate ligament in dogs. *American Journal of Veterinary Research*, v.46, p.1166-70.
- Lorenzetti, G. J., Fortenberry, B., & Busby, E.(1972). Influence of bee venom in the adjuvantinduced arthritic rat model. *Res Comm Chem Pathol Pharmacol* 4(2):4,339
- Madzia, A., Agrawal, C., Jarit, P., Petterson, S., Plancher, K., & Ortíz, R. (2020). Sustained Acoustic Medicine Combined with A Diclofenac Ultrasound Coupling Patch for the Rapid Symptomatic Relief of Knee Osteoarthritis: Multi-Site Clinical Efficacy Study. *The open orthopaedics journal*, 14, 176–185. <https://doi.org/10.2174/1874325002014010176>
- Maia, A. B. R. A., & Rocha, M. P. S.( 2002). *Fracionamento e Caracterização da apitoxina*. Mensagem Doce, Apacame, São Paulo.
- Marshall, J. L. (1969). Periarticular osteophytes. Initiation and formation in the knee of the dog. *Clinical Orthopaedics & Related Research*, (62), 37-47.
- Moreira, C., & Carvalho, M. A. P. (2001). *Reumatologia - Diagnóstico e Tratamento*. 2a ed. Rio de Janeiro (RJ): Médica e Científica, 371-89
- Moreno, M., & Giralt, E. (2015). Three Valuable Peptides from Bee and Wasp Venoms for Therapeutic and Biotechnological Use: Melittin, Apamin and Mastoparan. *Toxins*, 7, 1126-1150; 10.3390/toxins7041126
- Morsoleto, M. J. M. S., Morsoloto, F., Alves de Matos, A., Morgado, F., & Anaruma, C. (2015). A Study of the Effects of Phonophoretic Application of Hydrocortisone on the Regeneration of Injuries to Skeletal Muscle. *Microscopy and Microanalysis*, 21(S5), 77-78. 10.1017/S1431927615014191
- Morsoleto, M. J. M. S., Reis R. R., Amstalden, E. M. I., & Bertolo, M. B. (2007). Clinical and morphologic evolution of the induced experimental artrite in *Rattus norvegicus albinus* to wistar, *Braz. J. Morphol. Sci*, 24 (2), 75-81

- Morsoleto, M. J. M. S., (2003). Transmissão de produtos farmacêuticos tópicos através de energia ultra-sônica na regeneração de lesões da musculatura esquelética – enfoque morfológico *Unesp/RC*
- Nader, R. A., Mackieh, R., Wehbe, R., El Obeid, D., Sabatier, J. M., & Fajloun, Z. (2021). Beehive Products as Antibacterial Agents: A Review. *Antibiotics*, 10(6), 717. <https://doi.org/10.3390/antibiotics10060717>
- Oliver S. J., & Brahn, E. (1996). Combination therapy in rheumatoid arthritis: the animal model perspective. *J Rheum* 23 (Supl 24): 56-60
- Orr, C., Vieira-Sousa, E., Boyle, D. L., Buch, M. H., Buckley, C. D., Cañete, J. D., Catrina, A. I., Choy, E., Emery, P., Fearon, U., Filer, A., Gerlag, D., Humby, F., Isaacs, J. D., Just, S. A., Lauwerys, B. R., Le Goff, B., Manzo, A., McGarry, T., McInnes, I. B., & Tas, S. W. (2017). Synovial tissue research: a state-of-the-art review. *Nature reviews. Rheumatology*, 13(8), 463–475. <https://doi.org/10.1038>
- Pond, M. J., & Nuki, G. (1973). Experimentally-induced osteoarthritis in the dog. *Annals of the Rheumatic Diseases*, 32, 387-8.
- Reitman, M. L. (2018). Of mice and men – environmental temperature, body temperature, and treatment of obesity. *FEBS Letters*, 592(12), 2098-2107. <https://doi.org/10.1002/1873-3468.13070>
- Saliba, S., Mistry, D. J., Perrin, D. H., Gieck, J., & Weltman, A. (2007). Phonophoresis and the absorption of dexamethasone in the presence of an occlusive dressing. *Journal of athletic training*, 42(3), 349–354
- Sato, M., Nagata, K., Kuroda, S., Horiuchi, S., Nakamura, T., Karima, M., Inubushi, T., & Tanaka, E. (2014). Low-intensity pulsed ultrasound activates integrin-mediated echanotransduction pathway in synovial cells. *Ann Biomed Eng*. Oct;42(10):2156-63. 10.1007/s10439-014-1081-x
- Shinjo, S. K., Moreira, C. (2021). *Livro da Sociedade Brasileira de Reumatologia*, (2a ed.), ed Manole.
- Simics, M. (2005). Symptoms of honeybee venom. *Apitronic services*.
- Silva, A. N. G., Oliveira, J. R. S., Madureira, Álvaro N. de M., Lima, W. A., Silva, A. P. S. & Lima, V. L. M. (2021). Muscle regeneration mechanisms stimulated by ultrasound therapy. *Research, Society and Development*, 10(12), e579101221044. <https://doi.org/10.33448/rsd-v10i12.21044>
- Silvano, D. A., Ferreira, S. K., Frade, I. R., & Ribeiro, A. O. M. (2020). Uso da apitoxina como recurso terapêutico para a artrite reumatoide: uma revisão integrativa. *NBC*, 10(19), 108
- Sokol, P. T., Hu, W., Yi, L., Toral, J., Chandra, M., & Ziai, M.R. (1994) Cloning of an apamin binding protein of vascular smooth muscle. *Journal of Protein Chemistry*, 13(1), 117-128.
- Sun, L., An, S., Zhang, Z., Zhou, Y., Yu, Y., Ma, Z., Fan, X., Tang, L. & Guo, J. (2021). Molecular and Metabolic Mechanism of Low-Intensity Pulsed Ultrasound Improving Muscle Atrophy in Hindlimb Unloading Rats. *International Journal of Molecular Sciences*, 22(22), 12112. <https://doi.org/10.3390/ijms222212112>
- Van den Berg, W. B. (2005) Animal models of arthritis. What have we learned? *J Rheumatol Suppl*. 2005 Jan;72:7-9
- Wadsworth, J. D. F., Doorty, K. B., & Srong, P.N. (1994). Comparable 30-kDa apamin binding olypeptides may fulfill equivalent roles within putative subtypes of small conductance Ca-2- activated K/ channels. *Journal of Biological Chemistry*, v.269, n.27, p. 18053-18061
- Watanabe, M., Kojima, S. & Hoso, M. (2017). Effect of low-intensity pulsed ultrasound therapy on a rat knee joint contracture model. *Journal of physical therapy science*, 29(9), 1567–1572. <https://doi.org/10.1589/jpts.29.1567>
- Wehbe, R., Frangieh, J., Rima, M., El Obeid, D., Sabatier, J.-M. & Fajloun, Z. (2019). Bee Venom: Overview of Main Compounds and Bioactivities for Therapeutic Interests. *Molecules*, 24(16), 2997. <https://doi.org/10.3390/molecules24162997>
- Weis, W. A., Ripari, N., LopesConte, F., da Silva Honorio, M., Alves Sartori, A., HageMatucci, R., & José Mauricio,Sforcin, J. (2022). An overview about apitherapy and its clinical applications. *Phytomedicine Plus*. 2(2)
- William, A. R. (1990) Phonophoresis: an in vivo. Evaluation using three topical anesthetic. *Ultrasonic*. 28:137-141. 10.1016/0041-624x(90)90075-y
- Xu, X., & Nelson, J.W. (1994). One-disulfide intermediates of apamin exhibit native-like structure. *Biochemistry*, 33(17), 5253-5261.
- Young-bae K., et al., (2001). Bee venom injection into an acupuncture point reduces arthritis associated edema and nociceptive responses. *Pain*. 90, (3), 271-280
- Zhang, S., Liu, Y., Ye, Y., Wang, X. R., Lin, L. T., Xiao, L. Y., Zhou, P., Shi, G. X., & Liu, C. Z. (2018). Bee venom therapy: Potential mechanisms and therapeutic applications. *Toxicon*, 148, 64–73. <https://doi.org/10.1016/j.toxicon.2018.04.012>