

Measurement analysis of the mandible body using CBCT images in the mental foramen region to determine sexual dimorphism

Análise da mensuração do corpo da mandíbula usando imagens de TCFC na região do forame mental para determinar o dimorfismo sexual

Análisis de la medición del cuerpo mandibular utilizando imágenes CBCT en la región del foramen mentoniano para determinar el dimorfismo sexual

Received: 05/20/2022 | Reviewed: 06/12/2022 | Accept: 06/14/2022 | Published: 06/15/2022

Paulo Roberto Vieira Martins

ORCID: <https://orcid.org/0000-0002-6278-2904>

University of São Paulo, Brazil

E-mail: paulo.roberto.martins@usp.br

Maria José Souza Schües

ORCID: <https://orcid.org/0000-0002-9034-8531>

University of São Paulo, Brazil

E-mail: schues.mariajose@gmail.com

Edna Alejandra Gallardo Lopez

ORCID: <https://orcid.org/0000-0002-3312-1939>

University of São Paulo, Brazil

E-mail: edna.gallardo@gmail.com

Ana Luiza Esteves Carneiro

ORCID: <https://orcid.org/0000-0002-3799-5043>

University of São Paulo, Brazil

E-mail: ana.esteves.carneiro@usp.br

Daniela Miranda Richarte de Andrade Salgado

ORCID: <https://orcid.org/0000-0003-4646-7389>

University of São Paulo, Brazil

E-mail: daniricharte@usp.br

Claudio Costa

ORCID: <https://orcid.org/0000-0003-2831-8670>

University of São Paulo, Brazil

E-mail: clacosta@usp.br

Abstract

The purpose of this study was to assess the distance between the mandibular canal and the base of the mandible in the mental foramen region, in order to determine sexual dimorphism in the Brazilian population. The assessment of this distance is also important to prevent injuries to the inferior alveolar neurovascular bundle and to avoid clinical complications during surgical procedures. Using the simplified Kalabalik and Aytuğarn method for studies in Forensic Dentistry or Anatomy, this study assessed 100 cone-beam computed tomography images of male and female patients. The distance between the inferior border of the mandibular canal and the base of the mandible in the mental foramen region was evaluated bilaterally. No significant statistical differences were found between the right and left sides of the mandible. However, statistically significant difference between the genders was found ($p=0.038$). The lower distance (D2) measure can be applied to determine sexual dimorphism in the Brazilian population. Further studies presenting larger samples are needed to confirm these initial findings.

Keywords: Cone-Beam Computed Tomography; Mandibular nerve; Mandible.

Resumo

O objetivo desse estudo foi determinar a distância entre o canal mandibular e a base da mandíbula na região do forame mental para determinar o dimorfismo sexual na população brasileira. Essa avaliação é importante para prevenir lesões no nervo alveolar inferior, evitando complicações clínicas durante procedimentos cirúrgicos mandibulares. Utilizando o método simplificado de Kalabalik and Aytuğarn para estudos em Odontologia Forense ou Anatomia, o estudo utilizou 100 imagens de tomografia computadorizada de feixe cônico de pacientes de ambos os sexos. A distância entre a borda inferior do canal da mandíbula e a base da Mandíbula obtidas nas regiões do forame mental foi avaliada bilateralmente. Não houve diferenças estatísticas significantes entre os lados direito e esquerdo da mandíbula. No entanto, houve diferença estatística significativa entre os sexos ($p=0,038$). A medida da distância

inferior (D2) pode ser aplicada para determinar o dimorfismo sexual na população brasileira. Estudos com amostras maiores são necessários para confirmar os achados iniciais.

Palavras-chave: Tomografia Computadorizada de Feixe Cônico; Nervo mandibular; Mandíbula.

Resumen

El objetivo de este estudio fue determinar la distancia entre el canal mandibular y la base de la mandíbula en la región del agujero mentoniano para determinar el dimorfismo sexual en la población brasileña. Esta evaluación es importante para prevenir lesiones del nervio alveolar inferior, evitando complicaciones clínicas durante los procedimientos quirúrgicos mandibulares. Utilizando el método simplificado de Kalabalik y Aytuğarn para estudios en Odontología Forense o Anatomía, el estudio utilizó 100 imágenes de Tomografía computarizada de haz cónico de pacientes de ambos sexos. La distancia entre el borde inferior del canal mandibular y la base de la mandíbula obtenidos en las regiones del foramen mental se evaluó de forma bilateral. No hubo diferencias estadísticas significativas entre los lados derecho e izquierdo de la mandíbula. Sin embargo, hubo una diferencia estadísticamente significativa entre los sexos ($p=0,038$). La medida de distancia inferior (D2) se puede aplicar para determinar el dimorfismo sexual en la población brasileña. Se necesitan estudios con muestras más grandes para confirmar los hallazgos iniciales.

Palabras clave: Tomografía Computarizada Haz Cónico; Nervo mandibular; Mandibular.

1. Introduction

The mandibular canal (MC) is an anatomical structure located within the internal aspect of the mandible. It begins its course in the mandibular foramen on the medial surface of the ascending mandibular ramus, runs obliquely downwards and forwards on the mandibular ramus, then horizontally forward on the mandible body to the mental foramen. The inferior alveolar nerve, the most important sensory nerve of the mandible, runs through the MC. During surgical procedures, the clinician must pay close attention to anatomical structures such as the MC, being aware of their precise position in order to avoid iatrogenic injuries such as severe post-operative pain, temporary numbness or even permanent loss of sensitivity (Kalabalik & Aytuğarn, 2019; Shaban et al., 2017; Tuditam et al., 2019; Zambrana et al., 2020).

The MC has important anatomical variations, such as foramina, accessory canals and bifurcations. The knowledge of these anatomical variations is extremely important, since the inferior alveolar nerve is a meaningful structure found in the mandible. Precisely in the lower premolar region, where the mental foramen and the final portion of the mandibular canal are located, some anatomical variations can be found, such as the anterior loop of the MC (inferior alveolar nerve path into the mandibular incisor canal) (Naitoh et al., 2009; Panjnoush et al., 2016; Vieira et al., 2018).

Conventional radiographic images such as periapical and panoramic radiographs are often unable to show the presence of bifurcations and anatomical variations of the MC (Zambrana et al., 2020). On the other hand, Cone Beam Computed Tomography (CBCT) is a novel imaging modality that allows the observation of anatomical structures without superposition and distortion, being a reliable and accurate gold standard method for obtaining linear measurements (Aljarbou et al., 2019).

The most common clinical procedures that can affect the inferior alveolar nerve are associated with needle-induced trauma after infiltration of local anesthetic (a reversible character), complications associated with extraction of third molars, and complications associated with implant placement, which may be reversible or not. Surgical techniques regarding bone maneuvers or manipulation of the lower alveolar nerve necessarily require previous tomographic assessment to ensure efficient and accurate surgical planning, once these types of procedures present a great risk of definitive paresthesia (Khorshidi et al., 2017; Velasco-Torres et al., 2017).

Studies regarding the MC anatomy and anatomical variations go beyond clinical surgical dentistry. The lower jaw is considered a strong bone and has great importance in forensic dentistry. The literature shows that linear measurements performed in different regions of the mandible body present considerable relevance in the identification of gender (Albalawi et al., 2019; Kalabalik & Aytuğarn, 2019).

The purpose of the present investigation was to assess the distance of the inferior border of the mandibular canal and the base of the mandible (lower distance) in the mental foramen region to verify sexual dimorphism, using CBCT images.

2. Methodology

Sample

This retrospective study was approved by the local Research Ethics Committee, under the ethics committee opinion number 3.239.265. This study was performed using CBCT images obtained from patients who needed the examination for different dental reasons. Images were obtained from the archive of the Laboratory for Analysis and Image Processing (LAPI) of the Discipline of Radiology, Stomatology Department, School of Dentistry of University of São Paulo, Brazil.

A total of 100 CBCT images were selected, being 50 female and 50 male patients, aged between 20 and 76 years. Images containing pathological findings or bone fractures were excluded of the study.

CBCT image parameters

The CBCT images were acquired on i-CAT Classic NG® unit (Imaging Sciences International, Inc., PA, USA) with the following parameters: voxel size 0.25 mm, 120 kVp, 5 mA, FOV of 13x16 cm and a 26,9-s scan time.

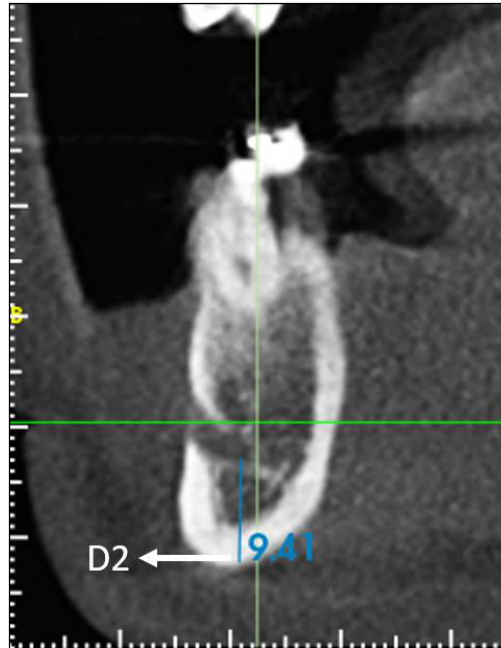
Image analysis

The volumetric data obtained from CBCT examinations was exported in DICOM format (Digital Imaging and Communications in Medicine) to dedicated software Xelis Dental® (Infinit, South Korea), where the measurements were obtained. The observer presented experience in cbct imaging, was previously calibrated and evaluated the images in a room under low light conditions.

The Kalabalik and Aytuğarn (2019) method was proposed to determine the location of the mandibular canal (MC) and mental foramen (MF). Four linear measurements were assessed: D1 (The distance from the superior border of the mandibular canal (MC) to the superior border of the alveolar process - upper distance), D2 (The distance from the inferior border of the MC to the inferior mandibular border - lower distance), D3 (The distance from the buccal border of the MC to the outer buccal margin of the mandible - buccal distance) and D4 (The distance from the lingual border of the MC and the lingual margin of the mandible - lingual distance) (Kalabalik & Aytuğarn, 2019).

An arch was drawn in the axial plane following the center of the mandible in order to obtain a panoramic reconstruction and cross-sectional slices. The panoramic reconstruction thickness was set at 30 mm, and the cross-sectional slices thickness was set at 1 mm. This study considered only the D2 measure = lower distance, obtained in the cross-sectional slice of the mental foramen region, bilaterally, aiming to assess a possible size difference found between sexes (Figure 1).

Figure 1. D2 measure - The distance from the inferior border of the MC to the inferior mandibular border - lower distance.



Source: Authors.

Statistical analysis

The results were tabulated on Microsoft Excel 2013 (Microsoft Corp., EUA) and statistical analysis of the data was performed using dedicated software SPSS 13.0 (Apache Software Foundation, Los Angeles, CA). The T test was used to evaluate measurement differences between sides and genders. For all analyses, statistical significance level was set at $p \leq 0.05$.

3. Results

A total of 100 cbct exams were included in the study. There were 50 (50%) males and 50 (50%) females, with age ranging from 20 to 76 years. D2 measure was obtained from the right and left sides of the mandible in the mental foramen region. No statistical differences were found for D2 measure between right and left side of the mandible in male ($p=0.088$) and female ($p=0.072$) patients (Table 1).

Table 1. Comparison of the D2 measurement on the right and left sides in the male and female groups.

	FEMALE (20-76 YEARS)	MALE (28-65 YEARS)
	Mean (SD)	Mean (SD)
RIGHT	8,86 (1,51)	9,00 (1,64)
LEFT	8,82 (1,55)	9,02 (1,62)
P-value	0,072	0,088

Source: Authors.

When the sexes were compared, significant differences were found on D2 measure ($p=0.038$). The male group showed higher mean values than the female group (Table 2).

Table 2. Comparison of the D2 measurement between the two sexes.

	FEMALE (20-76 YEARS) Mean (SD)	MALE (28-65 YEARS) Mean (SD)
	8,84 (1,53)	9,01 (1,63)
P-value	0,038	

Source: Authors.

4. Discussions

The MC carries the inferior alveolar nerve, one of the largest branches of the trigeminal nerve that presents great importance in the dental field, thus, dental surgeons must be aware of this anatomical and radiographic structure to avoid many surgical complications. The literature shows several studies describing the location of the MC in cadaveric materials, dry skull, panoramic radiographs, CT and CBCT scans, and some of these studies evaluated age and sexes (Albalawi et al., 2019; Aljarbou et al., 2019; Jang & Han, 2019; Khorshidi et al., 2017; Magat, 2020; Naitoh et al., 2009; Panjnoush et al., 2016; Shaban et al., 2017; Tudtiam et al., 2019; Vieira et al., 2018; Zambrana et al., 2020).

CBCT is considered an excellent imaging modality to assess maxillofacial anatomy, allowing preoperative examination of surgical sites using three-dimensional images (Tadinada et al., 2017; Vujanovic-Eskenazi, et al., 2015; Zambrana et al., 2020). When compared to conventional CT, CBCT offers high spatial resolution images at lower cost and lower radiation dose (Altun et al., 2018).

The position and course of MC and MF is important in surgical approaches. Some authors (Zmyslowska-Polakowska et al., 2019) reported that MF position depends on the ethnical origin of the patient and that males presented MF horizontal and vertical diameters significantly higher than females, corroborating with our results.

Three different types of MC were reported: a) catenary (a symmetric elliptic arc), b) progressive descending (a spoon-shape curve similar to a dissymmetry elliptic arc and c) straight type (linear pattern). Although the authors showed that the course and position of the MC were not affected by the sex, in male group the most frequent type was the catenary and in female group the most frequent type was progressive descending, considering the Iranian population (Mirbeigi et al., 2016). Other authors (Vieira et al., 2018) used the same classification and showed that in Brazilian population the most frequent MC course was the straight type, with no significant differences between the sexes. The MC morphology and position can vary in different groups and, if left unseen, these anatomical variations may cause post-operative problems (Anbiaee et al., 2015).

According to the Kalabalik's et al. (2019), the MC was vertically located nearby to the inferior cortical border of the mandible, and horizontally nearby to the lingual border of the mandible. The authors also found that D2 measure was significantly greater in males than females, bilaterally. Khorshid et al. (2017) reported that mean bone thickness of the female group was significantly smaller than the male group, in vertical and horizontal planes, and showed that the lower distance (D2) was significantly lower in female group, agreeing with the results of this study.

Linear measurements applied to cbct images are easy to reproduce and allow morphological analysis with results similar to real measurements. Linear CBCT measurements (D2) were significantly lower in women, and no differences were found between left and right sides. However, D2 measurements could be affected by the presence of anatomical variations regarding MC position (Mirbeigi et al., 2016).

These results can be justified by the presence of bone morphological differences between sexes, showing that men tend to present measurements of larger physical dimensions than women. A limitation of this study lies on the fact that the presence of hormonal changes in the female group was not evaluated, and the literature shows that women in the climacteric phase can begin to present bone resorption, which could imply in smaller measures (Calciolari et al., 2015).

5. Conclusion

The D2 in women was significantly smaller than in men, thus this measure can be used to determine sexual dimorphism in CBCT images. Further studies with larger sample, clinical information and more observers are necessary to confirm these initial findings.

References

- Albalawi, A. S., Alam, M. K., Vundavalli, S., Ganji, K. K., & Patil, S. (2019). Mandible: An Indicator for Sex Determination - A Three-dimensional Cone-Beam Computed Tomography Study. *Contemp Clin Dent*, 10(1), 69-73. 10.4103/ccd.ccd_313_18
- Aljarbou, F. A., Aldosimani, M., Althumairy, R. I., Alhezam, A. A., & Aldawsari, A. I. (2019). An analysis of the first and second mandibular molar roots proximity to the inferior alveolar canal and cortical plates using cone beam computed tomography among the Saudi population. *Saudi Med J*, 40(2), 189-194.
- Altun, O., Miloğlu, Ö., Dedeoğlu, N., Duman, Ş., & Törenek, K. (2018). Evaluation of localisation of mandibular foramen in patients with mandibular third molar teeth using cone-beam computed tomography. *Folia Morphol (Warsz)*, 77(4), 717-723. 10.5603/FM.a2018.0044
- Anbiaee, N., Eslami, F., & Bagherpour, A. (2015). Relationship of the Gonial Angle and Inferior Alveolar Canal Course Using Cone Beam Computed Tomography. *J Dent (Tehran)*, 12(10), 756-763.
- Calciolari, E., Donos, N., Park, J. C., Petrie, A., & Mardas, N. (2015). Panoramic measures for oral bone mass in detecting osteoporosis: a systematic review and meta-analysis. *J Dent Res*, 94(3 Suppl), 17S-27S. 10.1177/0022034514554949
- Jang, H. Y., & Han, S. J. (2019). Measurement of mandibular lingula location using cone-beam computed tomography and internal oblique ridge-guided inferior alveolar nerve block. *J Korean Assoc Oral Maxillofac Surg*, 45(3), 158-166. 10.5125/jkaoms.2019.45.3.158
- Kalabalik, F., & Aytuğar, E. (2019). Localization of the Mandibular Canal in a Turkish Population: a Retrospective Cone-Beam Computed Tomography Study. *J Oral Maxillofac Res*, 10(2), e2. 10.5037/jomr.2019.10202
- Khorshidi, H., Raoofi, S., Ghapanchi, J., Shahidi, S., & Paknahad, M. (2017). Cone Beam Computed Tomographic Analysis of the Course and Position of Mandibular Canal. *J Maxillofac Oral Surg*, 16(3), 306-311. 10.1007/s12663-016-0956-9
- Magat, G. (2020). Radiomorphometric analysis of edentulous posterior mandibular ridges in the first molar region: a cone-beam computed tomography study. *J Periodontal Implant Sci*, 50(1), 28-37. 10.5051/jpis.2020.50.1.28
- Mirbeigi, S., Kazemipoor, M., & Khojastepour, L. (2016). Evaluation of the Course of the Inferior Alveolar Canal: The First CBCT Study in an Iranian Population. *Pol J Radiol*, 81, 338-341. 10.12659/PJR.896229
- Naitoh, M., Hiraiwa, Y., Aimiya, H., Gotoh, K., & Arijji, E. (2009). Accessory mental foramen assessment using cone-beam computed tomography. *Oral Surg Oral Med Oral Pathol Oral Radiol Endod*, 107(2), 289-294. 10.1016/j.tripleo.2008.09.010
- Panjnoush, M., Rabiee, Z. S., & Kheirandish, Y. (2016). Assessment of Location and Anatomical Characteristics of Mental Foramen, Anterior Loop and Mandibular Incisive Canal Using Cone Beam Computed Tomography. *J Dent (Tehran)*, 13(2), 126-132.
- Shaban, B., Khajavi, A., Khaki, N., Mohiti, Y., Mehri, T., & Kermani, H. (2017). Assessment of the anterior loop of the inferior alveolar nerve via cone-beam computed tomography. *J Korean Assoc Oral Maxillofac Surg*, 43(6), 395-400. 10.5125/jkaoms.2017.43.6.395
- Tadinada, A., Schneider, S., & Yadav, S. (2017). Evaluation of the diagnostic efficacy of two cone beam computed tomography protocols in reliably detecting the location of the inferior alveolar nerve canal. *Dentomaxillofac Radiol*, 46(5), 20160389. 10.1259/dmfr.20160389
- Tudtiam, T., Leelarungsun, R., Khoo, L. K., Chaiyasamut, T., Arayasantiparb, R., & Wongsirichat, N. (2019). The Study of Inferior Alveolar Canal at the Lower Third Molar Apical Region With Cone Beam Computed Tomography. *J Clin Med Res*, 11(5), 353-359. 10.14740/jocmr3794
- Velasco-Torres, M., Padiál-Molina, M., Avila-Ortiz, G., García-Delgado, R., Catena, A., & Galindo-Moreno, P. (2017). Inferior alveolar nerve trajectory, mental foramen location and incidence of mental nerve anterior loop. *Med Oral Patol Oral Cir Bucal*, 22(5), e630-e635. 10.4317/medoral.21905
- Vieira, C. L., Veloso, S. D. A. R., & Lopes, F. F. (2018). Location of the course of the mandibular canal, anterior loop and accessory mental foramen through cone-beam computed tomography. *Surg Radiol Anat*, 40(12), 1411-1417. 10.1007/s00276-018-2081-6
- Vujanovic-Eskenazi, A., Valero-James, J. M., Sánchez-Garcés, M. A., & Gay-Escoda, C. (2015). A retrospective radiographic evaluation of the anterior loop of the mental nerve: comparison between panoramic radiography and cone beam computerized tomography. *Med Oral Patol Oral Cir Bucal*, 20(2), e239-245. 10.4317/medoral.20026
- Zambrana, J. R. M., Carneiro, A. L. E., Zambrana, N. R. M., Neto, H. T., Salgado, D. M. R. A., Ribeiro, R. A., & Costa, C. (2020). Lingual Lateral Canal Mimicking Mandible Fracture. *J Craniofac Surg*, 31(5), e509-e511. 10.1097/SCS.0000000000006678
- Zmyslowska-Polakowska, E., Radwanski, M., Ledzion, S., Leski, M., Zmyslowska, A., & Lukomska-Szymanska, M. (2019). Evaluation of Size and Location of a Mental Foramen in the Polish Population Using Cone-Beam Computed Tomography. *Biomed Res Int*, 2019, 1659476. 10.1155/2019/1659476