

Evaluation of surgery indication of cold knife conization and anatomopathological reports in patients with cervical squamous intraepithelial lesion or cervical cancer

Avaliação da indicação cirúrgica de conização clássica e resultados anatomopatológicos em pacientes com lesão intraepitelial cervical ou câncer do colo do útero

Evaluación de la indicación quirúrgica de conización e informes anatomopatológicos en pacientes con lesión intraepitelial escamosa cervical o cáncer de cuello uterino

Received: 05/31/2022 | Revised: 06/10/2022 | Accepted: 06/18/2022 | Published: 10/04/2022

Barbara Bomfim Muniz Moraes

ORCID: <https://orcid.org/0000-0002-5140-7957>
Universidade Federal de São Paulo, Brazil
E-mail: barbarabomfim94@gmail.com

Maria Gabriela Baumgarten Kuster Uyeda

ORCID: <https://orcid.org/0000-0003-4189-3645>
Universidade Federal de São Paulo, Brazil
E-mail: gabrielakuster@gmail.com

Patrícia Napoli Belfort Mattos

ORCID: <https://orcid.org/0000-0002-3267-7935>
Universidade Federal de São Paulo, Brazil
E-mail: drapatricianapoli@gmail.com

Bruna Cristine de Almeida

ORCID: <https://orcid.org/0000-0003-1641-5609>
Universidade de São Paulo, Brazil
E-mail: bruc_10@hotmail.com

Madalena Leonor Pereira Campos

ORCID: <https://orcid.org/0000-0002-4410-2477>
Universidade Federal de São Paulo, Brazil
E-mail: madalena_campos@hotmail.com

Gustavo Rubino de Azevedo Focchi

ORCID: <https://orcid.org/0000-0002-5978-0879>
Universidade Federal de São Paulo, Brazil
E-mail: gustavo.focchi@terra.com.br

Neila Maria Góis Speck

ORCID: <https://orcid.org/0000-0002-3713-5393>
Universidade Federal de São Paulo, Brazil
E-mail: nezespeck@uol.com.br

Fernanda Kesselring Tso

ORCID: <https://orcid.org/0000-0002-7900-8018>
Universidade Federal de São Paulo, Brazil
E-mail: fernandaktso@gmail.com

Abstract

The objective of this study was to evaluate the concordance between indication of cold knife conization by cervical cytology (CC), biopsy, or large loop excision of the transformation zone (LLETZ), and the anatomopathological report of surgical specimens of patients with precancerous lesions of the cervix or cervical cancer. In addition, to observe the presence of residual lesion after LLETZ in cases of microinvasive squamous cell carcinoma (SCC) and margins with high-grade squamous intraepithelial lesion (HSIL). To this end, a retrospective study was conducted involving 82 women with cervical intraepithelial lesions or cancer aged between 28 and 71 years. Women had either CC, biopsy, or LLETZ between January 2014 and January 2020 and had cold knife conization indicated according to procedure results. Surgical indication was the result of CC in 30.5% of patients; in 12.2%, it was due to cervical biopsy, and in 24.4% of cases, it was due to CC confirmed by biopsy. Moreover, 32.9% of patients had the surgery done because of compromised margins after LLETZ procedure. Agreement was found in 57.3% of surgical indications, and 42.7% did not show concordance. Residual lesion was observed in 55.6% of women who underwent LLETZ, but in the group of microinvasive squamous cell carcinoma (SCC), there was a rate of 60% of no residual lesion. Therefore, it indicates that LLETZ appears to be an effective treatment for microinvasive SCC of the cervix, and a complementary surgery with cold knife conization seems not to be required when there are compromised margins with HSIL.

Keywords: Squamous intraepithelial lesions of the cervix; Uterine cervical neoplasms; Conization.

Resumo

O objetivo desse trabalho fundamentou-se em avaliar a concordância entre a indicação cirúrgica de conização clássica por citologia cervical (CC), biópsia ou excisão da zona de transformação (EZT), e o resultado anatomopatológico final das pacientes submetidas ao procedimento devido a lesões precursoras ou câncer do colo do útero. Além disso, visou observar a presença de lesão residual após EZT com diagnóstico histológico de carcinoma espinocelular (CEC) microinvasivo e margens comprometidas por lesão intraepitelial de alto grau (LIEAG). Para tal, realizou-se estudo retrospectivo envolvendo 82 mulheres com lesões intraepiteliais cervicais ou câncer com idade entre 28 e 71 anos. Estas foram submetidas a citologia cervicovaginal, biópsia de colo ou EZT entre janeiro de 2014 e janeiro de 2020 e tiveram a conização clássica indicada de acordo com os resultados dos procedimentos diagnósticos. A indicação cirúrgica foi a citologia em 30.5% dos casos; em 12.2%, foi devido à biópsia cervical, e em 24.4%, devido à citologia confirmada pela biópsia. Além disso, 32.9% das pacientes tiveram a cirurgia realizada devido a margens comprometidas após EZT. Foi encontrada concordância em 57.3% das indicações e 42.7% não apresentaram concordância. Observou-se lesão residual em 55.6% de todas as pacientes submetidas a EZT, mas no grupo de CEC microinvasivo, houve taxa de 60% de ausência de lesão residual na peça cirúrgica da conização. Portanto, isso indica que a EZT parece ser tratamento eficaz para o CEC microinvasivo do colo do útero, e uma cirurgia complementar parece não ser necessária na presença de margens comprometidas por LIEAG.

Palavras-chave: Lesões intraepiteliais escamosas cervicais; Neoplasias do colo do útero; Conização.

Resumen

El objetivo de este trabajo fue evaluar la concordancia entre la indicación de conización por citología cervical (CC), biopsia o escisión de la zona de transformación (EZT), y el informe patológico de muestras quirúrgicas de pacientes con lesiones precancerosas o cáncer de cuello uterino. Además, observar la presencia de lesión residual después de EZT con carcinoma de células escamosas (CEC) microinvasivo y márgenes con lesión intraepitelial de alto grado (LIEAG). Para ello, se realizó estudio retrospectivo con participación de 82 mujeres con lesiones intraepiteliales cervicales o cáncer de cuello uterino de entre 28 y 71 años. Se sometieron a CC, biopsia o EZT entre enero de 2014 y enero de 2020 y tuvieron conización indicada de acuerdo con los resultados del procedimiento. La indicación de conización fue el resultado de CC en el 30.5% de los casos; en el 12.2%, se debió a biopsia, y en el 24.4%, se debió a CC confirmado por biopsia. Además, el 32.9% de las mujeres presentaron indicación debido a márgenes comprometidos después de un EZT. Se encontró concordancia en el 57.3% de las indicaciones quirúrgicas y el 42,7% no estuvo de acuerdo. Se observó lesión residual en el 55.6% de todas las pacientes sometidas a EZT, pero en el grupo de CEC microinvasivo, hubo una tasa del 60% de ninguna lesión residual. Por lo tanto, EZT parece ser un tratamiento efectivo para el CEC microinvasivo del cuello uterino, y la cirugía complementaria con conización no parece ser necesaria para los márgenes comprometidos con LIEAG.

Palabras clave: Lesiones intraepiteliales escamosas de cuello uterino; Neoplasias del cuello uterino; Conización.

1. Introduction

Persistent infection of high-risk human papillomaviruses (HPV) can lead to cell transformations and precancerous lesions of the cervix that, in some cases, if not treated, can become cervical cancer (INCA, 2022; National Cancer Institute, 2021). According to the American Cancer Society (ACS), the U.S. estimate for cervical cancer is 14,480 new cases and 4,290 deaths for 2021. It is the fourth most common female cancer worldwide (American Cancer Society, 2021; Dantas et al., 2020), and 90% of deaths generally occur in low- and middle-countries (Dantas et al., 2020). In Brazil, the National Cancer Institute (INCA) estimated approximately 16,590 new cases and 6,596 deaths in 2020 (INCA, 2020). This incidence and the mortality rates have intermediate values in relation to developing countries but are high when compared to developed countries with organized screening programs (INCA 2020). The implementation of planned programs and the establishment of public policies in the areas of screening and treatment of precursor lesions in order to decrease these indicators are extremely important and may provide a significant reduction in incidence and mortality (Hartman et al, 2021; Teixeira et al, 2018).

For patients with cytological abnormalities or precancerous lesions, i.e., high-grade squamous intraepithelial lesion (HSIL), glandular cell atypia, or even early-stage cervical cancer as microinvasive carcinoma, a referral for colposcopy is recommended and excision is proposed as the treatment (Teixeira et al., 2018; INCA, 2016). However, there are several modalities of excisional treatment, such as large loop excision of the transformation zone (LLETZ) and cold knife conization that are recommended for microinvasive squamous cell carcinoma (SCC) and adenocarcinoma in situ (or suspected) (Cooper et al., 2021; Basu et al., 2018). Conization is also indicated when there is a disagreement between cytology and biopsy reports,

with suspicion of microinvasion in glandular cell lesions, or that enter the endocervical canal cranially, and in some cases of unsatisfactory colposcopic evaluation with evidence of cervical dysplasia. This procedure is extremely valuable for histopathological diagnosis and treatment (Cooper et al., 2021). In addition, in cases of surgical conization, when specimens from microinvasive SCC stage Ia1 (with up to 3 mm of stromal invasion) present compromised margins by HSIL, a second excisional procedure is recommended to exclude invasion. This is important due to the higher frequency of invasive lesions in positive surgical margins, and free conization margins are necessary to ensure the resection of the entire lesion (Hartman et al., 2021; Chen et al., 2018). Conversely, there is an increasing demand for more conservative treatment modalities in order to preserve the reproductive life of patients and reduce surgical risks (Kalliala et al., 2020). In this sense, the LLETZ has emerged as a safe procedure that can be performed at the ambulatory level at low cost (Schwarz et al., 2015; Lindsay et al. 2014). This study aimed to assess the reliability and concordance between the surgical indication for cold knife conization by cervical cytology (CC), biopsy, or LLETZ, and the anatomopathological report of surgical specimens of the uterine cervix. In addition, it was observed the presence or absence of residual lesion in these specimens, in the case of a surgical complementation of LLETZ with microinvasive SCC and margins with HSIL, conditions that would justify the second procedure.

2. Methodology

The present study was conducted in accordance with the Declaration of Helsinki and the protocol was approved by the Institutional Committee of the Federal University of São Paulo (protocol No. 39992020.0.0000.5505), and all patients previously agreed with and signed an informed consent form. In accordance with the journal's guidelines, we will provide our data for the reproducibility of this study in other centers if requested.

In this observational retrospective study, 82 patients were evaluated between January 2014 and January 2020. Patients attended the Gynecological Disease Prevention Nucleus (NUPREV) clinic of the Department of Gynecology of the Federal University of São Paulo - Paulista Medical School (UNIFESP/EPM) and submitted to diagnostic methods such as LLETZ, CC, biopsy, or CC associated with biopsy (CC+biopsy). Surgical indication of cold knife conization occurred after diagnostic procedures and the pathological assessment. Surgeries were performed at the São Paulo Hospital. Patients with any suspicion of invasive cervical lesions were included in the study, and pregnant and lactating patients were excluded.

Like it was done by another study of our group (Campos et al., 2018) clinical data were collected from patient charts and pathology reports, which included results of LLETZ, CC, biopsy, and pathology reports of specimens collected by cold knife conization. All information regarding treatment, histopathology, and follow-up were carefully analyzed. An experienced pathologist evaluated all histological specimens.

Statistical analysis was performed to evaluate the agreement between the surgical indication and the final pathological result, with a possible comparison between the reliability of the indication by cytological and histological study. Patients were divided into groups according to age group categorization. Statistical analysis was initially performed using absolute and relative frequencies. The inferential analyses employed in order to confirm or refute evidence found in the descriptive analysis were Pearson's Chi-Square, Fisher's Exact, or its extension. In all the conclusions obtained through the inferential analysis, a level of alpha significance equal to 5% was used. Statistical significance was established as $p < 0.05$. All data were entered in Excel 2010 for Windows, and the analyses were performed using SPSS Statistics version 24 (IBM Corp., Armonk, NY).

3. Results

The patients had a mean age of 43.21 years old with a standard deviation of 10.39, ranging from 28 to 71 years. Table 1 shows all patients divided into age groups according to the screening or diagnostic method.

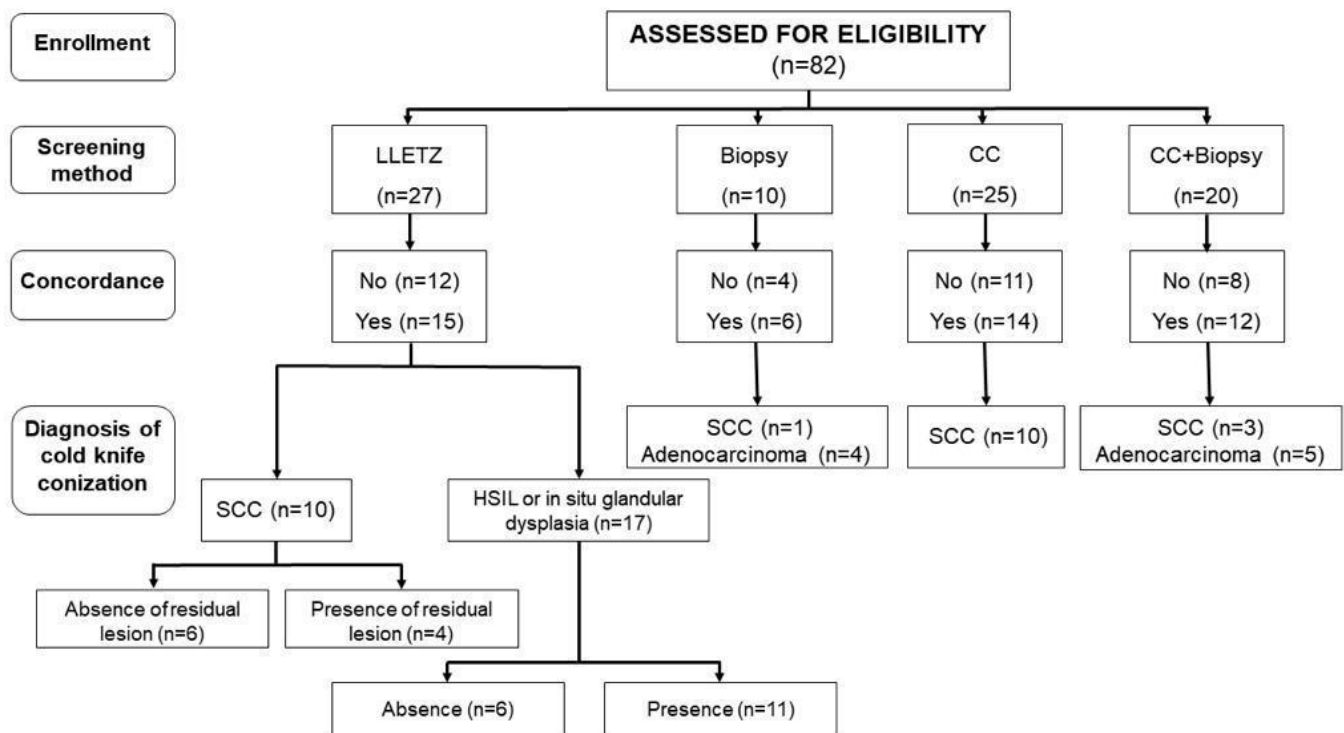
Table 1. Classification of patients according to the age and the diagnostic method for cold knife conization indication.

Age	LLETZ n (%)	Biopsy n (%)	CC n (%)	CC+biopsy n (%)	Total n (%)	P-value*
26-30	1 (3.7)	-	1 (4)	1 (5)	3 (3.7)	0.948
31-35	5 (18.5)	1 (10)	4 (16)	3 (15)	13 (15.9)	
36-40	11 (40.7)	5 (50)	6 (24)	6 (30)	28 (34.1)	
41-45	4 (14.8)	-	6 (24)	3 (15)	13 (15.9)	
46-50	2 (7.4)	2 (20)	2 (8)	3 (15)	9 (11)	
>50	4 (14.8)	2 (20)	6 (24)	4 (20)	16 (19.5)	
Total	27 (100)	10 (100)	25 (100)	20 (100)	82 (100)	

Note: *Extension of Fisher's exact test; LLETZ: large loop excision of the transformation zone; CC: cervical cytology. Source: Authors.

Regarding the surgical indication, it was observed that in 30.5% (25/82) of women surgery was indicated due to CC, which did not exclude invasive lesion. In 12.2% (10/82) of patients the indication occurred by anatomopathological examination of the cervical biopsy that presented a possible invasive lesion, and in 24.4% (20/82), it was due to CC+biopsy. We also noted that 32.9% (27/82) of them had an indication of cold knife conization due to LLETZ specimens that showed compromised margins indicating the presence of HSIL. Of these, 37% (10/27) of cases showed microinvasive SCC and 63% (17/27) showed HSIL without exclude invasion or glandular dysplasia *in situ* (Figure 1).

Figure 1. Flow diagram of study design with details of the number of participants and concordance with pathological result and diagnosis for each screening or diagnostic method



Source: Authors.

In the concordance analysis of the indication of cold knife conization performed by LLETZ, CC, biopsy, or CC+biopsy, it was found a concordance of 57.3% (47/82) in the surgical indication based on pathology reports, and 42.7% did not show concordance; no significant differences were observed between the screening or diagnostic methods (p = 0.987).

Furthermore, in cold knife conizations performed after LLETZ procedures, there were residual lesions in 55.6% (15/27) of patients, while 44.4% (12/27) did not show residual epithelial lesions, indicating that all epithelium with histological alterations had been removed by LLETZ (Table 2). Microinvasive SCC with stage Ia1 was the indication of conization in 37% (10/27) of patients who underwent LLETZ; of these, 60% (6/10) showed absence of residual lesions, with healthy epithelium and/or thermal injury resulting from the previous procedure, and 40% (4/10) showed residual lesions after LLETZ procedure in the specimens of cold knife conization.

Table 2. Concordance analysis of the cold knife conization indications according to pathology reports of cervical cytology, biopsy, large loop excision of the transformation zone.

Concordance	LLETZ n (%)	Biopsy n (%)	CC n (%)	CC+biopsy n (%)	Total n (%)	P-value*
No	12 (44.4)	4 (40)	11 (44)	8 (40)	35 (42.7)	0.987
Yes	15 (55.6)	6 (60)	14 (56)	12 (60)	47 (57.3)	
Total	27 (100)	10 (100)	25 (100)	20 (100)	82 (100)	

Note: *Pearson's Chi-Square test; LLETZ: large loop excision of the transformation zone; CC: cervical cytology. Source: Authors.

In order to evaluate the differences in diagnostic sensitivity among cytological and histological methods used, the indication of surgery in patients diagnosed with SCC (14) or adenocarcinoma (9) was analyzed, excluding the patients who underwent LLETZ. In the group with SCC, 71.4% (10) presented indication of cold knife conization surgery due to CC samples, 21.4% (3) due to CC+biopsy, and 7.2% (1) because of biopsy samples (Table 3).

Table 3. Classification of patients with squamous cell carcinoma and adenocarcinoma of the cervix according to the diagnostic method for cold knife conization indication.

Surgical indication	SCC n (%)	Adenocarcinoma n (%)	Total n (%)	P-value*
CC	10 (71.4)	0 (0)	10 (43)	0.002
Biopsy	1 (7.2)	4 (44.4)	5 (22)	
CC+Biopsy	3 (21.4)	5 (55.6)	8 (35)	
Total	14 (100)	9 (100)	23 (100)	
CC	10 (91)	0 (0)	10 (67)	0.003
Biopsy	1 (9)	4 (100)	5 (33)	
Total	11 (100)	4 (100)	15 (100)	
CC	10 (77)	0 (0)	10 (56)	0.006
CC+Biopsy	3 (23)	5 (100)	8 (44)	
Total	13 (100)	5 (100)	18 (100)	
Biopsy	1 (25)	4 (44)	5 (38)	1.000
CC+Biopsy	3 (75)	5 (56)	8 (62)	
Total	4 (100)	9 (100)	13 (100)	

Note: *Extension of Fisher's exact test; SCC: squamous cell carcinoma; CC: cervical cytology. Source: Authors.

For women with adenocarcinoma, indication of cold knife conization surgery came from biopsy in 44.4% (4) of cases and CC+biopsy in 55.6% (5) (p=0.002). None of patients with adenocarcinoma had isolated abnormal cytology. Therefore, cytology showed significant differences in the diagnostic sensitivity for SCC compared to biopsy (p=0.003), and CC+biopsy (p=0.006). There were no significant differences between the biopsy and CC+biopsy (p=1.000).

4. Discussion

In this study, we were able to profile the age of patients who underwent cold knife conization surgery due to

development of precursor lesions or with early-stage cervical cancer already established. More than 65% of patients were between 31 and 45 years old, and only 3.7% were less than 30 years old. Patients with precursor lesion diagnoses were between 28 and 71 years old, and patients with cervical cancer had a similar profile of 31 to 71 years old (average of 43 years). The annual incidence of cervical lesions in young women is more frequent between 20 and 24 years old for low-grade squamous intraepithelial lesion (LSIL), and the peak of HSIL occurs between 25 and 29 years old (Bekos et al., 2018). However, the Centers for Disease Control and Prevention (CDC) demonstrated a significant decline of lesions in women less than 24 years old and a significant increase in women over 40 years of age (McClung et al., 2019). Cervical cancer is most frequently diagnosed in women over 35 years old (35 to 44 years old) with the average age at diagnosis of 50 years (American Cancer Society, 2022). Screening of precursor lesions of cervical cancer in the asymptomatic phase enables early diagnosis and treatment, reducing incidence and mortality from this neoplasm (American Cancer Society, 2020). In Brazil, the screening is performed with cervical cytology (Pap smear test); however, we still have to evolve coverage at the national population level. In 2013, the Brazilian Institute of Geography and Statistics (IBGE) showed that 79.4% of Brazilian women aged between 25 and 64 years had been screened in the last 3 years (Oliveira et al., 2018). Published data by the Ministry of Health indicated that a sizeable number of CC tests was performed in young women (under 20 years old) that comprised a nontarget population and age group range smaller than recommended, harming the effectiveness of the program (INCA, 2013). In this study, almost one-third of patients had the indication of cold knife conization because of cytological alterations, which highlights the importance of Pap smears as primary care in screening for cervical dysplasia.

The vast majority of SCC cases were initially screened by CC in this study. On the other hand, CC screening was not enough to identify and indicate conization for patients with adenocarcinoma. CC had greater sensitivity in detecting changes in squamous cells related to glandular cells; the technique used can contribute to this difference. Conventional slide smears have been used for sample collections, and this technique was established as the standard method in our institution. Compared to liquid cytology, the slide smear offers a greater chance of obtaining unsatisfactory samples (Beerman et al., 2008; Sykes et al., 2008). Glandular cells collected with an endocervical brush may be lost in the transfer of the material to a blade and/or its fixation, therefore, alterations will not be able to be identified.

Stage Ia1 microinvasive cervical cancer, which has up to 3 mm of stromal invasion, was diagnosed in 17 patients. According to the recommendations of the International Federation of Gynecology and Obstetrics (FIGO) in 2018, this disease stage is considered treated after a patient undergoes conization surgery (Salib et al., 2020). The 10 patients with stage Ia1 SCC who underwent LLETZ had margins compromised by HSIL, and lymphovascular invasion was not detected in any sample. All patients were later submitted to cold knife conization, following the recommendations of the current guidelines (INCA, 2016). However, the final anatomopathological report of six conizations showed no residual lesion. This might raise the question of whether a second procedure, that has risks and potential consequences for reproduction, is really necessary. A similar result was found by Bryson et al. (2004); there was clinical follow-up of patients diagnosed with adenocarcinoma in situ of the cervix after the LLETZ, and the patients did not have a recurrence (Bryson et al., 2004). They considered that LLETZ might be a curative treatment for cases of adenocarcinoma in situ with free margins, different from the well-established approach of performing a simple hysterectomy (INCA, 2016). However, even in patients with positive margins who subsequently underwent hysterectomy or conization, no residual glandular dysplasia was observed, which matches what it was found in this study except for the difference in the histological type. Regarding microinvasive adenocarcinoma, some authors advocate conization as a definitive treatment, which seems not to show differences in survival compared to hysterectomy and highlights the trend to choose more conservative treatments (Feng et al., 2018; Bean et al., 2017; Spoozak et al., 2012). Nevertheless, microinvasive SCC is considered curable if the cancer is minimally treated with conization, and the surgical samples present free margins. Lee et al. (2009) stated that conservative treatment with follow-up of patients even after the first procedure with

positive margins is possible. In their study, 75 patients had stage Ia1 SCC of the cervix and underwent LLETZ. Of these, 53 patients were definitively treated with hysterectomy, 12 underwent clinical follow-up with cytology, 6 underwent LLETZ again, and 4 underwent the conization procedure. The last three groups were classified as conservative treatment. This strategy had 90.9% effectiveness in the SCC treatment and absence of residual lesion was observed in most cases where patients underwent a second procedure (LLETZ or cold knife conization). In addition, more than half of the hysterectomy samples in the first group had no lesion (Lee et al., 2009). This result could be explained due to the thermal effect of the LLETZ and the inflammatory reaction generated in wound healing (Yang et al., 2020). In contrast, another study emphasized that it is necessary to perform a second surgery, such as new conization or a hysterectomy in the absence of reproductive desire, if the samples have positive margins in the first excisional procedure. They considered that the presence of positive margins is the main predictor of the risk of residual lesions and even invasive lesions (Hefler et al. 2010).

Furthermore, there is a discussion about the benefits and disadvantages of cold knife conization versus LLETZ. A meta-analysis with 20 studies compared these techniques and showed that, despite the fact that LLETZ is related to a higher incidence of positive margins for epithelial dysplasia, probably due to the smaller depth of tissue removed, there is no statistically significant difference when compared to conization in terms of recurrence and residual disease (Jiang & Chen, 2016). In addition, LLETZ allows more satisfactory colposcopic follow-up with better visualization of the squamocolumnar junction (El-Nashar et al., 2017). From the reproductive perspective point of view, both methods are associated with worse obstetric outcomes, but cold knife conization has a higher correlation with premature rupture of membranes, premature birth, and low birth weight (Kalliala et al., 2020; Teixeira et al., 2018). Therefore, LLETZ has been gaining more attention for being a low-cost outpatient procedure performed under local anesthesia, which is relatively safe with low complication rates (Yap, Nathan & Farrell, 2020). It is important to highlight that LLETZ enables reliable histopathological diagnosis only if there is no fragmentation of the excised specimens, since the extensive thermal injury makes it difficult to interpret its margins (Teixeira et al., 2018; Sparić et al., 2016).

This study had some limitations, such as the small sample size of patients treated with LLETZ, hence, likely underpowered to detect other significant associations. In addition, it was not possible to reach a conclusion as to the margin of LLETZ specimens with the presence of high-grade lesions in the cases of absence of residual lesion after conization. Studies with a larger number of patients would be necessary to clarify whether it is appropriate to adopt a conservative approach of follow-up with cytology and colposcopy, in cases of SCC stage Ia1 after LLETZ with positive margins, without increased risk of disease persistence or recurrence.

In summary, we obtained a concordance rate of just over half of the cases, considering all types of surgery indications. Findings also indicated that in patients with stage Ia1 microinvasive SCC, complementary surgery with conization may not be required after LLETZ, in cases with compromised margins with high-grade lesions. This cancer type may be considered treated just with LLETZ, and the cold knife conization seems not to be an indispensable requisite. Moreover, CC has apparently more sensitivity in identification of squamous dysplasia rather than glandular dysplasia. We also highlight the importance of methods for screening and definitive diagnosis of cervical cancer. In addition, we opened the question of the real need to proceed with treatment modalities that are currently well established, reinforcing the increasingly present trend of more conservative therapeutic forms, both from the point of view of the risk of the procedure itself and its possible consequences for the reproductive future of patients.

5. Conclusion

It was possible to highlight the great importance of methods for screening and definitive diagnosis of cervical neoplasms. In addition, it was possible to open the question about the real need to proceed to treatment modalities already well

established today, reinforcing the increasingly present trend of more conservative therapeutic forms, both from the point of view of the risk of the procedure itself and its possible consequences for the reproductive future of patients.

Studies with a larger number of patients would be necessary to clarify whether it is appropriate to adopt a follow-up with cytology and colposcopy, in cases of microinvasive SCC and specimens of LLETZ with positive margins, without increased risk of disease persistence or recurrence.

References

- American Cancer Society. (2022). *Key statistics for cervical cancer*. <https://www.cancer.org/cancer/cervical-cancer/about/key-statistics.html>
- American Cancer Society. (2021). *Cancer statistic center – estimated new cases*. <https://cancerstatisticscenter.cancer.org/#/data-analysis/NewCaseEstimates>
- American Cancer Society. (2020). *Facts & Figures 2020 Reports Largest One-year Drop in Cancer Mortality*. <https://www.cancer.org/latest-news/facts-and-figures-2020.html>
- Basu, P., Taghavi, K., Hu, S. Y., Mogri, S., & Joshi, S. (2018). Management of cervical premalignant lesions. *Current Problems in Cancer*, 42 (2), 129-36. <https://doi.org/10.1016/j.currproblecancer.2018.01.010>.
- Bean, L. M., Ward, K. K., Plaxe, S. C., & McHale, M. (2017). Survival of women with microinvasive adenocarcinoma of the cervix is not improved by radical surgery. *American Journal of Obstetrics & Gynecology*, 217, 332.e1-332.e6. <https://doi.org/10.1016/j.ajog.2017.05.021>
- Beerman, H., van Dorst, E. B. L., Kuenen-Boumeester, V., & Hogendoorn P. C. W. (2009). Superior performance of liquid-based versus conventional cytology in a population-based cervical cancer screening program. *Gynecologic Oncology*, 112 (3), 572-576. <https://doi.org/10.1016/j.ygyno.2008.12.012>.
- Bekos, C., Schwameis, R., Heinze, G., Gärner, M., Grimm, C., Joura, E., Horvat, R., Polterauer, S., & Polterauer, M. (2018). Influence of age on histologic outcome of cervical intraepithelial neoplasia during observational management: results from large cohort, systematic review, meta-analysis. *Scientific Reports*, 8 (1), 6383. <https://doi.org/10.1038/s41598-018-24882-2>.
- Bryson, P., Stulberg, R., Shepherd, L., McLelland, K. & Jeffrey, J. (2004). Is electrosurgical loop excision with negative margins sufficient treatment for cervical ACIS? *Gynecologic Oncology*, 93 (2), 465-468. <https://doi.org/10.1016/j.ygyno.2004.01.028>.
- Campos, M. L. P. et al. (2018). *Concordância entre o resultado histológico da biópsia de colo, e o da exérese da zona de transformação, em um centro de referência na cidade de São Paulo*. Seção de pôster apresentado no XXI Congresso Brasileiro de Patologia do Trato Genital Inferior e Colposcopia, São Paulo, SP.
- Chen, J. Y., Wang, Z. L., Wang, Z. Y., & Yang, X. Y. (2018). The risk factors of residual lesions and recurrence of the high-grade cervical intraepithelial lesions (HSIL) patients with positive-margin after conization. *Medicine (Baltimore)*, 97 (41), e12792. <https://doi.org/10.1097/MD.00000000000012792>
- Cooper, D. B., Carugno, J., & Menefee, G. W. (2021). *Conization of cervix*. <https://www.ncbi.nlm.nih.gov/books/NBK441845/>
- Dantas, D. B., da Luz Costa, T., da Silva, A. S. A., de Campos Gomes, F., & de Melo-Neto, J. S. (2020). Mortality from cervical cancer in Brazil: an ecological epidemiologic study of a 22-year analysis. *Ecancermedicalscience*, 14, 1064-1076. <https://doi.org/10.3332/ecancer.2020.1064>.
- El-Nashar, S. A., Shazly, S. A., Hopkins, M. R., Bakkum-Gamez, J., & Famuyide, A. O. (2017). Loop Electrosurgical Excision Procedure Instead of Cold-Knife Conization for Cervical Intraepithelial Neoplasia in Women With Unsatisfactory Colposcopic Examinations: A Systematic Review and Meta-Analysis. *Journal of Lower Genital Tract Disease*, 21 (2), 129-136.
- Feng, Y., Zhang, Z., Lou, T., Wang, S., Bai, H., & Zhang, Z. (2018). The safety of fertility preservation for microinvasive cervical adenocarcinoma: a meta-analysis and trial sequential analysis. *Archives of Gynecology and Obstetrics*, 298 (3), 465-475. <https://doi.org/10.1007/s00404-018-4799-0>.
- Hartman, C. A., Bragança, J. F., Gurgel, M. S. C., Zeferino, L. C., Andrade, L. A. L. A., & Teixeira, J. C. (2021). Conservative treatment of microinvasive squamous cell carcinoma of the cervix stage IA1: Defining conization height to an optimal oncological outcome. *PLoS One*, 16 (7), e0253998-e0253400. <https://doi.org/10.1371/journal.pone.0253998>.
- Hefler, L. A., Polterauer, S., Schneitter, A., Concin, N., Hofstetter, G., Bentz, E., Leipold, H., Tempfer, C., & Reinthaller, A. (2010). Repeat surgery in patients with cervical cancer stage FIGO IA1: a series of 156 cases and a review of the literature. *Anticancer Research*, 30 (2), 565-568.
- INCA. Instituto Nacional de Câncer José Alencar Gomes da Silva. (2022). *Tipos de câncer – câncer do colo do útero*. <https://www.inca.gov.br/tipos-de-cancer/cancer-do-colo-do-uterio>
- INCA. Instituto Nacional de Câncer José Alencar Gomes da Silva. (2020). *Estimativa 2020: incidência de câncer no Brasil*. <https://www.inca.gov.br/sites/ufu.sti.inca.local/files/media/document/estimativa-2020-incidencia-de-cancer-no-brasil.pdf>
- INCA. Instituto Nacional de Câncer José Alencar Gomes da Silva. (2016). *Diretrizes brasileiras para o rastreamento do câncer do colo do útero*. (2a ed.). INCA. <https://www.inca.gov.br/publicacoes/livros/diretrizes-brasileiras-para-o-rastreamento-do-cancer-do-colo-do-uterio>
- INCA. Instituto Nacional de Câncer José Alencar Gomes da Silva. (2013). *Informativo detecção precoce: monitoramento das ações de controle dos cânceres do colo do útero e de mama*. <https://www.inca.gov.br/sites/ufu.sti.inca.local/files/media/document/informativo-deteccao-precoce-1-2013.pdf#:~:text=O%20Informativo%20Detec%C3%A7%C3%A3o%20Precoce%20C3%A9%20uma%20estrat%C3%A9gia%20de,c%C3%A2nceres%20o%20colo%20do%20C3%BAterio%20e%20de%20mama>.

- Jiang, Y. M., Chen, C. X., & Li, L. (2016). Meta-analysis of cold-knife conization versus loop electrosurgical excision procedure for cervical intraepithelial neoplasia. *Onco Targets and Therapy*, 9, 3907-3915. <https://doi.org/10.2147/OTT.S108832>.
- Kalliala, I., Athanasiou, A., Veroniki, A. A., Salanti, G., Efthimiou, O., Raftis, N., Bowden, S., Paraskevaidi, M., Aro, K., Arbyn, M., Bennett, P., Nieminen, P., Paraskevaidis, E., & Kyrgiou, M. (2020). Incidence and mortality from cervical cancer and other malignancies after treatment of cervical intraepithelial neoplasia: a systematic review and meta-analysis of the literature. *Annals of Oncology*, 31 (2), 213-227. <https://doi.org/10.1016/j.annonc.2019.11.004>.
- Lee, S. W., Kim, Y. M., Son, W. S., You, H. J., Kim, D. Y., Kim, J. H., Kim, Y. T., & Nam, J. H. (2009). The efficacy of conservative management after conization in patients with stage IA1 microinvasive cervical carcinoma. *Acta Obstetrica et Gynecologica Scandinavica*, 88 (2), 209-215. <https://doi.org/10.1080/00016340802596009>.
- Lindsay, R., Burton, K., Shanbhag, S., Tolhurst, J., Millan, D., & Siddiqui, N. (2014). Fertility conserving management of early cervical cancer: our experience of LLETZ and pelvic lymph node dissection. *International Journal of Gynecological Cancer*, 24 (1), 118-123. <https://doi.org/10.1097/IGC.000000000000023>.
- McClung, N. M., Gargano, J. W., Park, I. U., Whitney, E., Abdullah, N., Ehlers, S., Bennett, N. M., Scahill, M., Nicolai, L. M., Brackney, M., Griffin, M. R., Pemmaraju, M., Querec, T. D., Cleveland, A. A., Unger, E. R., & Markowitz, L. E. (2019). Estimated Number of Cases of High-Grade Cervical Lesions Diagnosed Among Women - United States, 2008 and 2016. *Morbidity and Mortality Weekly Report*, 68 (15), 337-343. <https://doi.org/10.15585/mmwr.mm6815a1>.
- National Cancer Institute. (2021). *HPV and cancer*. <https://www.cancer.gov/about-cancer/causes-prevention/risk/infectious-agents/hpv-and-cancer>
- Oliveira, M. M., Andrade, S. S. C. A., Oliveira, P. P. V., Silva, G. A. E., Silva, M. M. A. D., & Malta, D. C. (2018). Pap-test coverage in women aged 25 to 64 years old, according to the National Health Survey and the Surveillance System for Risk and Protective Factors for Chronic Diseases by Telephone Survey, 2013. *Revista Brasileira de Epidemiologia*, 21, e180014. <https://doi.org/10.1590/1980-549720180014>.
- Salib, M. Y., Russel, J. H. B., Stewart, V. R., Sudderuddin, S. A., Barwick, T. D., Rockall, A. G., & Bhaewani, N. (2020). 2018 FIGO Staging Classification for Cervical Cancer: Added Benefits of Imaging. *RadioGraphics*, 40 (6), 1807-1822. <https://doi.org/10.1148/rg.2020200013>.
- Schwarz, T. M., Kolben, T., Gallwas, J., Crispin, A., & Dannecker, C. (2015). Comparison of two surgical methods for the treatment of CIN: classical LLETZ (large-loop excision of the transformation zone) versus isolated resection of the colposcopic apparent lesion - study protocol for a randomized controlled trial. *Trials*, 16, 225. <https://doi.org/10.1186/s13063-015-0736-8>
- Sparić, R., Tinelli, A., Guido, M., Stefanović, R., Babović, I., & Kesić, V. (2016). The role of surgeons' colposcopic experience in obtaining adequate samples by large loop excision of the transformation zone in women of reproductive age. *Geburtshilfe und Frauenheilkunde*, 76 (12), 1339-1344. <https://doi.org/10.1055/s-0042-113773>
- Spoozak, L., Lewin, S. N., Burke, W. M., Deutsch, I., Sun, X., Herzog, T. J., & Wright, J. D. (2012). Microinvasive adenocarcinoma of the cervix. *American Journal of Obstetrics and Gynecology*, 206 (1), 80.e1-6. <https://doi.org/10.1016/j.ajog.2011.07.029>.
- Sykes, P. H., Harker, D. Y., Miller, A., Whitehead, M., Neal, H., Wells, J. E., & Peddie, D. (2008). A randomised comparison of SurePath liquid-based cytology and conventional smear cytology in a colposcopy clinic setting. *BJOG: An International Journal of Obstetrics & Gynaecology*, 115 (11), 1375-1381. <https://doi.org/10.1111/j.1471-0528.2008.01865.x>.
- Teixeira, J. C., Maestri, C. A., Machado, H. D. C., Zeferino, L. C., & Carvalho, N. S. (2018). Cervical cancer registered in two developed regions from Brazil: upper limit of reachable results from opportunistic screening. *Revista Brasileira de Ginecologia e Obstetrícia*, 40 (6), 347-53. <https://doi.org/10.1055/s-0038-1660841>.
- Yang, E. J., Kim, N. R., Choi, J. Y., Kim, W. Y., & Lee, S. J. (2020). Loop electrosurgical excision procedure combined with cold coagulation for cervical intraepithelial neoplasia and adenocarcinoma in-situ: a feasible treatment with a low risk of residual/recurrent disease. *Infectious Agents and Cancer*, 15, 58. <https://doi.org/10.1186/s13027-020-00326-3>.
- Yap, S. J., Nathan, E., & Farrell, L. (2020). LLETZ make it simple: Anxiety, pain and treatment outcomes with outpatient large loop excision of the transformation zone under local anaesthesia. *Australian and New Zealand Journal of Obstetrics and Gynaecology*, 60 (3), 438-443. <https://doi.org/10.1111/ajo.13121>.