

Noninvasive intracranial pressure in patients with traumatic brain injury

Pressão intracraniana não invasiva em pacientes com traumatismo craneoencefálico

Presión intracranial no invasiva en pacientes con trauma craneoencefálico

Received: 07/18/2022 | Reviewed: 07/26/2022 | Accept: 07/29/2022 | Published: 08/08/2022

Caroline Link

ORCID: <https://orcid.org/0000-0001-6711-2590>
State University of Ponta Grossa, Brazil
E-mail: caroline-link@hotmail.com

Ana Flávia Botelho

ORCID: <https://orcid.org/0000-0002-5940-5323>
State University of Ponta Grossa, Brazil
E-mail: ana_flavia_ast@hotmail.com

Thomas Markus Dhaese

ORCID: <https://orcid.org/0000-0002-6519-0007>
State University of Ponta Grossa, Brazil
E-mail: tdhaese@gmail.com

Gustavo Frigieri

ORCID: <https://orcid.org/0000-0002-4288-468X>
Brain4care, Brasil
E-mail: gustavo.frigieri@brain4.care

José Carlos Rebuglio Velloso

ORCID: <https://orcid.org/0000-0003-4747-9197>
State University of Ponta Grossa, Brazil
E-mail: vellosajcr@hotmail.com

Leonardo Christiaan Welling

ORCID: <https://orcid.org/0000-0001-9987-6819>
State University of Ponta Grossa, Brazil
E-mail: leonardowelling@yahoo.com.br

Abstract

Monitoring and treatment of intracranial pressure are extremely important procedures in the management of patients with traumatic brain injury. The monitoring methods currently marketed are invasive and are not suitable for all patients. In addition to the risks offered, they are not available on all services. This study aims to describe the cases of five patients with traumatic brain injury of different severity who underwent noninvasive monitoring of intracranial pressure in the acute phase of the injury, relating the changes identified with the clinical picture presented. Patients showed important changes in intracranial pressure wave morphology, possibly related to the lesions, clinical presentation and therapeutic interventions used.

Keywords: Intracranial pressure; Compliance; Traumatic brain injury.

Resumo

A monitorização e o tratamento da pressão intracraniana são procedimentos de extrema importância no manejo do paciente com traumatismo craneoencefálico. Os métodos de monitoramento atualmente comercializados são invasivos, não sendo indicados para todos os pacientes. Além dos riscos oferecidos, não estão disponíveis em todos os serviços. Este estudo tem como objetivo descrever os casos de cinco pacientes com traumatismo craneoencefálico de diferentes gravidades submetidos a monitorização não invasiva da pressão intracraniana na fase aguda da lesão, relacionando as alterações identificadas com o quadro clínico apresentado. Os pacientes apresentaram alterações importantes na morfologia da onda da pressão intracraniana, possivelmente relacionadas com as lesões, apresentação clínica e intervenções terapêuticas utilizadas.

Palavras-chave: Pressão intracraniana; Complacência; Traumatismo craneoencefálico.

Resumen

La monitorización y el tratamiento de la presión intracraneal son procedimientos extremadamente importantes en el manejo de pacientes con lesión cerebral traumática. Los métodos de monitorización comercializados actualmente son invasivos y no son adecuados para todos los pacientes. Además de los riesgos ofrecidos, no están disponibles en todos los servicios. Este estudio tiene como objetivo describir los casos de cinco pacientes con traumatismo craneoencefálico de diferente gravedad a los que se les realizó monitorización no invasiva de la presión intracraneal en la fase aguda de la lesión, relacionando las alteraciones identificadas con el cuadro clínico presentado. Los

pacientes mostraron cambios importantes en la morfología de la onda de presión intracraneal, posiblemente relacionados con las lesiones, la presentación clínica y las intervenciones terapéuticas utilizadas.

Palabras clave: Presión intracraneal; Conformidad; Traumatismo craneoencefálico.

1. Introduction

Monitoring and treating intracranial pressure (ICP) are extremely important procedures in managing patients with severe traumatic brain injury (TBI). Despite the controversies regarding the real available evidence, the Brain Trauma Foundation guideline (Carney et al., 2017) recommends invasive ICP monitoring in patients with severe TBI (Glasgow coma scale (GCS) of 3-8 with computed tomography (CT) scans abnormalities or in patients with normal CT and two or more risk factors (> 40 years, abnormal postures or systolic blood pressure lower than 90 mmHg).

The actual ICP monitoring methods are invasive, carrying a risk of hemorrhage, worsening brain edema, parenchymal damage, and infection (Evensen & Eide, 2020). Even with the risks, the insertion of an intraventricular catheter through a neurosurgical procedure with the connection to an external pressure transducer is considered the "gold standard" for ICP monitoring (Carney et al., 2017).

As an alternative to invasive methods, Brazilian researchers have developed a monitoring method with an strip transducer at first time "called" minimally invasive where a small incision was made and this one was placed over the calvaria which was kept intact (Mascarenhas et al., 2012) (Vilela et al., 2016). Few years later a noninvasive system where created where the transducer was placed over the intact skin. (Cabella et al., 2016). The device consists of an electrical resistance strain gauge (sensor) capable of capturing bone micro deformations resulting from ICP variation. The technology has already been validated with the invasive sensor (Brasil, et al., 2021) (Moraes et al., 2022) and has already received marketing authorization in Brazil (ANVISA) and in the USA (FDA).

This noninvasive ICP monitoring (niICP) analysis the ICP waveform morphology. Such wave has three peaks: P1 or percussion peak, P2 or tidal, and P3 or dicrotic wave. Some measurements resulting from the ICP curve may demonstrate the loss of brain compliance. In other words, in situations where the ICP is adequate, it is expected that the pulse wave will be represented as $P1 > P2 > P3$ and, in raised ICP situations, an increase in P2 over P1 is detected (Nucci, et al., 2016).

For demonstration purposes the authors reports five elusive TBI patients who underwent monitoring of the ICP waveform obtained through a noninvasive device and discussed possible associated findings.

2. Methodology

This is a case study (Yin, 2015) carried out in the emergency department, wards, and intensive care unit (ICU). The local ethics committee approved this study under registration number 3.361.003. All included patients or legal responsible provided signed consent. Eligible patients included TBI patients with or without indication for craniotomy, over 18 years old. The exclusion criteria are decompressive craniectomy or extensive and depressive skull fractures.

The first niICP was made within 12 hours after the initial CT and the subsequent ones, 24, 48, 72, 96, and 120 hours after the first CT. A total of 1 to 6 monitoring lasting 10 minutes each was made. The niICP was interrupted before according to the ICU patient's discharge or death.

The anthropometric and sociodemographic data, trauma mechanism, time since injury and first niICP monitoring, Glasgow Coma Scale, pupillar asymmetry, vital signs, and medication use were collected. CT was obtained at patient admission and during the acute phase of the injury, when necessary, and described according to the Marshall classification (Marshall et al., 1992). Laboratory variables were collected according to the hospital routine. The length of stay was recorded, and the outcome was assessed using the Glasgow Outcome Scale (GOS) at hospital discharge.

The sensor was applied to the temporoparietal bone, 1 to 1.5 cm above the ear, and the signals obtained by the sensor were filtered, amplified, digitized, and recorded. The analysis of the monitoring signal of the curves was done by the Brain4care Analytics System, which obtains the waves with a confidence level of 95% and measures the amplitude in millivolts of the sub-divisions P1 and P2. The pulse slope (TTP – time to peak) was calculated between the beginning of the wave's increase and its highest point, resulting in an angle between the formed line and the base of the pulse. A P2/P1 ratio greater than one, $P2 > P1$, was defined as abnormal.

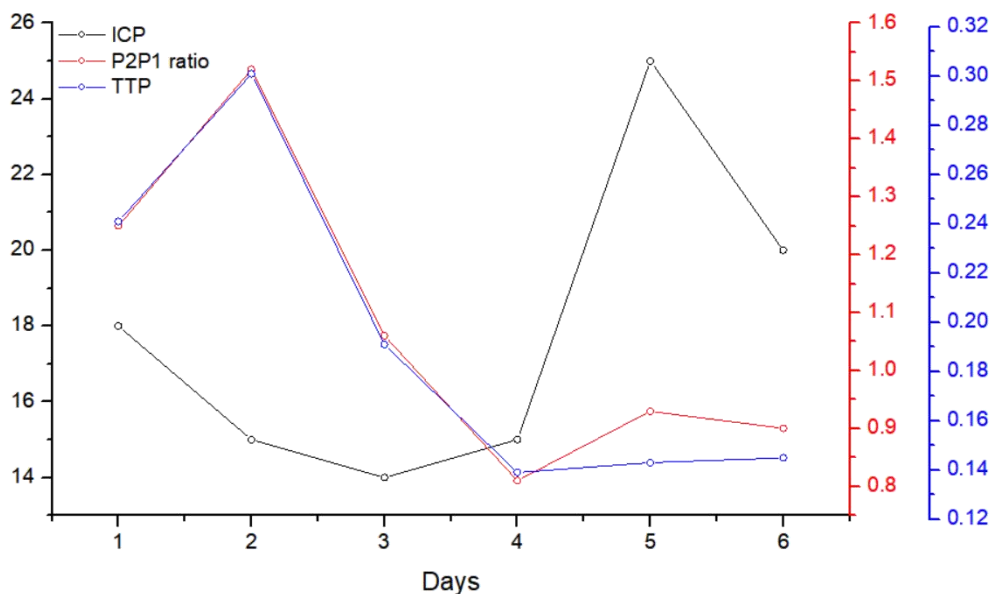
3. Results and Discussion

3.1 Case 1

A 23 years-old male patient, train collision victim was admitted with severe TBI (GCS 8 and anisocoria) grade II splenic trauma (conservative treatment), hemothorax and pulmonary contusion. The brain CT scan demonstrated signs of diffuse axonal injury and subarachnoid hemorrhage (SAH), without lesions with mass effect or midline shift (Marshall Diffuse injury III). An invasive ICP (iICP) catheter was inserted and neuroprotection measures (HOB elevation, deep sedation, mannitol infusion when necessary) were prescribed.

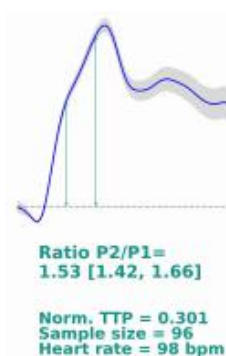
When ICP elevation episodes occurred, the external ventricular drain was opened, and if the ICP kept raised mannitol was administered. There were moments when ICP peaks of up to 53 mmHg documented. During niICP monitoring, the patient was hemodynamically stable, without vasoactive drugs, but with increasing doses of sedatives as the days gone (in the first monitoring, midazolam 0.17 and 0.25 mg/kg/h from the second to the fourth and 0.34 mg/kg/h in the last two), with the initiation of neuromuscular blockers on the fourth day. Following study protocol, the P2/P1 ratio in subsequent monitoring was 1.25; 1.52; 1.06; 0.81; 0.93 and 0.9, the TTP was at 0.241; 0.301; 0.191; 0.139; 0.143 and 0.145 and the iICP, in values of 18, 15, 14, 15, 25 and 20 respectively.

Figure 1: ICP variation, P2/P1 ratio, and TTP over time.



Source: Authors.

Figure 2: ICP wave morphology obtained non-invasively in the second monitoring of the patient.



Source: Authors.

On the second day of hospitalization, head CT was repeated, no changes were noted. On the fourth day, there was an increase in edema around the hemorrhagic foci, and on the sixth day, when the patient had an episode of anisocoria, the CT scan showed a reduction in brain swelling but an increase in the edema around the hemorrhagic foci. Nine days after the trauma, the iICP catheter was removed.

On the tenth day of hospitalization, he developed hypotension refractory to fluid replacement and desaturation. The patient developed sepsis of a pulmonary focus and ventilatory dysfunction, requiring increasing doses of noradrenaline (1.05 mcg/kg/min), blood transfusion, and hemodialysis without clinical conditions for weaning from sedation.

On the thirteenth day, he underwent pulmonary decortication by video thoracoscopy for clotted hemothorax and pulmonary incarceration. On the nineteenth day, he underwent thoracotomy for pulmonary decortication and phrenorrhaphy, where the bleeding was identified in the abdominal cavity, and exploratory laparotomy was performed. The patient evolved with cardiorespiratory arrest and did not respond to resuscitation maneuvers (GOS 1).

3.2 Case 2

A 46-year-old male patient was admitted after a motor vehicle collision. Neurological assessment identified GCS 3, isochoric pupils. The head CT identified subarachnoid, subdural and intraparenchymal hemorrhage (Marshall non evacuated mass lesion). A fracture of the right ischiopubic ramus and clavicle was identified and conservative treatment was indicated. At a first evaluation, any neurosurgical procedure was indicated.

During the niICP monitoring moments, 4hs after the trauma, the patient was sedated (midazolam 0.21 mg/kg/h). Hypotension episodes occurred, and the device captured the values of 1.49 concerning P2/P1 relationship and TTP of 0.283, both indirect values suggestive of intracranial hypertension (Brasil, et al., 2021), (Moraes et al., 2022). Due to the anisocoria, decompressive craniotomy and hematoma drainage were indicated without interurrences during the procedure.

On the fifth day of hospitalization, sedation was turned off, evolving with fluctuation in the level of consciousness (ECG 8-11), pneumonia, and sepsis unresponsive to clinical measures, evolving to death on the thirty-third day of hospitalization due to sepsis (GOS 1).

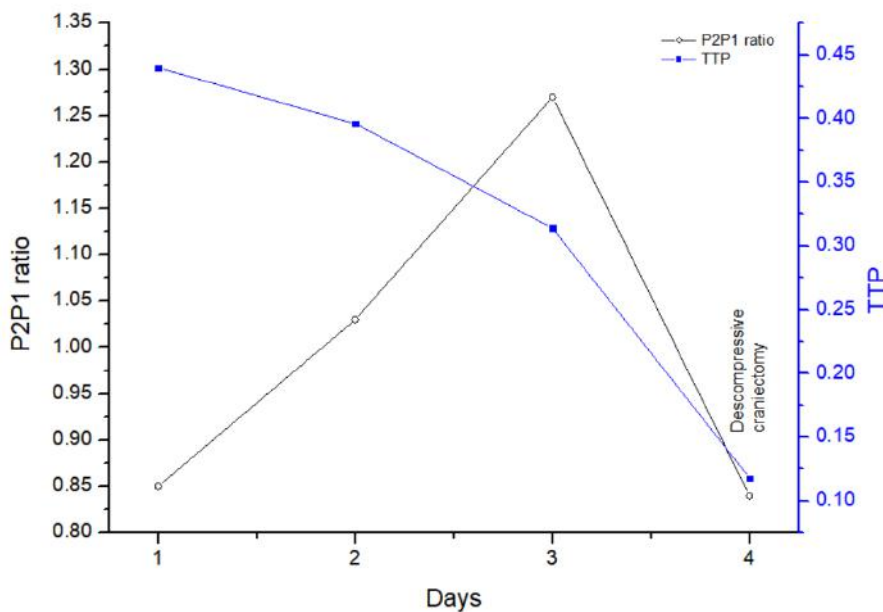
3.3 Case 3

A 28-year male patient victim of a car accident was admitted with GCS 4, isochoric and reactive pupils. The head CT identified a grade III Marshall injury (subarachnoid and thin subdural hematoma). Regarding other systems a pneumothorax,

grade I hepatic and grade II splenic trauma under conservative treatment were documented. The iICP was indicated, however for socioeconomic reasons the fiberoptic catheter was unavaialbe. Empirically measures were initiated for the management of supposed intracranial hypertension (HOB elevation, hyperventilation, mannitol).

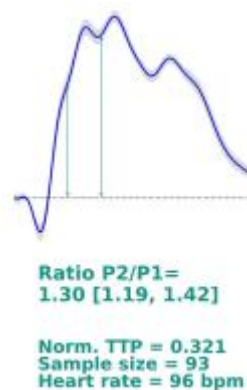
An niICP was proposed and during the monitoring, the patient was sedated (midazolam 0.32 mg/kg/h in the first two and 0.42 mg/kg/h in the following ones), using vasoactive drugs (noradrenaline 0.4; 0.51; 0.28 and 0.22 mck/kg/h) and arterial pressure were 76/49; 92/37; 103/45 and 166/66 mmHg. The values of P2/P1 during the monitoring were 0.85; 1.03; 1.27 and 0.84, and the TTP 0.44; 0.396; 0.314 and 0.118.

Figure 3: Variation of morphology over time, showing improvement in TTP due to neuroprotective measures and P2/P1 ratio after decompressive craniectomy.



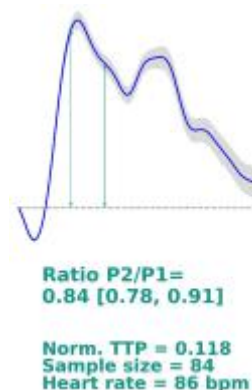Source: Authors.

Figure 4: ICP waveform morphology was obtained non-invasively in the third patient monitoring.



Source: Authors.

Figure 5: ICP wave morphology obtained non-invasively on the fourth patient monitoring.



Source: Authors.

On the second day of hospitalization, antibiotics were initiated for bronchoaspiration pneumonia. On the fourth day, a head CT scan was repeated, with worsening edema and midline deviation (Marshall diffuse injury IV). Decompressive frontotemporoparietal craniectomy was indicated. The procedure was uneventful, and mannitol was suspended.

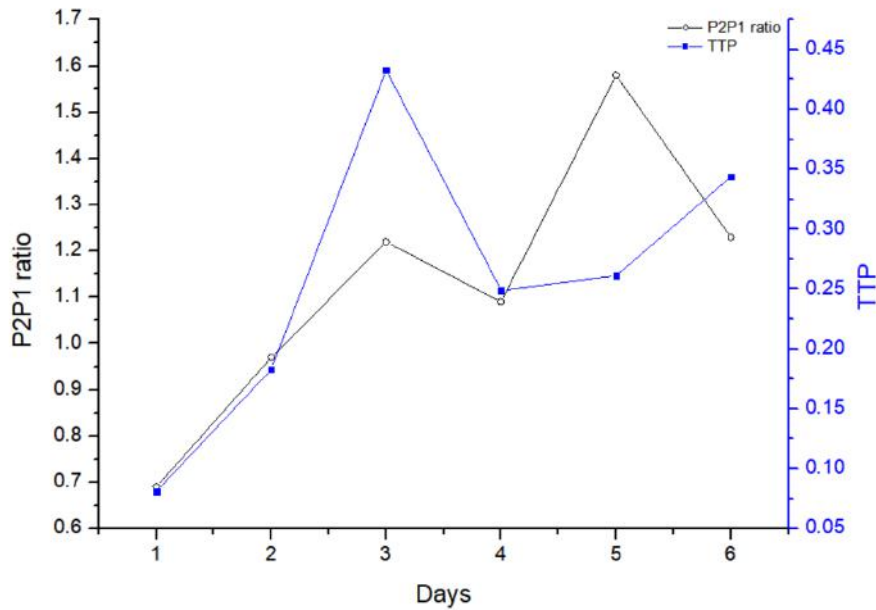
The patient evolved well, with reduced noradrenaline doses, subsequent CT with reduced midline shift, and sedation discontinuation on the ninth day of admission. He showed significant neurological improvement, being discharged on the eighteenth day of hospitalization with GCS 15 and GOS 4.

3.4 Case 4

A 46-year male patient, aggression victim, was admitted in GCS 14 and isochoric. The CT have showed subarachnoid hemorrhage, subdural hematoma, and diffuse edema with midline shift (Marshall non evacuated mass lesion), without extracranial lesions. The patient reported loss of consciousness, vomiting, confusion, and amnesia, without seizures. Opted for conservative treatment by neurosurgery team and neurological surveillance.

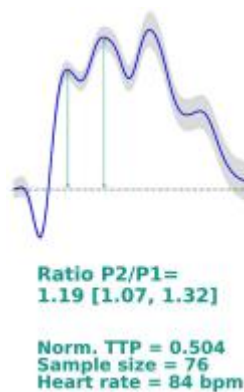During monitoring, the patient was hemodynamically stable, with GCS 15 (except in the fourth, GCS 14 due to confusion) and P2P1 values of 0.69; 0.97; 1.22; 1.09; 1.58 and 1.23 and TTP of 0.081; 0.183; 0.433; 0.249; 0.261 and 0.344. In the first three monitoring, the patient was asymptomatic, however, a few hours after the third monitoring, he developed an episode of generalized tonic-clonic seizures, which was treated with intravenous (IV) diazepam, and phenytoin load was started. On the fourth and subsequent monitoring, the patient reported episodes of severe headache.

Figure 6: Variation of P2/P1 and TTP ratio parameters over time.



Source: Authors.

Figure 7: ICP wave morphology was obtained non-invasively in the third patient monitoring.



Source: Authors.

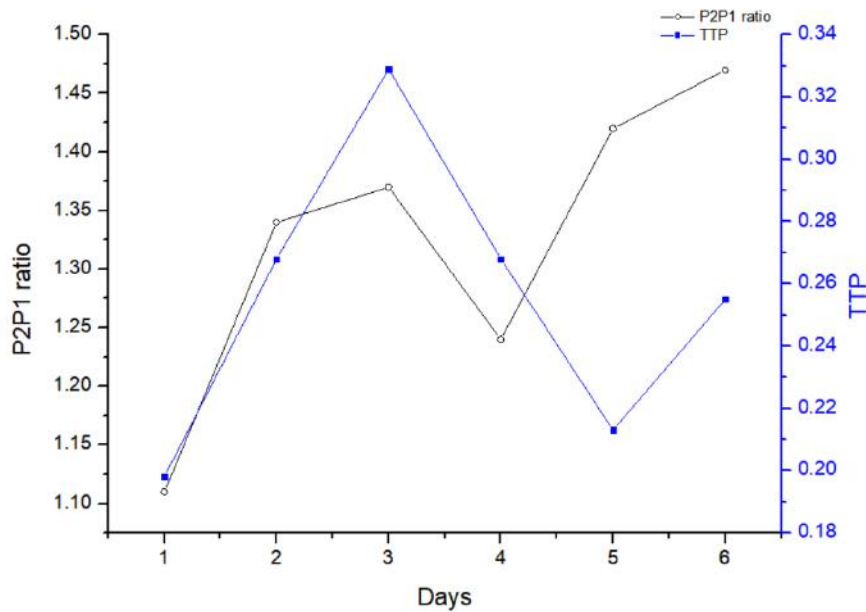
On the second day of hospitalization and the seventh day, a head CT scan was performed for control, with no significant changes. The patient had no other episodes of seizures and, on the tenth day, after a significant improvement in the headache, he was discharged from the hospital (GOS 5).

3.5 Case 5

A 40-year male victim of a fall from a height of approximately 4 meters with mild TBI was admitted. In the first evaluation he was GCS 15 with isochoric pupils. The head CT demonstrated skull fracture, subarachnoid hemorrhage, subdural and extradural hematoma, hemorrhagic contusions (Marshall diffuse injury III), without injuries extracranial. The patient denied loss of consciousness, nausea, and emesis and arrived at the referral hospital walking. Conservative treatment by neurosurgery and neurological surveillance was proposed.

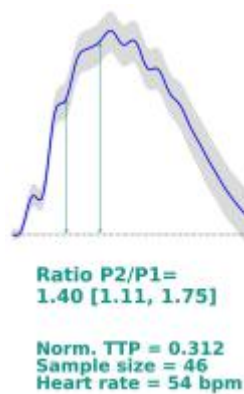During monitoring, the patient was hemodynamically stable, with a P2/P1 ratio of 1.11; 1.34; 1.37; 1.24; 1.42 and 1.47 and TTP 0.198; 0.268; 0.329; 0.268; 0.213 and 0.255. At first, he did not report symptoms. However, from the second onwards, he started to report severe headaches and, from the third onwards, an association of nausea and vomiting.

Figure 8: Variation of the P2/P1 and TTP ratio parameters over time.



Source: Authors.

Figure 9: ICP wave morphology was obtained non-invasively in the third patient monitoring.



Source: Authors.

On the second day of hospitalization, a control CT scan was performed, which showed more evident SAH and edema (Marshall diffuse injury III). On the fourth day, a new CT was performed with the same findings as in the previous exams (Marshall diffuse injury III). On the seventh day, the patient reported significant symptoms improvement and was discharged from the hospital.

3.6 Considerations about the cases

In many situations where invasive ICP monitoring is not available, but there is a possibility of ICP elevation, therapeutic decisions are made only by clinical findings such as headache, vomiting, fundoscopy, reduction of GCS scores, or image suppositions of raised ICP, generating suboptimal therapeutic efforts.

The new non-invasive method of monitoring ICP has already been described with clinical analysis and exams for guiding neuroprotection procedures (Rojas, et al., 2021). It has also been studied in cases of chronic kidney disease on dialysis (Rickli et al., 2021). al., 2021), patients with chronic stroke (Ocamoto, et al., 2021), and innumerable ICU conditions (Brasil, et al., 2021). It also have been reports in sedation situations (Bueno, et al., 2021) idiopathic intracranial hypertension (Dhaese, et al., 2021).

In the case 1, it is observed that the P2/P1 values decreased as there was an increase in sedation and the reduction of cerebral edema detected in the CT performed on the sixth post-trauma day. Regarding the ICP values, there is a possibility that the average of P2/P1 reflects not only the ICP value found during the monitoring but demonstrates the reduction of intracranial compliance that precludes the increase in ICP (Langfitt, et al., 1965).

In case 2, we visualized the indication for neurosurgery through clinical analysis and imaging methods. In this scenario, the P2/P1 ratio was significantly altered, demonstrating the possibility of aiding decision-making. Some indications for decompressive craniotomy are midline shift, unilateral lesions, and diffuse edema (Li, et al., 2010). However, according to The Brain Trauma Foundation (Carney et al., 2017), this intervention is considered second-choice and should be considered in patients with raised ICP refractory to first-choice therapeutic measures.

In case 3, initially, there was a tendency towards an increase in the P2/P1 ratio, congruent with the worsening of edema and midline deviation on CT. However, in the last monitoring, one day before the surgical intervention, there was a reduction in P2/P1, a possible effect of mannitol administration (Shi, et al., 2020).

In case 4, the patient started with normal P2/P1 values, with a significant increase before the seizure episode, which raises questions about the relationship between brain compliance and brain electrical events. Seizures are frequent events after TBI, occurring in more than 20% of patients with moderate or severe TBI (Vespa et al., 1999). Some risk factors for seizures in trauma patients are neurosurgical intervention, uncorrected sinking fracture, and parietal lesions on CT (Temkin, 2003). One of the consequences of posttraumatic seizures is the episodic and lasting increases in ICP (Vespa et al., 2007), as we observed in the patient mentioned above. It was observed that after the reported crisis, showed a tendency to increase the P2/P1 ratio.

In cases 4 and 5, the patients present symptoms that, in a way, accompany the changes in brain compliance, better characterized in case 5. This patient started with altered P2/P1, but with progressive worsening at the same time as he started to present headache, nausea, and vomiting, classic symptoms of intracranial hypertension. In addition to symptoms, CT also corroborates changes in compliance, demonstrating an increase in SAH and edema.

There are no studies in the literature relating tomographic findings with changes in the ICP morphology, and although edema with midline shift, midbrain cisterns obliteration and the SAH presence are predictors of increased ICP (Eisenberg et al., 1990). In some scenarios, ability to predict raised ICP only by CT scan is contradictory (Kishore, et al., 1981).

A relevant question, and study's limitation, is the threshold value of the P2/P1 ratio. The value used in this work was described in studies with invasive methods and in sedated patients (Yau et al., 2002). As these are monitoring methods in different locations (Frigieri et al., 2018) and the known neuroprotective effect of sedative drugs (Roberts, et al., 2011), it is possible that the value to be considered to be different for noninvasive monitoring, as demonstrated in the Brazilian study (Brasil, et al., 2021), in patients without sedation.

Another relevant issue is the elevated P2/P1 ratio in patients with mild TBI, in which the probability of raised ICP is very low. Sometimes the P2/P1 ratio is greater than severe TBI patients. In order to assess whether the P2 elevation would be a good predictor, 30 minutes before, of a large increase in ICP in patients with severe TBI, Fan et al. (2008) observed that the P2 elevation was not only present in situations of ICP elevation, but also in patients without intracranial hypertension, which may explain our findings, in addition to the known neuroprotective effect of sedatives (Roberts, et al., 2011).

4. Conclusion

Three of the patients had a formal indication for invasive ICP monitoring; however, due to the unavailability of the resource, only one used the fiberoptic catheter. The non-invasive method for monitoring ICP identified morphological changes in brain compliance waves after TBI. The reported method demonstrated the possibility of clinical application in the acute phase of the injury and can be used as a new parameter to assist in decision making. Even in patients with no indication for invasive monitoring, alterations were identified, thus indicating the need for further investigation of intracranial phenomena in situations of mild or moderate cranial trauma.

As it is a method without major risks, non-invasive ICP monitoring has the potential to be used in new studies involving neurological or systemic diseases in which there is a possibility of ICP alteration but which, due to the invasive nature and risks offered by the commonly used methods, such variations are not investigated. It is necessary to expand the evidence of the use of this technology also in scenarios where invasive monitoring is indicated, allowing it to become an alternative to it. In addition, the changes detected should be correlated with the clinical picture, interventions performed and patient outcomes.

References

- Brasil, S., Solla, D. J. F., Nogueira, R. C., Teixeira, M. J., Malbouisson, L. M. S., & Paiva, W. S. (2021) A Novel Noninvasive Technique for Intracranial Pressure Waveform Monitoring in Critical Care. *Journal of Personalized Medicine* 11 (12), 1302-1317.
- Bueno, B. F., Barbosa, C. R., Borato, D. C. K., & Velloso, J. C. R. (2021) Elderly non invasive intracranial pressure monitorization: a report of wave morphology and cerebral compliance. *Brazilian Journal of Development* 7 (1), 6952-6960.
- Cabella, B., Vilela, G. H. F., Mascarenhas, S., Czosnyka, M., Smielewski, P., Dias, C., & Colli, B. O. (2016) Validation of a New Noninvasive Intracranial Pressure Monitoring Method by Direct Comparison with an Invasive Technique. *Acta Neurochirurgica Supplement* 122, 93-96.
- Carney, N., Totten, A. M., O'Reilly, C., Ullman, J. S., Hawryluk, G. W. J., Bell, M. J., & Ghajar J. (2017) Guidelines for the Management of Severe Traumatic Brain Injury, Fourth Edition. *Neurosurgery* 80 (1), 6-15.
- Dhaese, T. M., Welling, L. C., Kosciasnki, A. M., Frigeri, G., Auada, J., Rabelo, N. N., & Figueiredo, E. G. (2021) Non-invasive intracranial pressure monitoring in idiopathic intracranial hypertension and lumbar puncture in pediatric patient: Case report. *Surgical Neurology International* 12, 493-497.
- Eisenberg, H. M., Gary, H. E., Aldrich, E. F., Saydjari, C., Turner, B., Foulkes, M. A., & Young, H. F. (1990) Initial CT findings in 753 patients with severe head injury. A report from the NIH Traumatic Coma Data Bank. *Journal of Neurosurgery* 73 (5), 3688-698.
- Evensen, K. B., & Eide, P. K. (2020) Measuring intracranial pressure by invasive, less invasive or non-invasive means: limitations and avenues for improvement. *Fluids Barriers of the Central Nervous System* 17(1), 34-67.
- Fan, J. Y., Kirkness, C., Vicini, P., Burr, R., & Mitchell, P. (2008) Intracranial pressure waveform morphology and intracranial adaptive capacity. *American Journal of Critical Care* 17 (6), 545-54.
- Frigieri, G., Andrade, R. A. P., Dias, C., Spavieri, D. L., Brunelli, R., Cardim, D. A., & Mascarenhas, S. (2018) Analysis of a Non-invasive Intracranial Pressure Monitoring Method in Patients with Traumatic Brain Injury. *Acta Neurochirurgica Supplement* 126, 107-110.
- Kishore, P. R., Lipper, M. H., Becker, D. P., Silva, A. A. D., & Narayan, R. K. (1981) Significance of CT in head injury: correlation with intracranial pressure. *American Journal of Roentgenology* 73 (5), 688-98.
- Langfitt, T. W., Kassell, N. F., & Weindstein, J. D. Cerebral blood flow with intracranial hypertension. (1965) *Neurology* 15, 761-773.
- Li, L. M., Timofeev, I., Czosnyka, M., & Hutchinson, P. J. A. (2010) Review article: the surgical approach to the management of increased intracranial pressure after traumatic brain injury. *Anesthesia & Analgesia* 111 (3), 736-748.

- Marshall, L. F., Marshall, S. B., Klauber, M. R., Clark, M. V. B., Eisenberg, H., Jane, J. A., & Foulkes, M. A. (1992) The diagnosis of head injury requires a classification based on computed axial tomography. *Journal of Neurotrauma* 9, 287-292.
- Mascarenhas, S., Vilela, G. H. F., Carlotti, C., Damiano, L. E. G., Seluque, W., Colli, B., & Nonaka, K. O. (2012) The new ICP minimally invasive method shows that the Monro-Kellie doctrine is not valid. *Acta Neurochirurgica Supplement* 114, 117-120.
- Moraes, F. M., Rocha, E., Barros, F. C. D., Freitas, F. G. R., Miranda, M., & Silva, G. S. (2022) Waveform Morphology as a Surrogate for ICP Monitoring: A Comparison Between an Invasive and a Noninvasive Method. *Neurocritical Care*.
- Nucci, C. G., Bonis, P. D., Mangiola, A., Santini, P., Sciandrone, M., Risi, A., & Anile, C. (2016) Intracranial pressure wave morphological classification: automated analysis and clinical validation. *Acta Neurochirurgica* 158 (3), 581-588.
- Ocamoto, G. N., Spavieri, D. L., Ribeiro, J. A. M., Vilela, G. H. F., Catai, A. M., & Russo, T. L. (2021) Noninvasive Intracranial Pressure Monitoring in Chronic Stroke Patients with Sedentary Behavior: A Pilot Study. *Acta Neurochirurgica Supplement* 131, 55-58.
- Rickli, C., Cosmoski, L. D., Santos, F. A., Frigieri, G. H., Rabelo, N. N., Schuinski, A. M., & Velloso, J. C. R. (2021) Use of non-invasive intracranial pressure pulse waveform to monitor patients with End-Stage Renal Disease (ESRD). *PLoS ONE* 16 (7).
- Roberts, D. J., Hall, R. I., Kramer, A. H., Robertson, H. L., Gallagher, C. N., & Zygun, D. A. (2011) Sedation for critically ill adults with severe traumatic brain injury: a systematic review of randomized controlled trials. *Critical Care Medicine* 39 (12), 2743-2751.
- Rojas, S. S. O., Ordinola, A. A. M., Veiga, V. C., & Souza, J. M. (2021) The use of a noninvasive intracranial pressure monitoring method in the intensive care unit to improve neuroprotection in postoperative cardiac surgery patients after extracorporeal circulation. *Revista Brasileira De Terapia Intensiva* 33 (3), 469-476.
- Shi, J., Tan, L., Ye, J., & Hu, L. (2020) Hypertonic saline and mannitol in patients with traumatic brain injury: A systematic and meta-analysis. *Medicine* 99 (35).
- Temkin, N. R. (2003) Risk factors for posttraumatic seizures in adults. *Epilepsia* 44, 18-20.
- Vespa, P. M., Miller, C., McArthur, D., Eliseo, M., Etchepare, M., Hirt, D., & Hovda, D. (2007) Nonconvulsive electrographic seizures after traumatic brain injury result in a delayed, prolonged increase in intracranial pressure and metabolic crisis. *Critical Care Medicine* 35 (12), 2830-2836.
- Vespa, P. M., Nuwer, M. R., Nenov, N., Engstrom, E. R., Hovda, D. A., Bergsneider, M., & Becker, D. P. (1999) *Journal of Neurosurgery* 91 (5), 750-760.
- Vilela, G. H. F., Cabella, B., Mascarenhas, S., Czosnyka, M., Smielewski, P., Dias, C., & Colli, B., O. (2016) Validation of a New Minimally Invasive Intracranial Pressure Monitoring Method by Direct Comparison with an Invasive Technique. *Acta Neurochirurgica Supplement* 122, 97-100.
- Yau, Y., Piper, I., Contant, C., Citerio, G., Kiening, K., Enblad, P., & Whittle, I. (2002) Multi-centre assessment of the Spiegelberg compliance monitor: interim results. *Acta Neurochirurgica Supplement* 81, 167-170.
- Yin, R.K. (2015). *O estudo de caso*: Bookman.