

## **Successful outcome of surgical reintervention for implant placement in borderline aesthetic area related to agenesia: a case report**

**Resultado bem-sucedido de reintervenção cirúrgica para colocação de implante em área estética limítrofe relacionada à agenesia: relato de caso**

**Resultado exitoso de la reintervención quirúrgica para la colocación de implantes en un área estética límite relacionada con la agenesia: reporte de un caso**

Received: 07/24/2022 | Reviewed: 07/31/2022 | Accept: 08/02/2022 | Published: 08/10/2022

### **Adriana Vieira Martins**

ORCID: <https://orcid.org/0000-0002-9799-2952>  
Universidade Federal de Minas Gerais, Brazil  
E-mail: [adriana@adrianavieiramartins.com.br](mailto:adriana@adrianavieiramartins.com.br)

### **Rodrigo de Castro Albuquerque**

ORCID: <https://orcid.org/0000-0002-9071-8010>  
Universidade Federal de Minas Gerais, Brazil  
E-mail: [albuquerque@yahoo.com.br](mailto:albuquerque@yahoo.com.br)

### **Lucas Moreira Maia**

ORCID: <https://orcid.org/0000-0002-9155-082X>  
Universidade Federal de Minas Gerais, Brazil  
E-mail: <mailto:lucasmoreiramaia@live.com>

### **Hans Hatner Araujo Oliveira**

ORCID: <https://orcid.org/0000-0002-3873-8305>  
Universidade Federal de Minas Gerais, Brazil  
E-mail: [hanshatner@yahoo.com.br](mailto:hanshatner@yahoo.com.br)

### **Rodrigo Keigo Nakagawa**

ORCID: <https://orcid.org/0000-0002-2032-3240>  
Universidade Federal de Minas Gerais, Brazil  
E-mail: [rodrigo.keigo@yahoo.com.br](mailto:rodrigo.keigo@yahoo.com.br)

### **Luis Fernando dos Santos Alves Morgan**

ORCID: <https://orcid.org/0000-0003-1418-9994>  
Universidade Federal de Minas Gerais, Brazil  
E-mail: [luismorgancd@yahoo.com.br](mailto:luismorgancd@yahoo.com.br)

### **Nelson Renato França Alves Silva**

ORCID: <https://orcid.org/0000-0002-9876-6017>  
Universidade Federal de Minas Gerais, Brazil  
E-mail: [nrfa.silva@gmail.com](mailto:nrfa.silva@gmail.com)

### **Rodrigo Richard da Silveira**

ORCID: <https://orcid.org/0000-0001-6225-0900>  
Universidade Federal de Minas Gerais, Brazil  
E-mail: [rodrigorsilveira@hotmail.com](mailto:rodrigorsilveira@hotmail.com)

### **Abstract**

The aim of this study is to illustrate and discuss the fundamentals of a well-succeeded and minimally invasive technique of surgical reintervention for installing implant in the reduced area of the alveolus, affected by agenesia, and traumatized by an unsuccessful intervention. Materials and methods: A 27-year-old patient sought dental care and her main cause was the great dissatisfaction with the aesthetic sequelae in the region of the right upper lateral incisor, in addition to the uncertainty regarding the predictability of a new unitary implant. Imaging exams showed trauma in the middle and apical region of the canine root surface. The dimensions of the edentulous area varied between 4.6 and 5.52 mm. A small diameter implant (BLT 2.9mm SC, Loxim SLActive® 12 mm, TiZr - Straumann Dental Implant System) was planned and installed, in addition to a subepithelial connective graft. Results: The results achieved allowed to restore the desired function and aesthetics, with excellence, low morbidity, in addition to a predictability favored by the benefits related to small diameter implants. Conclusions: The concept of minimally invasive dentistry is becoming an effective surgical approach and, although these implants present a higher risk for fracture than do large-diameter implants, implant fractures are rarely observed.

**Keywords:** Anodontia; Dental implants; Dental prosthesis; Dental prosthesis implant-supported.

## Resumo

O objetivo deste estudo é ilustrar e discutir os fundamentos de uma técnica bem-sucedida e minimamente invasiva de reintervenção cirúrgica para instalação de implante na área reduzida do alvéolo, acometido por agenesia e traumatizado por uma intervenção malsucedida. Materiais e métodos: Paciente de 27 anos procurou atendimento odontológico e sua principal causa foi a grande insatisfação com as sequelas estéticas na região do incisivo lateral superior direito, além da incerteza quanto à previsibilidade de um novo implante unitário. Os exames de imagem mostraram trauma na região média e apical da superfície radicular do canino. As dimensões da área edêntula variaram entre 4,6 e 5,52 mm. Foi planejado e instalado um implante de pequeno diâmetro (BLT 2,9mm SC, Loxim SLActive® 12 mm, TiZr - Straumann Dental Implant System), além de um enxerto conjuntivo subepitelial. Resultados: Os resultados alcançados permitiram restabelecer a função e estética desejadas, com excelência, baixa morbidade, além de uma previsibilidade favorecida pelos benefícios relacionados aos implantes de pequeno diâmetro. Conclusões: O conceito de odontologia minimamente invasiva está se tornando uma abordagem cirúrgica eficaz e, embora esses implantes apresentem maior risco de fratura do que os implantes de grande diâmetro, raramente são observadas fraturas de implantes.

**Palavras-chave:** Anodontia; Implantes dentários; Prótese dentária; Prótese dentária fixada por implante.

## Resumen

El objetivo de este estudio es ilustrar y discutir los fundamentos de una técnica de reintervención quirúrgica mínimamente invasiva y exitosa para la instalación de implantes en el área reducida del alvéolo, afectado por agenesia y traumatizado por una intervención fallida. Materiales y métodos: Una paciente de 27 años acudió a consulta odontológica y su principal causa fue la gran insatisfacción por las secuelas estéticas en la región del incisivo lateral superior derecho, además de la incertidumbre en cuanto a la previsibilidad de un nuevo implante unitario. Los exámenes de imagen mostraron un trauma en la región media y apical de la superficie de la raíz del canino. Las dimensiones del área edéntula variaron entre 4,6 y 5,52 mm. Se planificó e instaló un implante de pequeño diámetro (BLT 2.9mm SC, Loxim SLActive® 12 mm, TiZr - Straumann Dental Implant System), además de un injerto conectivo subepitelial. Resultados: Los resultados alcanzados permitieron restaurar la función y estética deseada, con excelencia, baja morbilidad, además de una previsibilidad favorecida por los beneficios relacionados con los implantes de pequeño diámetro. Conclusiones: El concepto de odontología mínimamente invasiva se está convirtiendo en un enfoque quirúrgico efectivo y, aunque estos implantes presentan un mayor riesgo de fractura que los implantes de gran diámetro, rara vez se observan fracturas de implantes.

**Palabras clave:** Anodoncia; Implantes dentales; Prótesis dental; Prótesis dental de soporte implantado.

## 1. Introduction

Dental agenesis is a phenomenon characterized by congenitally missing teeth. According to Magnusson (1977) hypodontia was found in an average of 7.9%, being the superior lateral incisors the third teeth with most cases.

For the rehabilitation of affected areas, dental implants have been indicated to be a conservative and viable alternative to conventional or adhesive fixed prostheses since they do not require dental wear.

However, certain characteristics associated with edentulous alveolus are challenging to treat, especially spaces for mandibular lateral incisors that are absent due to agenesis. Small horizontal spaces and alveolar atrophy are conditions that are frequently encountered in cases with these characteristics. (Trbakovic, et al., 2018)

Among the different types of osseointegrated implants, the most suitable alternative to the socket conditions are small-diameter implants (Yaltirik et al., 2011; Froum et al., 2020). The advantages of small-diameter implants include the absence of a need for additional bone grafts, as well as a lower risk for trauma to adjacent teeth. However, according to some studies, small-diameter implants are related to a lower success rate due to a higher risk for fracture compared to conventional implants. (Yaltirik et al., 2011; Allum, et al., 2008)

Implant fractures are rarely observed. The common technical complications include abutment fractures and abutment screw loosening, which have a cumulative incidence of 8.8% (95% CI: 5.1 to 15.0%) after 5 years, and the average implant fracture rate was found to be 0.92% (Jung et al., 2018; Lee et al., 2019; Zweers et al., 2015). Even so, when it comes to small-diameter implant fractures, these are justified by their use in the mandible region as fixed prosthesis pillars and overdentures (Zweers et al., 2015). In these cases, the compressive and lateral mechanical overload on the implant abutments is considered, regardless of the diameter of the implant (Duan et al., 2018).

However, although they are rare, implant fractures prove to be an unwanted condition for both dentists and patients. Thus, strong scientific evidence for planning purposes and thorough techniques for the execution of the plan are the fundamentals needed to minimize the risk for this type of complication.

Thus, the aim of this study is to discuss the existing scientific evidence on small-diameter implants. An additional aim is to illustrate the successful technique and result of surgical reintervention for the implantation of a border area implant that was related to lateral incisor agenesis and previously traumatized by an unsuccessful intervention.

## 2. Methodology

This article is a clinical case report with descriptive, exploratory purposes, with a qualitative approach (Pereira et al., 2018). It reports, in detail and based in scientific evidence, a minimally invasive technique of surgical reintervention for installing a narrow diameter implant in the reduced area of the alveolus, affected by agenesis, and traumatized by an unsuccessful intervention in an esthetic area.

This study followed the Helsinki Declaration ethical principles, the patient signed a consent form, and the study was approved by the Universidade Federal de Minas Gerais Ethical committee and received the approval nº 4.645.400.

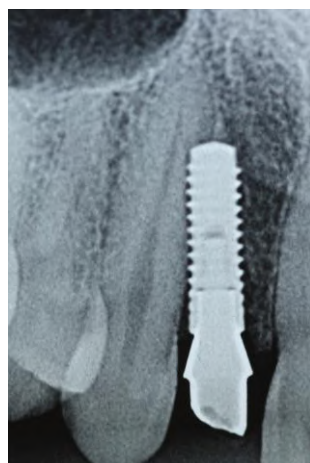## 3. Case Report

A 27-year-old patient sought dental care, and the patient's main complaint was great dissatisfaction with the aesthetic rehabilitation of the right upper lateral incisor region. The patient reported discoloration of the gum, a bad aspect of the prosthesis, difficulty cleaning, and bleeding during hygiene practices and bad taste.

During the investigation of the patient's history, she noted that she had undergone unsuccessful surgery for implantation and a simultaneous bone graft in the area corresponding to tooth agenesis of the right upper lateral incisor the year before.

The patient had postoperative periapical radiographs, and it was possible to visualize the presence of an implant, which was located in the middle third of the right superior canine mesial root surface and was facing the coronary third. The distal proximal surface of the right upper central incisor was preserved (Figure 1). The patient recalled that she felt severe pain in the postoperative period, and the implant was removed at this point in the patient's treatment course. She also reported good overall health.

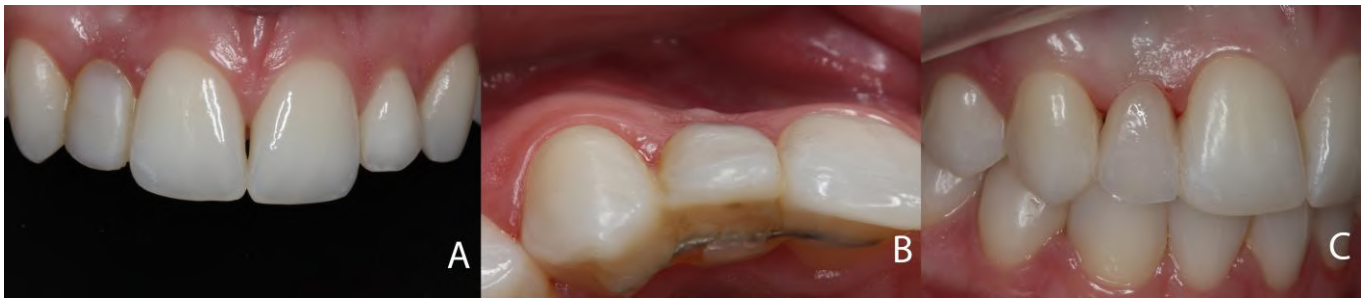**Figure 1:** X-ray image evidencing failure in the initial implant position.



Source: Own authorship.

In the clinical examination, a resin adhesive prosthesis was glued to the adjacent teeth with the aid of an orthodontic wire and composite resin, and the tissue margins appeared swollen. Because of the complaints and observed conditions, the prosthesis was removed, and a new adhesive prosthesis was initially made to promote hygiene and emotional comfort for the patient (Figures 2a, 2b and 2c).

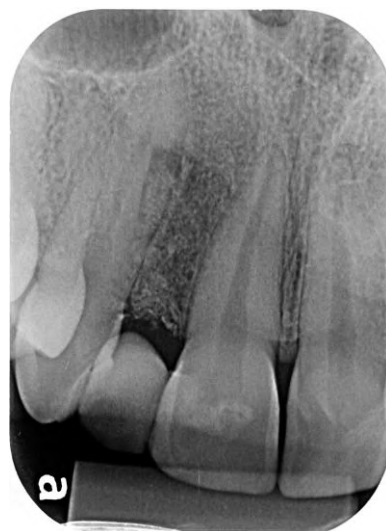**Figure 2:** 2a- initial front view of the smile; 2b- incisal view of the initial resin adhesive prosthesis; 2c- new resin adhesive prosthesis in place.



Source: Own authorship.

Subsequently, a periapical radiographic examination of the area was requested, showing an interruption of the peri-cement line and a radiolucent area in the middle third of superior right canine, suggesting external root resorption. This finding was asymptomatic due to a lack of pulp involvement. In this case, external root resorption was caused by the loss of dental structure, which was generated by contact of the implant with the root structure. Additionally, the presence of trabecular bone in the whole implant socket was noted (Figure 3).

**Figure 3:** X-ray image revealing interruption of the peri-cement line, radiolucent area in the middle third of the tooth 13, and presence of trabecular bone in the implant socket.



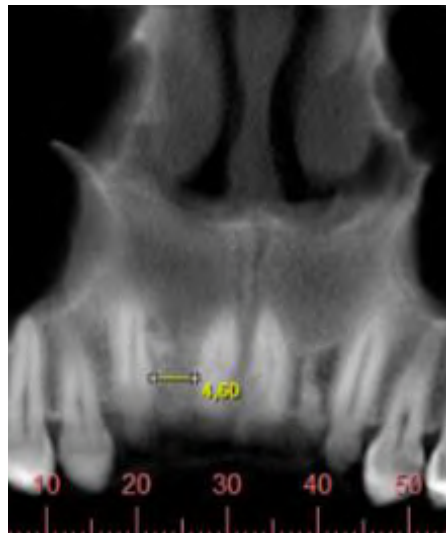
Source: Own authorship.

Given the favorable aesthetic conditions presented by the new fixed prosthesis and the restoration of the health of the surrounding soft tissue, a case control was chosen since the prognosis of tooth 13 was unclear. In addition, the patient clearly expressed a preference to retry implantation if possible.

After 3 years, there was no report of spontaneous pain, and a computed tomography scan of the area was requested. Once the causal factor had been removed, inflammatory resorption remained without compromising pulp integrity.

The dimensions of the edentulous area were measured; the smallest interradicular space at the intersection of the cervical and coronary thirds of teeth 11 and 13 was 4.6 mm, the bone tissue height was 13.00 mm, and the thickness ranged between 4.69 and 5.52 mm (Figure 4).

**Figure 4:** Interradicular space of 4,6 mm evidenced in the computed tomography image.



Source: Own authorship.

At this time, the plan to install a tapered implant with a diameter of 2.9 mm and a height of 12 mm was developed, with the intent to leave a tooth/implant space of 0.85 mm.

Local anesthesia was then performed, and the prosthesis was removed without rendering the pontic unusable.

Then, an intrasulcular incision was made from tooth 13 mesial to tooth 11 distal, following the crest of the alveolar ridge.

Afterward, a full-thickness flap was retracted, in both the buccal and palatal directions, to the height of the cementum-enamel junction of the teeth adjacent to the edentulous area to visualize the entire thickness of the rim in this area.

A sharp drill with a 1.6 mm diameter (Straumann Dental Implant System) was centered in the space, in both the mesiodistal and buccal-palatine directions, and drilling began under irrigation (saline) and a velocity of 800 revolutions per minute (rpm). The first millimeters of the osteotomy were performed, and at each millimeter of drilling, radiographic scans were taken until the root strangulation region was exceeded.

From the depth of 4 mm, parallelism with the adjacent teeth was verified, and once risk of injury to those teeth was eliminated, drilling continued until the necessary depth of 12 mm was reached.

The 2.2 mm thick helical pilot drill was also used under irrigation and at a constant speed of 800 rpm. With the alignment pin, parallelism and the depth were assessed and approved.

The final preparation of the socket was performed by the 2.9 mm diameter profile drill at 300 rpm, and threading was performed with the thread promoter at 15 rpm to a depth of 8 mm, completing this step.

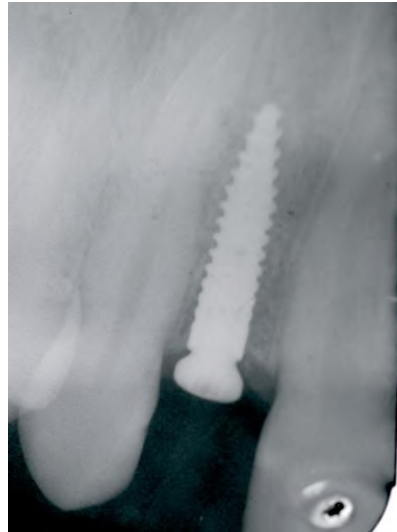The implant (BLT 2.9 mm SC, Loxim SLActive® 12 mm, TiZr - Straumann Dental Implant System) was installed with ratchet assistance, and high primary locking was obtained. A ½ mm locking screw was installed.

To correct the buccal concavity and minimize possible shadows related to the titanium implant, a subepithelial

connective graft, whose donor area was the mucosal region of the palate on the same side, was performed. The recipient area comprised the entire interdental space underlying the pre-existing keratinized mucosa and was divided by a partial flap.

To stabilize the subepithelial graft, a periosteum suture in the middle third of the keratinized mucosa, as well as two simple sutures in the region of future papillae, was performed. At the end, a periapical radiograph was performed by the parallelism technique, and the radiograph confirmed perfect positioning of the implant in relation to the adjacent natural pillars (Figure 5).

**Figure 5:** X-ray image evidencing correct implant positioning.



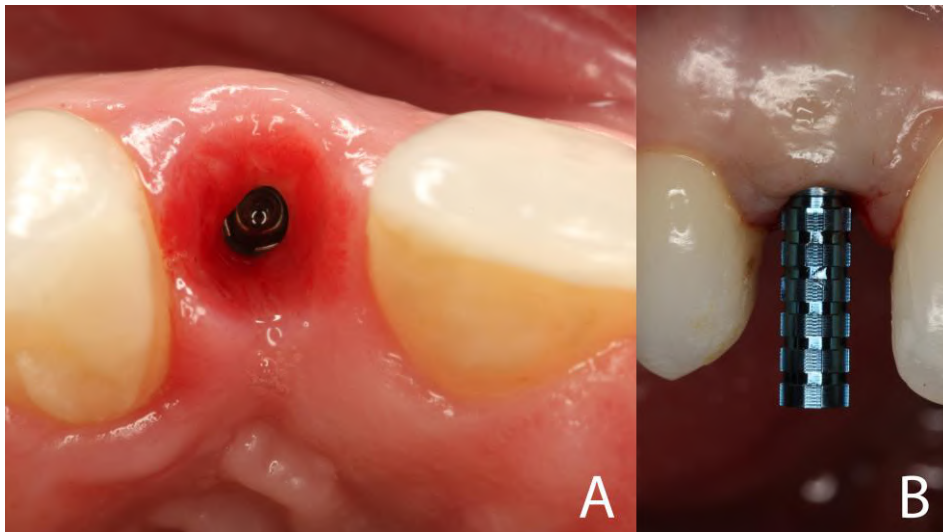
Source: Own authorship.

The pontic was reinstalled with the aid of an orthodontic wire and composite resin. Ten days after surgery, the suture was removed.

After 3 months, the provisional adhesive prosthesis and closure screw were removed (Figure 6a), and with a temporary abutment (Straumann Dental Implant System (Figure 6b), an immediate provisional restoration was screwed onto the implant.



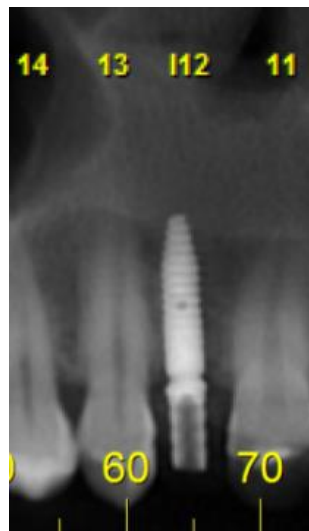**Figure 6:** **6a-** Intra-oral incisal view revealing healthy gingival peri-implant condition. **6b-** Temporary abutment fixed for immediate provisional construction.



Source: Own authorship.

Then, a new tomographic examination was requested to assess the postoperative conditions, including the conditions related to resorption in tooth 13. Regarding inflammatory resorption, once the causal factor was removed, according to the tomographic images, there were signs of repair of the area, and according to the results of a pulp sensitivity test, the pulp integrity was maintained (Figure 7).

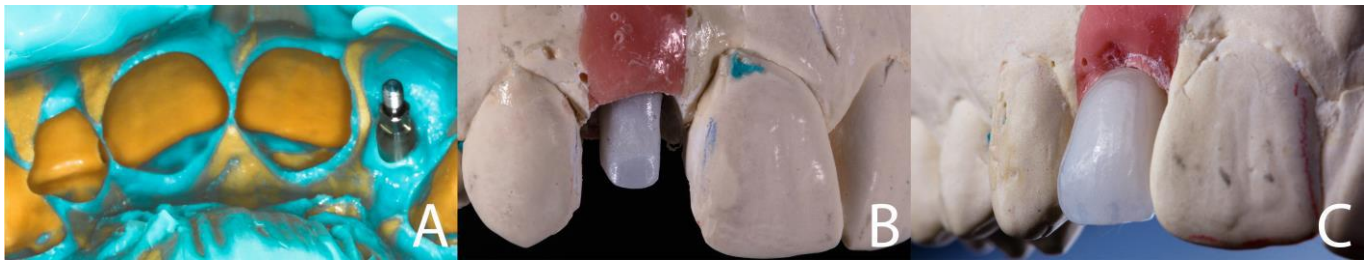
**Figure 7:** Computed tomography image revealing repair of the tooth 13 radicular resorption.



Source: Own authorship.

In the following session, after gingival conditioning occurred, the provisional restoration was removed, and the implant head was transferred with vinyl polysiloxane (Panasil, Ultradent) (Figure 5). The antagonist arch was molded with an irreversible hydrocolloid impression material. The models were created in type IV stone plaster. A titanium abutment was customized using zirconia (Zr Armann Girrbach), and a lithium disilicate monolithic ceramic crown (IPS e.max Ceram, Ivoclar Vivadent) was built on the abutment (Figure 8a, 8b and 8c).

**Figure 8:** **8a-** VPS impression with transfer. **8b-** Titanium abutment customized with zirconia. **8c-** final lithium disilicate crown.



Source: Own authorship.

The pillar was previously tested, and the crown adapted. Proximal adjustments were not necessary. Contacts at maximal intercuspal clearance, in addition to lateral contacts, were relieved the prosthesis was allowed to participate in the anterior guide. The prosthesis was allowed to participate in the previous guide. Then, with ceramic polishing rubbers, these areas were finished.

A torque of 32 newtons was applied to the abutment screw, as recommended by the manufacturer. The screw access cavity was sealed with Teflon tape.

Then, the inner portion of the ceramic restoration was conditioned by hydrofluoric acid for 20 seconds and was vigorously washed and dried. A 37% phosphoric acid solution (FGM, Brazil) was applied to remove the precipitate. A universal primer layer (Monobond Plus, Ivoclar Vivadent, Germany, Liechtenstein) was applied, air blast dried and photoactivated for solvent volatilization. Then, one coat of dental adhesive (Adper Single Bond 2, 3M ESPE) was applied.

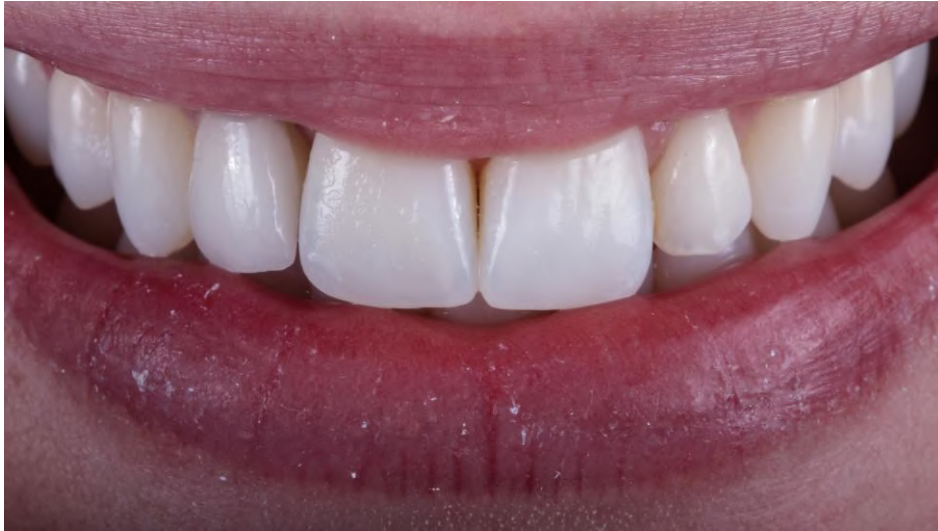Semiabsolute isolation of the operative field was performed (Madeitex rubber sheet) with high power suction. A conventional resin cement layer (Rylex Venner - 3M Espe), shade A1, was applied inside the crown, and it was then positioned. Excess cement was removed with a microbrush brush. The outer margins, vestibular and palatine faces were photoactivated for 60 seconds on each side.

At the end of the cementation process, the cement residues were removed with a scalpel blade 12 (Lamedid Solidor). A periapical X-ray scan was performed using the parallelism technique to ensure that excess cement was completely removed and to visualize the final adaptation of the restoration.

Thus, it was possible to complete the processes required to restore the soft tissue health, dental aesthetics, and self-esteem of the patient (Figure 9). After 12 months postoperatively, positive conditions related to the stability and health of the gingival margins, as well as a favorable implant response to the imposed loads, were noted (figure 10). Annual visits to control the tissue margin stability and implant conditions and to understand the behavior and longevity of the small-diameter implant considered here were suggested for the patient.

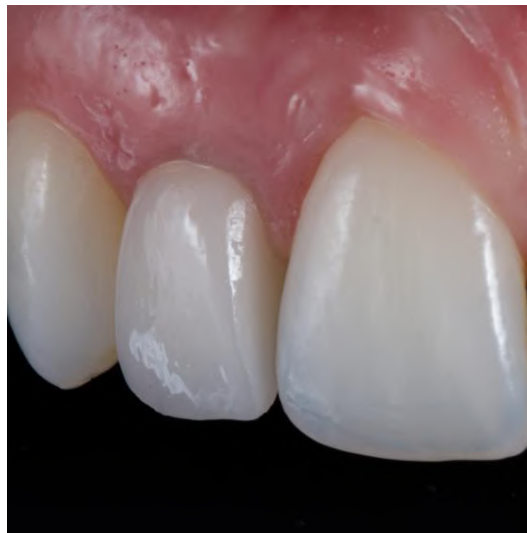

**Figure 9:** Final view of the smile.



Source: Own authorship.

**Figure 10:** Final aspect of the implant and crown restoration evidencing healthy gingival margins.



Source: Own authorship.

#### **4. Discussion**

In the field of oral implantology, increasingly more minimally invasive surgical materials and techniques are being developed. These developments emerge as treatment alternatives to standard concepts, which require additional surgeries to modify the bone architecture in order to adapt periodontal support to the implants of lengths and diameters that were previously available (Pommer et al., 2016)

Thus, small-diameter implants were introduced, which are classified as those with a diameter between 3.0 and 3.75 mm. Larger implants with diameters greater than 3.75 mm have emerged as an option since, especially in cases with reduced horizontal spaces, the risk for trauma to adjacent teeth, as in the case mentioned here, is high, in addition to the risk for tissue loss proximal to the bone (Trbakovic, et al., 2018).

The use of small-diameter implants is becoming more common, and especially for the anterior mandible, these implants are proving to be the most viable option. Narrow-diameter implants are also very well suited for replacing unit areas

in the aesthetic zone of the jaw due to the limited horizontal dimension (Yaltirik et al., 2011; Hof et al., 2013).

These implants, in turn, present a higher risk for fracture than do large-diameter implants since they have less mechanical stability and, consequently, an increased risk for failure due to overload, thus contributing to an increase in technical complications (Yaltirik et al., 2011). Lee *et al.*, (2019) reported a fracture rate for small-diameter implants that was 6 times higher than that for large-diameter implants, but implant fractures are rarely observed.

According to a 12-year retrospective study, such fractures are related to the absence of bone grafts, the absence of micro threads, implants located in all areas, except for the anterior mandible, and small-diameter implants. However, after 90 months, the diameter was no longer associated with the risk for fractures. Additionally, most fractures occurred in the posterior region.<sup>6</sup> These findings corroborate those reported by Zweers *et al.*, (2015), who explained the findings by the use of small-diameter implants in the mandible region, such as fixed prosthesis abutments and overdentures. In this region, the construction of these types of prostheses is very common, which favors the incidence of lateral loads and a lower resistance to their dissipation due to the configuration of these implants. Trbakovick *et al.*, (2018) reported the survival rate of small-diameter implants to be 100% over a period of 5 years and 97.2% after 9 years. For conventional implants, Sohrabi *et al.*, (2012) found a similar survival rate for conventional implants, where 97% survival was found. Pommer *et al.*, (2016) compared the survival rates of narrow and guided implants and found that the rate was higher in the maxilla than in the mandible (97.6% vs. 94.7%,  $P < 0.001$  and 98.5% vs 90.7%,  $P = 0.012$ ).

It is worth noting that, regardless of the implant diameter, it is important to consider the amount of mechanical fatigue on the implant abutments. Dental implants are constantly subjected to repeated masticatory loading cycles throughout their lifetime (Duan & Griggs, 2018).

To preserve the peri-implant tissues, the literature recommends a bone thickness around the implants between 1.5 and 3 mm (Grunder, et al., 2005; Esposito, et al., 1993).

Regarding the tooth-implant distance, the shorter tooth-implant distance is controversial (Cardaropoli, et al., 2003; Martin, et al., 2009). It is not uncommon to rehabilitate borderline conditions with small-diameter implants, where a bone thickness of less than one millimeter is observed between the tooth and implant (Galindo-Moreno et al., 2017). However, whether the bone crest can be preserved is questioned, and necrosis of adjacent teeth can develop due to the implantation of implants in very small spaces (Trbakovic, et al., 2018; Grunder, et al., 2005; Esposito, et al., 1993). However, recent data have shown that small-diameter implants (3.0 mm) are installed in small areas. A final tooth-implant distance of <1.5 mm yielded less marginal bone loss at the 3-year follow-up (Galindo-Moreno et al., 2017).

The stress concentration around the bone-implant interface is an important factor to consider for marginal bone preservation. The area where the first threads of an osseointegrated implant are located is invariably more susceptible to bone resorption.<sup>19</sup> This change is commonly observed after the implant is placed. Maeda *et al.*, (2007) demonstrated a vertical reduction of the bone crest by 1.5 to 2.0 mm from the pillar junction/implant after the implants came into function. However, in cases with unitary prostheses, this amount of resorption may be reduced or even nonexistent when the selected abutment presents a reduced platform in relation to the implant platform. This concept is considered the switching platform concept, which is characterized by a circumferential difference between the prosthetic component and the implant platform, which is present when there is a conical internal connection. Radiographic follow-ups conducted after more than 13 years showed smaller amounts of vertical change in the bone crest height when abutments with diameters smaller than those of the implants were selected. This result was associated with gains in the thickness of the surrounding tissues the bone crest region, which favored the homeostasis of the periodontal support tissues (Lazzara & Porter, 2006). Similarly, compared to external connections, internal prosthetic connections have been shown to be more favorable in the dissipation of both lateral and shear loads to the alveolar bone since the force acting on the center of this type of connection is better positioned. (Maeda *et al.*,

2006). Thus, for bone loss around implants to be within clinically acceptable standards, prosthetic planning is of paramount importance.

In the present report, a tooth-implant distance of 0.85 mm was allowed, which is in accordance with that reported in the literature (Galindo-Moreno et al., 2017), and a conical internal configuration and switching platform were used, which favor the preservation of the peri-implant bone crest.

In addition to the reduced interdental and bone dimensions for implant placement, another complicating factor lies in the consequently thin vestibular mucosa. Vestibular discoloration and gingival recession are also aspects that are commonly analyzed (Trbakovic, et al., 2018; Jung et al., 2012). In their study, Trbakovick *et al.*, (2018) highlighted that the main problems were vestibular discoloration, periodontal sacs and gingival recession.

Therefore, it is not uncommon for patients to complain about mucosal discoloration in the peri-implant area related to small spaces, which was also noted in this report. The previously observed negative aspect, related to the discoloration of the subepithelial mucosa, was improved by the connective graft proposed and performed here, which corrected the conic configuration of the vestibular aspect, and prevented possible gingival recession.

During the proservation period of the clinical case reported here, none of the previously mentioned problems were encountered. In the case of marginal discoloration and gingival recession, change in the gingival biotype from thin to thick, from the subepithelial connective graft, in addition to the well-adapted and finished prosthetic margins justify satisfactory aesthetic and biological results.

Regarding the possibility of a 2.9 mm implant fracture, it is noteworthy that occlusal adjustments and consequent stress distributions along the implant abutment contribute to a favorable long-term prognosis. Loads were not focused on the long axis of the implant, and lateral loads were removed. Only shear loads at the anterior guide were allowed, which are well tolerated by both natural abutments and implant abutments located in the lateral incisor region.

Other alternatives to rehabilitate the case presented here, in addition to an implant prosthesis, include an orthodontic approach or a fixed adhesive prosthesis. In terms of decision hierarchy, the most relevant issue is the prognosis related to each of the treatments.<sup>5</sup> In terms of orthodontic therapy, the possibility of increasing space and thus installing an implant of larger diameter was investigated. However, in addition to orthodontic therapy, an additional bone graft is required to increase the buccal-palatal width, further extending the morbidity of the case. It's worth mentioning that the patient had a stable occlusion and a class I type of occlusion according to Angle's classification. In addition, the inflammatory resorption condition in the tooth 13, once the causal factor was removed, could be repaired while maintaining pulp integrity. Orthodontic movement could reactivate the inflammatory resorption process.

Nevertheless, regarding the orthodontic interventions, one could think of closing the space and mesialize the canines. Thus, a surgical intervention can be avoided, as noted by Aspinwall-Rezende *et al.*, (2018). Regarding rehabilitation with a fixed adhesive prosthesis, there is still dental wear. Jung *et al.*, (2012) recalled that regarding unitary substitutions, the criteria for decision making should be guided essentially by scientific evidence and objective surgical and prosthetic criteria, and clinical and financial conditions should be considered. Therefore, because it was a stable occlusion, orthodontic therapy and/or an adhesive prosthesis were discarded, which reinforces the claim that implant therapy should be the first-line option for partial or total edentulous patients (Jugn et al., 2012).

In the present study, an average tooth-implant distance of 0.85 mm was found; therefore, the bone thickness was smaller than that recommended by most studies. However, according to a retrospective analysis of previous tomographic findings, compared with those after implantation, during the follow-up period considered here, there was no additional interproximal bone loss, and additional damage to the adjacent teeth was prevented.

## 5. Conclusion

From the results described, it can be concluded that in implantology, as in other fields, the concept of minimally invasive dentistry is becoming an effective surgical approach. Thus, small-diameter implants were introduced to enable the rehabilitation of edentulous areas devoid of the minimum dimensions required for the installation of conventional implants, and the small-diameter implants do not require additional bone grafts. According to this study, it was possible to rehabilitate the case presented here safely, effectively and with few morbidities and restore function and aesthetics with excellence.

## References

- Allum, S. R., Tomlinson, R. A., & Joshi, R. (2008). The impact of loads on standard diameter, small diameter and mini implants: a comparative laboratory study. *Clinical oral implants research*, 19(6), 553–559. <https://doi.org/10.1111/j.1600-0501.2007.01395.x>
- Aspinwall-Rezende, P. O., França, E. C., Lombardi, M. A., Drummond, A. F., Pretti, H., Martins, A. V., & Albuquerque, R. C. (2018). Orthodontic and restorative treatment of avulsed upper central incisors. *Journal of clinical orthodontics: JCO*, 52(10), 563–570.
- Busenlechner, D., Fürhauser, R., Haas, R., Watzek, G., Mailath, G., & Pommer, B. (2014). Long-term implant success at the Academy for Oral Implantology: 8-year follow-up and risk factor analysis. *Journal of periodontal & implant science*, 44(3), 102–108. <https://doi.org/10.5051/jpis.2014.44.3.102>
- Cardaropoli, G., Wennström, J. L., & Lekholm, U. (2003). Peri-implant bone alterations in relation to inter-unit distances. A 3-year retrospective study. *Clinical oral implants research*, 14(4), 430–436. <https://doi.org/10.1034/j.1600-0501.2003.00895.x>
- Duan, Y., & Griggs, J. A. (2018). Effect of loading frequency on cyclic fatigue lifetime of a standard-diameter implant with an internal abutment connection. *Dental materials*, 34(12), 1711–1716. <https://doi.org/10.1016/j.dental.2018.09.001>
- Duan, Y., Gonzalez, J. A., Kulkarni, P. A., Nagy, W. W., & Griggs, J. A. (2018). Fatigue lifetime prediction of a reduced-diameter dental implant system: Numerical and experimental study. *Dental materials*, 34(9), 1299–1309. <https://doi.org/10.1016/j.dental.2018.06.002>
- Esposito, M., Ekkestubbe, A., & Gröndahl, K. (1993). Radiological evaluation of marginal bone loss at tooth surfaces facing single Brånemark implants. *Clinical oral implants research*, 4(3), 151–157. <https://doi.org/10.1034/j.1600-0501.1993.040306.x>
- Froum, S., Natour, M., Cho, S.-C., Yu, P., & Leung, M. (2020). Expanded Clinical Applications of Narrow-Diameter Implants for Permanent Use. *The International Journal of Periodontics & Restorative Dentistry*, 40(4), 529–537. doi:10.11607/prd.4565
- Galindo-Moreno, P., Padijal-Molina, M., Nilsson, P., King, P., Worsaae, N., Schramm, A., & Maiorana, C. (2017). The influence of the distance between narrow implants and the adjacent teeth on marginal bone levels. *Clinical oral implants research*, 28(6), 704–712. <https://doi.org/10.1111/clr.12867>
- Gross, M., & Laufer, B. Z. (1997). Splinting osseointegrated implants and natural teeth in rehabilitation of partially edentulous patients. Part I: laboratory and clinical studies. *Journal of oral rehabilitation*, 24(11), 863–870. <https://doi.org/10.1046/j.1365-2842.1997.00582.x>
- Grunder, U., Gracis, S., & Capelli, M. (2005). Influence of the 3-D bone-to-implant relationship on esthetics. *The International journal of periodontics & restorative dentistry*, 25(2), 113–119.
- Hof, M., Pommer, B., Strbac, G. D., Sütö, D., Watzek, G., & Zechner, W. (2013). Esthetic evaluation of single-tooth implants in the anterior maxilla following autologous bone augmentation. *Clinical oral implants research*, 24 Suppl A100, 88–93. <https://doi.org/10.1111/j.1600-0501.2011.02381.x>
- Jung, R. E., Zembic, A., Pjetursson, B. E., Zwahlen, M., & Thoma, D. S. (2012). Systematic review of the survival rate and the incidence of biological, technical, and aesthetic complications of single crowns on implants reported in longitudinal studies with a mean follow-up of 5 years. *Clinical oral implants research*, 23 Suppl 6, 2–21. <https://doi.org/10.1111/j.1600-0501.2012.02547.x>
- Lazzara, R. J., & Porter, S. S. (2006). Platform switching: a new concept in implant dentistry for controlling postrestorative crestal bone levels. *The International journal of periodontics & restorative dentistry*, 26(1), 9–17.
- Lee, D. W., Kim, N. H., Lee, Y., Oh, Y. A., Lee, J. H., & You, H. K. (2019). Implant fracture failure rate and potential associated risk indicators: An up to 12-year retrospective study of implants in 5,124 patients. *Clinical oral implants research*, 30(3), 206–217. <https://doi.org/10.1111/clr.13407>
- Maeda, Y., Miura, J., Taki, I., & Sogo, M. (2007). Biomechanical analysis on platform switching: is there any biomechanical rationale?. *Clinical oral implants research*, 18(5), 581–584. <https://doi.org/10.1111/j.1600-0501.2007.01398.x>
- Maeda, Y., Satoh, T., & Sogo, M. (2006). In vitro differences of stress concentrations for internal and external hex implant-abutment connections: a short communication. *Journal of oral rehabilitation*, 33(1), 75–78. <https://doi.org/10.1111/j.1365-2842.2006.01545.x>
- Magnússon T. E. (1977). Prevalence of hypodontia and malformations of permanent teeth in Iceland. *Community dentistry and oral epidemiology*, 5(4), 173–178. <https://doi.org/10.1111/j.1600-0528.1977.tb01635.x>
- Martin, W., Lewis, E., & Nicol, A. (2009). Local risk factors for implant therapy. *The International journal of oral & maxillofacial implants*, 24 Suppl, 28–38.
- Pereira, A. S., Shitsuka, D. M., Parreira, F. J., & Shitsuka, R. (2018). Metodologia da pesquisa científica. UFSM.

Pommer, B., Busenlechner, D., Fürhauser, R., Watzek, G., Mailath-Pokorny, G., & Haas, R. (2016). Trends in techniques to avoid bone augmentation surgery: Application of short implants, narrow-diameter implants and guided surgery. *Journal of cranio-maxillo-facial surgery*, 44(10), 1630–1634. <https://doi.org/10.1016/j.jcms.2016.08.012>

Sohrabi, K., Mushantat, A., Esfandiari, S., & Feine, J. (2012). How successful are small-diameter implants? A literature review. *Clinical oral implants research*, 23(5), 515–525. <https://doi.org/10.1111/j.1600-0501.2011.02410.x>

Trbakovic, A., Bongenhielm, U., & Thor, A. (2018). A clinical and radiological long-term follow-up study of narrow diameter implants in the aesthetic area. *Clinical implant dentistry and related research*, 20(4), 598–605. <https://doi.org/10.1111/cid.12627>

Yaltirik, M., Gökçen-Röhlig, B., Ozer, S., & Evlioglu, G. (2011). Clinical evaluation of small diameter straumann implants in partially edentulous patients: a 5-year retrospective study. *Journal of dentistry* (Tehran, Iran), 8(2), 75–80.

Zweers, J., van Doornik, A., Hogendorf, E. A., Quirynen, M., & Van der Weijden, G. A. (2015). Clinical and radiographic evaluation of narrow- vs. regular-diameter dental implants: a 3-year follow-up. A retrospective study. *Clinical oral implants research*, 26(2), 149–156. <https://doi.org/10.1111/clr.12309>