

Tracheal intraluminal canine pythiosis: case report

Pitiose traqueal intraluminal canina: relato de caso

Pitiosis intraluminal traqueal canina: reporte de caso

Received: 08/27/2022 | Reviewed: 09/09/2022 | Accept: 09/10/2022 | Published: 09/18/2022

Tales Santos Assis

ORCID: <https://orcid.org/0000-0003-0771-2775>
Universidade Federal de Campina Grande, Brazil
E-mail: diagnosticosporimagens@gmail.com

Almir Pereira de Souza

ORCID: <https://orcid.org/0000-0002-8587-5724>
Universidade Federal de Campina Grande, Brazil
E-mail: almir@cstr.ufcg.edu.br

Glauco José Nogueira de Galiza

ORCID: <https://orcid.org/0000-0002-0551-1964>
Universidade Federal de Campina Grande, Brazil
E-mail: ggaliza@yahoo.com

Antônio Flávio Medeiros Dantas

ORCID: <https://orcid.org/0000-0002-6123-2273>
Universidade Federal de Campina Grande, Brazil
E-mail: antonioflaviomd@gmail.com

Alan Glayboon de Freitas Oliveira

ORCID: <https://orcid.org/0000-0002-0221-3232>
Universidade Federal de Campina Grande, Brazil
E-mail: glayboonvet@hotmail.com

Elayne Cristina Lino de Oliveira

ORCID: <https://orcid.org/0000-0002-6672-7750>
Faculdade Nova Esperança, Brazil
E-mail: elayneoliver17@gmail.com

Aline Carla de Medeiros

ORCID: <https://orcid.org/0000-0002-0161-3541>
Universidade Federal de Campina Grande, Brazil
E-mail: alinecarla.edu@gmail.com

Abstract

This article reports a case of tracheal pythiosis in a dog with a clinical symptom of cough followed by retching with a suspected foreign body. Radiographic imaging showed a mass with soft tissue density in the tracheal lumen. The patient underwent an emergency tracheostomy due to respiratory failure caused by the obstruction, during which we found a reddish granulomatous, well-delimited macroscopic structure in the cervical segment of the trachea. The histopathological microscopic examination of the fragment revealed a granulomatous transmural tracheitis associated with hyphae compatible with *Pythium insidiosum*. The hyphae were strongly immunostained with anti-*Pythium insidiosum* polyclonal antibody, confirming the diagnosis of pythiosis based on epidemiology, clinical, and histopathological findings. However, 12 hours after the surgery, the animal died due to cardiopulmonary arrest.

Keywords: Dog; Pythiosis; Trachea.

Resumo

O trabalho relata um caso de pitiose traqueal em um cão que apresentou como queixa clínica tosse seguida de ânsia de vômito com suspeita de corpo estranho. Através dos exames de imagem, na radiografia, foi observada massa com densidade de tecidos moles, no lúmen traqueal. O paciente foi submetido a procedimento cirúrgico de emergência (traqueostomia) devido ao quadro de insuficiência respiratória causado pela obstrução onde visualizou macroscopicamente uma estrutura granulomatosa avermelhada, bem delimitada, localizada no segmento cervical da traqueia. Após coleta do fragmento para exame histopatológico, microscopicamente, observou-se traqueíte transmural granulomatosa associada a hifas compatíveis com *Pythium insidiosum*. As hifas foram fortemente imunomarcadas com anticorpo policlonal anti-*Pythium insidiosum* onde confirmou diagnóstico de pitiose que é baseado na epidemiologia, clínica e achados histopatológicos. Entretanto, após 12 horas de pós-operatório o animal veio a óbito por parada cardiorrespiratória.

Palavras-chave: Pitiose; Traqueia; Cão.

Resumen

El artículo reporta un caso de pitiosis traqueal en un perro que presentó como queja clínica tos seguida de arcadas con sospecha de cuerpo extraño. Mediante pruebas de imagen, en la radiografía se observó una masa con densidad de partes blandas en la luz traqueal. El paciente fue intervenido quirúrgicamente de urgencia (traqueotomía) por insuficiencia respiratoria provocada por la obstrucción, donde macroscópicamente visualizó una estructura granulomatosa rojiza, bien delimitada, localizada en el segmento cervical de la tráquea. Tras la recogida del fragmento para estudio histopatológico, al microscopio se observó traqueítis transmural granulomatosa asociada a hifas compatibles con *Pythium insidiosum*. Las hifas fueron fuertemente inmunoteñidas con anticuerpo policlonal anti-*Pythium insidiosum* que confirmó un diagnóstico de pitiosis que se basa en hallazgos epidemiológicos, clínicos e histopatológicos. Sin embargo, 12 horas después de la operación, el animal falleció a causa de un paro cardiorrespiratorio.

Palabras clave: Pitiosis; Tráquea; Perro

1. Introduction

Described in tropical, subtropical and temperate regions, pythiosis is a disease chronic granulomatous disease, capable of infecting animals and humans, not being reported direct transmission between animals and from animals to humans (Santurio et al., 1998; Mendoza et al., 2005; Gaastra et al., 2010)

The disease has a worldwide distribution, in tropical, subtropical, and temperate regions, and affects animals with access to wet or swampy areas (Gaastra 2010). The infective forms have tropism for furs and can penetrate breaks in the skin and mucous membranes (Santurio et al., 2006; Hunning et al., 2010; Mari et al., 2013).

Several studies reported canine pythiosis in Paraíba, Brazil, describing the gastroenteric form of the disease (Smith et al., 1989; Fischer et al., 1994; Patton et al., 1996; Helman & Oliver, 1999; Firmino & Frade et al., 2017). Pythiosis was found in skin lesions of cattle, goats, horses, mules, donkeys, dogs, and cats; in the nasal cavity of horses (Tabosa et al., 1999) and sheep; in pre-stomachs of sheep; in esophagus of ostrich; and the gastrointestinal forms in dogs and cats.

Canines are the second mammal family most affected by pythiosis, both in the cutaneous and gastrointestinal forms (Leal et al 2001). The first report of canine pythiosis in Brazil occurred in 1997 in São Paulo involving a female dog with skin lesions on the left pelvic limb (Larsson et al., 1997). In the dog, it manifests in a chronic/progressive form and is potentially fatal in most cases. The diagnosis of pythiosis relies on clinical and histopathological characteristics, isolation, and identification of the agent through its morphological cultural characteristics. Dogs commonly develop the gastrointestinal form with digestive disorders and nodular masses (Miller et al., 1983; Smith et al., 1989; Fischer et al., 1994).

Pythiosis gastrointestinal lesions are characterized by the formation of large masses in the gastric and intestinal walls composed of granulomatous and pyogranulomatous inflammation with areas of necrosis, intense eosinophilic infiltrate, and the presence of hyphae (Smith et al., 1989; Fischer et al., 1994). The upper digestive tract can also be affected. Patton et al. (1996) reported two cases of chronic esophagitis due to *Pythium insidiosum* infection. Helman and Oliver (1999) observed an oropharyngeal mass affecting the larynx and cranial esophagus. The proximity of digestive and respiratory tracts, in pharynx region, causes concerns due to the chance of infections in respiratory system by contiguity. Given this condition and the lack of description of respiratory forms of the disease in dogs, in this work, we report a case of pythiosis in the tracheal lumen of a dog.

2. Methodology

This is a qualitative study, characterized as a case study. The description of the study started from the analysis of a dog with clinical evidence of tracheal intraluminal canine pythiosis, where medical strategies were initially designed to diagnose the case. Finally, the clinical routine of the dog was described, observing the results of exams, image evaluation and other protocols.

3. Case Report

The case involved a two-year-old Maltese dog weighing 3.5 kg, raised in a home environment. The animal presented cough followed by retching, dyspnea, and cyanosis with the complaint of choking and suspicion of a possible foreign body for approximately one week.

The dog underwent a radiographic examination. In the first appointment, we performed orthogonal projections of the cervical and thoracic regions, which revealed an increase in radiographic density in the larynx (glottic region) and increased opacity of the tracheal rings (mineralizations). The cardiac silhouette was preserved and the lung fields showed no signs of bronchitis, edema, or effusion. The diaphragmatic dome and thoracic musculoskeletal structures were visualized and preserved. There was no evidence of a foreign body in the esophageal and tracheal lumen.

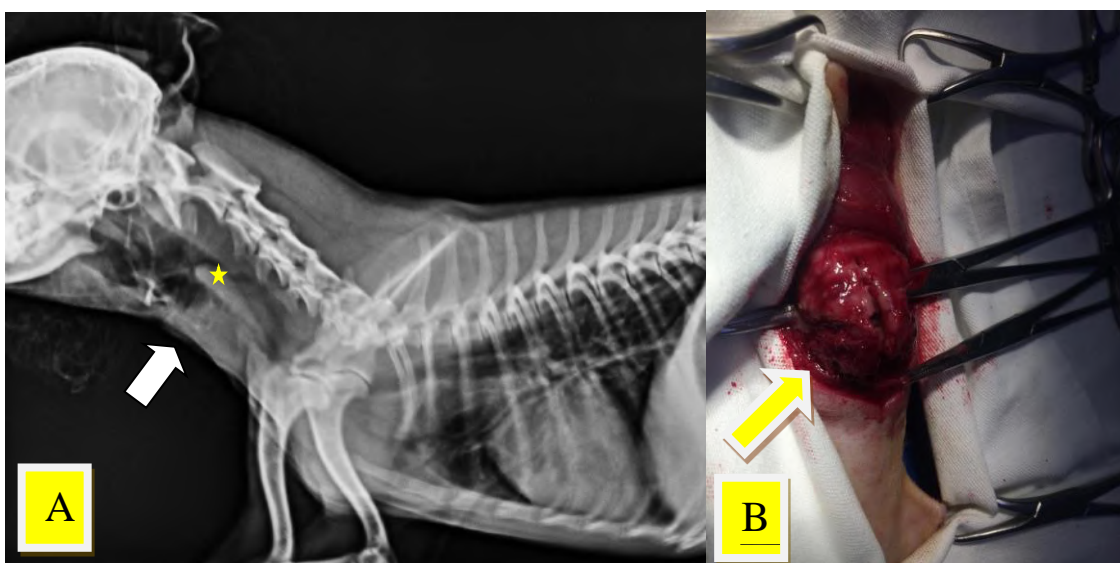
A tracheoscopy was suggested to investigate the radiographic findings. Still, the tutor did not agree to perform the exam and we prescribed a conservative treatment with prednisolone at a dose of 1mg/kg for 7 days.

After five months, the animal returned with worsening clinical status, showing anorexia, mixed dyspnea, respiratory distress, cyanosis, and tachycardia. The physical examination revealed an increased volume with firm consistency in the cranial cervical trachea.

A cervical radiographic examination in a latero-lateral projection was performed, which showed a rounded intraluminal area with a density similar to soft tissues in the cervical trachea, suggesting a granuloma, mass, with a radiographic density of water indicating mucus, with mineralization in the tracheal rings, but with preserved lung fields (FIGURE 1A).

The animal was referred for an emergency surgical procedure (tracheostomy) due to the clinical picture of respiratory distress. A granulomatous structure was visualized adhered to the tracheal lumen without the possibility of removal (FIGURE 1B), from which samples were taken for histopathological analysis. A permanent tracheostomy was chosen due to the size and location of the lesion. However, 12 hours after the operation, the animal died due to cardiopulmonary arrest.

Figure 1. Tracheal granuloma in a dog diagnosed with tracheal pythiosis. **A)** Radiographic image in lateral cervical projection with the presence of structure in the tracheal lumen with soft tissue density. **B)** Exploratory surgery of the trachea, visualizing a reddish mass in the lumen adhered to the tracheal wall.

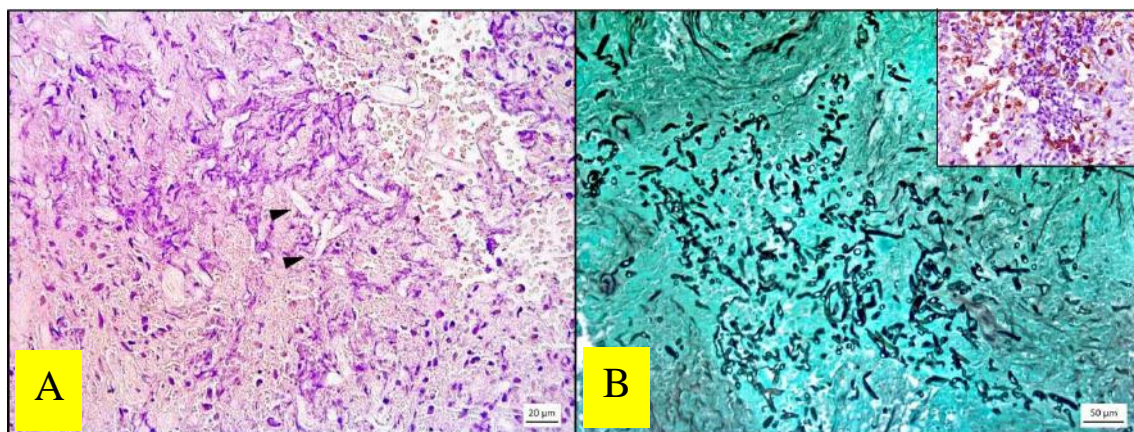


Source: Authors.

The microscopic analysis of samples collected for biopsy showed transmural distention of the tracheal wall by a substantial inflammatory infiltrate consisting of macrophages, Langhans-type multinucleated giant cells, and intact and degenerated neutrophils, associated with multifocal to coalescing areas of necrosis with numerous negative tubuliform hypha-like images, visualized in transversal and longitudinal sections (FIGURE 2A). The Grocott silver methenamine (GMS) histochemical staining impregnated the hyphae in black and showed parallel walls, irregular ramifications, rare septa, and measurements from 2 to 9 μm in diameter (FIGURE 2 B). In Periodic Acid Schiff (PAS) hyphae were faintly stained pink.

The material was submitted to immunohistochemistry analysis following the protocol described by Souto et al. (2020) with modifications. We used the anti-*Pythium insidiosum* polyclonal antibody, diluted at a ratio of 1:1000, followed by incubation with polymer (HiDef Detection™ HRP Polymer System - Cell Marque) and 3,3'-diaminobenzidine (DAB) chromogen. As a positive control, confirmed samples of equine pythiosis were used. Sections of pythiosis in horses and the case evaluated were used as negative controls, replacing the primary antibody with a phosphate-buffered solution with 0.5% polysorbate 20 (PBST). The hyphae were strongly immunostained in brown (Figure 2B).

Figure 2. Tracheal pythiosis in a dog. **A)** Tracheal mass showing negative tubuliform images in longitudinal sections amid the area of necrosis and inflammatory infiltrate (arrowheads). HE. Bar=20 μm . **B)** Tracheal mass with numerous hyphae impregnated in black. GMS Bar=20 μm . In detail, hyphae were strongly immunostained in brown with anti-*Pythium insidiosum* antibody. IHQ. DAB



Source: Authors.

4. Discussion

The beginning of pythiosis in the dog of the reported case coincided with the onset of rains in the region. As a result, places close to rivers or flooded areas in urban zones can become sources of contamination, increasing the risk of the disease. The access of animals to external environments (urban and peri-urban) and sources of stagnant water is described in almost all cases reported in the literature, and individuals usually remain submerged for some time (Martins, 2010; Nobrega et al., 2013).

In the present report, as it is an infection in the trachea, the animal may have inhaled the mobile zoospore or the infection was an extension of a primary esophageal lesion. In the case reported, the dog never had access to the countryside, however, he lived in a house next to a stream that in rainy periods overflowed into the street where the dog had contact during walks with the owner. This important information from the anamnesis was only obtained after the patient's death by investigating the place where the animal resided.

The diagnosis was made by histopathological and immunohistochemical findings. Pythiosis is usually diagnosed based on epidemiology, clinic, histopathological findings, IHC, and serological techniques (Mendoza et al., 1996; Firmino & Frade

2017). However, early identification of pythiosis is hard when based on clinical and pathological findings and the isolation and identification of the agent through its morphological and reproductive characteristics, especially in an atypical presentation of the disease.

The tracheoscopy requested in the first visit to the dog could have led to a more accurate diagnosis during the initial phase of the disease. Tracheobronchoscopy is the most reliable nonsurgical method for exploring and collecting samples from the respiratory mucosa under suspicion of inflammation and tumors (Passos et al., 2004). Early identification of pythiosis is difficult through physical, clinical, laboratory, and imaging tests such as plain radiography. Tracheoscopy would provide the most relevant information for diagnosis.

The intraluminal obstructive lesion in the radiographic image was visualized only in the advanced stage. It should be included in the differential diagnosis of obstructions such as neoplasms, polyps, or abscesses in the upper airways, as they are radiographically identical. Thus, biopsy for the histopathological study is the fastest and most accurate method for final diagnosis.

The main differential diagnosis for this disease would be a fungal infection such as Aspergillosis, caused by the saprobic and opportunistic fungi *Aspergillus* spp., or a neoplasm, but primary tumors of the trachea are uncommon in dogs and cats. Osteochondroma and epithelial tumors are the most frequent in the canine and feline trachea, respectively.

In the case reported, the tumors produced consistent clinical signs, such as airway obstruction, which affect middle-aged to older dogs, except in dogs with osteochondroma. However, our patient was young, which makes it epidemiologically less likely to be a neoplastic cause. It is not possible to differentiate inflammatory, benign, or malignant neoplasms radiographically. Cysts or abscesses may have similar radiographic features (Carlisle et al., 1991).

Cases of tracheal pythiosis in dogs, although atypical in this anatomical region, should be taken into account as a differential diagnosis of tracheal obstructions. The prognosis of this disease depends on the time of perception of the tutor and driving to the Veterinarian for diagnosis and treatment.

References

- Chaffin, M. K., Schumacher, J., & Hooper, N. (1992). *Multicentric cutaneous pythiosis in a foal. Journal of the American Veterinary Medical Association*, 201(2), 310-312.
- Carlisle, C. H., Biery, D. N., & Thrall, D. (1991). *Tracheal and laryngeal tumors in the dog and cat: literature review and 13 additional patients. Vet Radiol.* 32:229-235.
- Dykstra, M. J., Sharp, N. J. H., Olivry, T., Hillier, A., Murphy, K. M., Kaufman, G. A., Kunkle, G. A., & Pucheu-Haston, C. (1999). *A description of cutaneous-subcutaneous pythiosis in fifteen dogs. Med. Mycol.* 37(6), 427-433.
- Fischer, J. R., Pace, L. W., & Turk, J. R. (1994). *Gastrointestinal pythiosis in Missouri dogs: eleven cases. J Vet Diagn Invest*, 6, 380-382.
- Foil, C. S. O., Short, B. G., Fadok, V. A., & Kunkle, G. A. 1984. *A report of subcutaneous pythiosis in 5 dogs and a review of the etiologic agent Pythium spp. J. Am. Anim. Hosp. Assoc.* 20(6):959-966.
- Gaastra, W., Lipman, L. J. A., De Cock, A. W. A. M., Exel, T. K., Pegge, R. B. G., Scheurwater, J., Vilela, R., & Mendoza, L. (2010). *Pythium insidiosum: an overview. Veterinary Microbiology*, 146(1-2):1-16.
- Hunning, P. S., Rigon, C. T., Pavarini, A., Sampaio, D. S., Beheregaray, W. K., & Driemeier, D. 2010. *Obstrução intestinal por Pythium insidiosum em um cão: relato de caso. Arquivo Brasileiro de Medicina Veterinária e Zootecnia*, 62(4):801-805.
- Helman, R. G., & Oliver, J. *Pythiosis of the digestive tract in dogs from Oklahoma. J Am Anim Hosp Assoc*, 35(2), 111-114, 1999.
- Howerth, E. W., Brown, C. C., & Crowder, C. 1989. *Subcutaneous pythiosis in a dog. J. Vet. Diag. Invest.* 1(1), 81-83.
- Jaeger, G. H., Rotstein, D. S., & Law, J. M. 2002. *Prostatic pythiosis in a dog. J. Vet. Intern. Med.* 16(5), 598-602.
- Leal, A. T., Leal, A. B. M., Flores, E. F., & Santurio, J. M. (2001). *Pitiose. Ciencia Rural*, 31(4), 735-743.
- Mari, C., Bassuino, D. M., & Sonne, L. *Pitiose Gástrica em um Cão. In: Congresso Medvep de Especialidades Veterinárias*, 2013, Bento Gonçalves. Anais... Bento Gonçalves: Medvep.
- Martins, T. B. *Morfologia comparada da pitiose em cavalos, cães e bovinos. 2010. 104f. Dissertação (Mestrado em Medicina Veterinária) - Centro de Ciências Rurais, Programa de Pós-Graduação Medicina Veterinária, Universidade Federal de Santa Maria, Santa Maria-RS.2010.*

- Mendoza, L., Ajello, L., & McGinnis, M. R. 1996. *Infections caused by the oomycetous pathogen Pythium insidiosum*. J. Mycol. Med. 6(4), 151-164.
- Mendoza, L., Mandy, W., & Glass, R. (2003). *An improved Pythium insidiosum-vaccine formulation with enhanced immunotherapeutic properties in horses and dogs with pythiosis*. Vaccine 21:2797-2804.
- Miller, R. I. Investigations into the biology of three 'phycomycotic' agents pathogenic for horses in Australia. Mycopathologia, 81(1), 23-28, 1983.
- Nobrega, D. F., Silva-Junior, A. B., Caleffo, T., Teruya, C. S., & Viott, A. L. 2013. Pitiose intestinal em cão – relato de caso. Cães e Gatos, 29(169),14-17.
- Passos, R., Aquino, J., Oliveira, G., Sanches, R., & Maniscalco, C. (2004). Viabilidade da inspeção traqueobrônquica, por videoendoscopia, em cães. Brazilian Journal of Veterinary Research and Animal Science. 41. 10.1590/S1413-95962004000500009.
- Patton, C. S., Hake, R., & Newton, J. (Esophagitis due to *Pythium insidiosum* infection in two dogs. J Vet Internal Med, 10(3), 139-142, 1996.
- Rech r. R., Graça, D. L., & Barros, C. L. S. 2004. *Pitiose em um cão: relato de caso e diagnósticos diferenciais*. Clínica Veterinária, 9(50):68-72.
- Rivierre, C., Laprie, C., Guiard-Marigny, O., Bergeaud, P., Berthelemy, M., & Guillot, J., 2005. *Pythiosis in Africa. Emerging Infect. Dis.*11(3):479-481.
- Santurio, J. M., Monteiro, A. B., Leal, A. T., Kommers, G. D., Sousa, R. S., & Catto, J. B. Cutaneous Pythiosis insidiosum in calves from the Pantanal region of Brazil. Mycopathologia, 141(3), 123-125, 1998.
- Santurio, J. M., Alves, S. H., Pereira, D. B., & Argenta, J. S. 2006. *Pitiose: uma micose emergente*. Acta Scient. Vet. 34(1):1-14.
- Smith, J. B., Padhye, A. A., Maslin, W. R. Canine pythiosis-isolation and identification of *Pythium insidiosum*. J Vet Diagn Invest, v.1, p.295-298, 1989.
- Stragliotto, A., Pires, M. A. M., & Presser, C. I., Guimarães, D. *Enterite granulomatosa por Pythium insidiosum em cão*. In: *Congresso Brasileiro de Medicina Veterinária*, 38, 2011, Florianópolis. Anais... Florianópolis: Sociedade Catarinense de Medicina Veterinária.
- Tabosa, I. M., Medeiros, V. T., & Dantas, A. F. M. Pitiose cutânea em eqüídeos no semi-árido da Paraíba. *Arq Bras Med Vet Zoot*, 51, 27-30, 1999.