

Prevalence and consequences of molar incisor hypomineralization in a São Paulo state public school

Prevalência e consequências da hipomineralização dos molares e incisivos em uma escola pública do interior do estado de São Paulo

Prevalencia y consecuencias de la hipomineralización de molares e incisivos en una escuela publica del interior del estado de Sao Paulo

Received: 07/28/2022 | Reviewed: 08/18/2022 | Accept: 08/20/2022 | Published: 09/03/2022

Karine Takahashi

ORCID: <https://orcid.org/0000-0002-6192-6398>
Universidade do Oeste Paulista, Brasil
E-mail: karinetakahashi@gmail.com

Mariali Muniz Sassi

ORCID: <https://orcid.org/0000-0001-7417-3711>
Faculdade São Leopoldo Mandic, Brasil
E-mail: mariali_sassi@hotmail.com

Mariana Meira França

ORCID: <https://orcid.org/0000-0002-0422-2968>
Universidade Adamantina Integrada, Brasil
E-mail: marianamf@hotmail.com

Heitor Ceolin Araujo

ORCID: <https://orcid.org/0000-0001-5749-592X>
Universidade Estadual Paulista, Brasil
E-mail: heitorceolin@hotmail.com

Sérgio Vilhegas

ORCID: <https://orcid.org/0000-0002-8611-6287>
Universidade do Oeste Paulista, Brasil
E-mail: sergiovilhegas@terra.com.br

Cintia Medid Barbieri

ORCID: <https://orcid.org/0000-0003-3264-3521>
Universidade Adamantina Integrada, Brasil
E-mail: cintiamb@fai.com.br

Abstract

Objective: This work aims to determine prevalence and consequences of Molar Incisor Hypomineralization in the city of Ouro Verde – SP. *Methodology:* 457 children, students from the municipal school EMEF Julia Roseira Jerônimo were examined, aging from 7 to 11 years old. Clinical examinations for the diagnosis were performed by a single trained and calibrated examiner using the criteria proposed by the European Academy of Pediatric Dentistry (EAPD, 2009) using natural light and wood spatulas. *Result:* The index found in the city was 15% of students (79 affected children) and only one case with sensitivity. *Conclusion:* prevalence was significant, although symptoms related were rare.

Keywords: Molar incisive hypomineralization; Permanent tooth; Dentin sensitivity; Prevention.

Resumo

Objetivo: Este trabalho tem como objetivo determinar a prevalência e consequências da Hipomineralização Molar Incisivo na cidade de Ouro Verde – SP. *Metodologia:* 457 crianças foram examinadas, estudantes da Escola Municipal EMEF Julia Roseira Jerônimo, com idades entre 7 e 11 anos. Os exames clínicos para diagnóstico foram realizados por um único examinador treinado e calibrado utilizando os critérios propostos pela Academia Europeia de Odontopediatria (EAPD, 2009), utilizando luz natural e espátulas de madeira. *Resultado:* O índice encontrado no município foi de 15% dos alunos (79 crianças acometidas) e apenas um caso apresentava sintomas de sensibilidade. *Conclusão:* a prevalência foi significativa, porém, sintomas associados foram pouco encontrados.

Palavras-chave: Hipomineralização molar incisivo; Dente permanente; Sensibilidade dentinária; Prevenção.

Resumen

Objetivo: Este trabajo tiene como objetivo determinar la prevalencia y las consecuencias de la Hipomineralización Incisivo Molar en la ciudad de Ouro Verde – SP. *Metodología:* fueron examinados 457 niños, alumnos de la escuela

municipal EMEF Julia Roseira Jeronimo con edades de 7 a 11 años. Los exámenes clínicos para el diagnóstico fueron realizados por un único examinador entrenado y calibrado utilizando los criterios propuestos por la Academia Europea de Odontología Pediátrica (EAPD, 2009) utilizando luz natural y espátulas de madera. *Resultado:* El índice encontrado en la ciudad fue de 15% de estudiantes (79 niños afectados) y solo un caso con sensibilidad. *Conclusión:* la prevalencia fue significativa, mas los síntomas fueran raros.

Palabras clave: Hipomineralización molar incisivo; Diente permanente; Sensibilidad de la dentina; Prevención.

1. Introduction

Described in the late 1970s, in Sweden, Molar Incisor Hypomineralization obtained numerous nomenclatures in the literature such as “idiopathic enamel stains”, “internal enamel hypoplasia”, “enamel opacity”, “idiopathic hypomineralization of first permanent molars”, “non enamel opacity related to fluoride”, “and “cheese molars” (Weerheijm et al., 2001; Weerheijm et al., 2003; Weerjheim & Mejåre 2003).

Molar Incisor Hypomineralization (MIH) is a defect of systemic origin of the first molars and permanent incisors that consists of hypoplastic enamel defects characterized by white-yellowish spots on cusp tips in molars and free surfaces in incisors in these cases (Weerheijm et al., 2001; Weerjheim et al., 2003), the teeth in question are vulnerable, drastically affected (Basso et al., 2007; Canavarró et al., 2010; Costa-Silva et al., 2010), the enamel is porous, clinically characterized with opaque white, yellow or brown colors varying with the degree of severity, it is subdivided into mild, moderate and severe, thus causing exposed dentin, facilitating the development of carious lesions, in addition to other changes such as early loss of enamel, tooth sensitivity, need for recurrent and extensive treatments (Canavarró et al., 2010; Vilani et al., 2014; Soviero et al., 2009), co-existing, up to 81% in children, although most studies do not distinguish between diffuse and demarcated lesions, for this reason the percentage affected by MIH is unknown (Crombie et al., 2008).

The most common injury is a partially common and painful dental condition that affects a considerable part of the population and is clearly uncomfortable for the patient because of the denudation of the root due to the loss of periodontal structures or exposure of the cervical dentin layer which results in the removal of the coronary enamel. For this reason, erosion, abrasion, abfraction and caries can be observed. Associated a characteristic short and sharp pain arise from dentin exposed to the oral environment resulting from a tactile, osmotic, volatile or chemical thermal stimulus, which cannot be attributed to any other form of dental pathology or defect (Segre et al., 1997).

Most studies analyzed developmental failures using the enamel developmental failure index, rather than specifically analyzing MIH. The prevalence bases are usually based on data for circumscribed opacities, as this is the most specific category of enamel development defects. Although it is generalized, 81% occurs in children, but most studies do not distinguish between diffuse and demarcated lesions, for this reason the percentage affected is unknown ⁽⁷⁾. Some data are available regarding its prevalence and most Dental Surgeons understand that this is a clinical difficulty that needs further investigation (Giovani, 1990)

Most studies from northern Europe showed that prevalence of MIH varies between 2.8 to 40%, which determines as a continental fact, declaring this condition also as a huge clinical problem (Assunção et al., 2014; Jeremias, 2010). Several continents also carry out studies to diagnose the severity of this condition in their populations, since in America it was observed 40.2%, in Africa percentages of 2.9 and 13, 7 and in Asia 2.8 (Soviero et al., 2009; Cho et al., 2008; Kemoli, 2008) Epidemiological studies regarding the frequency of enamel hypoplasia in contemporary populations revealed the association between socioeconomic circumstances and the prevalence of this variation. Since the prevalence of this condition in relation to developed countries has an average of 10%, in developing countries it is higher than 50% (Weerheijm, 2003).

According to data the prevalence in Brazil is 40.2% in China 2.8% varying between different countries. Part of this variation is related to the lack of regularization of the defect evaluation criteria. In 2003, the EAPD (European Academy of

Pediatric Dentistry) established the diagnostic criteria that aid in the differential diagnosis of MIH and its classification (Canavarro et al., 2003).

The study of this condition is essential due to the high frequency analyzed in clinical practice, as well as the difficulty of care, as it may be related to large fractures of the tooth structure, complexity in the adhesion of restorative materials, increased sensitivity, and the need for retreatment (Whatling et al., 2008~; Giovani, 1990). Today with great relevance in clinical practice in Pediatric Dentistry, affecting children from the moment of its eruption, which may vary in socioeconomic, cultural, regional and ethnic levels.

The etiology in some studies is attributed to the use of dioxins and polychlorinated biphenyls. In this context, a recent study opposed the hypothesis that dioxin is an etiological factor of MIH, as it observed a similar prevalence of the condition among children exposed and not exposed to dioxin (Ahamadi et al., 2012). Premature birth, pre and perinatal problems, common childhood illnesses, especially in the first three years of life and early use of amoxicillin were demonstrated. This anomaly interferes with the quality of life of individuals, being relevant for greater care, guidance and treatment (Weerheijm et al., 2002; Basso et al., 2007; Alalussua et al., 1996). The appearance of MIH in children whose mothers have a pregnancy problem such as premature birth, prolonged delivery and twins are also related to MIH. It is recommended that such complications are capable of causing hypoxia affecting the ameloblasts, however, some authors do not have the same association (Diederich et al., 2003; Ruschel et al., 2001), although metabolic disorders of phosphate and calcium are related (Whatling et al., 2008), even though genetic studies are necessary. Some studies determined a multifactorial etiology with the probability of genetic susceptibility. According to Whatling, Fearn in 2008, because its clinical relevance and prevalence, high variability, survey and clinical work should be encouraged, both in Brazilian and foreign populations (Jalevik et al., 2001).

This study aimed to verify prevalence of MIH and the incidence of pain in teeth affected by it in 457 children from 7 to 10 years old from the public network of the city of Ouro Verde (SP) in EMEF municipal school Julia Roseira Jerônimo.

2. Methodology

Clinical examinations for the diagnosis were performed by a single trained and calibrated examiner using the criteria proposed by the European Academy of Pediatric Dentistry (EAPD, 2009) which include changes in at least one permanent first molar such as: demarcated opacity greater than 1 mm ; post-eruptive enamel fracture; and/or atypical restorations in which the presence of opacity is verified on its margins; absence of permanent first molars in dentition with low caries activity associated with another of the previously mentioned factors (Fernandes et al., 2012). Tactile sensitivity: the patient's sensitivity will be recorded after mechanical application without pressure of the tip of an explorer probe in the cervical region of all teeth. Volatile sensitivity: ten minutes after tactile stimulation, an air jet will be applied with a triple syringe applied perpendicularly to the cervical region of each tooth at a distance of 1 cm (Xie et al., 2008). The intensity of sensitivity of each tooth will be recorded according to the verbal classification scale presented below:

0– Absence of pain.

1– Mild sensitivity (mild opacity demarcated without the need for treatment).

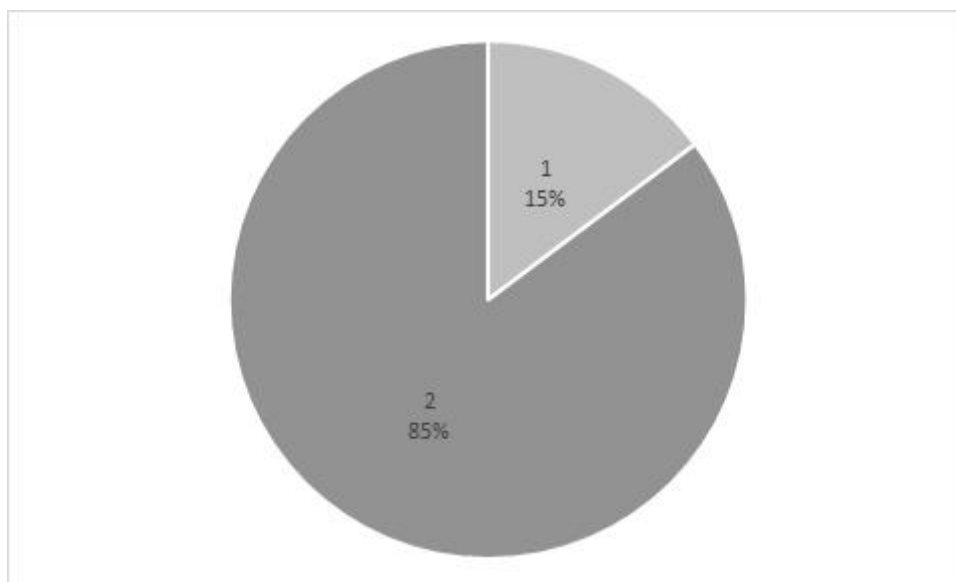
2– Pain during stimulus application (moderate - rough or fractured enamel).

3– Pain during stimulus application and immediately after (severe - loss of tooth structure affecting enamel and dentin, tissue replacement with atypical restorations and extracted teeth due to hypomineralization) (Segre et al., 1997).

3. Results

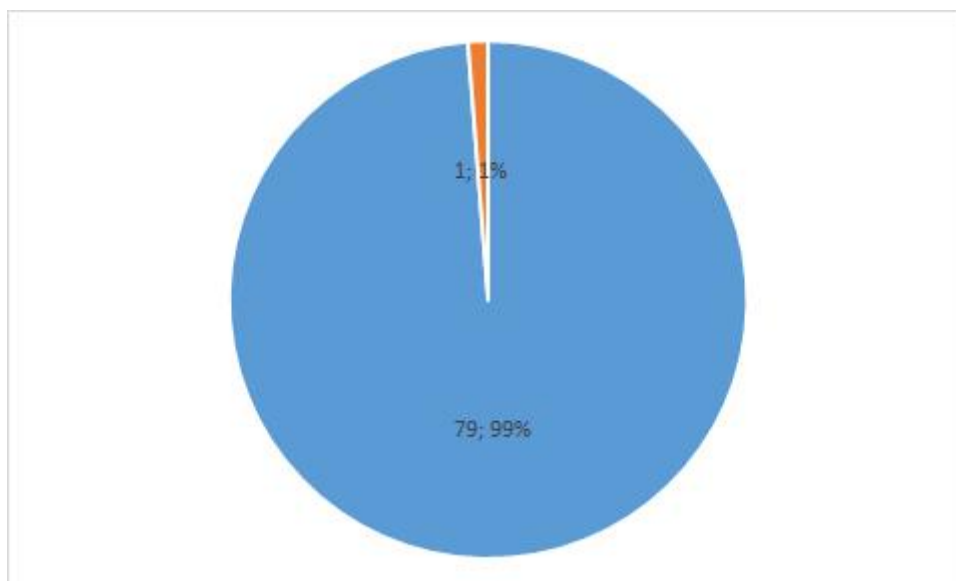
With data collection, analyzing 457 students, from the municipal school system of the city of Ouro Verde (SP), from the EMEF Prof. Julia Roseira Jerônimo, aged between 7 and 10 years old, revealed 79 cases and only one case showed sensitivity.

Graph 1: MIH prevalence in children examined at the EMEF Julia Roseira Jeronimo school.



Source: Authors.

Graph 2: prevalence of sensitivity in patients with MIH at the EMEF Julia Roseira Jeronimo school.



Source: Authors.

Analyzing data, it can be determined that the rates vary as in Europe from 2.8% to 40%, in America they are around 40.2%, in Africa 2.8 to 3.7% and in Asia 2.8%, with the index in the EMEF Julia Roseira Jerônimo school with 15% shows that it is below the index found in America.

In the clinical context, MIH is diversified from enamel hypoplasia as it refers to a qualitative enamel defect, whereas hypoplasia is related to a localized reduction in the enamel, having surface depressions, with rounded and smooth edges (Segre et al., 1997), MIH is determined by demarcated opacities and when loss of structure, the tissue margins are irregular and rough (Weerheijm et al., 2001; Suckling, 1998; Weerheijm & Mejøre, 2003).

It can also be distinguished from amelogenesis imperfecta, since in amelogenesis most of the dentition is symmetrically compromised, in addition to the correlated hereditary pattern (Weerheijm et al., 2001; Ruschel et al., 2001) The differential diagnosis made with fluorosis is based on the fact that MIH is not associated with prolonged fluoride exposure and shows opposite demarcated opacities from the diffuse opacities of fluorosis (Suckling, 1998).

The exam must be performed at 8 years of age, as it is considered an optimal age and corresponds to the eruption of the incisors and permanent first molars. It is a progressive disease, because in this early stage, the first permanent molar will be proportionally in good condition. Generally, molar injuries manifest themselves under the direct influence of masticatory forces, unlike what happens in incisors that are on the buccal face as marked opacities and generally do not present fractures (Frageli, 2012). The extension and severity of the injury vary according to the individual, being able to reach one or all of permanent molars (Weerheijm & Mejøre, 2003). In one patient, a molar with intact opacity will possibly be observed, since in other molars, enamel fragments can fracture after the tooth eruption, giving the appearance that this tissue has not been formed⁽¹⁾. When there is a severe defect in a dental element, the contralateral element is often affected as well (Alalussua et al., 1993). With temperature variation, teeth can be very sensitive, during inrush and brushing. Affected molars need periodic and extensive treatment. In order to reduce the development of caries lesions and post-eruptive fractures, preventive treatments need to be used and in more severe cases, curative treatments, even the indication of extraction correlated with orthodontic therapy, need to be considered (Weerheijm et al., 2003).

In addition to the defects present in the first molars, in some cases, opacities in the upper and lower incisors can be seen 1 with the number of molars affected the risk of defects in the incisors increases 1 16 and the enamel in these teeth hardly has loss of structure opacities in the incisors in eruption need to be considered as a risk factor for the occurrence of MIH molars ((Weerheijm et al., 2003; Giovani, 1990).

The lower quality of dental enamel linked to post-eruptive fractures favor the formation of unusual cavities, which increase the susceptibility of teeth with MIH to tooth decay and contribute to the accumulation of biofilm in these areas⁽²⁵⁾.

Since carious lesions can mask hypomineralized surfaces, leading to rapid destruction of the dental crown and indispensability of atypical restorations ((Weerheijm et al., 2001).

A normal and efficient oral hygiene should be associated with the topical application of fluoride and the use of a desensitizing toothpaste in order to help relieve tooth sensitivity (Lopes, 2010). Daily mouthwashes with sodium fluoride and weekly application of varnish or topical fluorine gel can: minimize tooth sensitivity, increase post-eruptive maturation and enamel remineralization.

For those considered mild: teeth with some sensitivity to any treatment or brushing, it is recommended to give instructions on oral hygiene to parents and patients, in cases of brushing with difficulty (because of sensitivity, on the poorly mineralized surfaces of the affected molars) the following way to ease the sensitivity, try to reduce the porosity: Brush the affected molars gently with a desensitizing toothpaste (if possible with fluoride) and a soft bristle brush; Application of a CPP-ACP cream (Casein Phosphopeptide - Amorphous Calcium Phosphate) topic daily using a cotton swab, it is important to know if the patient does not have any type of allergy; Application of a fluoride gel of a not very high concentration, often with a

cotton swab on the tooth surface, specific oral hygiene instructions should be instituted when the occurrence of remineralization and desensitization of affected molars (Vassend, 1993).

Fluoride-containing glass ionomers can be applied, as they can reduce sensitivity and provide some protection against caries (Giovani, 1990; Fayle, 2003). For partially erupted dental elements where moisture control during the procedure is not easily achieved, glass ionomer cements and sealants can provide protection against decay and reduce surface permeability. Retention is poor, however, sealants will probably need to be reconstructed in the future with a resin sealant, when optimal moisture control is achieved (Giovani, 1990). Some treatment options include glass ionomer cements, resin-modified glass ionomer cements, polyacid-modified composite resins, composite resins, amalgam, stainless steel crowns, and indirect or cast adhesive crowns or "onlays" (Vassend, 1993).

It is even necessary that in mild cases this is frequently evaluated with 2-3 consultations for at least one year (Frageli, 2012; Giovani, 1990, Ligiadakis et al., 2010). The type of adhesive used for fixation on hypomineralized enamel may also play an important role (Vassend, 1993). Self-etching adhesives have greater adhesion to hypomineralized enamel compared to single-bottle total etching adhesives, probably due to the omission of washing, thus removing residual water interference on the element. However, the hydrophilic properties of acetone placed in some of the total conditioning systems can play the same role to remove residual water from the enamel, increasing the availability of the enamel surface for adhesion (Vassend, 1993; Giovani, 1990; Frageli, 2012).

In elements considered 'moderate', those in which the enamel/dentin defect is only on one or two sides, restorations with compomers are the treatment of choice. Resin materials are often used to directly restore the faces of elements with MIH as well as glass ionomers are commonly used as a temporary restoration ((Weerheijm et al., 2001; (Weerheijm et al., 2003; Giovani, 1990; Lopes, 2010). Restorations with composite resin in hypomineralized molars need to be reviewed very frequently, as fractures in affected enamel can occur in the margins of the restoration (Frageli, 2012; Giovani, 1990; Ligiadakis et al., 2010) speaking of adhesion to enamel Hypomineralized decreases the adhesion effectiveness of resin-based materials and may increase the chance of restoration failure ((Weerheijm et al., 2003; Lopes, 2010, Giovani 1997).

In "severe" cases of MIH, most of the time it reaches the cusps, with or without involvement of the pulp. There are variations in the choice of treatment in these cases, ranging from restoration to extraction, often combining endodontics and orthodontics for a more complete treatment in patients with MIH characterized as severe. These factors, such as occlusion, are altered with the presence of MIH in Pediatric Dentistry or with dental crowding, with all dental development in general, tooth absence or malformation and the long-term prognosis will determine the decision to maintain or extract the molars affected by MIH (Frageli, 2012; Giovani, 1997; Ligiadakis et al., 2010). When opting for restorations, full-covering molar crowns are always a choice. Precast stainless steel crowns have excellent results in restoring hypomineralized molars (Fitzpatrick O'lonnel, 2007). Precast crowns are of affordable value, aiming at economy and their durability is more than 10 years ^(30,33,37) polish it all before cementing (Frageli, 2012, Giovani, 1997; Daly & Waldron, 2009). Even with the lack of long-term clinical studies on the use of precast stainless steel crowns in permanent molars, they are recommended by the American Academy of Pediatric Dentistry as one of the forms of treatment for hypomineralized defects (Giovani, 1997; Fayle, 2003). This restores occlusion and maintains the arch's shape, decreasing sensitivity and removing the need for restorative interventions in the future^(33,35).

Another suggestion for treating "severe" cases of MIH is extraction, which depends on the number of molars extensively affected. Molar-Incisor Hypomineralization in Pediatric Dentistry nowadays, the time of extraction of affected molars is less critical, as today there is greater dissemination and knowledge about orthodontic techniques with fixed appliances (Frageli, 2012; Giovani, 1997; Daly & Waldron, 2009)

5. Conclusion

Prevalence and the incidence of MIH was significant thus showing the need for further clinical research to study severity.

References

- Ahmadi, R., Ramazani, N., & Nourinasab, R. (2012). Molar incisor hypomineralization: a study of prevalence and etiology in a group of Iranian children. *Iran J Pediatr*, 22(2),245-51.
- Alalususua, S., Lukinmaa, P. L., Vartiainen, T., Partanen, M., Torppa, J., & Tuomisto, J. (1996). Polychlorinated dibenzo-p-dioxins and dibenzofurans via mother's milk may cause developmental defects in the child's teeth. *Environ Toxicol Pharmacol*, 1,193-97.
- Assuncao, C. M., Girelli, V., Sarti, C. S., Ferreira, E. S., Araujo, F. B. R., & Almeida, J. (2014). Molar-incisor hypomineralization (MIH): case report and follow-up of restorative treatment. *Rev. Assoc. Paul. Cir. Dent*,68(4), 346-350.
- Basso, A. P., Ruchel, H. C., Gatterman, A., & Ardenghi, T. M. (2007). Molar-incisor hypomineralization. *Rev Odonto Ciênc*,22 (58), 371-6.
- Canavarro, M. C., Pereira, M., Moreira, H., & Paredes, T. (2010). Quality of life and health: WHOQOL applications. *Foundations*,III(3),243-68.
- Cho, S. Y., Ki, Y., & Chu, V. (2008). Molar incisor hypomineralization in Hong Kong Chinese children. *Int J Paed Dent*,18, 348-52.
- Costa-Silva, C. M., Jeremias, F., Souza, J. F., Cordeiro, R. C. L., Santos-Pinto, L., & Zuanon, A. C. C. (2010) Molar incisor hypomineralization: prevalence, severity and clinical consequences in Brazilian children. *International Journal of Pediatric Dentistry*,20,426-34.
- Crombie, F. A., Manton, D. J., Weerheijm, K. L., & Kilpatrick, N. M. (2008). Molar incisor hypomineralization: a survey of members of the Australian and New Zealand Society of Pediatric Dentistry. *Aust Dent J*, 53,160-166.
- Daly, D., & Waldron, J. M. (2009). Molar incisor hypomineralisation: clinical management of the young patient. *J of the Irish Dental Association*, 55(2),83-86.
- Diedrich, G., Sperling, S., Hetzer, G. (2003). Molar incisor hypomineralization in a group of children and adolescents living in Dresden (Germany). *Eur J Pediatr Dent*, 3, 133-7.
- Fayle, S. A. (2003). Molar Incisor Hypomineralisation: restorative management. *Eur J Paed Dent*, 03,121-126.
- Fernandes, A. S., Mesquita, P., & Vinhas, L. (2012). Incisor-molar hypomineralization: a literature review. *Rev Port Estomatol Med Cir Maxiofac*, 53, 258-62.
- Fitzpatrick, L., O'Connell, A. (2007). First permanent molars with molar incisor hypomineralisation. *J Ir Dent Assoc. Spring*,53(1),32-7.
- Fragelli, C. M. B. (2012). Molar-incisor hypomineralization: longitudinal assessment in children aged 6 to 9 years.-- Araraquara: [sn],
- Giovani, P. A. (1990). Hypomineralization of molars and incisors: diagnosis and approach in children's clinic Piracicaba, SP: [sn].
- Jälevik, B., Norén, J. G., Klingberg, G., & Barregard, L. (2001). Etiologic factors influencing the prevalence of demarcated opacities in permanent first molars in a group of Swedish children. *Eur J Oral Sci*, 109, 230-4.
- Jeremias, F. (2010). Molar-Incisor Hypomineralization: prevalence, severity and etiology in schoolchildren from Araraquara / Fabiano Jeremias. – Araraquara: [sn].
- Kemoli, A. M. (2008). Prevalence of molar incisor hypomineralisation in six to eight year-olds in two rural divisions in Kenya. *East Afr Med J*, 85, 514-9.
- Kusco, O. O., Çağlar, E., Aslan, S., Durmusoglu, E., Karademir, A., & Sandalli, N. (2009). The prevalence of molar incisor hypomineralization (MIH) in a group of children in a highly polluted urban region and a windfarmgreen energy island. *Int J Pediatr Dent*, 19, 176-85.
- Lopes, A. R. C. (2010). Incisive-Molar Hypomineralization in Pediatric Dentistry. Coimbra.
- Lygidakis, N. A., et al. (2010). Best Clinical Practice Guidance for clinicians dealing with children presenting with Molar-Incisor-Hypomineralisation (MIH): An EAPD Policy Document. *Eur. Arch. Pediatrics Dent*,11(2), 75-81.
- Ruschel, H. C., Souza, I. P. R., Froner, A. L., & Laitemberg, D. E. (2001). Amelogenesis imperfecta: a clinical, genetic and histological approach. *J Bras Odontop Odonto Baby*, 4(21), 367-74.
- Segre, M., & Ferraz, F. C. (1997). The concept of health. *Rev Public Health*, 31(5), 538-42.
- Soviero, V., Haubek, D., Trindade, C., Matta, T., & Poulsen, S. (2009). Prevalence and distribution of demarcated opacities and their sequelae in permanent 1st molars and incisors in 7 to 13-year-old Brazilian children. *Odontol Scan*, 67, 170-5.
- Suckling, G. W. (1989). Developmental defects of enamel-historical and present-day perspectives of their pathogenesis. *Adv Dent Res*, 3,87-94.
- Tourino, L. F. P. (2015). Prevalence of molar-incisor hypomineralization and associated factors in schoolchildren from a municipality in southeastern Brazil// Luciana Fonseca de Pádua Gonçalves Tourino. –. 103 f.

- Towned, E., Dimigen, G., & Fung, D. (2000). A clinical study of child dental anxiety. *Behav Res Ther*, 38, 31-46.
- Vassend, O. (1993). Anxiety, pain and discomfort associated with dental treatment. *Behav Res Ther*, 31, 659-66.
- Vilani, P. N. L., Paim, A. S., Penido, C. V. S. R., & Barra, S. G. (2014). Molar-incisor hypomineralization: case report. *Lins School of Dentistry Unimep*, 24 (1), 64-8.
- Weerheijm, K. L. (2003). Molar incisor hypomineralisation (MIH). *Eur J Pediatr Dent*, 4, 114-20.
- Weerheijm, K. L., & Mejäre, I. (2003). Molar incisor hypomineralization: an inventory of its occurrence in member countries of the European Academy of Pediatric Dentistry (EAPD). *Int J Pediatr Dent*, 13, 411-6.
- Weerheijm, K. L., & Mejäre, I. (2003). Molar incisor hypomineralization: a questionnaire inventory of its occurrence in member countries of the European Academy of Pediatric Dentistry (EAPD). *Int J Pediatr Dent*, 13, 411-6.
- Weerheijm, K. L., et al. (2003). Judgment criteria for molar incisor hypomineralisation (MIH) in epidemiologic studies: A summary of the European meeting on MIH held in Athens. *Eur J Pediatr Dent*, 4(3), 110-3.
- Weerheijm, K. L., Jalevik, B., & Alaluusua, S. (2001). Molar incisor hypomineralisation. *Caries Res*, 35(5), 390-1.
- Whatling, R., & Fearn, J. M. (2008). Molar incisor hypomineralization: a study of aetiological factors in a group of UK children. *Int J Paed Dent*, 18, 155-62.
- Williams, K. D., MA Ringer, C. A., Senior, M. J., Webb, B. J., McAvaney, N., Andronova, S., Bony, J.-L., Dufresne, S., Emori, R., Gudgel, T., Knutson, B., Li, K., Lo, I., Musat, J., Wegner, A., Slingo, & Mitchell, J. F. B. (2006). Evaluation of a component of the cloud response to climate change in an intercomparison of climate models. *Clim. Dyn*, 26, 145-165.
- Xie, Z., Kilpatrick, N. M., Swain, M. V., Munroe, P. R., & Hoffman, M. (2008). Transmission electron microscope characterization of molar-incisor hypomineralisation. *J Mater Sci*, 19, 3187-92.