

## **First ultrasound report of temporal extension of bichat fat: correlation between anatomy and ultrasonography**

**Primeiro relatório ultrassonográfico de extensão temporal da gordura de bichat: correlação entre anatomia e ultrassonografia**

**Primer informe ecográfico de extensión temporal de la grasa de bichat: correlación entre anatomía y ultrasonografía**

Received: 07/31/2022 | Reviewed: 08/13/2022 | Accept: 08/16/2022 | Published: 08/24/2022

### **Vivian Almeida Castilho**

ORCID: <https://orcid.org/0000-0003-1794-1707>  
Municipal University Hospital of Taubate, Brazil  
E-mail: viuss@yahoo.com.br

### **Gisele Rosada Dônola Furtado**

ORCID: <https://orcid.org/0000-0002-6508-2671>  
Ingá University Center, Brazil  
E-mail: agf.gisele@gmail.com

### **Ricardo César Gobbi de Oliveira**

ORCID: <https://orcid.org/0000-0002-0725-2337>  
Ingá University Center, Brazil  
E-mail: rcgobbi@gmail.com

### **Kledson Lopes Barbosa**

ORCID: <https://orcid.org/0000-0002-6916-8990>  
UNINASSAU University Center, Brazil  
E-mail: kledsonlopesb@gmail.com

### **Abstract**

The knowledge of facial anatomy and its correlation with ultrasonography has been gaining ground in the clinical practice of several professionals. Therefore, the knowledge of facial anatomical structures through dynamic ultrasonography images must be understood as a critical element for the clinical practice of guided esthetic facial procedures. In this pictorial essay focuses on discussing unprecedented anatomical details Temporal Extension of Bichat Fat correlating the anatomy with routine ultrasonography images. Knowledge of the US features of the temporal and buccal extensions of Bichat's fat will help narrow the differential diagnosis and guide clinical decision-making through spatial resolution and the ability to assess these structures using muscle contraction dynamically.

**Keywords:** Facial anatomy; Bichat fat; Ultrasonography; Facial ultrasonography; Dermatologic ultrasonography.

### **Resumo**

O conhecimento da anatomia facial e sua correlação com a ultrassonografia vem ganhando espaço na prática clínica de diversos profissionais. Portanto, o conhecimento das estruturas anatômicas faciais por meio de imagens ultrassonográficas dinâmicas deve ser entendido como elemento crítico para a prática clínica dos procedimentos estéticos faciais guiados. Neste ensaio pictórico foca-se na discussão de detalhes anatômicos inéditos da Extensão Temporal da Gordura de Bichat correlacionando a anatomia com imagens ultrassonográficas de rotina. O conhecimento das características ultrassonográficas das extensões temporais e bucais da gordura de Bichat ajudará a estreitar o diagnóstico diferencial e orientar a tomada de decisão clínica por meio da resolução espacial e da capacidade de avaliar essas estruturas usando a contração muscular dinamicamente.

**Palavras-chave:** Anatomia facial; Gordura de Bichat; Ultrassonografia; Ultrassonografia facial; Ultrassonografia dermatológica.

### **Resumen**

El conocimiento de la anatomía facial y su correlación con la ultrasonografía ha ido ganando terreno en la práctica clínica de varios profesionales. Por lo tanto, el conocimiento de las estructuras anatómicas faciales a través de imágenes ultrasonográficas dinámicas debe entenderse como un elemento crítico para la práctica clínica de procedimientos estéticos faciales guiados. En este ensayo pictórico se enfoca en discutir detalles anatómicos sin precedentes. Extensión Temporal de Bichat Fat correlacionando la anatomía con imágenes de ultrasonografía de rutina. El conocimiento de las características ecográficas de las extensiones temporales y bucales de la grasa de Bichat ayudará a reducir el diagnóstico

diferencial y guiará la toma de decisiones clínicas a través de la resolución espacial y la capacidad de evaluar estas estructuras mediante la contracción muscular de forma dinámica.

**Palabras clave:** Anatomía facial; Grasa de Bichat; Ultrasonografía; Ultrasonografía facial; Ultrasonografía dermatológica.

## 1. Introduction

Detailed knowledge of facial anatomy and its correlation with the image examinations is crucial for use in various clinical scenarios such as pathology recognition, preoperative evaluation, and even for the safe identification of anatomical structures in ultrasonography-guided (USG)-guided esthetic procedures (Guryanov & Guryanov, 2015; Almuhanha et al., 2021; Hernández et al., 2021).

Bichat fat ultrasonography (BFUSG) is an excellent tool for anatomical recognition. However, in the literature, we found a correlation with other imaging methods, such as computer tomography (CT) and magnetic resonance imaging (MRI) (Guryanov & Guryanov, 2015; Tart et al., 1995). The anatomy of the buccal fat pad was firstly described in 1802 (Bichat, 1802). In addition to USG recognition of the BF itself, other structures can be visualized in the image to fully understand the anatomical relationships, including the buccinator muscle, the masseter muscle, facial vein, parotid duct topography, and parotid masseteric fascia (Hernández et al., 2021).

The oral space is an anatomical region with structures that play a relevant role in stability, masticatory function, and neurovascular protection (Yousuf et al., 2010; Singh et al., 2010). The added value of the use of ultrasonography is to provide a dynamic complementary tool to help in the clinical approach and also for facial aesthetic pre- and post-procedures, such as the removal of Bichat fat for aesthetic purposes, which aims to reach the zygomatic prominences, providing the formation of the inverted triangle of beauty (Moura et al., 2018).

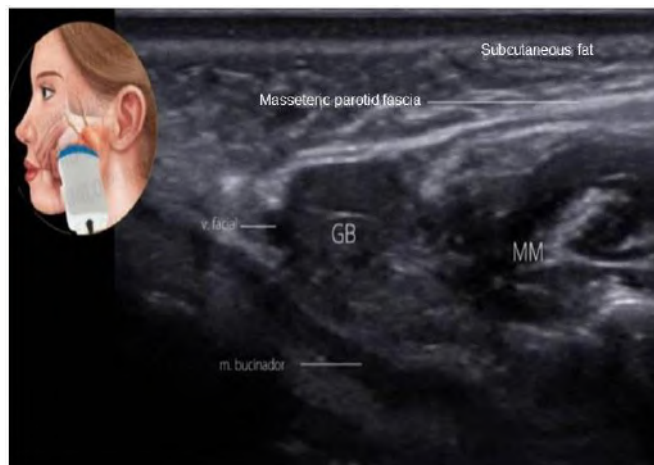
The main objective of this pictorial essay is to review and discuss the anatomical details of Bichat fat (BF) by correlating the anatomy with typical ultrasonography images and presenting a recognition methodology based on anatomical references of neighboring structures.

## 2. Methodology

Dermatological and facial ultrasonography have better image resolution in devices with high-frequency (or more than 15 Mhz) transducers (Almuhanha et al., 2021). It is possible to acquire images also with low-frequency transducers due to the depth of the BF on the face. This study used a high-frequency transducer, i.e., between 15Mhz and 18Mhz (Mindray Mx7 and Samsung HM70).

For ultrasonography examination of BF, the preferred position is the patient supine on the examination table, with the head in a neutral position. EBBF has fat echogenicity (hypoechoic), and by its shape, it can be distinguished from other adjacent fat tissues (Figure 1).

**Figure 1.** Ultrasonography image of the anatomical relationships of the BF: facial vein, masseter muscle (MM), buccinator muscle, and parotid-masseteric fascia. Section performed in the pre-masseteric region of the face on the right with a portable US (Mindray, Model Mx7, high-frequency linear transducer (23 Mhz).

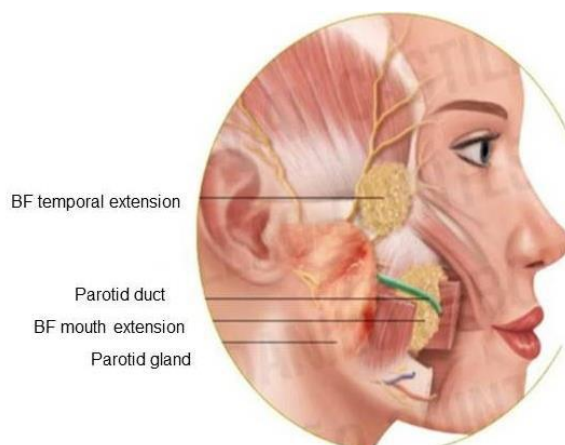


Source: Authors (2022).

### 3. Results and Discussion

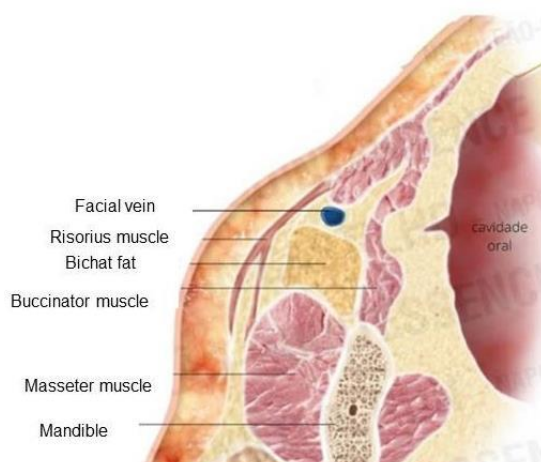
BF comprises encapsulated and lobulated fat tissue with approximately 9.6 mL (ranging from 8.33 to 11.9 mL) (Tostevin & Ellis, 1995; Stuzin et al., 1990). It has a central body and four extensions: buccal, pterygoid, pterygopalatine, and temporal (Loukas et al., 2006). It is vascularized mainly by branches of the maxillary artery and the transverse facial artery. Venous drainage is performed mainly through the facial vein (Bichat, 1802). The anatomical relationships of the buccal extension of Bichat's fat show that it is superficially inside the cheek in the chewing space, and the temporal extension runs under the zygomatic arch towards the temporal fossa (Figure 2) (Tostevin & Ellis, 1995; Loukas et al., 2006), with the BF located anteriorly to the masseter muscle (Figure 3).

**Figure 2.** Schematic drawing in the sagittal section shows Bichat's fat's buccal and temporal extensions.



Source: Kindly provided by Editora Napoleão, Quintessence, 2021. Adapted from the book "Complications and ultrasonography in facial aesthetics and cosmiatry".

**Figure 3.** Schematic drawing in the axial section showing Bichat's fat, facial vein, masseter muscle, buccinator muscle, and risorius muscle.



Source: Kindly provided by Editora Napoleão, Quintessence, 2021. Adapted from the book “Complications and ultrasonography in facial aesthetics and cosmetology”.

The maneuver of filling the mouth with air can facilitate the identification of BF. The primary anatomical references proposed for the location of the BFBE are the masseter muscle, the buccinator muscle, the parotideomasseteric fascia, and the facial vein (Table 2, Figure 3).

**Table 1.** Anatomical relationships of the buccal portion of the BF.

Anatomical reference	Relative position of the buccal portion of the BF
Masseter muscle	Anterior
Buccinator muscle	Floor or Lateral
Vein and arteries	Posterior
Parotid duct and parotid-masseteric fascia	Medial

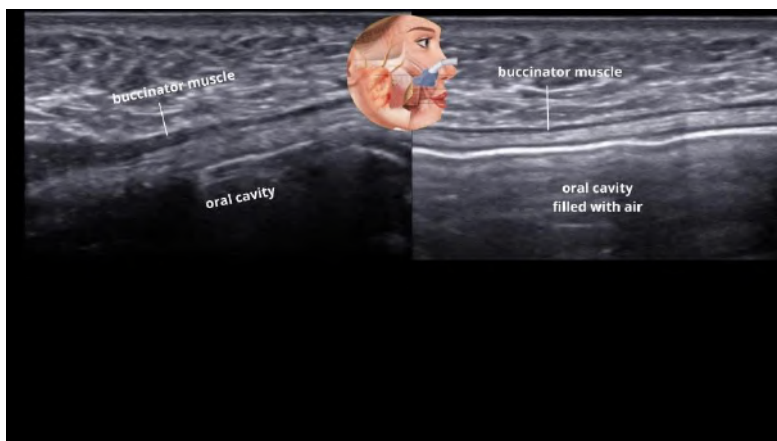
Source: Authors (2022).

### 3.1 Oral Extension of Bichat fat (OEBF) and Its Anatomical Relationships

As mentioned before, the BF is located anteriorly to the masseter muscle (Figure 2), and the masseter is one of the primary anatomical references to locate the BF in the ultrasonography image. These structures and other anatomical relationships of the buccal portion of the BF can be seen in Table 1.

BFBE has fat echogenicity (hypoechoic), and by its shape, it can be distinguished from other adjacent fat tissues (Figure 3). Concerning the buccinator muscle, the BFBE is located laterally. The buccinator muscle appears as a thin hypoechoic structure that makes up the cheek wall and is close to the oral mucosa. If we ask to fill the mouth with air during the ultrasonography image acquisition, we visualize the proximity of the oral mucosa and the buccinator muscle (Figure 4).

**Figure 4.** Ultrasonography image showing the buccinator muscle when the mouth is without air or is filled with air to demonstrate the proximity of this muscle to the oral cavity. Cross-section performed in the cheek region, posterior to the right modiolus, obtained from a portable US (Mindray, Model Mx7, high-frequency linear transducer (23 Mhz)).

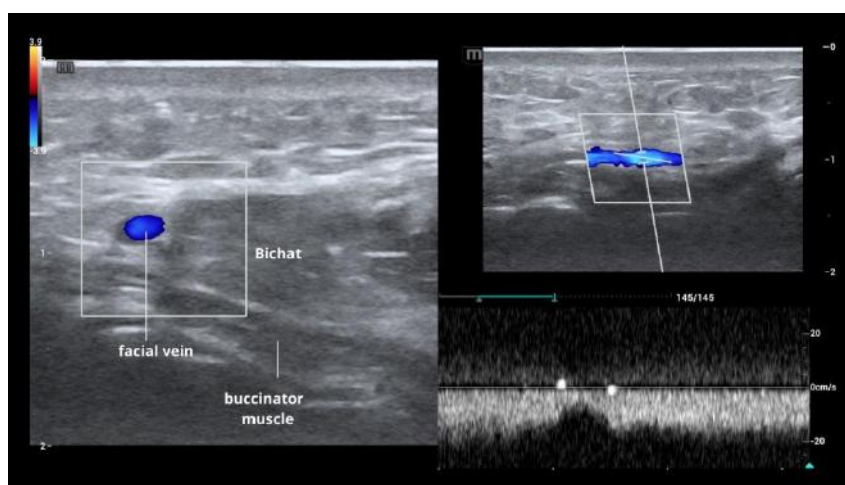


Source: Authors (2022).

The parotid duct (PD) follows a lateral and anterior course concerning the BFBE in most cases (having some anatomical variants about its position) (Hwang et al., 2005). The PD penetrates the buccinator muscle, entering the oral cavity close to the second maxillary molar (Figure 3) (Stuzin et al., 1990). Adjacent to the parotid duct, there are branches of the facial nerve and the parotid masseteric fascia (Mendelson et al., 2008; Tsai et al., 2019). The individualization of the PD in the ultrasonography image is not always possible unless its lumen is ecstatic or contains liquid.

The facial vein is another anatomical relationship of the BFBE that is easily visualized on the ultrasonography image, located close to and anterior to the BF (Figure 1 and 2). The cross-section is a rounded and anechoic structure that captures flow with a venous pattern on Doppler; in the longitudinal section, it has a tubular shape (Figure 5).

**Figure 5.** Color Doppler ultrasonography of the facial vein. The image on the right shows a longitudinal axis section of the facial vein and a Doppler spectral curve showing a venous pattern. Bichat fat (BF). Section performed in the pre-masseteric region of the face on the right with a portable US (Mindray, Model Mx7, high-frequency linear transducer (23 Mhz)).



Source: Authors (2022).

### 3.2 Temporal Extension of Bichat Fat (TEBF)

The direction of the anatomical section performed to identify the Temporal Extension of Bichat Fat (TEBF) and its anatomical relationships was longitudinal on the face superior to the edge of the zygomatic arch (Figure 6). We will show its superficial portion visible in the temporal fossa just above the bony part of the zygomatic arch. The anatomical relationships of the temporal portion of the BF can be seen in Table 2.

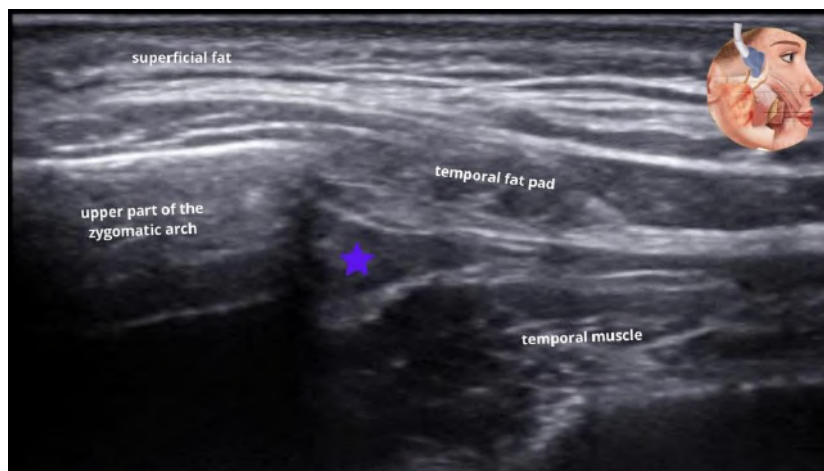
**Table 2.** Positions of the anatomical relationships of the temporal portion of the BF

Anatomical Reference	Relative position of the temporal portion of the BF
Masseter muscle	Posterior
Temporal Fat Pad and Deep Temporal Fascia	Anterior
Zygomatic Arch	Anterior

Source: Authors (2022).

The TEBF is an echogenic fat structure with an approximately triangular shape anterior to the temporal muscle (Figure 6). The dynamic maneuver of voluntary contraction of the temporal muscle facilitates its individualization. The primary anatomical references proposed for locating the TEBF are temporal muscle, zygomatic arch, and temporal fat pad. We identified the upper bony border of the zygomatic arch and the limits of the temporal muscle.

**Figure 6.** Ultrasonography image of the temporal region. Blue star: temporal extension of Bichat's fat. Section performed in the temporal region, superior to the zygomatic arch on the right with portable USG (Mindray, Model Mx7, high-frequency linear transducer (23 Mhz)).

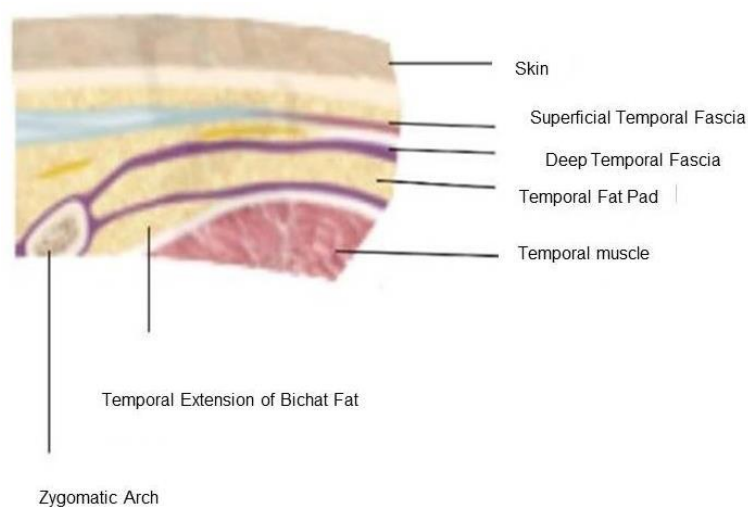


Source: Authors (2022).

The TEBF presents a path below the zygomatic arch towards the temporal fossa, as seen in Figure 1 (Tostevin & Ellis, 1995; Loukas et al., 2006; Tsai et al., 2019). No description of its anatomical appearance was found in the literature, only in other imaging methods such as CT and MRI.

TEBF has similar echogenicity to fat and can be better individualized after a temporal muscle contraction maneuver. In the longitudinal section in the region of the temporal fossa, after identifying the zygomatic bone portion and the limits of the temporal muscle, we visualized a structure with an approximately triangular shape anteriorly to the temporal muscle and inferiorly to the zygomatic arch (Figure 6 and 7).

**Figure 7.** Schematic drawing of the temporal region showing the layers and structures visualized on ultrasonography - longitudinal section of the temporal region.



Source: Kindly provided by Editora Napoleão, Quintessence, 2021. Adapted from the book “Complications and ultrasonography in facial aesthetics and cosmetology”.

To minimize the surgical risks in removing the Bichat fat, new approaches using USG are increasingly present pre and trans-surgically in bichectomy. This is because USG is useful to demonstrate the relationship between BF and its adjacent structures and may also reveal anatomical variations in its position, bringing predictability and safety to the procedure (Pereira et al., 2020).

In addition to the USG showing broad benefits, as we demonstrated in this study, it is a tool that provides a quick, accessible, and without contraindications imaging exam (Sigrist et al., 2017). It is a ubiquitous diagnostic method for soft tissue analysis (Jaeger et al., 2016), which is one of the principles that guide the idea of this essay.

The preoperative US examination allows verifying the volume of oral extension of the BF, which is the portion of interest to professionals qualified in the bichectomy procedure. In addition, from the US, it is also possible to clarify cases of anatomical variations regarding its position, making sure that the BF is positioned between the masseter and buccinator muscles (Loukas et al., 2006), as we could identify in our study.

The bichectomy can be challenging in particular cases, as excess facial volume may be related to masseter muscle hypertrophy, skeletal arrangement, or even poorly known pathological conditions (Tarallo et al., 2018; Sezgin et al., 2019). In this sense, the clinical approach alone is often insufficient to assess and determine an adequate diagnosis (Jaeger et al., 2016; Sezgin et al., 2019). This leads us to understand that using USG as a complementary tool for diagnostic imaging and facial mapping for candidates for aesthetic procedures is valuable and necessary in today's world.

#### 4. Conclusion

This pictorial study demonstrated the ability of USG to visualize the detailed anatomy of the buccal and temporal extensions of the BF, showing good spatial resolution and the ability to dynamically assess these structures using muscle contraction, even though USG is a limited tool for visualizing bone-covered structures. In addition, the recognition of BF anatomy and its anatomical relationships expands our diagnostic capacity, surgical planning, and expertise in USG-guided

procedures in aesthetic-surgical clinical practice. Therefore, further anatomical studies on the temporal portion of Bichat's fat are needed to make this structure better known to professionals who work with facial aesthetic treatments.

## Acknowledgments

We kindly thank Editora Napoleão, Quintessence for kindly providing the figures.

## References

- Almuhanna, N., Wortsman, X., Wohlmuth-Wieser, I., Kinoshita-Ise, M., & Alhusayen, R. (2021). Overview of Ultrasound Imaging Applications in Dermatology [Formula: see text]. *Journal of Cutaneous Medicine and Surgery*, 25(5), 521-529. <https://doi.org/10.1177/1203475421999326>
- Bichat, F. (1802). *Anatomie Generale, Appliquee a la Physiologie et a la Medicine*. Paris: Grosson, Gabon, and Cie.
- Guryanov, R. A., & Guryanov, A. S. (2015). CT Anatomy of Buccal Fat Pad and its Role in Volumetric Alterations of Face. *The International Archives of the Photogrammetry, Remote Sensing and Spatial Information Sciences*, XL-5(W6), 25-27. [https://ui.adsabs.harvard.edu/link\\_gateway/2015ISPAr.XL5...33G/doi:10.5194/isprsarchives-XL-5-W6-33-2015](https://ui.adsabs.harvard.edu/link_gateway/2015ISPAr.XL5...33G/doi:10.5194/isprsarchives-XL-5-W6-33-2015)
- Hernández, O., Altamirano, J., Soto, R., & Rivera, A. (2021). Relaciones anatómicas del cuerpo adiposo de la mejilla asociadas a complicaciones de bichectomía. A propósito de un caso. *International Journal of Morphology*, 39(1), 123-133. <http://dx.doi.org/10.4067/S0717-95022021000100123>
- Hwang, K., Cho, H. J., Battuvshin, D., Chung, I. H., & Hwang, S. H. (2005). Interrelated buccal fat pad with facial buccal branches and parotid duct. *The Journal of Craniofacial Surgery*, 16(4), 658-660. <https://doi.org/10.1097/01.scs.0000157019.35407.55>
- Jaeger, F., de Castro, C. H. B. C., Pinheiro, G. M., de Souza, A. C. R. A., Junior, G. T. M., de Mesquita, R. A., Menezes, G. B., & de Souza, L. N. (2016). A novel preoperative ultrasonography protocol for prediction of bichectomy procedure. *Arquivo Brasileiro de Odontologia*, 12(2), 7-12.
- Loukas, M., Kapos T., Louis Jr, R. G., Wartman, C., Jones, A., & Hallner, B. (2006). Gross anatomical, CT and MRI analyses of the buccal fat pad with special emphasis on volumetric variations. *Surgical and Radiologic Anatomy*, 28(3), 254-260. <https://doi.org/10.1007/s00276-006-0092-1>
- Mendelson, B. C., Freeman, M. E., Wu, W., & Huggins, R. J. (2008). Surgical anatomy of the lower face: the premasseter space, the jowl, and the labiomandibular fold. *Aesthetic Plastic Surgery*, 32(2), 185-195. <https://doi.org/10.1007/s00266-007-9060-3>
- Moura, L. B., Spin, J. R., Spin-Neto, R., & Preira-Filho, V. A. (2018). Buccal fat pad removal to improve facial aesthetics: an established technique?. *Medicina Oral, Patologia Oral y Cirugia Bucal*, 23(4), e478-e484. <https://doi.org/10.4317/medoral.22449>
- Pereira, A. G., Napoli, G. F., Gomes, T. B., Rocha, L. P. C., Rocha, T. de C., & e Silva, M. R. M. A (2020). Ultrasound-guided bichectomy: A case report of a novel approach. *International Journal of Case Reports and Images*, 11(1), 1-5. <http://www.ijcasereportsandimages.com/archive/article-full-text/101086Z01AP2020>
- Sezgin, B., Tatar, S., Boge, M., Ozmen, S., & Yavuzer, R. (2019). The excision of the buccal fat pad for cheek refinement: Volumetric considerations. *Aesthetic Surgery Journal*, 39(6), 585-592. <https://doi.org/10.1093/asj/sjy188>
- Singh, J., Prasad, K., Lalitha, R. M., & Ranganath, K. (2010). Buccal pad of fat and its applications in oral and maxillofacial surgery: a review of published literature (February) 2004 to (July) 2009. *Oral Surgery, Oral Medicine, Oral Pathology, Oral Radiology and Endodontics*, 110(6), 698-705. <https://doi.org/10.1016/j.tripleo.2010.03.017>
- Stuzin, J. M., Wagstrom, L., Kawamoto, H. K., Baker, T. J., & Wolfe, S. A. (1990). The anatomy and clinical applications of the buccal pad of fat. *Plastic and Reconstructive Surgery*, 85(1), 29-37. <https://doi.org/10.1097/00006534-199001000-00006>
- Tarallo, M., Fallico, N., Maccioni, F., Bencardino, D., Monarca, C., Ribuffo, D., & Di Taranto, G. (2018). Clinical significance of the buccal fat pad: How to determine the correct surgical indications based on preoperative analysis. *International Surgery Journal*, 5(4), 1192-1194. <https://dx.doi.org/10.18203/2349-2902.isj20181100>
- Tart, R. P., Kotzur, I. M., Mancuso, A. A., Glantz, M. S., & Mukherji, S. K. (1995). CT and MR imaging of the buccal space and buccal space masses. *RadioGraphics*, 15(3), 531-550. <https://doi.org/10.1148/radiographics.15.3.7624561>
- Tostevin, P. M., & Ellis, H. (1995). The buccal pad of fat: a review. *Clinical Anatomy*, 8(6), 403-406. <https://doi.org/10.1002/ca.980080606>
- Tsai, C. H., Ting, C. C., Wu, S. Y., Chiu, J. Y., Chen, H., Igawa, K., Lan, T. H., Chen, C. M., Takato, T., Hoshi, K., & Ko, E. C. (2019). Clinical significance of buccal branches of the facial nerve and their relationship with the emergence of Stensen's duct: An anatomical study on adult Taiwanese cadavers. *Journal of Cranio-Maxillo-Facial Surgery*, 47(11), 1809-1818. <https://doi.org/10.1016/j.jcms.2018.12.018>
- Sigrist, R. M. S., Liau, J., Kaffas, A. E., Chammas, M. C., & Willmann, J. K. (2017). Ultrasound Elastography: Review of Techniques and Clinical Applications. *Theranostics*, 7(5), 1303-1329. <https://doi.org/10.7150/thno.18650>
- Yousuf, S., Tubbs, R. S., Wartmann, C. T., Kapos, T., Cohen-Gabool, A. A., & Loukas, M. (2010). A review of the gross anatomy, functions, pathology, and clinical uses of the buccal fat pad. *Surgical and Radiologic Anatomy*, 32(5), 427-436. <https://doi.org/10.1007/s00276-009-0596-6>