

Assessment of the presence of radix in lower first and second molars using cone-beam computed tomography and panoramic radiography

Avaliação da presença de radix em primeiro e segundo molares inferiores por meio de tomografias computadorizadas de feixe cônico e radiografia panorâmica

Valoración de la presencia de radix en primeros y segundos molares inferiores mediante tomografía computarizada de haz cónico y radiografía panorâmica

Recebido: 10/07/2022 | Revisado: 18/08/2022 | Aceito: 19/08/2022 | Publicado: 28/08/2022

Jaqueline Vilas Bôas

ORCID: <https://orcid.org/0000-0003-1388-3925>
Faculdade São Leopoldo Mandic, Brazil
E-mail: jaquelinevilasboas@hotmail.com

Alexandre Sigrist De Martin

ORCID: <https://orcid.org/0000-0002-3320-9172>
Faculdade São Leopoldo Mandic, Brazil
Email: a-sigrist@uol.com.br

Carlos Eduardo Fontana

ORCID: <https://orcid.org/0000-0002-2868-6839>
Pontifícia Universidade Católica de Campinas, Brazil
E-mail: ceffontana@hotmail.com

Ana Grasiela da Silva Limoeiro

ORCID: <https://orcid.org/0000-0003-4633-720X>
Consultório particular, Brasil
E-mail: grasielalimoeiro@gmail.com

Rina Andrea Pelegrine

ORCID: <https://orcid.org/0000-0003-4175-2121>
Faculdade São Leopoldo Mandic, Brazil
E-mail: rinapelegrine@terra.com.br

Carlos Eduardo Da Silveira Bueno

ORCID: <https://orcid.org/0000-0002-2675-0884>
Faculdade São Leopoldo Mandic, Brazil
E-mail: carlosesbueno@terra.com.br

Daniel Guimarães Pedro Rocha

ORCID: <https://orcid.org/0000-0001-9792-2260>
Pontifícia Universidade Católica de Campinas, Brazil
E-mail: dnlrocha@uol.com.br

Abstract

Objective: To compare the prevalence of radix in the mandibular first and second molars using cone beam computed tomography and panoramic radiography. **Methods:** 850 exams were analyzed, dated from January 2017 to February 2021, in a radiology clinic in the city of Brumado-Ba. Images were acquired using a Cranex 3D CT scanner. Thus, a total of 280 lower first and second molars were selected by tomographic images and then the images of the relative panoramic radiographs were separated. Radix prevalence was analyzed using On Demand software for the scans from CT and Scanora software for the panoramic radiographs. The data obtained were analyzed using descriptive and inferential statistics, using methods to compare between variables and methods of interest. A significance level of 5% was assumed for all analyzes. **Results:** No case of radix was identified in the analysis of panoramic radiograph images, corresponding to a percentage of 0%. In tomographic sections, this study showed that the prevalence of radix was 0.7%, 100% of which was radix entomolres. There was no statistically significant difference in the prevalence of these canals with respect to age group, sex, and group of teeth examined (first or lower second molars). **Conclusion:** It was concluded that CBCT is an important auxiliary method in the analysis of the presence of radix canals. **Keywords:** Additional root; Anatomical changes; Tooth morphology; Distolingual root.

Resumo

Objetivo: avaliar a prevalência de Radix em primeiros e segundos molares inferiores, fazendo análise comparativa através de Tomografia Computadorizada de Feixe Cônico e Radiografia Panorâmica. Além disso, este estudo relacionou essa prevalência com idade, gênero e grupo de dentes avaliados (primeiros e segundos molares inferiores). **Métodos:** Foram analisados 850 exames, datados no período de Janeiro de 2017 a Fevereiro de 2021, em uma Clínica Radiológica

estabelecida na cidade de Brumado–Ba. As imagens foram adquiridas por um Tomógrafo Cranex 3D. Assim, foram selecionados um total de 280 primeiros e segundos molares inferiores por imagens tomográficas, e depois foram separadas as imagens de Radiografias Panorâmicas relativas. A prevalência de Radix foi analisada através do software On Demand, para as tomografias, e no software Scanora, para as radiografias panorâmicas. Os dados obtidos foram analisados mediante estatística descritiva e inferencial, utilizando métodos de comparação entre as variáveis e métodos de interesse. Para todas as análises foram adotados o nível de significância de 5%. **Resultados:** Na avaliação de imagens de radiografias panorâmicas, não foram identificadas nenhum caso de Radix, resultando num percentual de 0%, enquanto nos cortes tomográficos, este estudo mostrou que a prevalência de Radix foi de 0,7%, sendo 100% destes, de Radix Entomolres. Em relação à faixa etária, gênero e grupo de dentes estudados (primeiros ou segundos molares inferiores), não houve diferença estatisticamente significativa da prevalência destes canais. **Conclusão:** Concluiu-se assim, que a TCFC é um método auxiliar importante na análise da presença de canais Radix.

Palavras-chave: Raiz adicional; Alterações anatômicas; Morfologia dental; Raiz distolingual.

Resumen

Objetivo: evaluar la prevalencia de Radix en primeros y segundos molares inferiores, realizando un análisis comparativo mediante Tomografía Computarizada Cone Beam y Radiografía Panorámica. Además, este estudio tuvo como objetivo comparar esta prevalencia con la edad, el sexo y el grupo de dientes evaluados (primeros y segundos molares inferiores). **Métodos:** Se analizaron 850 exámenes, con fecha de enero de 2017 a febrero de 2021, en una Clínica Radiológica establecida en la ciudad de Brumado-Ba. Las imágenes fueron adquiridas por un escáner Cranex 3D CT. Así, se seleccionaron un total de 280 primeros y segundos molares inferiores mediante imágenes tomográficas, y luego se separaron las imágenes de las Radiografías Panorámicas relativas. La prevalencia de Radix se analizó utilizando el software On Demand para tomografías computarizadas y el software Scanora para radiografías panorámicas. Los datos obtenidos fueron analizados mediante estadística descriptiva e inferencial, utilizando métodos de comparación entre las variables y métodos de interés. Para todos los análisis se adoptó un nivel de significación del 5%. **Resultados:** En la evaluación de imágenes radiográficas panorámicas no se identificó ningún caso de Radix resultando un porcentaje de 0%, mientras que en los cortes tomográficos este estudio arrojó que la prevalencia de Radix fue de 0,7%, con un 100% de estos, por Radix Entomolres. En cuanto al grupo de edad, sexo y grupo de dientes estudiados (primeros e segundos molares inferiores), no hubo diferencia estadísticamente significativa en la prevalencia de estos conductos. **Conclusión:** Se concluyó que CBCT es un método auxiliar importante en el análisis de la presencia de canales Radix.

Palabras clave: Alteraciones anatômicas; Morfología dental; Raíz adicional; Raíz distolingual.

1. Introduction

The fundamental goal of endodontic therapy is the chemical and mechanical cleaning of the pulp cavity and the three-dimensional filling of this root complex (Setzer et al. 2017). Therefore, mastering the anatomical and morphological differences of the root canal system through imaging examination greatly increases the success and prognosis of endodontic treatment (Cantatore et al. 2006).

Lower molars are among the teeth that most frequently require endodontic treatment (Abarca et al. 2020), and due to their complex internal anatomy, treatment success may be compromised by the professional's inability to locate all root canals (Mohammadi et al. 2016).

In 1844, Carabelli described an additional third root (called radix), which may be a short conical extension or a mature root of usual length. This supernumerary root is a developmental anomaly that can affect any tooth. When the supernumerary root is located distolingually, it is classified as radix entomolaris (RE), and when the accessory root occurs mesiobuccally, it is classified as radix paramolaris (RP) (Calberson et al. 2007).

Given the anatomical differences, the importance of ancillary examinations in assessing the root canal, its morphology, and configurations becomes apparent. These examinations include radiographs (Chandra et al. 2007), in vitro studies, and cone-beam computed tomography (CBCT) (Martins et al. 2017).

In addition to periapical radiography, panoramic radiography is also a popular radiographic examination. Since it provides a bilateral view, it would therefore be suitable for screening all pathologies and possible variations in root and root canal configurations. Moreover, it could be inserted into an artificial intelligence system that classifies automatic datasets to make classifications, whether anatomical or pathological (Hiraiwa et al. 2019).

Conventional radiographic examinations limit the evaluation of three-dimensional structures because they show a two-dimensional image that overlays certain common bone and dental structures and is also inadequate for soft tissue evaluation (Rechet a. 2015). In this way, CBCT is used in treatment planning, decision making, case discussion, and reducing occupational stress levels and has had a positive impact since 2014 (Patel et al. 2019). With the advent of computed tomography, diagnostic tools became more accurate and reliable, mainly due to the ability to obtain the image of structures in three dimensions, which led dentistry into a new era in the field of diagnosis (Grauer et al. 2019). The major advantage of CBCT is also that it can be used in vivo and larger sample sizes can be obtained (Ordinola-Zapata et al. 2017). Several endodontists are already using CBCT for diagnosis, treatment planning, and clinical procedures (Setzer et al. 2017).

Even the internal anatomical classification of dental units, previously based on studies by Vertucci (1984), has now been presented by Ahmed et al. (2007) due to the advent of these new three-dimensional technologies, overcoming the limitations of previous classifications (Venskutonis et al. 2014).

In the context of the Brazilian population, for example, CBCT becomes essential for prior planning of the anatomical condition of the tooth to be treated, since the Brazilian population is ethnically mixed of European, African, Asian, and Native American groups, which in turn have a complex internal anatomy of the lower molars, as evidenced by several studies (Caputo et al. 2016).

Thus, it appears that the image obtained by CBCT, with its three-dimensional range, allowed a more detailed identification of structures and pathologies that were "invisible" or misinterpreted in radiographic examinations, compared to any two-dimensional radiographic examination in the patients presented here.

The aim of the present study was to evaluate the prevalence of radix in the mandibular first and second molars by comparative analysis using CBCT and panoramic radiography in a retrospective observational study. In addition, the prevalence was to be compared with age, sex, and the group of teeth examined (lower first and second molars).

2. Materials and Methods

This was a retrospective observational study submitted to the local ethics committee and approved under CAAE 45259821.6.0000.5374. An investigator specializing in endodontics and radiology performed an analysis of digital CBCT images in sagittal, coronal, and axial sections. The sections were performed in 03 axial planes, comparing CBCT with panoramic radiography. The frequency distributions of the number of roots and canals present in these teeth were observed according to the position of the tooth (right or left), as well as the data related to the sex and age of the patient.

The study was carried out in 2021 in the city of Brumado, state of Bahia, as follows: 850 records were randomly selected with tomographic and radiographic examinations previously requested by indicators. This list was forwarded to a dental surgeon specialized in radiology and endodontics, who in turn created an Excel spreadsheet with the data, in which numerical codes were defined to facilitate the final count. Number "1" for male, "2" for female. In the other column, "0" for the absence of the radix and "1" for the presence of the radix.

Inclusion criteria were presence of at least one permanent first or second lower molar without endodontic treatment, fully developed roots, and images with sharpness and adequate contrast. Exclusion criteria were dark and compromised CBCT images or images with artifacts that interfered with viewing the tooth of interest, making it difficult to evaluate, teeth with open root apices or with pathologic problems, root canal treatments, periapical abscesses, root resorption and calcification, and patients who refused to participate in the study.

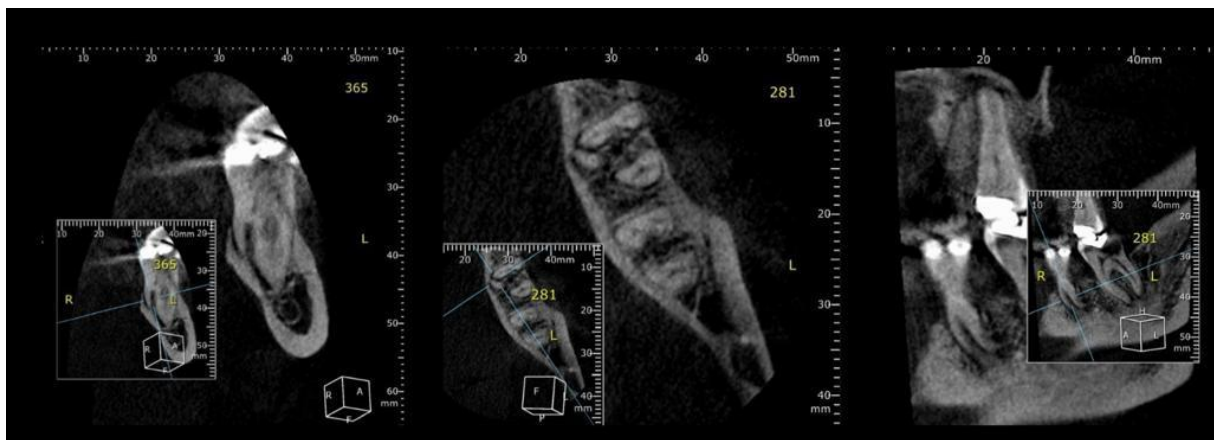
The determination of the number of mandibular molars examined by CBCT in this study was based on the sample calculation using the proportion estimation method according to the following equation: $n = z^2 * p * (1 - p) / d^2$, where 'n' represents

the sample size, 'z' the critical value corresponding to the confidence interval (1.96), p the prevalence rate (16.4%), and d the estimation error (5.0%).

Considering that the prevalence rate of radix in mandibular molars is 16.4%, the sample of this study was formed from 211 mandibular molars at an allowable error of 5% (expected precision around prevalence) and a confidence interval of 95%.

The images used were obtained by an experienced radiologist according to the instruction manual using a CRANEX 3D tomograph, model PP3-1, (SOREDEX, PaloDEX Group Nahkelantie 160 (P.O. Box 20) FIN -04300 Tuusula, FINLAND, according to ISO13485 and ISO9001 standards with a field of view of: (FOV) 61 x 41 mm (height X diameter). The image volume was reconstructed using isotropic isometric voxels of 0.25 x 0.25 x 0.25 mm Pixel image 200 m The tube voltage was 90 KVP, the tube current was 12.5mA, and the exposure time was 6.1s (Fig. 1).

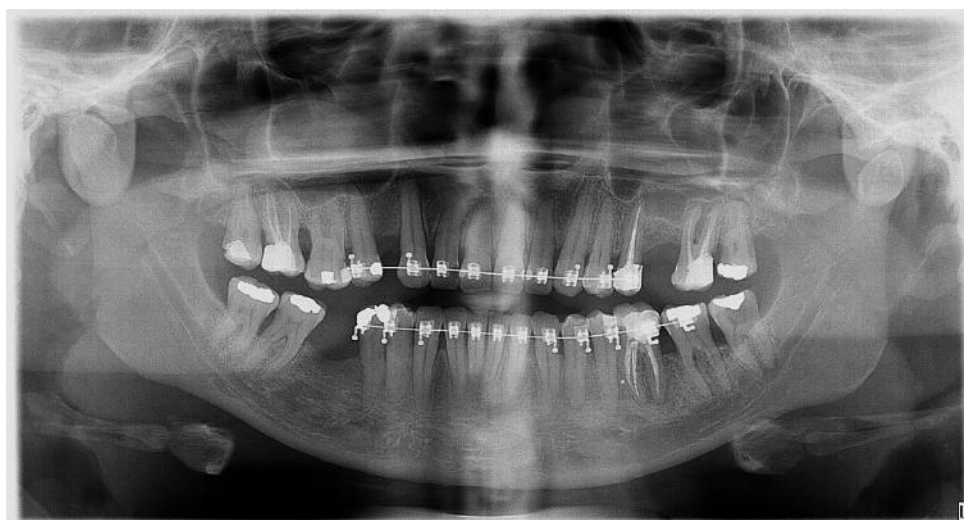Figure 1 – Micro-CT images of sections: coronal, axial and sagittal images.



Source: own authorship.

As well as X-ray image with 70KV and 13 mA, pixel image 100 x 100 m and exposure time 16.4s (Fig.2).

Figure 2 - Panoramic radiography.



Source: own authorship.

Images in DICOM format were processed, interpreted, and measured on a 20" LCD display, 1600 x 1200. The number of roots and canals was analyzed using axial sections (cervical, middle, and apical thirds), sagittal, coronal, and three-dimensional reconstructions to determine the number of roots.

A total of 850 cone beam computed tomography examinations were evaluated. Of these, a total of 422 (74.0%) were excluded because they were maxillary images; 101 (17.7%) because they were third molars; 38 (6.6%) because of edentulism in the areas of interest; and 9 (1.7%) because of endodontic treatment of the teeth of interest.

A total of 280 panoramic radiographs and CT scans were considered for analysis in the software IBM SPSS (26.0, IBM Corporation, Armonk, New York, USA). Fisher's exact association test was used to compare the frequency of distribution of RADIX by sex, and the Mann-Whitney test was used to compare the age of cases in which radix was or was not identified. U. A significance level of 5% was assumed for all tests.

3. Results

Examinations of 247 patients were evaluated. Of the 280 images evaluated (panoramic radiographs and computed tomography), 179 (63.9%) were from female subjects and 101 (36.1%) were from male subjects. The mean age of the individuals was 36.36 (± 12.34 years), with a median of 35.00 (27.25 - 44.00), with a minimum age of 9 and a maximum age of 84 years. A total of 108 (38.6%) lower left second molars, 90 (32.1%) lower right second molars, 49 (17.5%) lower left first molars, and 33 (11.8%) lower right first molars were examined.

Of all the teeth examined, a total of 2 teeth (0.7% of the total number of teeth examined) from different patients showed radix in tomography, whereas no radix was seen in radiography, with 100% agreement between the diagnoses of the two examinations. All cases of radix were identified in the lower left second molars and all those found were localized distolingually and classified as radix entomolar.

Although all cases of radix were identified in females, there was no statistically significant association between the presence of radix and the sex of the individuals examined on the imaging studies ($p = 0.300$; Fisher's Exact Test) (Table 1).

Table 1 - Distribution of individuals according to gender and presence/absence of radix in the CT scan. Brumado - BA, Brazil. 2022.

Gender	Radix in CBCT		P
	Não	Sim	
Female	177 (98,8%)	2 (1,2%)	0,300
Male	101 (100,0%)	0 (0,0%)	

Fisher's Exact Test. Significance level = 5%. Source: Own authorship.

As médias de idade dos pacientes onde se identificou ou não Radix foram de respectivamente, 42,25 ($\pm 9,25$) e de 36,28 ($\pm 12,37$) anos, com medianas de 38,50 (36,50 – 51,75) e de 35,00 (27,00 – 44,00) anos, não havendo diferença estatisticamente significante entre as idades para os casos em que se identificou ou não Radix ($p = 0,135$; Teste de Mann-Whitney U).

4. Discussion

The success of endodontic treatment is based on the eradication of microorganisms from the root system and the prevention of reinfection. Therefore, lack of knowledge about the complexity of the internal tooth anatomy may provide a niche for infection if a canal is overlooked (Mohammadi et al. 2016), which could compromise outcomes. For example, the treatment

of lower molars has always been a dilemma, mainly because of their anatomical variations (Abarca et al. 2020). Carabelli, 1844 introduced an important anatomical variation of the two lower first molars by a distolingual third root called radix entomolaris (RE) or mesiobuccal radix paramolaris (RP).

Many methods have been used to study the number of canals in tooth groups. Among them, computerized microtomography and diaphanization technique provide accurate information, but these methods can only be applied to extracted teeth (Martins et al. 2017).

CBCT is recommended by the American Association of Endodontists to identify anatomical variations and to study more complex cases (Patel et al. 2019). allows more accurate diagnosis than periapical radiography in identifying and locating root canals (Mohammadi et al. 2016), as it is a noninvasive technique that provides three-dimensional images in living teeth with axial, sagittal, and coronal sections

In our study, of all the teeth examined, a total of 2 teeth (0.7% of the total number of teeth examined and 0.8% of the total number of individuals examined) from different patients had a radix in tomography, whereas no radix was seen in panoramic radiography, with a difference in classification of 100% between the diagnoses of the two types of examination. In this case, the null hypothesis was not accepted.

The mean ages of patients in whom radix was or was not identified were 42.25 (± 9.25) and 36.28 (± 12.37) years, respectively, with medians of 38.50 (36.50-51.75) and 35.00 (27.00-44.00) years, with no statistically significant difference between the ages of cases in whom radix was or was not identified ($p = 0.135$; Mann-Whitney U test).

According to Carbberson et al. (2007), the percentage of prevalence by radix classification indicates that these root variations vary by ethnicity. Radix paramolars is a very rare variant and occurs less frequently than radix entomolars. PR occurs with a prevalence of less than 0.5%. The frequency of occurrence of ER is higher in the Asian region, ranging from 5 to 30%.

In China, for example, Zang et al. 2011 conducted a study with 232 teeth examined, in which 69 radix entomolar occurred, which corresponds to a rate of 29.7%. In Turkey, Çolak et al. 2012 conducted a study on 1205 teeth, of which 12 had radix entomolar, representing a rate of 1%. In South India, Chandra et al. 2011 conducted a study on a sample of 1000 teeth, of which 133 had radix entomolars, corresponding to 13.3%. In India, Bharti et al. 2011 conducted a study on 1265 teeth, which showed 20 radix entomolars, corresponding to a prevalence of 1.58%.

In a study conducted in Brazil, Rodrigues et al. 2016 found only 04 teeth with radix out of 232 teeth examined, for a rate of 1.7%, and all were radix entomolar. Already Silva et al. 2013 had 3.5% radix entomolartes in their study with 460 teeth evaluated.

In our study with 280 evaluated teeth, only 2 teeth had radix with a rate of 0.7%, and all were radix entomolartes, which is a low prevalence, supporting the study of Rodrigues in Brazil.

Regarding tooth type, the works of Duman et al. 2020, Bharti et al. 2011, Song et al. 2010, Zhang et al. 2011 differ from our study, as they found a higher prevalence in first molars, while the works of Scarfe et al. 2006 and Silva et al. 2013 found a higher prevalence in second molars, confirming our study, in which all cases of radix in second molars were identified on the left side.

Regarding gender, all cases of radix were identified in females in our study. The studies of Bharti et al. 2011 and Rodrigues et al. 2016 confirmed our work by finding a higher prevalence in females, while Çolak et al. 2012 and Duman et al. 2020 found a higher prevalence in males.

Regarding the position of the radix, some studies, such as that of De Souza Freitas et al, report a bilateral occurrence of ER from 50% to 67%. However, Barthi et al 2011 confirms our work with a higher incidence of radix unilateral.

Regarding the side of the mandible, the studies by Duman et al. 2020 and Barthi et al. 2011 found a higher prevalence on the right side of the mandible, thus disagreeing with the present study, in which ER was found only on the left side of the mandible.

To date, no study has been found that compared panoramic radiography and computed tomography for radix evaluation and radix examination in mandibular second molars in Brazil.

According to the meta-analysis performed by Martins et al, the worldwide prevalence rate of radix entomolar is 5.6%.

Although the Brazilian population has a low prevalence of radix in the first and second lower molars, further studies on the prevalence of anatomical variations such as radix are warranted, since Brazil is a country with high racial mixing, where genetic inheritance occurs from the main continental groups.

The clinical significance of this study is that the success of endodontic treatment is not compromised by the dentist's inability to locate all root canals.

5. Conclusion

It was concluded that CBCT is an important auxiliary method in analyzing the presence of radix canals. Panoramic radiography was not effective in diagnosing the presence of radix.

References

- Abarca, J., Duran, M., Parra, D., Steinfors, K., Zaror, C., & Monardes, H. (2020). Root morphology of mandibular molars: a cone-beam computed tomography study. *Folia Morphologica*, 79(2), 327-332.
- Ahmed, H. A., Abu-Bakr, N. H., Yahia, N. A., & Ibrahim, Y. E. (2007). Root and canal morphology of permanent mandibular molars in a Sudanese population. *International endodontic journal*, 40(10), 766-771.
- Bharti, R., Arya, D., Saamyendra, V. S., Kulwinder, K. W., Tikku, A. P., & Chandra, A. (2011). Prevalence of radix entomolaris in an Indian population. *Indian Journal of Stomatology*, 2(3), 165.
- Calberson, F. L., De Moor, R. J., & Deroose, C. A. (2007). The radix entomolaris and paramolaris: clinical approach in endodontics. *Journal of endodontics*, 33(1), 58-63.
- Cantatore, G., Berutti, E., & Castellucci, A. (2006). Missed anatomy: frequency and clinical impact. *Endodontic Topics*, 15(1), 3-31.
- Caputo, B. V., Noro Filho, G. A., de Andrade Salgado, D. M. R., Moura-Netto, C., Giovani, E. M., & Costa, C. (2016). Evaluation of the root canal morphology of molars by using cone-beam computed tomography in a Brazilian population: part I. *Journal of endodontics*, 42(11), 1604-1607.
- Carabelli, G. (1844). *Systematic handbook of dentistry*. Braumuller and Seidel Publication, Vienna.
- Chandra, S. S., Chandra, S., Shankar, P., & Indira, R. (2011). Prevalence of radix entomolaris in mandibular permanent first molars: a study in a South Indian population. *Oral Surgery, Oral Medicine, Oral Pathology, Oral Radiology, and Endodontology*, 112(3), e77-e82.
- Çolak, H., Özcan, E., & Hamidi, M. M. (2012). Prevalence of three-rooted mandibular permanent first molars among the Turkish population. *Nigerian Journal of Clinical Practice*, 15(3), 306-310.
- Duman, S. B., Duman, S., Bayrakdar, I. S., Yasa, Y., & Gumussoy, I. (2020). Evaluation of radix entomolaris in mandibular first and second molars using cone-beam computed tomography and review of the literature. *Oral radiology*, 36(4), 320-326.
- Grauer, D., Cevidanes, L. S., & Proffit, W. R. (2009). Working with DICOM craniofacial images. *American Journal of Orthodontics and Dentofacial Orthopedics*, 136(3), 460-470.
- Hiraiwa, T., Arijji, Y., Fukuda, M., Kise, Y., Nakata, K., Katsumata, A., & Arijji, E. (2019). A deep-learning artificial intelligence system for assessment of root morphology of the mandibular first molar on panoramic radiography. *Dentomaxillofacial Radiology*, 48(3), 20180218.
- Martins, J. N., Marques, D., Mata, A., & Caramês, J. (2017). Root and root canal morphology of the permanent dentition in a Caucasian population: a cone-beam computed tomography study. *International Endodontic Journal*, 50(11), 1013-1026.
- Mohammadi, Z., Asgary, S., Shalavi, S., & Abbott, P. V. (2016). A clinical update on the different methods to decrease the occurrence of missed root canals. *Iranian endodontic journal*, 11(3), 208.
- Ordinola-Zapata, R., Bramante, C. M., Versiani, M. A., Moldauer, B. I., Topham, G., Gutmann, J. L., & Abella, F. (2017). Comparative accuracy of the Clearing Technique, CBCT and Micro-CT methods in studying the mesial root canal configuration of mandibular first molars. *International endodontic journal*, 50(1), 90-96.

- Patel, S., Brown, J., Semper, M., Abella, F., & Mannocci, F. (2019). European Society of Endodontology position statement: Use of cone beam computed tomography in Endodontics: European Society of Endodontology (ESE) developed by. *International endodontic journal*, 52(12), 1675-1678.
- Rech, A. S., Toé, K. P. D., Claus, J., Pasternak, B., Freitas, M. P. M., & Thiesen, G. (2015). Utilização da tomografia computadorizada de feixe cônico no diagnóstico odontológico. *Rev. FullDent. Sci*, 6(22), 261-275.
- Rodrigues, C. T., Oliveira-Santos, C. D., Bernardineli, N., Duarte, M. A. H., Bramante, C. M., Minotti-Bonfante, P. G., & Ordinola-Zapata, R. (2016). Prevalence and morphometric analysis of three-rooted mandibular first molars in a Brazilian subpopulation. *Journal of Applied Oral Science*, 24, 535-542.
- Scarfe, W. C., Farman, A. G., & Sukovic, P. (2006). Clinical applications of cone-beam computed tomography in dental practice. *Journal-Canadian Dental Association*, 72(1), 75.
- Setzer, F. C., Hinckley, N., Kohli, M. R., & Karabucak, B. (2017). A survey of cone-beam computed tomographic use among endodontic practitioners in the United States. *Journal of endodontics*, 43(5), 699-704.
- Silva, E. J. N. L., Nejaim, Y., Silva, A. V., Haiter-Neto, F., & Cohenca, N. (2013). Evaluation of root canal configuration of mandibular molars in a Brazilian population by using cone-beam computed tomography: an in vivo study. *Journal of endodontics*, 39(7), 849-852.
- Song, J. S., Choi, H. J., Jung, I. Y., Jung, H. S., & Kim, S. O. (2010). The prevalence and morphologic classification of distolingual roots in the mandibular molars in a Korean population. *Journal of endodontics*, 36(4), 653-657.
- de Souza-Freitas, J., Lopes, E. S., & Casati-Alvares, L. (1971). Anatomic variations of lower first permanent molar roots in two ethnic groups. *Oral Surgery, Oral Medicine, Oral Pathology*, 31(2), 274-278.
- TU, Ming-Gen., et al. (2009). Detection of permanent three-rooted mandibular first molars by cone-beam computed tomography imaging in Taiwanese individuals. *Journal of endodontics*, 35(4), 503-507.
- Venskutonis, T., Plotino, G., Juodzbaly, G., & Mickevičienė, L. (2014). The importance of cone-beam computed tomography in the management of endodontic problems: a review of the literature. *Journal of endodontics*, 40(12), 1895-1901.
- Vertucci, F. J. (1984). Root canal anatomy of the human permanent teeth. *Oral surgery, oral medicine, oral pathology*, 58(5), 589-599.
- Zhang, R., Wang, H., Tian, Y. Y., Yu, X., Hu, T., & Dummer, P. M. H. (2011). Use of cone-beam computed tomography to evaluate root and canal morphology of mandibular molars in Chinese individuals. *International endodontic journal*, 44(11), 990-999.