

Epidemiological, clinical and anatomopathological characterization of nasal rhinosporidiosis in a horse

Caracterização epidemiológica, clínica e anatomopatológica da rinosporidiose nasal em um cavalo

Caracterización epidemiológica, clínica y anatomopatológica de la rinosporidiosis nasal en un caballo

Received: 08/14/2022 | Reviewed: 08/28/2022 | Accept: 08/31/2022 | Published: 09/08/2022

Isabela Calixto Matias

ORCID: <https://orcid.org/0000-0003-0548-1125>
Universidade Federal de Campina Grande, Brazil
E-mail: isabelacm.vet@gmail.com

Laynaslan Abreu Soares

ORCID: <https://orcid.org/0000-0002-6489-7326>
Universidade Federal de Campina Grande, Brazil
E-mail: laynaslanabreu@gmail.com

Amanda de Carvalho Gurgel

ORCID: <https://orcid.org/0000-0002-0530-1318>
Instituto Federal de Educação, Ciência e Tecnologia da Paraíba, Brazil
E-mail: amandagurgelvet@gmail.com

Amanda Estefanir Cordeiro

ORCID: <https://orcid.org/0000-0001-7936-1690>
Instituto Federal de Educação, Ciência e Tecnologia da Paraíba, Brazil
E-mail: amanda.veterinaria13@gmail.com

Caroline Gomes da Silva

ORCID: <https://orcid.org/0000-0001-8382-3923>
Instituto Federal de Educação, Ciência e Tecnologia da Paraíba, Brazil
E-mail: carol33silva@gmail.com

Hodias Sousa de Oliveira Filho

ORCID: <https://orcid.org/0000-0002-5954-8922>
Instituto Federal de Educação, Ciência e Tecnologia da Paraíba, Brazil
E-mail: hodiasfilho2@gmail.com

Hermano Manoel Francisco Figueiredo Bezerra

ORCID: <https://orcid.org/0000-0003-4250-1236>
Instituto Federal de Educação, Ciência e Tecnologia da Paraíba, Brazil
E-mail: hermanomanoel21@gmail.com

Gerônimo Sucupira Júnior

ORCID: <https://orcid.org/0000-0001-7456-5010>
Instituto Federal de Educação, Ciência e Tecnologia da Paraíba, Brazil
E-mail: geronciojuniorvet@gmail.com

Glauco José Nogueira de Galiza

ORCID: <https://orcid.org/0000-0002-0551-1964>
Universidade Federal de Campina Grande, Brazil
E-mail: ggaliza@yahoo.com

Lisanka Ângelo Maia

ORCID: <https://orcid.org/0000-0002-2471-5700>
Instituto Federal de Educação, Ciência e Tecnologia da Paraíba, Brazil
E-mail: lisanka.maia@ifpb.edu.br

Antônio Flávio Medeiros Dantas

ORCID: <https://orcid.org/0000-0002-6123-2273>
Universidade Federal de Campina Grande, Brazil
E-mail: antonioflaviomd@gmail.com

Abstract

The objective of this study is to describe the clinical, epidemiological and anatomopathological aspects of a case of nasal rhinosporidiosis in a horse in the Northeast of Brazil. A 15-year-old female horse of mixed breed presented a nodule in the mucosa of the right nasal septum. Surgical excision was performed and sent for histopathological examination. Macroscopically, the nodule had an irregular and reddish surface, and when cut it was soft, whitish, and polypoid in shape. Microscopically, myriads of sporangia with endospores inside were observed in the lamina propria, morphologically similar to *Rhinosporidium seeberi* in various stages of maturation. The structures were also evidenced and marked by periodic acid Schiff (PAS), Grocott methenamine silver (GMS) and toluidine blue. The diagnosis of

rhinosporidiosis was made based on macroscopic aspects and confirmed through histopathological examination. The presence of myriads of sporangia measuring 115 to 220 μm , containing endospores in its interior allowed the diagnosis. Although rhinosporidiosis is considered rare in Brazil, in the Northeast region there are descriptions of the disease in humans, suggesting that the disease in animals occurs and has possibly not been diagnosed. Therefore, it is important to include it as a differential diagnosis of diseases that affect the nasal cavity of horses in the region and that present similar lesions.

Keywords: *Rhinosporidium seeberi*; Equine; Nasal septum; PAS.

Resumo

O objetivo deste trabalho é descrever os aspectos clínicos, epidemiológicos e anatomopatológicos de um caso de rinosporidiose nasal em um equino no Nordeste do Brasil. Um equino, fêmea, de 15 anos de idade, sem raça definida (SRD) apresentava um nódulo na mucosa do septo nasal direito. Foi realizada exérese cirúrgica e envio para exame histopatológico. Macroscopicamente, o nódulo apresentava superfície irregular e avermelhada, e ao corte exibia projeções digitiformes nas extremidades. Microscopicamente, observou-se na lâmina própria miríades de esporângios com endósporos em seu interior com morfologia semelhante a *Rhinosporidium seeberi* em várias fases de maturação. As estruturas também foram evidenciadas e marcadas pelo ácido periódico de Schiff (PAS), metenamina de prata de Grocott (GMS) e azul de toluidina. O diagnóstico de rinosporidiose foi realizado baseado nos aspectos macroscópicos e confirmados através do exame histopatológico. A presença de miríades de esporângios medindo de 115 a 220 μm , contendo endósporos em seu interior permitiram o diagnóstico. Apesar de a Rinosporidiose ser considerada rara no Brasil, na região Nordeste há descrição da doença em humanos, sugerindo que a doença em animais ocorre e possivelmente não tem sido diagnosticada. Portanto, torna-se importante incluí-la como diagnóstico diferencial das doenças que afetam a cavidade nasal de equídeos na região e que cursam com lesões semelhantes.

Palavras-chave: *Rhinosporidium seeberi*; Equídeos; Septo nasal; PAS.

Resumen

El objetivo de este estudio es describir los aspectos clínicos, epidemiológicos y anatomopatológicos de un caso de rinosporidiosis nasal en un caballo del Nordeste de Brasil. Un caballo mestizo hembra de 15 años de edad presentó un nódulo en la mucosa del tabique nasal derecho. Se realizó escisión quirúrgica y se envió para examen histopatológico. Macroscópicamente el nódulo tenía una superficie irregular y rojiza, y al corte presentaba proyecciones digitiformes en las extremidades. Microscópicamente, se observó en la lámina propia miríadas de esporangios con endosporas en su interior con una morfología similar a *Rhinosporidium seeberi* en varios estados de maduración. Las estructuras también fueron evidenciadas y marcadas por ácido periódico de Schiff (PAS), metenamina de plata de Grocott (GMS) y azul de toluidina. El diagnóstico de rinosporidiosis se basó en aspectos macroscópicos y se confirmó mediante examen histopatológico. La presencia de miríadas de esporangios de 115 a 220 μm , que contenían endosporas en su interior, permitió el diagnóstico. Aunque la rinosporidiosis se considera rara en Brasil, en la región Nordeste existe una descripción de la enfermedad en humanos, lo que sugiere que la enfermedad en animales ocurre y posiblemente no haya sido diagnosticada. Por ello, es importante incluirlo como diagnóstico diferencial de enfermedades que afectan la fosa nasal de los equinos de la región y que presentan lesiones similares.

Palabras clave: *Rhinosporidium seeberi*; Équidos; Tabique nasal; PAS.

1. Introduction

Rhinosporidiosis is a chronic and zoonotic infection caused by *Rhinosporidium seeberi* (López & Martinson, 2017; Pereira & Meireles, 2007), currently considered a parasite of the kingdom Protista, class Mesomycetozoa and family Rhinosporideaceae (López & Martinson, 2017). Although previously described as a fungus (Seeber, 1900), the modification in its taxonomic classification was based on the microorganism's inability to grow in synthetic culture media (Vilela & Mendoza, 2012).

Cases of rhinosporidiosis have been described mainly in horses (Argenta et al., 2018; Tizzano et al., 2021; Zibordi et al., 2020), humans (Ghosh et al., 2021; Sarkar et al., 2020; Tiwari et al., 2015), and sporadically in cattle (Riet-Correa et al., 1983), mules (Berrocal & López, 2007), canines (Borrás et al., 2020; Borteiro et al., 2018; Cridge et al., 2021), cats (Brenseke & Saunders, 2010; Moisan & Baker, 2001) and waterfowl (Kennedy et al., 1995). Lesions are characterized by polypoid, granulomatous, friable and painless nodules, which can occur in the nasal cavity, larynx, ocular conjunctiva, skin, oral mucosa, genitalia, lips and ears (Tiwari et al., 2015). In horses, the nasal cavity is the most affected site and the occurrence of clinical signs is associated with the size and site of the lesion (Abud & Pereira, 2007).

Rhinosporidiosis is endemic in India, Sri Lanka and Argentina, and isolated cases have been described in Australia, South Africa, United States and Brazil (Pereira & Meireles, 2007). In Brazil, although the disease occurs sporadically, there are reports of the disease in the southern region in cattle (Riet-Correa et al., 1983) and horses (Argenta et al., 2018; Bernardo et al., 2016; Sampaio et al., 2018; Santos et al., 2014), and in the southeast region in dogs (Neves et al., 2014) and horses (Zibordi et al., 2020). In the Northeast, the disease is frequent in humans (Abud & Pereira, 2007; Silva et al., 1975), but there are no descriptions in animals. Therefore, the objective is to describe the clinical, epidemiological and anatomopathological aspects of a case of nasal rhinosporidiosis in a horse in the Northeast region of Brazil.

2. Methodology

A 15-year-old female horse of mixed-breed, during a routine clinical evaluation, was observed to have a nodule inside the nostril. It was raised together with another horse on a farm in the semiarid region of Paraíba. It fed on native pasture and drank water from a dam. On clinical examination, the animal was active, with a present appetite, heart rate of 32 bpm, and respiratory rate of 16 bpm. The nodule was adhered to the mucosa of the right nasal septum, and was pink in color, with a verrucous appearance, irregular surface and soft consistency (Figure 1. A). A cytological examination of the nodule was performed using the fine needle aspiration technique (FNA), with a diagnosis suggestive of cryptococcosis. Nodectomy with surgical margins measuring one centimeter in diameter was chosen, using local anesthetic block in the right infraorbital foramen, with 2% lidocaine.

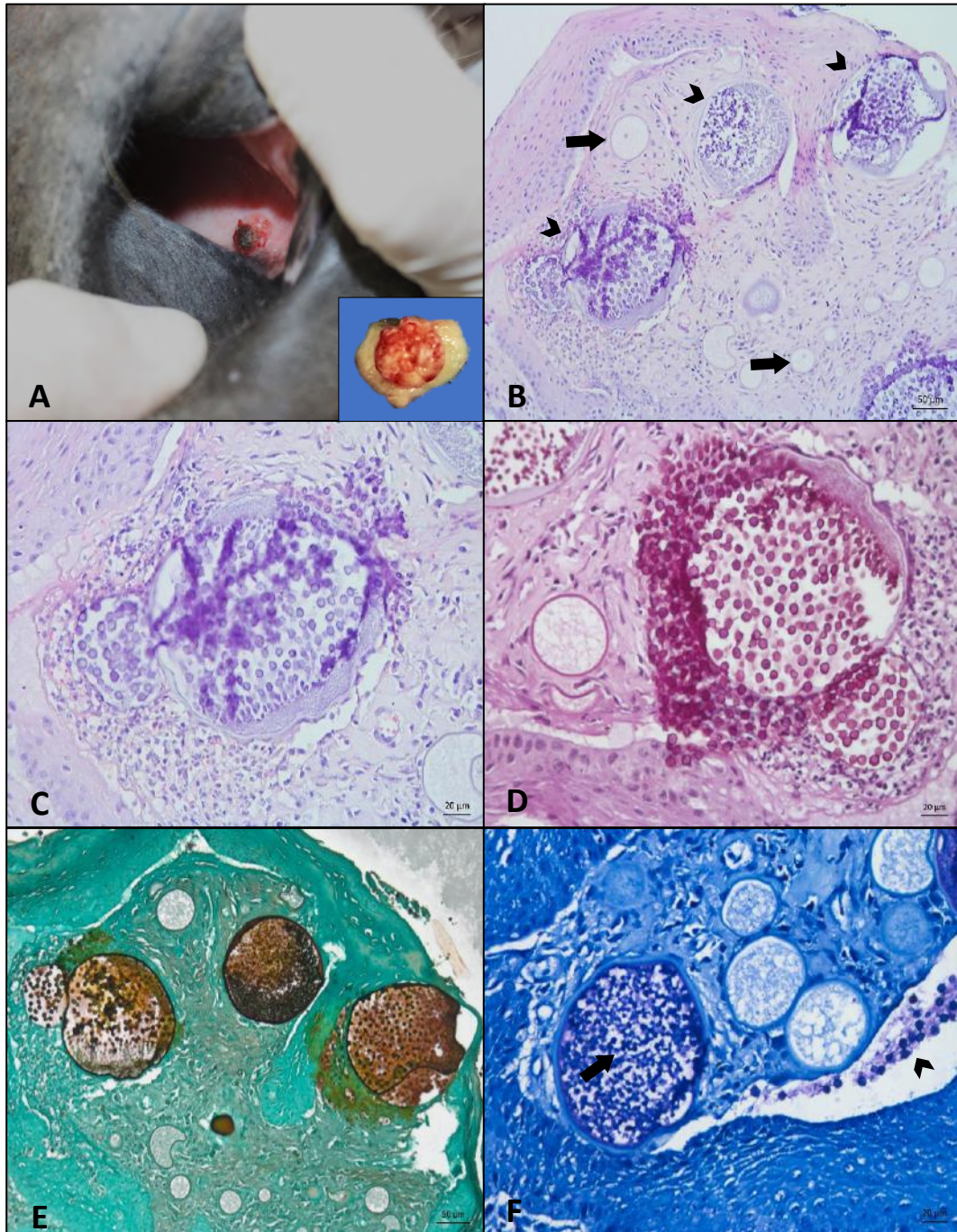
The collected material was fixed in 10% buffered formalin and sent for histopathological processing, according to the protocol described by Michalany (1998). The slides were stained with hematoxylin and eosin (HE), in addition to special histochemical stains such as periodic acid Schiff (PAS), Grocott methenamine silver (GMS) and toluidine blue.

3. Results

Macroscopically, the nodule measured approximately 0.5x0.5x0.2 cm in size, with an irregular and reddish surface (Figure 1. A, detail). When cut, it was soft, whitish and polypoid in shape. Microscopically, a discrete inflammatory infiltrate consisting of plasmocytes, lymphocytes, intact and degenerated neutrophils, and occasional macrophages associated with myriads of sporangia with endospores in their interior with morphology similar to *Rhinosporidium seeberi* in various stages of maturation was observed in lamina propria (Figure 1. B).

Young sporangia, measuring 7 to 65 μm , had a basophilic unilaminar wall, sometimes with a central nucleus surrounded by eosinophilic granular material (Figure 1. B). Mature sporangia were in greater number and measured from 115 to 220 μm , characterized by being rounded with a basophilic bilaminar wall, with immature endospores in the periphery and rounded mature endospores measuring up to 5 μm in the center. There were also sporangia with an intact cell wall and no internal structures, and others with a broken wall and free endospores. It was also observed proliferation of epithelial cells into the lamina propria, forming digitiform projections, in addition to acanthosis.

Figure 1. Equine nasal rhinosporidiosis. **(A)** Nodule in the mucosa of the animal's right nasal septum. Detail: note that the mass has a digitiform and reddish irregular surface. **(B)** *Rhinosporidium seeberi* sporangia distributed multifocally in the lamina propria. Note that the young sporangia have a basophilic unilaminar wall and a central nucleus (arrows), and the mature sporangia have a basophilic bilaminar wall with endospores inside (arrowheads). HE, bar = 50µm. **(C)** Ruptured endospore surrounded by lymphoplasmacytic inflammatory infiltrate and mild necrosis with degenerated neutrophils. HE, bar = 20µm. **(D)** Magenta-impregnated wall of sporangia and endospores. PAS, bar = 20µm. **(E)** Mature sporangia impregnated in black and endospores stained brown. GMS, bar = 50µm. **(F)** Walls of mature sporangia and immature endospores (arrow) impregnated in blue, endospores heavily impregnated in purple (arrowhead). Toluidine Blue, bar = 20µm.



Source: Animal Pathology Laboratory – IFPB Veterinary Hospital.

The walls of the mature and immature sporangia, in addition to the wall and the internal granular bodies of the endospores, were strongly stained in pink (magenta) in the PAS (Figure 1. E). The GMS staining showed black impregnation of the walls of mature and ruptured sporangia and brown impregnation of endospores and granular bodies contained within (Figure 1. D). Young sporangia were not marked. The toluidine blue staining showed blue impregnation of the walls of mature, ruptured and young sporangia, and purple impregnation of the endospores (Figure 1. F). After surgical removal, the animal received monthly follow-up for two months and no recurrence was reported.

4. Discussion

The diagnosis of rhinosporidiosis was made based on clinical and macroscopic aspects, and confirmed through histopathological examination. The presence of myriads of sporangia measuring 115 to 220 μm containing endospores in their interior, and the positive PAS staining for capsule and internal granules of the endospores allowed the diagnosis.

The epidemiology, infection mechanisms and pathogenesis of rhinosporidiosis are not fully elucidated. It is believed that the transmission of *R. seeberi* is related to sources of stagnant water and soil contaminated by spores (Rath et al., 2015), and the nasal mucosa is the main site of infection through inhalation of spores or direct contact with water, allowing for agent inoculation (Neves et al., 2014).

There are no reports of animal-to-animal transmission (Ferreira & Ferreira, 1990). In this case, the animal had access to a dam, which was probably the source of infection. The importance of diagnosing this case is highlighted, as it awakens to the existence of sources of infection, as well as cultural and environmental characteristics of the Northeast region, which include the accumulation of water in dams, high temperatures and humidity, which possibly favor the perpetuation and development of this etiological agent, increasing the possibility of occurrence of the disease. It is noteworthy that in the Northeast region there is a description of the disease in humans, mainly in the states of Maranhão, Piauí and Bahia (Abud & Pereira, 2007; Silva et al., 1975; Vallarelli et al., 2011), suggesting that the disease also occurs in animals, but possibly has not been diagnosed.

After inoculation, it's believed that the microorganism invades the subepithelial stroma of the nasal mucosa or skin and induces chronic inflammation, which consequently culminates in the formation of solitary or multiple polyps, papillomas or warts (Jones et al., 2000). Depending on the dimensions of the lesions, there may be occlusion of the nasal passages and associated respiratory symptoms (Abud & Pereira, 2007; Jones et al., 2000). In this case, the verrucous lesion was only a finding during the clinical evaluation and respiratory signs were not observed. Possibly the characteristics of solitary lesions and slow growth, associated with the possibility of this disease being self-limiting (Neves et al., 2014) have contributed to the low occurrence of rhinosporidiosis diagnoses and, consequently, difficulty in clarifying its epidemiology, infection mechanisms and pathogenesis. Therefore, the importance of reports of this pathology in different animal and human species is highlighted.

The macroscopic lesion observed in this case was similar to that described in other cases of rhinosporidiosis in horses (Argenta et al., 2018; Tizzano et al., 2021; Zibordi et al., 2020). It is noteworthy that, in addition to the nasal septum mucosa, rhinosporidiosis lesions in horses have also been described in the larynx (Santos et al., 2014; Zibordi et al., 2020).

Histologically, *Coccidioides immitis*, *Emmonsia parva* and *E. crescens* have morphological characteristics similar to *R. seeberi*, which include the size of the sporangia and the presence of endospores (Santos et al., 2014). However, *C. immitis* sporangia are typically smaller, more uniform in size and shape, and with beads measuring 20-200 μm in diameter. *Emmonsia* spp. organisms are larger and form single endospores, which are characterized by presenting uninucleate, spherical conidia, measuring 10-20 μm in diameter for *E. parva* and up to 300 μm for *E. crescens* (Caswell & Williams, 2016). PAS staining evidenced the capsule and internal granules of the endospores and has been used to identify the agent in nasal mycoses in humans

(Boni et al., 2002) and horses (Sampaio et al., 2018), as well as to differentiate from *C. immitis*, which stain only the capsule of the endospores (Jones et al., 2000).

Other less frequent forms of diagnosis have been performed, including polymerase chain reaction (PCR) (Husain et al., 2020; Leeming et al., 2007) and antibody detection through the indirect immunofluorescence test (Crosara et al., 2009) and ELISA-dot (Sudasinghe et al., 2011), however in this case, due to the size of the fragment and clinical suspicion of cryptococcosis, they were not performed.

The treatment chosen was surgical excision of the nodule, considering that the main clinical suspicion based on cytological examination was cryptococcosis. In this case, complete removal of the nodule with a wide surgical margin resulted in complete healing without a history of recurrence. However, cases of recurrence after surgical resection have been observed in horses and it is postulated that during the surgical procedure there may be a release of endospores in adjacent tissues that culminate in the formation of lesions (Burgess et al., 2012; Zibordi et al., 2020), therefore, it has been recommended to perform surgical resection associated with cauterization in horses (Leeming et al., 2007; Zibordi et al., 2020). It's believed that cauterization contributes to the destruction of possible remaining structures of *R. seeberi*, reducing the chances of recurrence (Bernardo et al., 2016). Treatment with systemic chemical agents, such as antifungals or antimicrobials, has not been recommended, as they have low penetration into the sporangia membrane (Tiwari et al., 2015).

Considering that in this species the lesion occurs mainly in the nasal septum mucosa (Tiwari et al., 2015), it is important to carry out the differential diagnosis with other diseases that have a similar macroscopic presentation, such as nasal polyps and neoplasms (Trotte et al., 2008), in addition to granulomatous lesions caused by *Aspergillus* spp. (Caswell & Williams, 2016), *Cryptococcus neoformans*, *Histoplasma* spp., *Pseudoallescheria boydii*, *Conidiobolus coronatus* and *Pythium insidiosum* (Santos et al., 2014).

5. Conclusion

The occurrence of rhinosporidiosis in horses in the Northeast region of Brazil highlights the need to carry out research and publications in relation to its casuistry. It is believed that the macroscopic characteristics of the granulomatous lesion and the previously non-occurrence of this agent at the site influence the misdiagnosis, which is sometimes attributed to other infectious agents or inflammatory and neoplastic processes.

References

- Abud, L. do N., & Pereira, J. C. (2007). Nasal Rhinosporidiosis - Four Cases Relate and Literature Review. *Arquivos Internacionais de Otorrinolaringologia*, 11(2), 214–219.
- Argenta, F. F., Mello, L. S., Vielmo, A., Pavarini, S. P., Driemeier, D., & Sonne, L. (2018). Rhinosporidiosis in horses. *Pesquisa Veterinaria Brasileira*, 38(12), 2213–2216. <https://doi.org/10.1590/1678-5150-PVB-5982>
- Bernardo, F. D., Pazinato, F. M., Alves, C. E. F., Bueno, V. L. C., Franciscato, C., & Elias, F. (2016). Equine Nasal rhinosporidiosis in the Southern Rio Grande do Sul, Brazil - Case Report. *Brazilian Journal of Veterinary Medicine*, 38(2), 175–180. <https://www.rbmv.org/BJVM/article/view/234>
- Berrocal, A., & López, A. (2007). Nasal rhinosporidiosis in a mule. *Canadian Veterinary Journal*, 48(3), 305–306.
- Boni, E. S., Saliba, Z. M., Sessino, D. B., de Miranda, J. N. R., & Boni, M. (2002). Rinosporidiose da conjuntiva - Relato de caso. *Arquivos Brasileiros de Oftalmologia*, 65(1), 103–105. <https://doi.org/10.1590/S0004-27492002000100020>
- Borrás, P., Messina, F., di Sarli, C., Fernandez, F., Querol, E., Iachini, R., & Santiso, G. (2020). Rinosporidiosis por *Rhinosporidium seeberi* en un canino de Argentina. *Revista Argentina de Microbiología*, 53(2), 179–180. <https://doi.org/10.1016/j.ram.2020.08.002>
- Borteiro, C., Etcheverze, J., de León, N., Nieto, C., Arleo, M., Debat, C. M., Kolenc, F., Ubilla, M., Freire, J., & Dutra, F. (2018). Rhinosporidiosis in a dog from uruguay and review of the literature. *Brazilian Journal of Veterinary Pathology*, 11(3), 92–96. <https://doi.org/10.24070/bjvp.1983-0246.v11i3p92-96>
- Brenseke, B. M., & Saunders, G. K. (2010). Concurrent nasal adenocarcinoma and rhinosporidiosis in a cat. *Journal of Veterinary Diagnostic Investigation*, 22(1), 155–157. <https://doi.org/10.1177/104063871002200135>

- Burgess, H. J., Lockerbie, B. P., Czerwinski, S., & Scott, M. (2012). Equine laryngeal rhinosporidiosis in western Canada: *Journal of Veterinary Diagnostic Investigation*, 24(4), 777–780. <https://doi.org/10.1177/1040638712445773>
- Caswell, J. L., & Williams, K. J. (2016). Respiratory system. In M. G. Maaxie (Ed.), *Jubb, Kennedy and Palmer's Pathology of Domestic Animals* (6th ed., pp. 523–653). W.B Saunders.
- Cridge, H., Mamaliger, N., Baughman, B., & Mackin, A. J. (2021). Nasal Rhinosporidiosis: Clinical Presentation, Clinical Findings, and Outcome in Dogs. *Journal of the American Animal Hospital Association*, 57(3), 114–120. <https://doi.org/10.5326/JAAHA-MS-7121>
- Crosara, P. F. T. B., Becker, C. G., Freitas, V. A., Nunes, F. B., Becker, H. M. G., & Guimarães, R. E. S. (2009). Rinosporidiose nasal: diagnóstico diferencial de sinusite fúngica e papiloma invertido. *Arq. Int. Otorrinolaringol. (Impr.)*, 13(1), 93–95. http://www.arquivosdeorl.org.br/conteudo/acervo_port.asp?id=595
- Ferreira, A. J., & Ferreira, C. (1990). *Doenças Infectocontagiosas dos Animais Domésticos* (4th ed.). Fundação Calouste Gulbenkian.
- Ghosh, R., Mondal, S., Roy, D., Ray, A., Mandal, A., & Benito-León, J. (2021). A case of primary disseminated rhinosporidiosis and dapsone-induced autoimmune hemolytic anemia: A therapeutic misadventure. *IDCases*, 24. <https://doi.org/10.1016/j.idcr.2021.e01076>
- Husain, U., Tilak, R., Priyadarshi, K., & Aggarwal, sushil K. (2020). Trends in Diagnosis of Hydrophilic Pseudofungal Organism *Rhinosporidium seeberi*- Old To Recent Approach. *Journal of Pure and Applied Microbiology*, 14(4), 2295–2297. <https://doi.org/10.22207/JPAM.14.4.07>
- Jones, T. C., Hunt, R. D., & King, N. W. (2000). *Patologia Veterinária* (6th ed.). Manole.
- Kennedy, F. A., Buggage, R. R., & Ajello, L. (1995). Rhinosporidiosis: a description of an unprecedented outbreak in captive swans (*Cygnus* spp.) and a proposal for revision of the ontogenic nomenclature of. *Journal of Medical and Veterinary Mycology*, 33(3), 157–165. <https://doi.org/https://doi.org/10.1080/02681219580000341>
- Leeming, G., Smith, K. C., Bestbier, M. E., Barrelet, A., & Kipar, A. (2007). Equine rhinosporidiosis in United Kingdom. *Emerging Infectious Diseases*, 13(9), 1377–1379. <https://doi.org/10.3201/eid1309.070532>
- López, A., & Martinson, S. A. (2017). Respiratory System, Mediastinum, and Pleurae. In J. F. Zachary (Ed.), *Pathologic Basis of Veterinary Disease* (6th ed., p. 490). Elsevier.
- Michalany, J. (1998). *Técnica histológica em anatomia patológica: com instruções para o cirurgião, enfermeiras e citotécnico* (3rd ed., p. 295). São Paulo.
- Moisan, P. G., & Baker, S. V. (2001). Rhinosporidiosis in a cat. *Journal of Veterinary Diagnostic Investigation*, 13(4), 352–354. <https://doi.org/10.1177/104063870101300414>
- Neves, C. D., Dutra, N. R., Barbari Neto, F., & Silveira, L. S. da. (2014). Canine nasal rhinosporidiosis: case report in Brazil. *Revista Brasileira de Ciência Veterinária*, 21(4), 223–225. <https://doi.org/10.4322/rbcv.2015.299>
- Pereira, D. B., & Meireles, M. C. A. (2007). Rinosporidiose. In F. Riet-Correa, A. L. Schild, R. A. A. Lemos, & J. R. J. Borges (Eds.), *Doenças de Ruminantes e Equídeos* (3rd ed., pp. 467–469). Varela.
- Rath, R., Baig, S. A., & Debata, T. (2015). Rhinosporidiosis presenting as an oropharyngeal mass: A clinical predicament? *Journal of Natural Science, Biology, and Medicine*, 6(1), 241. <https://doi.org/10.4103/0976-9668.149207>
- Riet-Correa, F., Schild, A. L., Mendez, M. del C., Oliveira, J. A., Gil-Turnes, C., & Pelotas, A. G. (1983). *Atividades do Laboratório de Diagnóstico e doenças da área de influência no período 1978-1982*. (No. 4).
- Sampaio, A. J. S. de A., Bracarense, A. P. F. R. L., & Maria, F. N. (2018). Rhinosporidiosis in equine: case report. *Journal of Veterinary Science and Public Health*, 5(1), 072–079. <https://doi.org/10.4025/revcivet.v5i1.39686>
- Santos, A. C., Nogueira, C. E. W., Vieira, P. S., de Araujo, L. O., Amaral, L. A., Pazinato, F. M., Santos, F. C. C., & Curcio, B. da R. (2014). Nasal and Laryngeal Rhinosporidiosis in a Horse. *Acta Scientiae Veterinariae*, 42(62), 1–5.
- Sarkar, N. K., Mia, M. M. R., & Hasan, M. R. (2020). Tracheobronchial rhinosporidiosis: an uncommon life-threatening benign cause of airway obstruction. *Respirology Case Reports*, 8(7), 1–5. <https://doi.org/10.1002/rcr2.653>
- Seeber, G. R. (1900). *Un nuevo esporozuário parasito del hombre. Dos casos encontrados en polypos nasales*. Universidad Nacional de Buenos Aires.
- Silva, J. F. da, Silva, W. M. da, Nogueira, A. de M., & Cavalcante, S. E. (1975). Rinosporidiose nasal - estudo de 11 casos. *Revista Da Sociedade Brasileira de Medicina Tropical*, 9(1), 19–25. <https://doi.org/10.1590/s0037-86821975000100004>
- Sudasinghe, T., Rajapakse, R. P. V. J., Perera, N. A. N. D., Kumarasiri, P. V. R., Eriyagama, N. B., & Arseculeratne, S. N. (2011). The regional sero-epidemiology of rhinosporidiosis in Sri Lankan humans and animals. *Acta Tropica*, 120(1–2), 72–81. <https://doi.org/10.1016/J.ACTATROPICA.2011.06.016>
- Tiwari, R., Karthik, K., Dhama, K., Shabbir, M. Z., & Khurana, S. K. (2015). Rhinosporidiosis: A Riddled Disease of Man and Animals. *Advances in Animal and Veterinary Sciences*, 3(2s), 54–63. <https://doi.org/10.14737/journal.aavs/2015/3.2s.54.63>
- Tizzano, M. A., della Vedova, R., Lopez, R. A., Amor, V., Zubía, C., Córdoba, S. B., & Reynaldi, F. J. (2021). Equine rhinosporidiosis in Buenos Aires, Argentina. *Revista Argentina de Microbiología*, xxx, 10–12. <https://doi.org/10.1016/j.ram.2020.12.007>
- Trotte, M. N. de S., Santos, I. B. dos, Miranda, L. H. M. de, Amorim, A. R., Borges, J. R. J., & Menezes, R. C. (2008). Histopatologia de lesões tumoriformes presentes na cavidade nasal de eqüídeos do Brasil. *Ciência Rural*, 38(9), 2535–2539. <https://doi.org/10.1590/S0103-84782008005000004>

Vallarelli, A. F. A., Rosa, S. P., & de Souza, E. M. (2011). Rinosporidiose - manifestação cutânea. *Anais Brasileiros de Dermatologia*, 86(4), 795–796. <https://doi.org/10.1590/S0365-05962011000400029>

Vilela, R., & Mendoza, L. (2012). The taxonomy and phylogenetics of the human and animal pathogen *Rhinosporidium seeberi*: A critical review. *Revista Iberoamericana de Micologia*, 29(4), 185–199. <https://doi.org/10.1016/j.riam.2012.03.012>

Zibordi, M., Belli, C. B., Zoppa, A. L. do V. de, Spagnolo, J. D., Silva, L. C. L. C. da, & Baccarin, R. Y. A. (2020). Nasal and Laryngeal Rhinosporidiosis in Horses Treated with Electrocautery. *Acta Scientiae Veterinariae*, 48(October), 1–6. <https://doi.org/10.22456/1679-9216.101910>