

## **Gastrointestinal parasites in wild and exotic animals from a zoo in the State of Bahia, Brazil - first record**

**Parasitos gastrointestinais em animais silvestres e exóticos de um zoológico do estado da Bahia, Brasil - primeiro registro**

**Parásitos gastrointestinales en animales salvajes y exóticos de un zoológico del estado de Bahía, Brasil – primer registro**

Received: 09/05/2022 | Revised: 09/16/2022 | Accepted: 09/19/2022 | Published: 09/26/2022

### **Márcio Borba da Silva**

ORCID: <https://orcid.org/0000-0002-6497-7924>  
Universidade Federal da Bahia, Brasil  
E-mail: [biolmarcioborba@gmail.com](mailto:biolmarcioborba@gmail.com)

### **Deborah Froes de Oliveira**

ORCID: <https://orcid.org/0000-0003-4253-3078>  
Parque Municipal da Matinha, Brasil  
E-mail: [deborahmedvet@hotmail.com](mailto:deborahmedvet@hotmail.com)

### **Fábio Viana Santos**

ORCID: <https://orcid.org/0000-0002-8978-7801>  
Secretaria Municipal de Meio Ambiente de Itapetinga, Brasil  
E-mail: [fabioviana.pedagogo@gmail.com](mailto:fabioviana.pedagogo@gmail.com)

### **Caique Dos Santos Aguiar**

ORCID: <https://orcid.org/0000-0002-3714-1988>  
Universidade Federal da Bahia, Brasil  
E-mail: [caique1704@gmail.com](mailto:caique1704@gmail.com)

### **Isabela Sousa Prado**

ORCID: <https://orcid.org/0000-0003-2994-8949>  
Universidade Estadual de Santa Cruz, Brasil  
E-mail: [isabelapradow@gmail.com](mailto:isabelapradow@gmail.com)

### **Deivson Araújo Brandão**

ORCID: <https://orcid.org/0000-0001-6678-7836>  
Universidade Federal da Bahia, Brasil  
E-mail: [deivson11araujo@gmail.com](mailto:deivson11araujo@gmail.com)

### **Aline Almeida Pereira**

ORCID: <https://orcid.org/0000-0002-6790-6240>  
Centro Universitário Faculdade de Tecnologia e Ciências, Brasil  
E-mail: [line-lrd@hotmail.com](mailto:line-lrd@hotmail.com)

### **Tiago Sousa de Queiroz**

ORCID: <https://orcid.org/0000-0002-9694-6962>  
Universidade Federal da Bahia, Brasil  
E-mail: [thy.queiroz@hotmail.com](mailto:thy.queiroz@hotmail.com)

### **Laize Tomazi**

ORCID: <https://orcid.org/0000-0003-0977-8508>  
Universidade Federal da Bahia, Brasil  
E-mail: [laizetomazi@yahoo.com.br](mailto:laizetomazi@yahoo.com.br)

### **Ricardo Evangelista Fraga**

ORCID: <https://orcid.org/0000-0001-9345-4869>  
Universidade Federal da Bahia, Brasil  
E-mail: [ricardoefraga@hotmail.com](mailto:ricardoefraga@hotmail.com)

## **Abstract**

Parasitic infections can be a serious health problem for wild animals kept in captivity, however, coproparasitological assessments in Brazilian zoos are scarce and spaced. Therefore, this study aimed to evaluate the occurrence of endoparasites in the feces of wild and exotic captive animals in the zoo of Matinha Municipal Park, Itapetinga, Bahia, Brazil, the only zoo in the interior of Bahia, through the Mini-FLOTAC® technique, providing subsidies for the diagnosis and therapeutic treatment of parasitized animals. From May to August 2022, 124 stool samples from 35 species of reptiles, birds and mammals were collected. Analyzes were performed using the Mini-FLOTAC® technique in combination with Fill-FLOTAC®. The results show that 70.97% of the samples were positive for at least one gastrointestinal parasite. Birds (76.7%; 33/43) were the most parasitized animals. Twenty-seven *taxa* of

gastrointestinal parasites were identified, whether cysts, oocysts or eggs, being 8 protozoans and 19 helminths, with a predominance of coccidia, Oxyuridae and *Angusticaecum* sp. for reptiles, coccidia, *Ascaridia* spp., *Heterakis* spp. and *Strongyloides* spp. for birds, coccidia, Ancylostomatidae, Strongylida and *Strongyloides* spp. for mammals. In summary, the results presented reveal the importance of periodically carrying out coproparasitological examinations in zoos, in order to subsidize interventions by the technical team to promote the health and well-being of animals. This work constitutes the first publication on the coproparasitological evaluation of animals from a zoo in the state of Bahia.

**Keywords:** Zoo; Parasite; Wild animals; Exotic animals; Brazil.

### Resumo

Infecções parasitárias podem constituir um grave problema de saúde para animais silvestres mantidos em cativeiros, entretanto, as avaliações coproparasitológicas em zoológicos brasileiros são escassas e espaçadas. Diante disso, esse trabalho teve como objetivo avaliar a ocorrência de endoparasitas nas fezes dos animais silvestres e exóticos cativos no zoológico do Parque Municipal da Matinha, Itapetinga, Bahia, Brasil, único zoológico do interior da Bahia, através da técnica do Mini-FLOTAC®, fornecendo subsídios para o diagnóstico e tratamento terapêutico dos animais parasitados. Foram coletadas entre os meses de maio a agosto de 2022, 124 amostras de fezes de 35 espécies de répteis, aves e mamíferos. As análises foram realizadas utilizando a técnica do Mini-FLOTAC® em combinação com o Fill-FLOTAC®. Os resultados apontam que 70,97% das amostras estavam positivas para pelo menos um parasita gastrointestinal. As aves (76,7%; 33/43) foram os animais mais parasitados. Foram identificados 27 taxa de parasitos gastrointestinais, quer seja cistos, oocistos ou ovos, sendo 8 protozoários e 19 helmintos, havendo predomínio de coccídeos, Oxyuridae e *Angusticaecum* sp. para répteis, coccídeos, *Ascaridia* spp., *Heterakis* spp. e *Strongyloides* spp. para as aves, coccídeos, Ancylostomatidae, Strongylida e *Strongyloides* spp. para mamíferos. Em síntese, os resultados apresentados revelam a importância da realização periódica dos exames coproparasitológicos no plantel de zoológicos, de modo a subsidiar intervenções por parte da equipe técnica para promover a saúde e bem estar dos animais. Este trabalho constitui a primeira publicação sobre a avaliação coproparasitológica de animais de um zoológico do estado da Bahia.

**Palavras-chave:** Zoológico; Parasitas; Animais silvestres; Animais exóticos; Brasil.

### Resumen

Las infecciones parasitarias pueden ser un grave problema de salud para los animales silvestres mantenidos en cautiverio, sin embargo, las evaluaciones coproparasitológicas en los zoológicos brasileños son escasas y espaciadas. Por lo tanto, este estudio tuvo como objetivo evaluar la ocurrencia de endoparásitos en las heces de animales silvestres y exóticos en cautiverio en el zoológico del Parque Municipal da Matinha, Itapetinga, Bahía, Brasil, único zoológico en el interior de Bahía, a través de la técnica Mini-FLOTAC®, otorgar subsidios para el diagnóstico y tratamiento terapéutico de animales parasitados. De mayo a agosto de 2022 se recolectaron 124 muestras de heces de 35 especies de reptiles, aves y mamíferos. Los análisis se realizaron utilizando la técnica Mini-FLOTAC® en combinación con Fill-FLOTAC®. Los resultados muestran que el 70,97% de las muestras fueron positivas para al menos un parásito gastrointestinal. Las aves (76,7%; 33/43) fueron los animales más parasitados. Se identificaron 27 taxones de parásitos gastrointestinales, ya sean quistes, ooquistes u huevos, siendo 8 protozoos y 19 helmintos, con predominio de coccidios, Oxyuridae y *Angusticaecum* sp. para reptiles, coccidios, *Ascaridia* spp., *Heterakis* spp. y *Strongyloides* spp. para aves, coccidios, Ancylostomatidae, Strongylida y *Strongyloides* spp. para mamíferos. En resumen, los resultados presentados revelan la importancia de realizar periódicamente exámenes coproparasitológicos en los zoológicos, con el fin de subsidiar las intervenciones del equipo técnico para promover la salud y el bienestar de los animales. Este trabajo constituye la primera publicación sobre la evaluación coproparasitológica de animales de un zoológico en el estado de Bahía.

**Palabras clave:** Zoo; Parásitos; Animales salvaje; Animales exóticos; Brasil.

## 1. Introduction

A zoo is defined as a legal entity enterprise, consisting of a wild animals' collection kept alive in captivity or in semi-freedom and exposed to public visitation, to meet scientific, conservationist, educational and sociocultural purposes. (Brasil, 2015). Zoos play an important role in welcoming and conserving endangered species or individuals unable to survive in the wild (Silva et al., 2019).

Orsini and Bondan (2006) state that the long period of captivity causes functional changes, as a result of somatic (sounds, images and strange odors, among others), psychological, behavioral and mixed stressors (malnutrition, intoxication, action of infectious and parasitic agents, among others), which can make animals weakened and lacking the physical and psychological skills necessary for survival.

Parasitism can be defined as an obligate trophic association between individuals of two species in which one (the parasite) obtains its food from a living organism of another species (the host). This symbiotic relationship is very common in nature, playing an important role in ecosystems, regulating host populations, stabilizing food chains and structuring animal communities (Atkinson, 2008).

Parasitic infections can be a serious health problem for wild animals kept in captivity, and the morbidity and mortality of infections are dependent on the host species, the parasite and the parasite load, nutritional status, immunocompetence and physiological conditions of the host. The weaknesses in the proper management for each species pose a great risk to the health of the animals (Santos et al., 2015).

Lima (2018) points out that environmental and ecological changes combined with the proximity between humans, domestic and wild species offer numerous opportunities for the emergence of interspecific interactions, which contribute to the spread of numerous parasitic zoonoses.

Copro-parasitological assessments in Brazilian zoos are sparse and spaced (Barbosa et al., 2019), with records for the states of Goiás (Melo et al., 2021), São Paulo (Hofstatter & Guaraldo, 2015; Rodrigues et al., 2020), Paraíba (Batista et al., 2021), Paraná (Hofstatter & Guaraldo, 2015; Snak et al., 2017) Rio de Janeiro (Barros et al., 2017; Barbosa et al., 2019), Rio Grande do Sul (Mewius et al., 2021), Santa Catarina (Muller et al., 2005) and Sergipe (Santos et al., 2022).

For Capasso et al. (2019) and Guo et al. (2021) animals raised in restricted environments, like zoos, are highly susceptible to gastrointestinal infection by helminths and protozoans. Zoos are environments with high contamination by parasites. These authors proved that the Mini-FLOTAC® technique in combination with the Fill-FLOTAC® can be used not only for the rapid diagnosis of parasitic infections in zoos, but also for monitoring control programs quickly and reliably.

Thus, the present study aimed to evaluate the occurrence of endoparasites in the feces of wild and exotic captive animals in the zoo of Matinha Municipal Park, Itapetinga, Bahia, Brazil, the only zoo in the interior of Bahia, using the Mini-FLOTAC® technique, providing subsidies for the diagnosis and therapeutic treatment of parasitized animals. It is worth mentioning that this is the first work carried out in a zoo in the Bahia state.

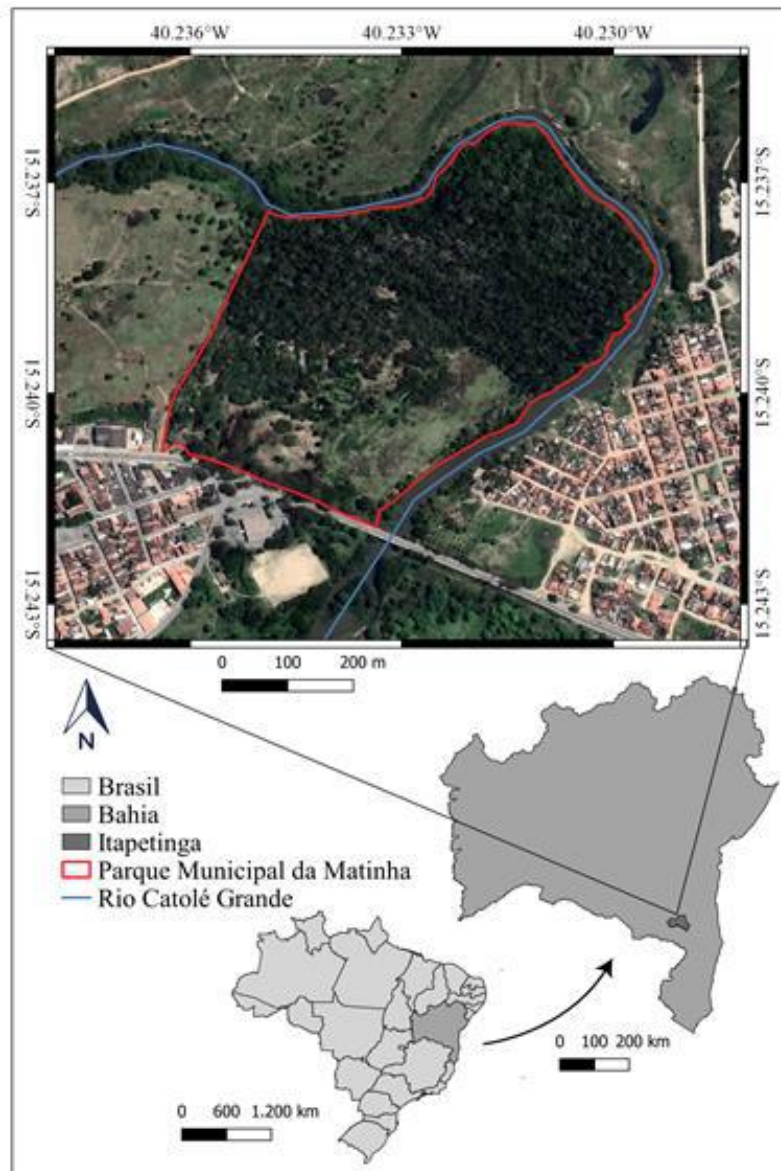
## **2. Methodology**

### **2.1 Study area**

The Matinha Municipal Park (Figure 1), created by municipal decree n° 860 of October 11, 1973 and law n° 528 of December 19, 1991, is located in the urban perimeter of the municipality of Itapetinga, southwest of Bahia, covering 24 hectares of which 10 hectares constitute a remaining area of the Atlantic Forest Biome surrounded by the Catolé Grande River up to the bridge next to the Bus Station (Kulka, 2014).

The park aims to preserve and conserve the representation of the Atlantic Forest, serving as a refuge for many species (Itapetinga, 2004). It houses a zoo, whose squad has species of birds, mammals and reptiles from the Center for the Triage of Wild Animals - CETAS (animals that are victims of trafficking and that often are no longer able to return to nature), in addition to exotic specimens from other zoos or breeding sites, thus constituting the only environmental protection area in the municipality and the only zoo in the interior of Bahia (Freitas et al., 2007).

**Figure 1:** Location of the study area, Matinha Municipal Park, Itapetinga, Bahia, Brazil.



Source: Authors.

Figure 1 shows the exact location of the Matinha Municipal Park, Itapetinga, Bahia, Brazil, which is highlighted with a red border, surrounded by the Catolé Grande River.

The zoo at Matinha Municipal Park had 36 enclosures at the time of collection. Figure 2 shows some animals and enclosures of the zoo. As the park was undergoing a restructuring in order to meet the requests of environmental agencies (INEMA - Instituto do Meio Ambiente e Recursos Hídricos), its squad was gradually increasing during collections as new species were incorporated into the enclosures.

**Figure 2:** Aspect of some enclosures and animals of the Matinha Municipal Park, Itapetinga, Bahia sampled in the study: a) Tortoise; b) Cougar; c) Scarlet macaw; d) Black-striped capuchin; e) Red-tailed boa; f) Crab-eating fox; g) Enclosure for black-striped capuchin; h) Brown brocket; i) Lion; j) Ostrich; k) Argentine black and white tegu; l) King vulture.



Source: Authors.

Figure 2 shows some animals and enclosures of the Matinha municipal park. By the end of the collections, the zoo had 35 species of captive animals, being 14 species of mammals, 06 species of reptiles and 15 species of birds, and all the enclosures were occupied.

## 2.2 Ethical aspects

The project was submitted to the Ethics Committee on the Use of Animals in Research of the Federal University of Bahia, Campus Anísio Teixeira of the Multidisciplinary Institute in Health (UFBA) (CEUA - IMS/CAT - UFBA) and approved (Opinion No. 104/2022).

## 2.3 Sampling

This work is descriptive quantitative research (Dalfovo et al., 2008; Pereira et al., 2018). Thus, 124 stool samples were collected from captive animals from the zoo at Matinha Municipal Park, Itapetinga, Bahia, Brazil between May and August 2022. 15 species of birds, 14 of mammals and 6 of reptiles were sampled (Table 1).

**Table 1:** Species of wild and exotic captive animals sampled from the zoo at Matinha Municipal Park, Itapetinga, Bahia, Brazil. NA: Number of animals; SN: Number of fecal samples.

Scientific name	Common name	NA	SN
<b>Order Testudines</b>			
<b>Family Testudinidae</b>			
<i>Chelonoidis carbonaria</i> (Spix, 1824)	Red-footed tortoise	8	13
<i>Chelonoidis denticulatus</i> (Linnaeus, 1766)	Yellow-footed tortoise	5	3
<b>Classe Lepidosauria</b>			
<b>Order Squamata</b>			
<b>Family Boidae</b>			
<i>Boa constrictor</i> (Linnaeus, 1758)	Red-tailed boa	1	2
<b>Família Pythonidae</b>			
<i>Malayopython reticulatus</i> (Schneider, 1801)	Reticulated python	1	2
<i>Python molurus</i> (Linnaeus, 1758)	India Rock python	1	1
<b>Family Teiidae</b>			
<i>Salvator merianae</i> Duméril & Bibron, 1839	Argentine black and white tegu	1	1
<b>Aves</b>			
<b>Order Cathartiformes</b>			
<b>Family Cathartidae</b>			
<i>Sarcoramphus papa</i> (Linnaeus, 1758)	King vulture	1	4
<b>Order Falconiformes</b>			
<b>Family Accipitridae</b>			
<i>Spizaetus melanoleucus</i> (Vieillot, 1816)	Black-and-white hawk-eagle	1	1
<b>Family Falconidae</b>			
<i>Caracara plancus</i> (Miller, 1777)	Crested caracara	2	3
<b>Order Galliformes</b>			
<b>Family Cracidae</b>			
<i>Ortalis guttata</i> (Spix, 1825)	Speckled chachalaca	1	3
<b>Family Phasianidae</b>			
<i>Pavo cristatus</i> Linnaeus, 1758	Common peafowl	4	5
<b>Order Piciformes</b>			
<b>Família Ramphastidae</b>			
<i>Ramphastos toco</i> Statius Muller, 1776	Toco toucans	2	1
<b>Order Psittaciformes</b>			
<b>Family Psittacidae</b>			
<i>Ara ararauna</i> (Linnaeus, 1758)	Blue-and-yellow macaw	6	4
<i>Ara chloropterus</i> Gray, 1859	Red-and-green macaw	6	4
<i>Ara macao</i> (Linnaeus, 1758)	Scarlet-macaw	2	1
<i>Aratinga auricapillus</i> (Kuhl, 1820)	Golden-capped parakeet	2	3
<i>Pionus maximiliani</i> (Kuhl, 1820)		4	3
<i>Psittacara leucophthalmus</i> (Statius Muller, 1776)	White-eyed parakeet	4	1

<b>Order Strigiformes</b>			
<b>Family Strigidae</b>			
<i>Pulsatrix perspicillata</i> (Latham, 1790)	Spectacled owl	1	1
<b>Família Tytonidae</b>			
<i>Tyto furcata</i> (Scopoli, 1769)	American barn owl	3	1
<b>Order Struthioniformes</b>			
<b>Family Struthionidae</b>			
<i>Struthio camelus</i> Linnaeus, 1758	Ostriches	4	8
<b>Classe Mammalia</b>			
<b>Order Artiodactyla</b>			
<b>Family Cervidae</b>			
<i>Mazama gouazoubira</i> Fischer, 1814	Brown brocket	4	4
<b>Família Camelidae</b>			
<i>Lama glama</i> (Linnaeus, 1758)	Llamas	2	2
<b>Order Carnivora</b>			
<b>Family Canidae</b>			
<i>Cerdocyon thous</i> (Linnaeus, 1766)	Crab-eating fox	3	6
<b>Family Procyonidae</b>			
<i>Potos flavus</i> Schreber, 1774	Kinkajou	1	2
<b>Family Felidae</b>			
<i>Leopardus pardalis</i> Linnaeus, 1758	Ocelot	2	2
<i>Panthera leo</i> (Linnaeus, 1758)	Lion	2	3
<i>Puma concolor</i> Linnaeus, 1771	Cougar	3	5
<b>Order Perissodactyla</b>			
<b>Family Tapiridae</b>			
<i>Tapirus terrestris</i> Linnaeus, 1758	South American tapir	2	1
<b>Order Pilosa</b>			
<b>Family Myrmecophagidae</b>			
<i>Myrmecophaga tridactyla</i> Linnaeus, 1758	Giant anteater	1	1
<b>Order Primates</b>			
<b>Family Atelidae</b>			
<i>Alouatta caraya</i> (Humboldt, 1812)	Black howler	2	3
<b>Family Callitrichidae</b>			
<i>Leontopithecus chrysomelas</i> (Kuhl, 1820)	Golden-headed Lion tamarin	1	1
<b>Family Cebidae</b>			
<i>Sapajus libidinosus</i> (Spix, 1823)	Black-striped capuchin	14	27
<b>Order Rodentia</b>			
<b>Family Caviidae</b>			
<i>Hydrochoreus hydrochaeris</i> Linnaeus, 1756	Capybaras	3	1
<b>Family Dasyproctidae</b>			
<i>Dasyprocta azarae</i> Lichtenstein, 1823	Azara's agouti	3	1

Source: Authors.

Table 1 shows the number of wild and exotic animals in captivity, with their respective orders and families, and the number of fecal samples collected.

The samples examined in this study were obtained by the keepers while cleaning the enclosures, prioritizing the collection of individual fresh fecal pellets. Each sample was defined as a sample of feces containing an amount greater than or equal to 2 grams, spontaneously eliminated by the animals, collected individually or in pools on the floor of the enclosure so as not to stress the animals. The definition of pool adopted in this work follows Fagiolini et al., (2010) and Capasso et al (2019), which consists of 2 grams of each individual fecal sample.

The fecal samples were placed in isothermal boxes (2 to 8°C) and immediately transported to the Zoology Laboratory of the Multidisciplinary Institute in Health, Campus Anísio Teixeira of the Federal University of Bahia, in Vitória da Conquista, Bahia, for analysis.

The fecal samples were processed using the Mini-FLOTAC® technique, following all the steps and guidelines as per the original description of the technique, using two flotation solutions: FS2 (Sodium Chloride, specific gravity SG = 1,200) and FS7 (Zinc Sulfate, SG = 1,350), and each sample was analyzed twice (Cringoli et al. 2017).

The preparations were examined under a binocular Optical Microscope at 100X and 400X magnifications. Photomicrographs and measurements of the parasitic structures were performed with the aid of a digital camera and micrometric eyepiece, respectively. Fecal samples were considered positive when at least one evolutionary form of a parasite (egg, cyst and/or oocyst) was detected (Barbosa et al., 2019).

The taxonomic identification of cysts, oocysts, and eggs was performed at the lowest possible taxonomic level with the help of specific bibliography (Brandão, 2007; Bowman et al., 2010; Lima et al, 2017; Carvalho, 2018; Monteiro, 2018; Zago, 2018; Ruivo, 2019; Taylor et al., 2020; Batista et al., 2021; Cesario, 2021; Souza et al., 2021). In some cases, when the characteristics and measurements performed did not allow a more specific refinement in the taxonomy, broader taxonomic categories were used, that is, Class (Trematoda), Order (Ascaridida, Strongylida), Family (Ancylostomatidae, Oxyuridae) or Superfamily (Trichostrongyloidea).

## 2.4 Data analysis

Data were tabulated and analyzed using the GraphPad Prism® version 5 software. The results were expressed as the arithmetic mean number of eggs/oocysts/cysts per gram (EPG/OPG/CPG) of feces, in addition to the minimum and maximum values (Capasso et al., 2019). Prevalence was estimated by dividing the number of positive samples by the total number of samples collected from each group of animals under study (Barbosa et al., 2019).

## 3. Results

Among the 124 pools analyzed, 88 were positive for at least one gastrointestinal parasite, which represents 70.97% of the samples. Comparing the zoological groups evaluated, birds (76.7%; 33/43) were the most parasitized when compared to the other groups, followed by mammals (72.9%; 33/43) and by reptiles (54.6%; 12/22) (Table 2).

In total, 27 *taxa* of gastrointestinal parasites were identified, whether cysts, oocysts or eggs, being 8 protozoans and 19 helminths (Table 2 and Figure 3). Among the protozoans, 12.5% were amoeba, 12.5% ciliated (both identified at the generic level) and the vast majority were coccidia, about 75% (5 *taxa* were identified to genus and the others grouped as non-sporulating coccidia). As for helminths, 10.5% were Trematoda flatworms, one of them identified at the genus level and the other only in the Trematoda class. All other helminths belonged to Nematoda, representing 89.5%. Of these, 11.8% were identified to the family, 11.8% to the order, 5.9% to the superfamily, 64.7% were identified at the genus level and 5.9% at the species level (Table 2).



**Table 2:** Number of positive samples for each animal category sampled in Matinha Municipal Park, Itapetinga – Bahia, Brazil. In parentheses the prevalence of each parasite in relation to the total number of samples for each sampled animal.

Parasites	Reptiles			Birds							Mammals					
	Tortoise	Snakes	Lizards	Cathartiformes	Falconiformes	Galliformes	Piciformes	Pittaciformes	Strigiformes	Struthioniformes	Artiodactyla	Carnivora	Perissodactyla	Pilosa	Primates	Rodentia
<b>Protozoans</b>																
<i>Entamoeba</i> spp.	4 (25%)	0	0	0	0	2 (25%)	0	2 (12,5%)	0	0	0	2 (11,2%)	0	0	0	0
<i>Blastocystis</i> spp.	1 (6,25%)	0	0	0	0	1 (12,5%)	0	0	0	0	0	2 (11,2%)	0	0	0	0
<i>Caryospora</i> spp.	0	2 (40%)	0	0	0	0	0	0	0	0	0	0	0	0	0	0
<i>Cyclospora</i> sp.	0	0	0	0	0	0	0	1 (6,25%)	0	0	0	0	0	0	0	0
<i>Eimeria</i> spp.	0	0	0	1 (25%)	0	4 (50%)	0	0	0	0	0	2 (11,2%)	0	0	1 (3,2%)	0
<i>Isospora</i> spp.	0	0	0	0	1 (25%)	2 (25%)	0	0	0	0	0	0	0	0	0	0
Non-sporulated																
Coccidia	0	0	0	0	2 (50%)	5 (62,5%)	0	1 (6,25%)	0	2 (25%)	2 (33,3%)	0	0	0	2 (6,4%)	0
<i>Nyctotherus</i> sp.	4 (25%)	0	0	0	0	0	0	0	0	0	0	0	0	0	0	0
<b>Helminths</b>																
Trematoda	1 (6,25%)	0	0	0	0	0	0	0	0	0	0	0	0	0	0	0
<i>Alaria</i> sp.	0	0	0	0	0	0	0	0	0	4 (50%)	0	0	0	0	0	0
Strongylida	0	2 (40%)	1 (100%)	2 (50%)	0	0	1 (100%)	1 (6,25%)	0	0	0	1 (5,6%)	1 (100%)	0	5 (16%)	
Ancylostomatidae	0	0	0	0	0	0	0	0	0	0	0	8 (44,8%)	0	0	3 (9,6%)	0
<i>Haemonchus</i> spp.	0	0	0	0	0	0	0	0	0	0	4 (66,6%)	0	0	0	0	0
Trichostrongyloidea	0	0	0	0	0	1 (12,5%)	0	1 (6,25%)	0	0	0	0	0	1 (100%)	0	1 (50%)
<i>Ostertagia</i> spp.	0	0	0	0	0	0	0	0	0	0	2 (33,3%)	0	0	0	0	0
Ascaridida	0	0	0	0	0	0	0	0	0	0	1 (16,7%)	2 (11,2%)	0	0	3 (9,6%)	0
<i>Ascaridia</i> spp.	0	0	0	0	0	0	0	6 (37,5%)	1 (50%)	5 (62,5%)	0	0	0	0	0	0
<i>Angusticaecum</i> sp.	7 (43,75%)	0	0	0	0	0	0	0	0	0	0	0	0	0	0	0
<i>Heterakis</i> spp.	0	0	0	0	0	0	0	1 (6,25%)	0	7 (87,5%)	0	0	0	0	0	0
<i>Toxascaris</i> sp.	0	0	0	0	0	0	0	0	0	0	0	1 (5,6%)	0	0	0	0
<i>Toxocara</i> spp.	0	0	0	0	0	0	0	0	0	0	0	1 (5,6%)	0	0	0	0
<i>Toxocara vitulorum</i>	0	0	0	0	0	0	0	0	0	0	1 (16,7%)	0	0	0	0	0
<i>Strongyloides</i> spp.	3 (18,75)	1 (20%)	0	1 (25%)	0	0	1 (100%)	2 (12,5%)	1 (50%)	1 (12,5%)	3 (50%)	2 (11,2%)	0	0	14 (44,8%)	0
<i>Capillaria</i> spp.	0	0	1 (100%)	0	1 (25%)	0	0	2 (12,5%)	0	0	0	0	0	0	0	0

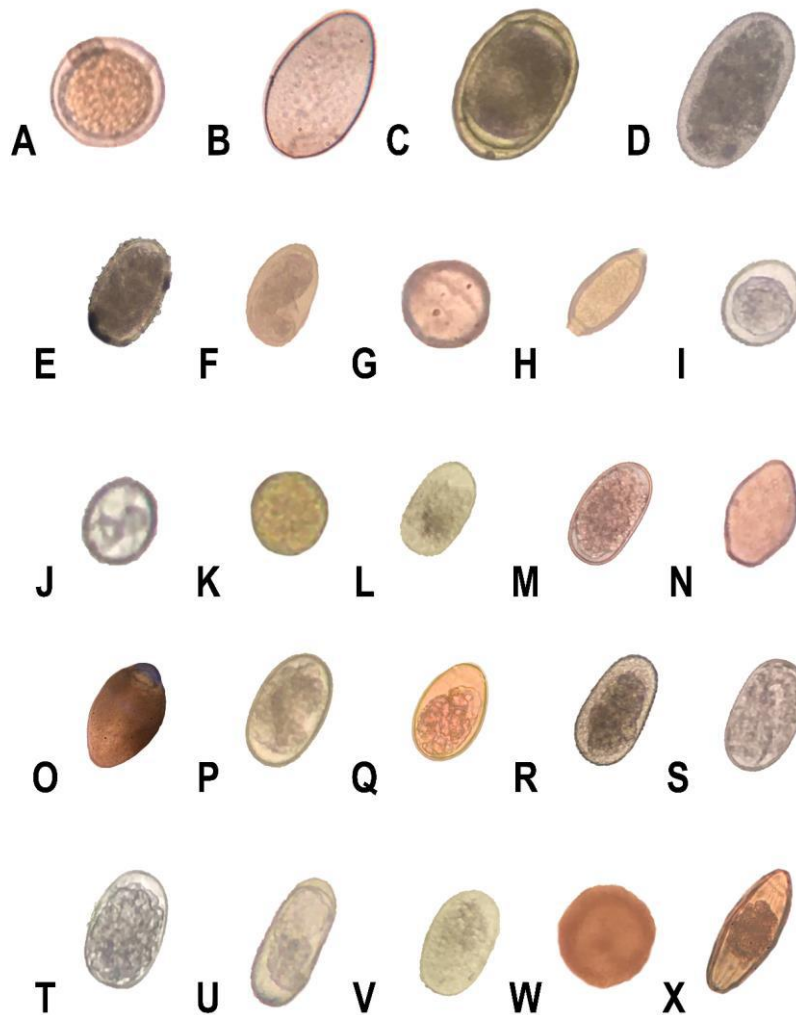
---

<i>Trichuris</i> sp.	0	0	0	0	0	0	0	0	0	0	0	0	1 (5,6%)	0	0	0	0
Oxyuridae	3 (18,75)	0	0	0	0	0	0	0	0	0	0	0	0	0	0	0	0
<i>Trypanoxyuris</i> sp.	0	0	0	0	0	0	0	0	0	0	0	0	0	0	0	2 (6,4%)	0
NI	1 (6,25%)	0	0	0	0	0	0	0	0	0	0	0	0	0	0	1 (3,2%)	0

---

Source: Authors.

**Figure 3:** Gastrointestinal parasites found in fecal samples of wild and exotic animals from the zoo at Matinha Municipal Park, Itapetinga, Bahia, Brazil. A- Egg of *Angusticaecum* sp. in *Chelonoidis carbonaria*; B- Egg of *Alaria* sp. in *Struthio camelus*; C- Egg of *Ascaridia* sp. in *Ara ararauna*; d- Egg of Ascaridida on *Sapajus libidinosus*; E- Ascarididae-type eggs in *Mazama gouazoubira* F- Ancylostomatidae-type eggs in *Panthera leo*; G- Oocyst of *Blastocystis* spp. on *Chelonoidis carbonaria*; H- Egg of *Capillaria* spp. on *Ara chloropterus*; I- Unsporulated oocyst of coccidia in *Pavo cristatus*; J- Oocyst of *Eimeria* spp. in *Potos flavus*; K- Cyst of *Entamoeba* spp. in *Sapajus libidinosus*; L- Egg of *Haemonchus* spp. in *Mazama gouazoubira*; M- Egg of Strongylida types in *Struthio camelus*; N- Oocyst of *Isospora* spp. in *Carcara plancus*; O- Cyst of *Nyctotherus* sp. in *Chelonoidis carbonaria*; P- Egg of *Ostertagia* sp. in *Lama glama*; Q- Oxyuridae-type eggs in *Chelonoidis carbonaria*; R- Strongylida-type eggs in *Salvator merianae*; S- Strongylida-type eggs in *Rhampastos toco*; T- Strongylida-type eggs in *Sapajus libidinosus*; U- Egg of *Strongyloides* spp. in *Sarcoramphus papa*; V- Trichostrongylidae-type eggs in *Ortalis guttata*; W- Egg of *Toxocara* sp. on *Leopardus pardalis*; X- Egg of *Tripaenoxuris* spp. in *Sapajus libidinosus*. Objective (40x).



Source: Authors.

Figure 3 shows photos of cysts, oocysts and eggs of gastrointestinal parasites found in the fecal samples of wild and exotic animals from the zoo.

Of the total positive samples for reptiles, 58.3% correspond to tortoises, 33.3% to snakes and 8.3% to lizards. We recorded 3 protozoans (*Caryospora* spp., *Isospora* spp. e *Nyctotherus* spp), 6 helminths, one up to class (Trematoda), one up to

order (Strongylida), one up to family (Oxyuridae), 3 genera (*Angusticaecum* sp., *Strongyloides* spp., *Capillaria* sp.) and an unidentified parasite. The most prevalent parasites for tortoises were *Angusticaecum* sp., *Strongyloides* spp., Oxyuridae and *Entamoeba* spp.; for snakes *Caryospora* spp. and *Strongylida*, and for the lizard *Strongylida* and *Capillaria* sp., were the most prevalent parasites (Table 2).

Of the positive samples for birds, 27.3% were Psittaciformes, 24.2% Sthruiformes and Galliformes, 9.1% Cathariniformes and Falconiformes, 3% Strigiformes and Piciformes. Six protozoans were identified, of which 5 genera (*Entamoeba* spp., *Blastocystis* spp., *Cyclospora* sp., *Eimeria* spp., *Isospora* spp.) and one categorized as non-sporulating coccidia, and 7 helminths, one identified to order (Strongylida), and one up to superfamily (Trichostrongyloidea) and 5 genera (*Alaria* sp., *Ascaridia* spp., *Heterakis* spp., *Strongyloides* spp. and *Capillaria* spp.). *Strongyloides* spp. and *Capillaria* spp. in Psittaciformes, *Coccidia* for the Galliformes and *Heterakis* spp., *Ascaridia* spp. and *Alaria* sp., for Struthioniformes (Table 2).

Considering the positive samples for mammals, 53.5% were from Primates, 25.6% from Carnivora, 14% from Artiodactyla, and 2.3% from the other orders. There were 4 protozoans, 3 genera (*Entamoeba* spp., *Blastocystis* spp., *Eimeria* spp.) and one categorized as non-sporulating coccidia, 12 helminths, two identified to order (Strongylida and Ascaridida), one to superfamily (Trichostrongyloidea), one to family (Ancylostomatidae), 7 genera (*Haemonchus* spp., *Ostertagia* spp., *Toxascaris* sp., *Toxocara* sp., *Strongyloides* spp. *Trichuris* sp. e *Trypanoxyuris* sp.), one species (*Toxocara vitulorum*) and one unidentified. Ancylostomatidae prevailed in Carnivora, *Strongyloides* spp. and *Strongylida* in Primates, and *Haemonchus* spp. and *Strongyloides* spp. in Artiodactyla (Table 2)

Quantitatively, the parasite intensity expressed in eggs, cysts and oocysts per gram of feces (EPG, CPG and OPG) detected in the feces of reptiles from the Matinha Municipal Park is presented in Table 3. For *C. carbonaria*, Oxyuridae eggs form the most abundant, ranging from 10-1060 EPG. For the snakes *B. constrictor* and *M. reticulatus* oocysts of the coccidian *Caryospora* spp. was the most abundant parasite, ranging from 0-3500 OPG and 0-1200 EPG, respectively. In the lizard *S. merianae*, eggs of *Strongyloides* spp. were the most abundant, representing about 170 EPG (Table 3).

**Table 3:** Intensity of gastrointestinal parasites eggs/oocysts/cysts per gram (EPG/OPG/CPG) of feces detected in reptiles from zoo of Matinha Municipal Park, Itapetinga, Bahia, Brazil by mini-FLOTAC® combined with fill FLOTAC® techniques. Mean (minimum-maximum). NI: Not identified.

Parasites	Host					
	<i>C. carbonaria</i>	<i>C. denticulatus</i>	<i>B. constrictor</i>	<i>M. reticulatus</i>	<i>P. molurus</i>	<i>S. merianae</i>
<b>Protozoans</b>						
<i>Caryospora</i> spp.	0	0	1750,0 (0-3500)	600,0 (0-1200)	0	0
<i>Isospora</i> spp.	0,8 (0-10)	0	0	0	0	0
<i>Nyctotherus</i> spp.	5,4 (0-30)	0	0	0	0	0
<b>Helminths</b>						
Trematoda	11,5 (0-150)	0	0	0	0	0
<i>Angusticaecum</i> sp.	24,6 (0-90)	0	0	0	0	0
Strongylida	0,0 (0-0)	0	5,0 (0-10,0)	5,0 (0-10,0)	0	170 (170)
<i>Strongyloides</i> spp.	19,2 (0-140)	0	5,0 (0-10,0)	0	0	0
<i>Capillaria</i> sp.	0	0	0	0	0	20 (20)
Oxyuridae	88,5 (1-1060)	0	0	0	0	0
NI	0,8 (0-10)	0	0	0	0	0
Pools examined	13	3	2	2	1	1
Positive pools	7	0	2	2	0	1
(%)	53,8	0,0	100,0	100,0	0,0	100,0

Source: Authors.

The parasitic intensity expressed in eggs, cysts and oocysts per gram of feces (EPG, CPG and OPG) detected in the feces of birds from the Matinha Municipal Park is shown in Table 4. In general, coccidia were very abundant in most birds. For *S. papa*, oocysts of *Eimeria* spp. were the most abundant, ranging from 0-500 OPG. In *S. melanoleucus*, coccidiosis and *Capillaria* spp., it is abundant. In the feces of *C. plancus*, oocysts of *Isospora* spp. predominated, ranging from 0-100 OPG. In *O. guttata*, coccidian oocysts predominated, varying in density from 0-80 OPG, followed by eggs of *Trichostrongyloidea*, ranging from 0-60 EPG (Table 4). In *R. toco*, Strongylida eggs (120 EPG) and in *P. perspicillata*, eggs of *Capillaria* spp. (280 EPG) were the most representative (Table 4).

In the feces of *P. cristatus* there was an absolute predominance of protozoans, reaching the highest parasitic densities among all the birds studied, being the oocysts of *Eimeria* spp., the most abundant, ranging from 0-44,380 OPG, followed by non-sporulated coccidia with varying densities from 0-1520 OPG. The second bird species that presented the highest densities of parasites per gram of feces was *S. camelus*, being *Alaria* sp. (0-2090 EPG) and non-sporulating coccidia (0-1200 OPG) were the most abundant parasites (Table 4).

The two macaw species had the third and fourth highest densities of gastrointestinal parasites in their feces. In *A. ararauna* the eggs of *Ascaridia* spp. (0-1040 EPG) and *Heterakis* spp. (0-50 EPG) and in *A. chloropterus* the eggs of *Ascaridia* spp. (0-750 EPG) and *Capillaria* spp. (0-160 EPG) were the most abundant. The other parrot species (*A. macao*, *A. auricapillus*, *P. maximiliani* and *P. leucophthalmus*) showed low densities of parasites in their feces (Table 4).

**Table 4:** Intensity of gastrointestinal parasites eggs/oocysts/cysts per gram (EPG/OPG/CPG) of feces detected in birds from zoo of Matinha Municipal Park, Itapetinga, Bahia, Brazil by mini-FLOTAC® combined with fill FLOTAC® techniques. Mean (minimum-maximum).

Parasites	Host														
	<i>S. papa</i>	<i>S. melanoleucus</i>	<i>C. plancus</i>	<i>O. guttata</i>	<i>P. cristatus</i>	<i>R. toco</i>	<i>A. ararauna</i>	<i>A. chloropterus</i>	<i>A. macao</i>	<i>A. auricapillus</i>	<i>P. maximiliani</i>	<i>P. leucophthalmus</i>	<i>P. perspicillata</i>	<i>T. furcata</i>	<i>S. camelus</i>
<b>Protozoans</b>															
<i>Entamoeba</i> spp.	0	0	0	6,7(0-20)	30,0 (0-150)	0	0,0	0,0	0	13,3 (0-30)	0,0	0	0	0	0,0
<i>Blastocystis</i> spp.	0	0	0	0	16,0 (0-80)	0	0,0	0,0	0	0,0	0,0	0	0	0	0,0
<i>Cyclospora</i> sp.	0	0	0	0	0,0	0	0,0	2,5 (0-10)	0	0,0	0,0	0	0	0	0,0
<i>Eimeria</i> spp.	125,0 (0-500)	0	0	3,3 (0-10)	8962 (0-44380)	0	0,0	0,0	0	0,0	0,0	0	0	0	0,0
<i>Isospora</i> spp.	0	0	36,7 (0-100)	0	12,0 (0-40)	0	0,0	0,0	0	0,0	0,0	0	0	0	0,0
Non-sporulated Coccidia	0	10	16,7 (0-50)	26,7 (0-80)	504,0 (0-1520)	0	0,0	10,0 (0-40)	0	0,0	0,0	0	0	0	203,8 (0-1200)
<b>Helminths</b>															
<i>Alaria</i> sp.	0	0	0	0	0,0	0	0,0	0,0	0	0,0	0,0	0	0	0	770,0 (0-2090)
Strongylida	22,5 (0-80)	0	0	0	0,0	120	0,0	0,0	0	0,0	3,3 (0-10)	0	0	0	131,3 (0-560)
Trichostrongyloidea	0	0	0	20 (0-60)	0,0	0	2,5 (0-10)	0,0	0	0,0	0,0	0	0	0	0,0
<i>Ascaridia</i> spp.	0	0	0	0	0,0	0	302,5 (0-1040)	200,0 (0-750)	30	0,0	3,3 (0-10)	0	20	0	46,3 (0-160)
<i>Heterakis</i> spp.	0	0	0	0	0,0	0	12,5 (0-50)	0,0	0	0,0	0,0	0	0	0	0,0
<i>Strongyloides</i> spp.	7,5 (0-30)	0	0	0	0,0	70	7,5 (0-30)	2,5 (0-10)	0	0,0	0,0	0	0	0	1,3 (0-10)
<i>Capillaria</i> spp.	0	10	0	0	0,0	0	2,5 (0-10)	40,0 (0-160)	0	0,0	0,0	0	280	0	0,0
Pools examined	4	1	3	3	5	1	4	4	1	3	3	1	1	1	8
Positive pools	3	1	2	3	5	1	2	3	1	2	1	0	1	0	8
(%)	75,0	100,0	66,7	100,0	100,0	100,0	50,0	75,0	100,0	66,7	33,3	0,0	100,0	0,0	100,0

Source: Authors.

The parasitic intensity expressed in eggs, cysts and oocysts per gram of feces (EPG, CPG and OPG) detected in the feces of mammals from the Matinha Municipal Park is shown in Table 5. In Artiodactyla, *M. gouazoubira* presented eggs of *Haemonchus* spp. (0-300 EPG), *Strongyloides* spp. (0-260 EPG) and Ascaridida (0-240 EPG) as the most abundant, followed by those found for *L. glama*, predominantly *Ostertagia* spp. (220-750 EPG). In the order Carnivora, the highest densities of parasites per gram of mammalian feces were recorded. Ancylostomatidae eggs had the highest densities among all identified mammalian parasites, with those recorded for *P. concolor* (0-1350 EPG) and *P. leo* (285-1090 EPG) having the highest densities (Table 5). *P. flavus* presented the highest abundance of coccidian oocysts among all mammals, exhibiting the genus *Eimeria* spp. (360-1240 OPG) as the most abundant. However, *L. pardalis* presented the lowest density of parasite eggs, among the other Carnivora species studied, with 0-35 EPG of *Toxocara* sp. (Table 5).

Primates were the second order of mammals that had higher densities of parasites, followed by Artiodactyla. The species *Sapajus libidinosus* showed the highest parasitic intensities of the order, being non-sporulating coccidia (0-850 OPG), *Strongyloides* spp. (0-710 EPG) and Strongylida (0-280 EPG) the most abundant (Table 5). The other mammalian species analyzed showed low parasite densities, with the exception of *H. hydrochaeris* (which had 630 EPG of Trichostrongyloidea) and *T. terrestris* (which had 140 EPG of Strongylida) (Table 5).

**Table 5:** Intensity of gastrointestinal parasites eggs/oocysts/cysts per gram (EPG/OPG/CPG) of feces detected in birds from zoo of Matinha Municipal Park, Itapetinga, Bahia, Brazil by mini-FLOTAC® combined with fill FLOTAC® techniques. Mean (minimum-maximum). NI: Not identified.

Parasites	Host													
	<i>M. gouazoubira</i>	<i>L. glama</i>	<i>C. thous</i>	<i>P. flavus</i>	<i>L. pardalis</i>	<i>P. leo</i>	<i>P. concolor</i>	<i>T. terrestris</i>	<i>M. tridactyla</i>	<i>A. caraya</i>	<i>L. chrysomelas</i>	<i>S. libidinosus</i>	<i>H. hydrochaeris</i>	<i>D. azarae</i>
<b>Protozoans</b>														
<i>Entamoeba</i> spp.	0	0	0	15,0 (0-30)	0	0	10,0 (0-50)	0	0	0	0	14,4 (0-160)	0	0
<i>Blastocystis</i> spp.	0	0	0	0	0	33,3 (0-65)	0	0	0	0	0	0	0	0
<i>Eimeria</i> spp.	0	0	0	800,0 (360-1240)	0	0	0	0	0	0	0	0,4 (0-10)	0	0
Non-sporulated Coccidia	2,5 (0-10)	30,0 (0-60)	0	0	0	0	0	0	0	0	0	34,1 (0-850)	0	0
<b>Helminths</b>														
Strongylida	0	0	0	10,0 (0-20)	0	0	0	140 (140)	0	0	0	33,0 (0-280)	0	0
Ancylostomatidae	0	0	0	0	15,0 (15,0)	588,3 (285-1090)	321,0 (0-1350)	0	0	0	0	3,3 (0-50)	0	0
<i>Haemonchus</i> spp.	82,5 (0-300)	50,0 (40-60)	0	0	0	0	0	0	0	0	0	0	0	0
Trichostrongyloidea	0	0	0	0	0	0	0	0	30 (30)	0	0	0	630 (630)	0
<i>Ostertagia</i> spp.	0	470,0 (220-720)	0	0	0	0	0	0	0	0	0	0	0	0
Ascaridida	60,0 (0-240)	0	0	5,0 (0-10)	0	0	4,0 (0-20)	0	0	0	0	2,6 (0-50)	0	0
<i>Toxascaris</i> sp.	0	0	0	0	0	3,3 (0-10)	0	0	0	0	0	0	0	0
<i>Toxocara</i> spp.	0	0	0	0	17,5 (0-35)	0	0	0	0	0	0	0	0	0
<i>Toxocara vitulorum</i>	1,3 (0-5)	0	0	0	0	0	0	0	0	0	0	0	0	0
<i>Strongyloides</i> spp.	65,0 (0-260)	40 (40)	0	0	0	0	16,0 (0-50)	0	0	0	0	134,8 (0-710)	0	0
<i>Trichuris</i> sp.	0	0	0	0	0	0	10,0 (0-50)	0	0	0	0	0	0	0
<i>Trypanoxyuris</i> sp.	0	0	0	0	0	0	0	0	0	0	0	0,7 (0-10)	0	0
NI	0	0	0	0	0	0	0	0	0	3,3 (0-10)	0	0	0	0
Pools examined	4	2	6	2	2	3	5	1	1	3	1	27	1	1
Positive pools (%)	4	2	0	2	2	3	4	1	1	1	0	22	1	0
	100,0	100,0	0,0	100,0	100,0	100,0	80,0	100,0	100,0	33,3	0,0	81,5	100,0	0,0

Source: Authors.



#### 4. Discussion

Most fecal samples from animals from the zoo at Matinha Municipal Park, Itapetinga, Bahia were positive for gastrointestinal parasites. This same pattern was recorded in several studies with captive animals, whether in zoos or CETAS (Hofstatter & Guaraldo, 2015; Barbosa et al., 2019; Oliveira et al., 2020; Batista et al., 2021). Among the zoological groups evaluated, birds and mammals were more parasitized than reptiles. This same pattern was detected by other authors (Batista et al., 2021; Mewius et al., 2021).

The most abundant parasites in fecal samples of *C. carbonaria* (Oxyuridae eggs), *B. constrictor* and *M. reticulatus* snakes (*Caryospora* spp. oocysts) and *S. merianae* lizard (*Strongyloides* spp. eggs) are commonly the most representative recorded in other works (Rataj et al., 2011; Souza et al., 2014; Rom et al., 2018). According to Ruivo (2019), the presence of oxyurids is very frequent in the lumen of the large intestine of herbivorous reptiles, being considered beneficial for the host by improving the passage of food content through the intestinal tract and contributing to the regulation of the microbiota of the cecum, through ingestion of bacteria by the parasites, however it can cause intestinal obstructions (Troiano, 2018). Infections caused by *Strongyloides* spp. in reptiles they can trigger asymptomatic conditions or anorexia, weight loss, lethargy, enteritis, diarrhea, urethral obstructions, nephritis, which can lead to their death (Ruivo, 2019). The genus *Caryospora* is found in the intestinal mucosa of snakes, lizards and turtles and its infection is usually asymptomatic (Schneller & Pantchev, 2008), but can cause destruction of the intestinal, biliary and renal epithelium with fibrosis and ulcerations (Troiano, 2018).

In most birds, coccidia were very abundant, and this pattern is commonly recorded in other studies (Hofstatter & Guaraldo, 2015; Lima et al., 2017; Oliveira et al., 2020). Coccidiosis is rare in free-ranging birds and is usually related to captive breeding, crowding or stress, where infected birds usually do not show any clinical signs in low-intensity infections, as coccidia destroy a limited number of epithelial cells, which can be replaced quickly. However, at high parasite densities, many cells are destroyed, leading to reduced food and water consumption, decreased intestinal absorption, hemorrhage, lack of appetite, weight loss, fall, loss of coordination, ruffled feathers and decreased egg production (Atkinson et al., 2008).

The parasitic intensity of coccidia recorded in fecal samples of *P. cristatus* was the highest when compared to all species of animals sampled in this work. Peacocks commonly have high densities of coccidia, as indicated by several studies in the literature (Rodrigues et al., 2020; Lozano et al., 2021; Yadav et al., 2021). Coccidia are spread by water and food contaminated by oocysts, affecting several species of birds and even mammals, such as man, and may be a zoonosis. Infections caused by coccidia can trigger severe damage to birds, promoting diarrhea, dehydration, apathy, reduced reproductive rate, weight loss and death (Marietto-Gonçalves et al., 2009). These results point to the need for the periodic use of anti-coccidial agents and the intensification of cleaning and disinfection of the enclosures, drinkers and feeders, in order to prevent the spread of this parasite to the zoo animals.

Samples of *S. camelus*, exhibited high densities of *Alaria* sp. and non-sporulating coccidia. *Alaria* sp. are trematode parasites that can cause asymptomatic conditions up to diarrhea and hematochezia (Batista et al., 2008). Its presence has already been recorded in several carnivores (canids, felids, mustelids and procyonids) (Ruas, 2005) and even birds, including *S. camelus* (Batista et al., 2008). Even when in large numbers, the presence of parasites in these birds may not be accompanied by characteristic clinical signs (Batista et al., 2008).

The most abundant gastrointestinal parasites in fecal samples of *A. ararauna* and *A. chloropterus* (*Ascaridia* spp., *Heterakis* spp. and *Capillaria* spp.) are often abundant helminths for birds in other studies (Hofstatter & Guaraldo, 2015; Santos et al., 2015; Oliveira et al., 2020). Infections caused by these parasites are frequent in birds, and usually present with the following clinical signs: weight loss, anorexia, anemia, gastroenteritis, depression and weakened immune system (Atinkson et al., 2008; Marietto-Gonçalves et al., 2009; Monteiro, 2018), which may compromise their survival.

The abundant parasites in the feces of *M. gouazoubira*, *Haemonchus* spp, *Strongyloides* spp. and Ascaridida were also reported by Lux Hoppe et al. (2010). These helminths can cause diarrhea, anemia, bristly hair, weight loss, nodular lesions and ulcerations in the mucosa of the gastrointestinal tract, with severe gastritis or catarrhal enteritis, associated with atrophy of the intestinal villi (Taylor et al., 2020). For Martins et al. (2018) several species of helminths can affect domestic and wild ruminants, thus showing the possibility of transmission between different animals.

In *L. glama*, *Ostertagia* spp. was the most abundant parasite. Richard & Bishop (1991) also recorded this parasite in pacific llamas and Gonzalez-Rivas et al. (2019) for llamas occurring in Argentina. Ostertagiosis usually presents with profuse watery diarrhea, anorexia, thirst, greenish stools, and weight loss (Taylor et al., 2020).

The animals of the Carnivora order studied exhibited the highest densities of parasites among all the mammals studied, with Ancylostomatidae being the most abundant for *P. concolor* and *P. leo*. This parasite was recorded by other studies that evaluated felid parasites (Srbek-Araujo et al., 2014; Gressler et al., 2016; Solórzano-García et al., 2017; Silva et al., 2021). The main adverse effects of hookworms for their hosts (humans, domestic animals and wild species) are anemia, growth retardation, secondary bacterial infections and mortality (Seguel & Gottdenker, 2017).

*P. flavus* showed the highest abundance of *Eimeria* spp. In the literature, the few studies on parasites with this mammal species generally report the presence of helminths (Taira et al., 2013; Tokiwa et al., 2014). Barbosa et al. (2019) found non-sporulating coccidian oocysts for the *P. flavus* sample from the Rio de Janeiro Zoo, being the record of *Eimeria* spp. of the present article the first record of this coccidian genus for Jupará.

*Sapajus libidinosus* exhibited the highest densities of non-sporulating coccidia, *Strongyloides* spp. and *Strongylide*. Alcantara et al., (2016) found *Strongyloides* sp. and *Ancylostoma* sp. as the most prevalent parasites for *S. libidinosus*. Souza et al. (2015) report *Strongyloides* spp. and *Strongylida* in *S. libidinosus* feces in Pernambuco and Santana et al. (2020) found *Strongyloides* spp., *Ancylostoma* sp. and *Enterobius* sp. as the most abundant parasites for 34 specimens of *Sapajus* sp (*S. libidinosus*, *S. xanthosternos* and hybrids) in Bahia. According to Santana et al. (2020), praziquantel is an effective drug for the control of parasitic infections by the aforementioned parasites, however environmental factors, such as access to other animals and the floor of the enclosures, can interfere with the maintenance of the health of these animals, thus reducing the interval of application of drug doses.

The parasite recorded in the *H. hydrochaeris* sample (Trichostrongyloidea) was also recorded in another study carried out with capybara populations in seven cities in the state of São Paulo (Souza et al., 2021). According to Souza et al., (2021), identification at the genus or species level based only on Trichostrongyloidea eggs is impossible, however, necropsy-based studies point to the parasites *Viannella hydrochoeri* and *Hydrochoerisnema anomalobursata* as the specific trichostrongyloids of capybaras, with *V. hydrochoeri* the most likely parasite that affects capybaras in natural and man-made areas.

In the sample of *T. terrestris*, there was a record of 140 EPG of Strongylida, the only parasite found for this mammal. These results differ from other analyzes carried out with this species, where Batista et al (2021) found only protozoans in the tapir samples, with a predominance of trophozoites and cysts of *Balantidium* sp., and non-sporulated oocysts of coccidia.

For Batista et al. (2021), the physical proximity of animals in zoos makes parasitic infections inevitable, which can be aggravated by the immune status of the host, whose circumstances of confinement and stress weaken the animal, thus aggravating its survival. Furthermore, some of these parasites can be zoonotic, impacting the health of zookeepers and workers (Iatta et al., 2020). Redoubled care with the hygiene and deworming of the animals are necessary in order to prevent the transmission of the parasites within the studied zoo.

The increase in the breeding stock promoted by the acquisition of new specimens and species at the zoo, may have contributed to the increase in the parasitic community, since some specimens obtained from other zoos, breeding sites and/or

sorting centers were parasitized and the lack of establishment of an effective deworming and quarantine protocol can lead to contamination of individuals residing in the zoo.

Oliveira et al. (2022) carried out a physical-chemical and microbiological evaluation of the water used by the animals of the zoo in the Matinha Municipal Park, being suitable for the watering of animals, but they recorded nonconformities in the microbiological parameters (*Escherichia coli* presence) for most of the animals' enclosures. These data indicate fecal contamination in the water of the zoo's enclosures. Therefore, we can infer that there is probably parasitic contamination in the water used for drinking, which may serve as a means of dissemination among the species that live in each enclosure.

## 5. Conclusion

Fecal samples from animals present at the zoo at Matinha Municipal Park, Itapetinga, Bahia, Brazil revealed the presence of gastrointestinal parasites in 70.97% of the samples. 27 taxa of gastrointestinal parasites, being 8 protozoans and 19 helminths were identified, with a predominance of coccidia, Oxyuridae and *Angusticaecum* sp. for reptiles; coccidia, *Ascaridia* spp., *Heterakis* spp. and *Strongyloides* spp. for birds; and coccidia, Ancylostomatidae, Strongylida and *Strongyloides* spp. for mammals. In summary, the results presented reveal the importance of periodically carrying out copro-parasitological examinations in zoos, in order to support interventions by the technical team to promote the health and well-being of animals. It is worth mentioning that new specimens must undergo a period in quarantine, before relocating them in the enclosures, and the performance of these exams, once again, become essential for clinical diagnosis and establishment of appropriate therapeutic conduct for each case, with administration of specific antiparasitic drug for each type of parasite, whether they are protozoans or helminths. Therefore, it is evident that routine copro-parasitological assessment of captive animals in zoos effectively contributes to diagnosis and improvements in park management. This work constitutes the first publication on the coproparasitological evaluation of animals from a zoo in the Bahia state.

## Acknowledgments

We thank the keepers and employees of the Matinha Municipal Park for their help in the collections.

## References

- Alcântara, D. S., Mendonça, I. L., Fernandes Neto, V. P., Carniel, P. G., & Pessoa, F. B. (2016). Estudo coproparasitológico da espécie *Cebus libidinosus* (macaco-prego). *Arquivo Brasileiro de Medicina Veterinária e Zootecnia*, 68, 1609-1612.
- Atkinson, C.T.; Thomas, N.J. & Hunter, B.D. (2008). *Parasitic diseases of wild birds*. Blackwell Publishing.
- Barbosa, A.S., Pinheiro, J.L., Santos, C. R., Lima, C.S.C.C., Dib, L.V., Echarte, G.V., Augusto, A.M., Bastos, A.C.M.P., Uchôa, C.M.A., Bastos, O.M.P., Santos, F. N., Fonseca, A.B.M., & Amendoeira, M.R.R. (2019). Gastrointestinal Parasites in Captive Animals at the Rio de Janeiro Zoo. *Acta Parasitologica*, 65, 237-249. <https://doi.org/10.2478/s11686-019-00145-6>
- Barros, L. A.; Sant, L. X. & Magalhães, B. S. N.(2017). Prevalência de parasitos gastrointestinais em mamíferos selvagens do Jardim Zoológico do Rio de Janeiro *Revista Brasileira de Ciências Veterinária*. 24(4), 179-183. <http://dx.doi.org/10.4322/rbcv.2017.034>
- Batista, A. I. V.; Lucena, G. V. C. de.; Nery, T. F. L.; Batista, C. C. N.; Batista, J. S.; Winkeler, I. E.; Rolim, C. M. de M.; Coelho, W. A. C.; Rocha, E. L. B.; Lima, V. F. S. & Pereira, J. S. (2021). Gastrointestinal parasites in wild and exotic animals from a Zoobotanical Park in Northeast of Brazil. *Research, Society and Development*, 10(13), e486101321255. <https://doi.org/10.33448/rsd-v10i13.21255>.
- Batista, A.M.B., Pereira, M.A.V.C. & Vita, G.F. (2008). Parasitismo intestinal em avestruzes (*Struthio camelus australis* Linnaeus, 1786) da Região Sul do Estado do Espírito Santo, no ano de 2006. *Revista Portuguesa de Ciências Veterinárias*. 103 (567-568), 189-193.
- Bowman, D.D., Lynn, R.C., Eberhard, M.L., & Alcaraz, A. (2010). *Parastologia Veterinária de Georgis*. Tradução de 9ª edição (2008). Elsevier.
- Brandão, M. L. (2007). *Helminths de mamíferos da região do Parque Nacional da Capivara, sudeste do Piauí: diversidade e influências antrópicas*. Dissertação (Mestrado em Saúde Pública) - Escola Nacional de Saúde Pública Sergio Arouca, Fundação Oswaldo Cruz.
- Brasil. (2015). *Instrução normativa IBAMA nº 07, de 30 de abril de 2015*. Institui e normatiza as categorias de uso e manejo da fauna silvestre em cativeiro, e define, no âmbito do IBAMA, os procedimentos autorizativos para as categorias estabelecidas. Diário Oficial da República Federativa do Brasil, Poder Executivo.

- Capasso, M., Maurelli, M. P., Ianniello, D., Alves, L. C., Amadesi, A., Laricchiuta, P., Silvestre, P., Campolo, M., Cringoli, G., & Rinaldi, L. (2019). Use of Mini-FLOTAC and Fill-FLOTAC for rapidly diagnosing parasitic infections in zoo mammals. *Revista brasileira de parasitologia veterinária = Brazilian journal of veterinary parasitology: Orgao Oficial do Colegio Brasileiro de Parasitologia Veterinaria*, 28(1), 168–171. <https://doi.org/10.1590/S1984-296120180087>
- Carvalho, T.J.F. (2018). *Parasitas gastrointestinais em répteis de uma coleção comercial*. Dissertação de mestrado. Universidade de Lisboa, Faculdade de Medicina Veterinária, Lisboa.
- Cesario, C.S. (2021) Aspectos parasitológicos e sanitários de tamanduás-bandeira (*Myrmecophaga tridactyla*) de vida livre. Tese de doutorado. Universidade Estadual Paulista, Instituto de Biociências, Letras e Ciências Exatas.
- Cringoli, G., Maurelli, M. P., Levecke, B., Bosco, A., Vercruyse, J., Utzinger, J., & Rinaldi, L. (2017). The Mini-FLOTAC technique for the diagnosis of helminth and protozoan infections in humans and animals. *Nature protocols*, 12(9), 1723-1732.
- Dalfovo, M. S., Lana, R. A., & Silveira, A. (2008). Métodos quantitativos e qualitativos: um resgate teórico. *Revista Interdisciplinar Científica Aplicada*, 2(4), 01-13.
- Fagiolini, M., Lia, R. P., Laricchiuta, P., Cavicchio, P., Mannella, R., Cafarchia, C., & Perrucci, S. (2010). Gastrointestinal parasites in mammals of two Italian zoological gardens. *Journal of Zoo and Wildlife Medicine*, 41(4), 662-670
- Freitas, M. S., Silva, S. L., Costa, E. N. & Lessa, A. O. (2007). O Parque Municipal da Matinha como instrumento de sensibilização ambiental. *Revista Eletrônica do Mestrado em Educação Ambiental*, 19(1): 235-245.
- González-Rivas, C.J., Borghi, C.E., De Lamo, D.A. (2019). Endoparasitos en guanaco (*Lama guanicoe*). Revisión de situación en Argentina y registros de la provincia de San Juan. *Revista de Investigaciones Veterinarias del Peru*, 30(1), 339-349.
- Gressler, L. T.; Noll, J.C.G.; Freitas, I.B. & Monteiro, S.G. (2016). Multiparasitism in a wild cat (*Leopardus colocolo*) (Carnivora: Felidae) in southern Brazil. *Rev Bras Parasitol Vet*. 25(3): 374-377. <https://doi.org/10.1590/S1984-29612016047>.
- Guo, Y.; Li, N.; Fenga, Y, et al. (2021). Zoonotic parasites in farmed exotic animals in China: Implications to public health. *International Journal for Parasitology: Parasites and Wildlife*. 14: 241-247. <https://doi.org/10.1016/j.ijppaw.2021.02.016>.
- Hofstatter, P.G. & Guaraldo, A.M.A. (2015). Levantamento parasitológico em aves de alguns zoológicos brasileiros. *Revista Brasileira de Parasitologia Veterinária*. 24 (1), 87-91. <https://doi.org/10.1590/S1984-29612015005>.
- Iatta, R; Natale, A; Ravagnan, S. et al. (2020). Zoonotic and vector-borne pathogens in tigers from a wildlife safari park, Italy. *International Journal for Parasitology: Parasites and Wildlife*. 12 (1-7). <https://doi.org/10.1016/j.ijppaw.2020.03.006>.
- Itapetinga (2004). *Projeto de Lei de agosto de 2004*. Dispõe sobre o Parque Municipal da Matinha. Câmara Municipal de Itapetinga.
- Kulka, D. D. (2014). *Conforto térmico em áreas verdes urbanas no município de Itapetinga, BA*. UESB, Itapetinga.
- Lima, V. F., Bezerra, T. L., Andrade, A. F., Ramos, R. A., Faustino, M. A., Alves, L. C., & Meira-Santos, P. O. (2017). Gastrointestinal parasites of exotic birds living in captivity in the state of Sergipe, Northeastern Brazil. *Revista brasileira de parasitologia veterinária = Brazilian journal of veterinary parasitology : Orgao Oficial do Colegio Brasileiro de Parasitologia Veterinaria*, 26(1), 96–99. <https://doi.org/10.1590/S1984-29612016080>
- Lima, V. F. S. (2018). Agentes parasitários em animais silvestres, sinantrópicos e domésticos: aspectos clínicos, epidemiológicos e de saúde pública. Tese (Programa de Pós-Graduação em Ciência Animal Tropical) - Universidade Federal Rural de Pernambuco.
- Lozano, J., Almeida, C., Victório, A. C., Melo, P., Rodrigues, J. P., Rinaldi, L., Cringoli, G., Gomes, L., Oliveira, M., Paz-Silva, A., & Madeira de Carvalho, L. (2021). Implementation of Mini-FLOTAC in Routine Diagnosis of Coccidia and Helminth Infections in Domestic and Exotic Birds. *Veterinary sciences*, 8(8), 160. <https://doi.org/10.3390/vetsci8080160>
- Lux Hoppe, E.G., Tebaldi, J.H., & Nascimento, A.A. (2010). Helminthological screening of free-ranging grey brocket deer *Mazama gouazoubira* Fischer, 1817 (Cervidae: Odocoileini) from Brazilian Pantanal wetlands, with considerations on *Pygarginema verrucosa* (Molin, 1860) Kadenatzii, 1948 (Spirocercidae: Ascarosinae). *Brazilian journal of biology = Revista brasleira de biologia*, 70 2, 417-23.
- Marietto-Gonçalves, G.A., Martins, T.F., Lima, E.T., Lopes, R.S., Andreatti-Filho, R.L. (2009). Prevalence of endoparasites in fecal samples of exotic and wild birds examined in the Laboratory of Ornitopatologia and Laboratory of Parasitics Diseases of the FMVZ-UNESP/Botucatu, SP. *Ciencia Animal Brasileira*. 10(1): 349-354.
- Martins, N. E. X., Ribeiro, A. P. C., Trindade, H. I., Silva, M. A. G. & Almeida, K.S. (2018). Helminthos de veados-mateiros (*Mazama americana*) e suas implicações a criação de ruminantes domésticos: revisão de literatura. *Revista científica eletrônica de medicina veterinária*, 10, 1-14.
- Melo, Y.J.O., Ferraz, H.T., Saturino, K.C., Silva, T.D.P., Braga, I.A., Meirelles-Bartoli, R.B., & Ramos, D.G.S. (2021). Gastrointestinal parasites in captive and free-living wild birds in Goiania Zoo. *Brazilian Journal of Biology*. 82, 1-8. <https://doi.org/10.1590/1519-6984.240386>
- Mewius, A., Lusa, E.R., Pertille, J.G., Dos Reis, T.D., Pletsch, J.A., & França, R.T. (2021). Endoparasites in group of wild animals raised in captivity. *Pesquisa Veterinaria Brasileira*. 41, 1-7. <https://doi.org/10.1590/1678-5150-PVB-6758>
- Monteiro, S.G. (2018). *Parasitologia na Medicina Veterinária*. Roca.
- Müller, G.C., Greinert, J.A., & Filho, H.G. (2005). Frequência de parasitas intestinais em felinos mantidos em zoológicos. *Arquivo Brasileiro De Medicina Veterinaria E Zootecnia*, 57, 559-561.

- Oliveira, M. S. ., Fraga, R. E. ., Aguiar, C. dos S., Brandão, D. A. ., Oliveira, D. F. de, Santos, F. V. ., Queiroz, T. S. de ., Tomazi, L. ., Rocha, M. A. ., & Silva, M. B. da . (2022). Evaluation of the physicochemical and microbiological quality of the water used by the animals in the Parque Municipal da Matinha, Itapetinga, Bahia, Brazil . *Research, Society and Development*, 11(3), e11911326481. <https://doi.org/10.33448/rsd-v11i3.26481>
- Oliveira, v. J., Teixeira, R. E. R., Santana, I. S. F., Santos, C. M. R., Macedo, E. C., Silva, M. B. & Fraga, R. E. (2020). Avaliação de parasitas gastrointestinais da avifauna silvestre mantidas em cativeiro. In: Melchior, L.A.K., Malavazi, P.F.N.S., Camargo, L.M.A., Oliveira, J. & Meneguetti, D.U.O. (Org.). *Atualidades em Medicina Tropical no Brasil: Veterinária. Stricto Sensu Editora*, 1, 274-288.
- Orsini, H., & Bondan, E. F. (2006). Fisiopatologia do estresse em animais selvagens em cativeiro e suas implicações no comportamento e bem-estar animal—revisão da literatura. *Rev Inst Ciênc Saúde*, 24(1), 7-13.
- Pereira, A. S., Shitsuka, D. M., Parreira, F. J., & Shitsuka R. (2018). *Metodologia da pesquisa científica*. Núcleo de Tecnologia Educacional da Universidade Federal de Santa Maria. <https://repositorio.ufsm.br/handle/1/15824>
- Rataj, A. V., Lindtner-Knific, R., Vlahović, K., Mavri, U., & Dovč, A. (2011). Parasites in pet reptiles. *Acta veterinaria Scandinavica*, 53(1), 33. <https://doi.org/10.1186/1751-0147-53-33>
- Rickard, L.G., & Bishop, J.K. (1991). Helminth parasites of llamas (*Lama glama*) in the Pacific Northwest. *Journal of the Helminthological Society of Washington*, 58, 110-115.
- Rodrigues, B., Salgado, P., Gonzalez, I., Quadrini, A., Holcman, M. M., Ramos, P. L., & Chagas, C. (2020). Comparative analyses of coproscopical techniques to diagnose enteroparasites in a group of captive Indian peafowl (*Pavo cristatus*). *Annals of parasitology*, 66(3), 397–406. <https://doi.org/10.17420/ap6603.279>
- Rom, B., Kornaš, S., & Basiaga, M. (2018). Endoparasites of pet reptiles based on coprosopic methods. *Annals of parasitology*, 64(2), 115–120. <https://doi.org/10.17420/ap6402.142>
- Ruas, J.L. (2005) *Caracterização da fauna parasitária do Pseudalopex gymnocercus (Graxaim-do-campo) e do Cerdocyon thous (graxaim-do-mato) na região do Rio Grande do Sul*. Universidade Federal do Rio Grande do Sul (Tese).
- Ruivo, M.G.V.V. (2019). *Parasitas gastrointestinais em répteis de estimação em Barcelona*. Universidade de Lisboa (Dissertação).
- Santana, I. S. F., Silva, M. B., Rodrigues, T.C., Silva, M.S., Rego, C. O., Tomazi, L., Fraga, R. E. Tratamento De Endoparasitas Em Primatas Mantidos Em Cativeiros. In: Melchior, L.A.K., Malavazi, P.F.N.S., Camargo, L.M.A., Oliveira, J. & Meneguetti, D.U.O. (Org.). *Atualidades em Medicina Tropical no Brasil: Veterinária. Stricto Sensu Editora*, 1, 258-273.
- Santos, P.M.S., Silva, S.G.N., Fonseca, C.F., & Oliveira, J.B. (2015). Parasites of birds and mammals in captivity in Pernambuco state, Brazil. *Pesquisa Veterinaria Brasileira*. 35(9), 788-794. <https://doi.org/10.1590/S0100-736X2015000900004>
- Santos, I. G.; Batista, A. I. V.; Silva, W. S. I.; Oliveira Neto, M. B.; Schettino, S. C.; Oliveira, M. R.; Ramos, R. A. N.; Alves, L. C.; Bezerra-Santos, M. & Lima, V. F. S. (2022). Gastrointestinal parasites in captive wild animals from two Brazilian Zoological Gardens. *Research, Society and Development*, 11(4), e28411426637. <https://doi.org/10.33448/rsd-v11i4.26637>
- Schneller, P. & Pantchev, N. (2008). *Parasitology in Snakes, Lizards and Chelonians: A Husbandry Guide*. Frankfurt am Main: Edition Chimaira
- Seguel, M., & Gottdenker, N. (2017). The diversity and impact of hookworm infections in wildlife. *International journal for parasitology. Parasites and wildlife*, 6(3), 177–194. <https://doi.org/10.1016/j.ijppaw.2017.03.007>
- Silva, A. C. S. et al. (2021). Parasitas em felinos selvagens mortos em estradas do norte do estado do Paraná, Brasil. *Revista Brasileira de Parasitologia Veterinária*. 30(1), e016320. <https://doi.org/10.1590/S1984-296120201090>.
- Silva, N.C., N., Fruhvald, E. & Marinho-Neto, F.A. (2019). Estresse em animais de zoológico. *Revista científica eletrônica de ciências aplicadas da fait*, VII, 13(1), 1-25.
- Snak, A., Agostini, K.M., Lenzi, P., Montanucci, C.R., Delgado, L.E., & Zabott, M.V. (2017). Perfil parasitológico de mamíferos silvestres cativos. *Veterinaria e Zootecnia*. 24(1): 193-200.
- Solórzano-García, Brenda, White-Day, Jennifer Mae, Gómez-Contreras, Magaly, Cristóbal-Azkárate, Jurgi, Osorio-Sarabia, David, & Rodríguez-Luna, Ernesto. (2017). Coprological survey of parasites of free-ranging jaguar (*Panthera onca*) and puma (*Puma concolor*) inhabiting 2 types of tropical forests in Mexico. *Revista mexicana de biodiversidad*, 88(1), 146-153. <https://doi.org/10.1016/j.rmb.2017.01.011>
- Souza, J.L., Barbosa, A.D., Vazon, A.P., Uchôa, C.M., Nunes, B.C., Cortez, M.B., Silva, V.L., Más, L.B., Melgarejo, A.R., & Bastos, O.M. (2014). Parasitological and immunological diagnoses from feces of captive-bred snakes at Vital Brazil Institute. *Revista brasileira de parasitologia veterinaria = Brazilian journal of veterinary parasitology : Orgao Oficial do Colegio Brasileiro de Parasitologia Veterinaria*, 23 2, 123-8 .Souza et al., 2014;
- Souza, S., Benatti, H. R., Luz, H. R., Costa, F. B., Pacheco, R. C., & Labruna, M. B. (2021). Endoparasites of capybaras (*Hydrochoerus hydrochaeris*) from anthropized and natural areas of Brazil. *Revista brasileira de parasitologia veterinaria = Brazilian journal of veterinary parasitology : Orgao Oficial do Colegio Brasileiro de Parasitologia Veterinaria*, 30(2), e027420. <https://doi.org/10.1590/S1984-29612021049>
- Srbek-Araujo, A.C., Santos, J.C., Almeida, V.M., Guimarães, M.P., & Chiarello, A.G. (2014). First record of intestinal parasites in a wild population of jaguar in the Brazilian Atlantic Forest. *Revista brasileira de parasitologia veterinaria = Brazilian journal of veterinary parasitology : Orgao Oficial do Colegio Brasileiro de Parasitologia Veterinaria*, 23 3, 393-8 .
- Taira, K., Une, Y., Šnábel, V., & Sugiyama, H. (2013). Baylisascaris sp. infection in a pet kinkajou *Potos flavus*. *Helminthologia*, 50, 238-243.
- Taylor, M.A.; Coop, R.L. & Wall, R.L. (2020). *Parasitologia Veterinária*. Guanabara Koogan.

Tokiwa, T., Nakamura, S., Taira, K., & Une, Y. (2014). *Baylisascaris potosis* n. sp., a new ascarid nematode isolated from captive kinkajou, *Potos flavus*, from the Cooperative Republic of Guyana. *Parasitology international*, 63 4, 591-6.

Troiano, J.C. (2018). *Doenças dos répteis*. MedVet.

Yadav, S.K., Sarkar, S., Sarkar, S., & Siddiki, A.Z. (2021). Prevalence of Endoparasites and Ectoparasites of Captive Peafowl Farm. *Advances in Animal and Veterinary Sciences*.9(3), 442-445.

Zago, G. (2018). *Fatores que afetam as enteroparasitoses em macacos-prego (Sapajus libidinosus) do ecótono Cerrado/Caatinga*. Tese de Doutorado. Instituto de Psicologia – Universidade de São Paulo.