

## Gingival epithesis: a simple technique with great results

Epítese gengival: uma técnica simples com grandes resultados

Epítisis gingival: una técnica sencilla con grandes resultados

Received: 09/10/2022 | Revised: 09/22/2022 | Accepted: 09/23/2022 | Published: 09/30/2022

### **Maria Cláudia Cardoso de Brito**

ORCID: <https://orcid.org/0000-0002-8806-5727>  
Centro Universitário Newton Paiva, Brazil  
E-mail: [britomariaclaudia@yahoo.com.br](mailto:britomariaclaudia@yahoo.com.br)

### **Diana Ankli**

ORCID: <https://orcid.org/0000-0001-8747-6463>  
Private practice, Brazil  
E-mail: [dianaankli@hotmail.com](mailto:dianaankli@hotmail.com)

### **Mariela Dutra Gontijo de Moura**

ORCID: <https://orcid.org/0000-0003-3576-3457>  
UNINCOR, Brazil  
E-mail: [dra.mariela@hotmail.com](mailto:dra.mariela@hotmail.com)

### **Polianne Alves Mendes**

ORCID: <https://orcid.org/0000-0001-6084-7017>  
Pontifícia Universidade Católica de Minas Gerais, Brazil  
E-mail: [polianne.am@gmail.com](mailto:polianne.am@gmail.com)

### **Frederico Santos Lages**

ORCID: <https://orcid.org/0000-0002-8885-1138>  
Universidade Federal de Minas Gerais, Brazil  
E-mail: [fredlages@hotmail.com](mailto:fredlages@hotmail.com)

### **Maria Ilma de Souza Côrtes**

ORCID: <https://orcid.org/0000-0002-9140-8495>  
Pontifícia Universidade Católica de Minas Gerais, Brazil  
E-mail: [mariailmac@gmail.com](mailto:mariailmac@gmail.com)

### **Abstract**

*Objective:* to describe the technique of making an epithesis in acrylic, to restore aesthetics and self-esteem of patients with periodontal tissue loss, in a simple and fast way. *Methodology:* A case report. Perform an impression with alginate, make an individual tray and obtain the working model. Performing the diagnostic wax-up, acrylization and intra oral installation. *Results:* The treatment, little known by clinicians, restored the patient's smile and self-esteem safely and quickly. *Conclusion:* The gingival epithesis in heat-curable acrylic offers a quick, accurate, non-invasive and simple technique that allows the patient to be rehabilitated with esthetics, comfort, good adaptation and low cost.

**Keywords:** Periodontal prosthesis; Dental prosthesis; Dental implants; Dental prosthesis design.

### **Resumo**

*Objetivo:* descrever a técnica de confecção de epítese em acrílico, para restaurar estética e autoestima de pacientes com perda de tecido periodontal, de forma simples e rápida. *Metodologia:* It is a description of the technique. It starts with an alginate impression, to obtain an individual tray and carry out a new impression for the working model. In this, the laboratory will carry out the diagnostic wax-up and subsequent acrylization, so that the intra-oral installation can be carried out. *Resultados:* O tratamento, pouco conhecido pelos clínicos, restaurou o sorriso e a autoestima do paciente com segurança e rapidez. *Conclusão:* A epítese gengival em acrílico termopolimerizável oferece uma técnica rápida, precisa, não invasiva e simples que permite reabilitar o paciente com estética, conforto, boa adaptação e baixo custo.

**Palavras-chave:** Prótese periodontal; Prótese dentária; Implantes dentários; Planejamento de prótese dentária.

### **Resumen**

*Objetivo:* describir la técnica de realización de una epítisis acrílica, para restaurar la estética y autoestima de pacientes con pérdida de tejido periodontal, de una forma sencilla y rápida. *Metodología:* Es una descripción de la técnica. Se comienza con una impresión de alginato, para obtener una cubeta individual y realizar una nueva impresión para el modelo de trabajo. En este, el laboratorio realizará el encerado diagnóstico y posterior acrilización, para poder realizar la instalación intraoral. *Resultados:* El tratamiento, poco conocido por los clínicos, restableció la sonrisa y la autoestima del paciente de forma segura y rápida. *Conclusión:* La epítisis gingival en acrílico termopolimerizable ofrece una técnica rápida, precisa, no invasiva y sencilla que permite rehabilitar al paciente con estética, comodidad, buena adaptación y bajo costo.

**Palabras clave:** Prótesis periodontal; Prótesis dental; Implantes dentales; Planificación de prótesis dentales.

## 1. Introduction

Epithesis is a type of prosthesis that rests only on the periphery of the defect, must contact all of his edges and this term is used more in maxillofacial prosthesis (D'Angelo, 2017; Federspil, 2010; Szmidt et al., 2019), being the gingival, auricular and bone-anchored the most used for craniofacial reconstruction (Cunliffe & Pretty, 2009; Desai et al., 2012) . However, several authors also call epithesis a removable acrylic gingival prosthesis that can recover aesthetic and phonetic functions, support of the lip, closing interdental cervical spaces and allowing proper hygiene procedures in the prosthesis and implants (Carreiro et al., 2008; Jawale et al., 2014; Rabaiolli et al., 2013). Other nomenclatures also used for this type of prosthesis are gingival mask, gingival veneer or gingival prosthesis (Rabaiolli et al., 2013).

In the anterior region, the two fundamental components that determine aesthetics are the gingival tissue and the teeth. Any change in this complex can cause unpleasant effects. The loss of gingival tissue visually increases the size of the tooth and creates black spaces between the roots, causing food impaction, visual and phonetic problems, due also to the passage of air between the teeth, which cause the emission of droplets of saliva during speech (Singh et al., 2013). The anterior implants rehabilitation is even more critical and difficult in relation to these aspects, due to the alveolar ridge resorption and gingival loss following tooth extraction (Rupawat et al., 2020).

Thus, for all these patients who, due to periodontal disease, extractions or other factors present large gingival losses, surgical treatment can be difficult to resolve, while the epithesis presents itself as a simple, inexpensive and predictable option (Burhan et al., 2015; Gopakumar & Sood, 2012). The purpose of the present article was to describe the technique of making an epithesis in acrylic. This technique is not popular among dentists, despite having a relatively simple execution and excellent aesthetic results.

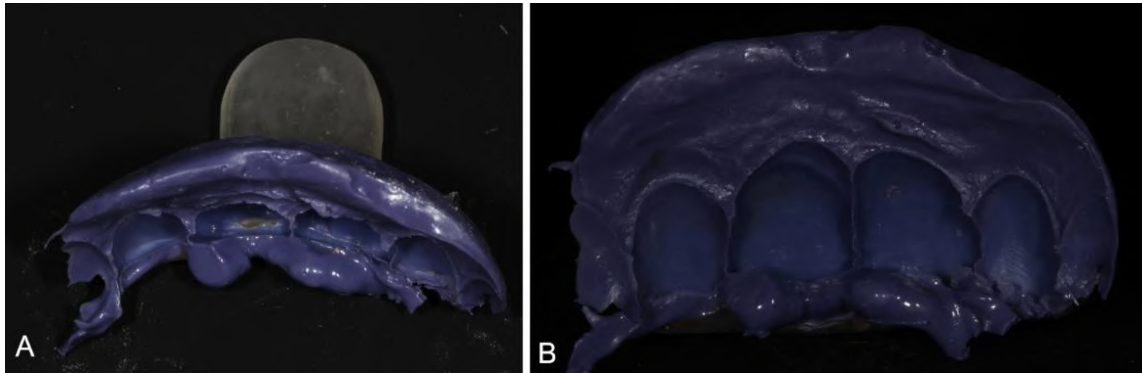
## 2. Methodology

This study is a technical note based on a case report, which was documented and presented according to the study methodology by (Estrela, 2018). In addition he was conducted in accordance with Declaration of Helsinki of 1975, revised in 2013. The patient signed the free and informed assent form and due to age, the free and informed consent form signed by the parents was also obtained. In accordance with CNS Resolution No. 510 of 2016, Art. 1, sole paragraph, "The CEP/CONEP system will not be registered or evaluated: VII - research aimed at theoretical deepening of situations that emerge spontaneously and contingently in professional practice, provided they do not reveal data that can identify the subject". Thus, submission for evaluation by the Research Ethics Committee was not necessary.

## 3. Technique

1 - Perform an impression with alginate and stock tray, to obtain a study model on which an individual tray will be made.

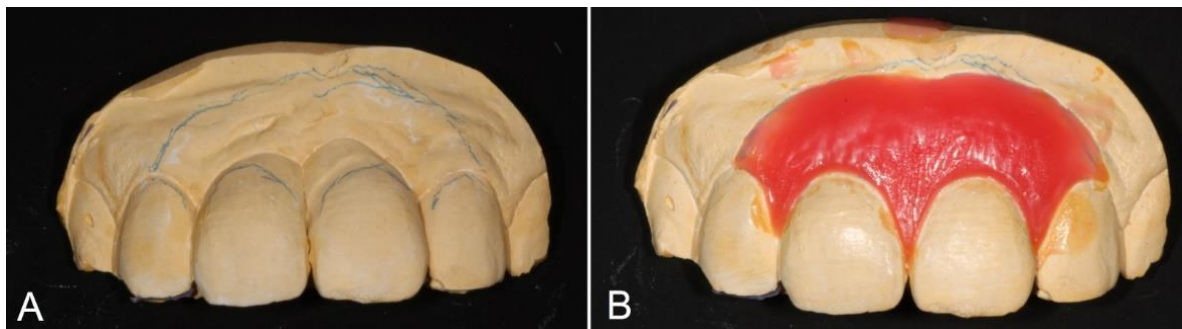
**Figure 1** - Mold made with individual tray.



Source: Authors.

2 - With the individual tray, a working molding is performed using polyether (Figure 1), which was chosen because it is a hydrophilic material, recommended for highly complex procedures, as it has excellent dimensional stability and high rigidity. Different from conventional molding, in which the tray is inserted vertically, for epithesis the tray is inserted horizontally, as we need to have a perfect reproduction of the dental embrasures. Type IV gypsum is used to obtain the working model.

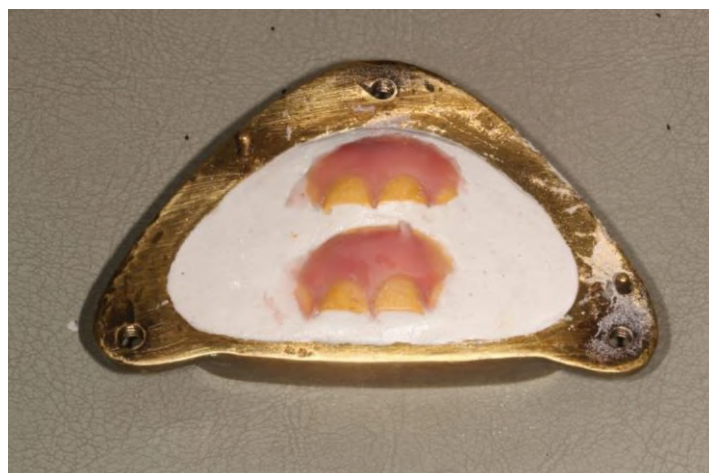**Figure 2** - Working model. A, delimitation of the area where the prosthesis will be made. B, epithesis wax-up.



Source: Authors.

3 - This model is delimited with a pencil and isolated, performing the diagnostic wax-up for the wax test (Figure 2).

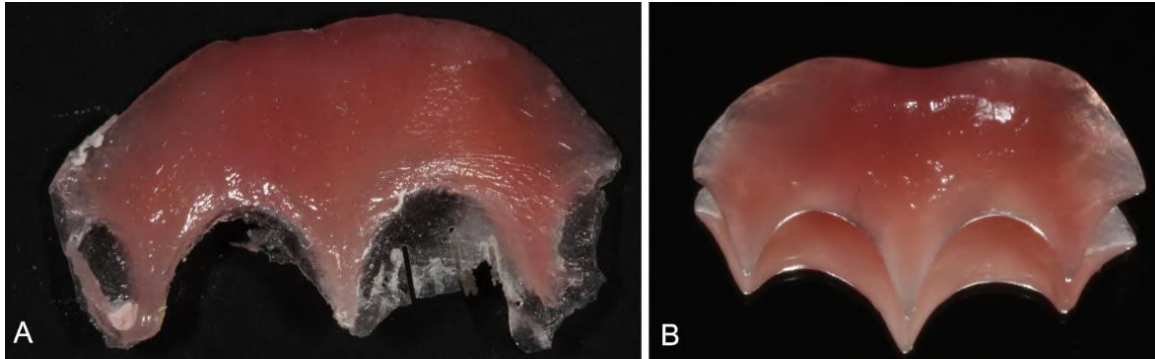
**Figure 3** - Muffle containing model and acrylic resin.



Source: Authors.

4 - After the waxing is perfectly adapted and adjusted in the mouth, the gingiva color is selected using the proper scale and then the wax work is sent for finalization (figure 3).

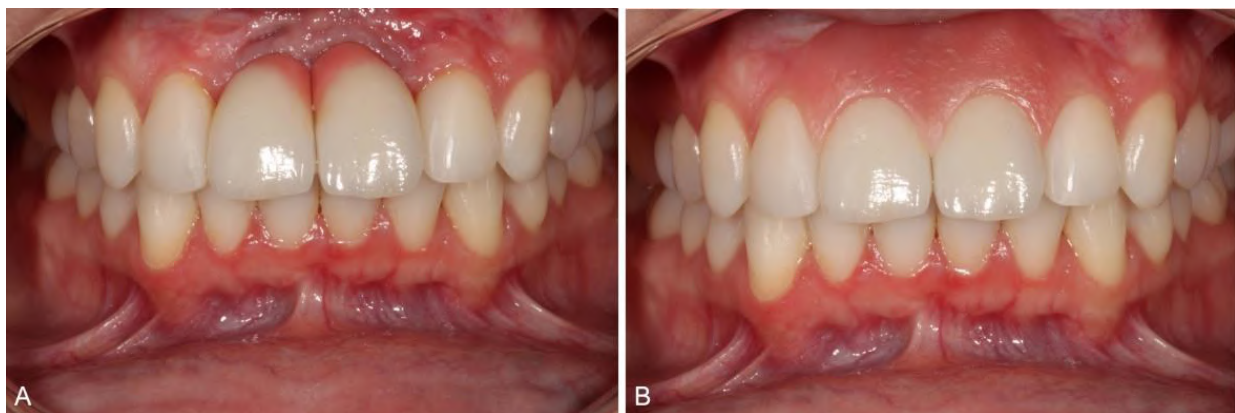
**Figure 4 -** Gingival epithesis. A, before finishing and polishing. B, after finishing and polishing.



Source: Authors.

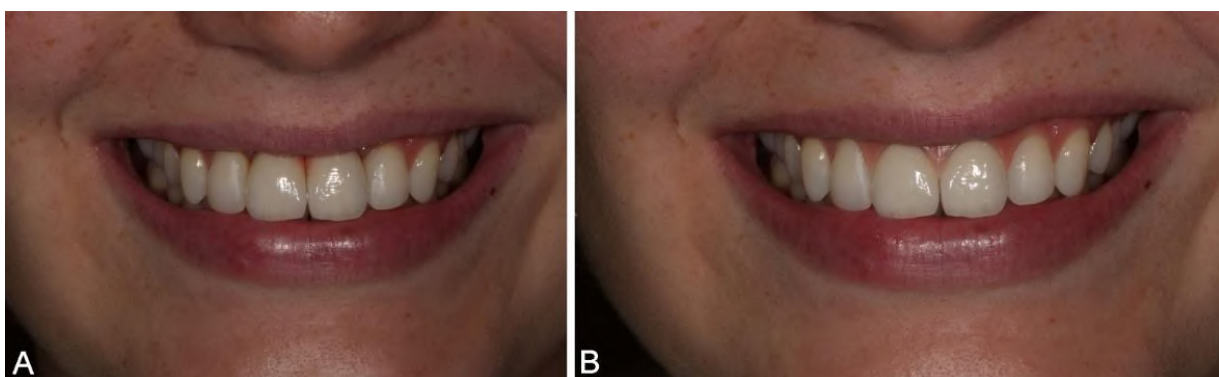
5 - The material chosen for making this gingival prosthesis is thermo-polymerizable acrylic resin (Figure 4). Various resin colors are used in order to get even closer to the original color of the patient's gingiva. Internally, its extensions must fill the proximal niches, to favor retention and prevent the escape of air.

**Figure 5 -** Intra-oral view. A, without the epithesis. B, with the epithesis.



Source: Authors.

**Figure 6 -** Full smile frontal view. A, without the epithesis. B, with the epithesis.



Source: Authors.

6 - In the installation of the prosthesis, verified adaptation, esthetics, phonetics and interferences in functional movements (Figures 5 and 6). If necessary, minimal adjustments can be made. Instructions for use are also given to the patient such as good hygiene, care with fractures and displacement in sports and with whistles and wind instruments.

#### 4. Discussion

One of the biggest challenges in dental practice is the vertical loss of soft and hard tissue in the anterior region, especially when the patient already presents with implants placed. In these cases, phonetic and aesthetic problems are common complaints of patients and difficult for the dentist to solve. Implant removal and vertical ridge reconstruction for implant replacement is an option to restore tissue contours and aesthetics, but the surgical costs, healing time, discomfort, and unpredictability make this choice unpopular (Ankli et al., 2018; Sonune et al., 2017).

Gingival epithesis can be used for a long time without complications (Kapari et al., 1991) and is an indicated solution for cases of malpositioned implants, gingival black spaces, exposed root surfaces and/or crown margins, lack of lip support due to bone and gum loss and cases of aesthetic compromise due to long anterior crowns (Antony & Khan, 2013; Barzilay & Irene, 2003). The great inconvenience of this type of prosthesis is the fact that it is removable, and like all removable prostheses, it requires careful planning to succeed in muscle, functional and aesthetic recovery (Mesquita et al., 2022). Other disadvantages are the difficulty in obtaining retention, potential for fracture during cleaning procedures and plaque accumulation (Zhao et al., 2003). However, it can be performed by the clinician in an easy, fast, safe and low-cost way (Kasaj et al., 2010).

The technique described here requires a good diagnosis and planning, as well as the patient's active participation in the decision for this treatment modality, aware of the advantages and disadvantages of each treatment option. To make a well-adapted epithesis, in harmony with the teeth and tissues, and which becomes invisible in the mouth, a good impression is essential, copying the interdental embrasures and the entire gingival support region, in addition to the material of choice, being the heat-cure acrylic resin the most suitable for these purposes. In addition, an experienced technician and a thorough color selection with appropriate scale ensure the mimicry of the region to be restored.

#### 5. Final Considerations

This article describes the gingival epithesis in heat-curable acrylic. This offers a quick, accurate, non-invasive and simple technique that allows the patient to be rehabilitated with esthetics, comfort, good adaptation and low cost.

However, due to being a technique little known by clinicians and with few publications in the literature, more studies, especially clinical trials, should be encouraged and carried out.

#### References

- Antony, V. V., & Khan, R. (2013). Gingival Mask - Restoring the lost smile. *IOSR-JDMS*, 5: 20-22
- Ankli, V., Limeira, F. I. R., Yamauti, M., et al. (2018). Gingival Veneer Used as Prosthetic Solution for Esthetic-Compromised Malpositioned Dental Implant. *Contemp Clin Dent* 9: 123-127.
- Barzilay, I., & Irene, T. (2003). Gingival prostheses--a review. *J Can Dent Assoc* 69: 74-8.
- Burhan, R., Raza Kazmi, S. M., & Quraeshi, S. (2015). Severe Gingival Recession: Gingival Veneer a Method of Camouflage. *J Coll Physicians Surg Pak* 25: 549-50.
- Carreiro, A. F. P., Moraes, S., Branco, N., et al. (2008). Epítese gengival removível: alternativa estética e de rápida resolução para repor tecidos periodontais anteriores. *Rev Gaúcha Odontol* 56: 451-455.
- Cunliffe, J., & Pretty, I. (2009). Patients's ranking of interdental "black triangles" against other common esthetic problems. *Eur J Prosthodont Restor Dent*, 17: 177-181.
- D'Angelo, M. P. (2017). Oral and Maxillofacial Implantology, Fundamental Pillar in Prosthetic Restoration. *EC Dental Science* 14: 260-273.

- Desai, R. B., Dange, S. P., & Vaidya, S. P. (2012). Gingival epithesis case report. *Clin Dent*. 8: 46–51.
- Federspil, P. A. (2010). Auricular prostheses. *Adv Otorhinolaryngol*. 68: 65-80.
- Gopakumar, A., & Sood, B. (2012). Conservative management of gingival recession: the gingival veneer. *J Esthet Restor Dent* 24: 385-93.
- Jawale, M. R., Chaurasia, R. K. R. P., Chaurasia, V. R., et al. (2014). Gingival epithesis: An esthetic solution in periodontally compromised patients. *Int J Appl Dent Sci* 1: 02-04.
- Kapari, D., Tsalikis, L., Lehmann, K. M., et al. (1991). Changes in the physical properties of Gingivamoll flexible gingival epithesis. *Dtsch Zahnarztl Z*. 46: 503-5.
- Kasaj, A., Willershausen, B., & Zafirooulos, G. G. (2010). Flexible gingival epithesis: treatment of recession defects. *Dent Today*. 29: 108, 110-1.
- Mesquita, V. T., Godoy, I. F., & Vajgel, B. F. C. (2022). Comparison between removable complete prosthesis made by conventional and digital methods: systematic review. *Research, Society and Development*. 11: p.e369111234516.
- Rabaioli, J. L., Rybu, B. R., Russomano, R. P., et al. (2013). Modified implant-supported fixed maxillary prosthesis: removable gingival veneer retained with attachments. *Stomatos* 19: 1-27.
- Rupawat, D., Maiti, S., Nallaswamy, D., et al. (2020). Aesthetic Outcome of Implants in the Anterior Zone after Socket Preservation and Conventional Implant Placement: A Retrospective Study. *J Long Term Eff Med Implants* 30: 233-239.
- Singh, V. P., Uppoor A. S., Nayak, D. G., et al. (2013). Black triangle dilemma and its management in esthetic dentistry. *Dent Res J (Isfahan)* 10: 296-301.
- Sonune, S. J., Kumar, S., Jadhav, M. S., et al. (2017). Gingival-colored Porcelain: A Clinical Report of an Esthetic-prosthetic Paradigm. *Int J Appl Basic Med Res*. 7: 275-277.
- Szmidt, M., Górski, M., Bendyk-Szeffer, M., et al. (2019). An Alternative Prosthodontic Management of Maxillary Dentoalveolar Defect in a Patient With Cleft Palate and Lip: Case Report. *Cleft Palate Craniofac J*. 56: 1256-1259.
- Zhao, X., Cao, J., & Zhang, Y. (2003). Clinical application of a kind of flexible gingival epithesis material. *Hua Xi Kou Qiang Yi Xue Za Zhi*. 21: 324-6.