

## Childhood meningitis and delay of four years in diagnosing bilateral profound sensorineural hearing loss: a case report

Meningite infantil e atraso de quatro anos no diagnóstico de perda auditiva neurosensorial bilateral profunda: relato de caso

Meningitis infantil y retraso de cuatro años en el diagnóstico de hipoacusia neurosensorial profunda bilateral: reporte de un caso

Received: 09/20/2022 | Revised: 10/03/2022 | Accepted: 10/07/2022 | Published: 10/13/2022

**Glaurea Regina de Santana Nunes**

ORCID: <https://orcid.org/0000-0001-9178-9446>

Federal University of Paraiba, Brazil

E-mail: [glaureanunes98@gmail.com](mailto:glaureanunes98@gmail.com)

**Camilla Porto Campello**

ORCID: <https://orcid.org/0000-0001-6689-5466>

Federal University of Paraiba, Brazil

E-mail: [camilla.campello@gmail.com](mailto:camilla.campello@gmail.com)

**Elker Lene Santos de Lima**

ORCID: <https://orcid.org/0000-0002-7171-7418>

University of Pernambuco, Brazil

E-mail: [elkerlene@yahoo.com.br](mailto:elkerlene@yahoo.com.br)

**Hannalice Gottschalck Cavalcanti**

ORCID: <https://orcid.org/0000-0003-2327-8040>

Federal University of Paraiba, Brazil

E-mail: [hannafono@gmail.com](mailto:hannafono@gmail.com)

### Abstract

Globally around 34 million children present disabling hearing loss. If unaddressed, hearing loss can negatively impact several aspects such as communication, cognition, language, and speech. Most needy people with hearing impairment do not have access to treatments and it's a national and international public health problem. Meningococcal disease is caused by the bacterium *Neisseria meningitides*, affects mainly children, can cause hearing loss, and is a global public health challenge. This study aimed to present the case report of a child who acquired meningococcal disease and bilateral profound sensorineural hearing loss in primary infancy. At the age of six months, the child acquired meningococcal meningitis and performed antibiotic therapeutics. Four years later, the audiometric evaluation detected hearing loss. At the age of seven years, the patient started speech language therapy sessions. At the age of nine years, hearing prostheses were provided by a hospital. At the age of ten, the child began to deny the use of hearing aids at home and school. Two years later, she started her studies at a special school where the deaf community is clearly present. At the age of fourteen, the patient became completely fluent in Sign language, stopping speech therapy sessions. The analyzed case demonstrated a lack of children's surveillance by a multidisciplinary team and the relevance of following children's guidance vaccination. It is required to provide adequate interventions for children with hearing loss, which can potentially aid them to develop their skills and to achieve a better quality of life.

**Keywords:** Sensorineural hearing loss; Bilateral deafness; Meningococcal meningitis; Global health; Public health services; Multidisciplinary team.

### Resumo

Globalmente, cerca de 34 milhões de crianças apresentam perda auditiva incapacitante. Se não tratada, a perda auditiva pode impactar negativamente em diversos aspectos, como comunicação, cognição, linguagem e fala. A maioria das pessoas carentes com deficiência auditiva não tem acesso a tratamentos, sendo este um problema de saúde pública nacional e internacional. A doença meningocócica é causada pela bactéria *Neisseria meningitides*, acomete principalmente crianças, pode causar perda auditiva, e é um desafio de saúde pública global. Este estudo teve como objetivo apresentar o relato de caso de uma criança que adquiriu doença meningocócica e perda auditiva sensorineural bilateral profunda na primeira infância. Aos seis meses, a criança adquiriu meningite meningocócica e realizou antibioticoterapia. Quatro anos depois, a audiometria detectou a perda auditiva. Aos sete anos de idade, a paciente iniciou sessões de terapia fonoaudiológica. Aos nove anos, as próteses auditivas foram fornecidas por um hospital. Aos dez anos, a criança começou a não utilizar mais os aparelhos auditivos em casa e na escola. Dois anos depois, iniciou seus estudos em uma escola especial onde a comunidade surda está claramente presente. Aos quatorze

anos, a paciente tornou-se completamente fluente em Língua de Sinais, interrompendo as sessões de terapia fonoaudiológica. O caso analisado demonstrou a falta de vigilância à criança pela equipe multidisciplinar e a relevância de seguir as orientações de vacinação infantil. É necessário fornecer intervenções adequadas para crianças com deficiência auditiva, que potencialmente podem auxiliá-las a desenvolver suas habilidades e alcançar uma melhor qualidade de vida.

**Palavras-chave:** Perda auditiva sensorioneural; Surdez bilateral; Meningite meningocócica; Saúde global; Serviços públicos de saúde; Comunicação multidisciplinar.

### Resumen

A nivel mundial, alrededor de 34 millones de niños presentan pérdida auditiva discapacitante. Si no se aborda, la pérdida auditiva puede tener un impacto negativo en varios aspectos, como la comunicación, la cognición, el lenguaje y el habla. La mayoría de las personas necesitadas con discapacidad auditiva no tienen acceso a tratamientos y es un problema de salud pública nacional e internacional. La enfermedad meningocócica es causada por la bacteria *Neisseria meningitidis*, afecta principalmente a niños, puede causar pérdida de audición y es un desafío de salud pública mundial. Este estudio tuvo como objetivo presentar el caso clínico de un niño que adquirió enfermedad meningocócica e hipoacusia neurosensorial profunda bilateral en la primera infancia. A la edad de seis meses, el niño contrajo una meningitis meningocócica y se le practicó una terapia antibiótica. Cuatro años después, la evaluación audiométrica detectó hipoacusia. A la edad de siete años, la paciente inició sesiones de logopedia. A la edad de nueve años, un hospital le proporcionó prótesis auditivas. A la edad de diez años, el niño comenzó a negar el uso de audífonos en el hogar y la escuela. Dos años más tarde, inició sus estudios en una escuela especial donde la comunidad sorda está claramente presente. A la edad de catorce años, el paciente domina completamente el lenguaje de señas, interrumpiendo las sesiones de terapia del habla. El caso analizado demostró la falta de vigilancia de los niños por un equipo multidisciplinario y la pertinencia de seguir las orientaciones de vacunación de los niños. Se requiere brindar intervenciones adecuadas para los niños con pérdida auditiva, que potencialmente puedan ayudarlos a desarrollar sus habilidades y lograr una mejor calidad de vida.

**Palabras clave:** Hipoacusia neurosensorial; Sordera bilateral; Meningitis meningocócica; Salud global; Servicios públicos de salud; Equipo multidisciplinario.

## 1. Introduction

Hearing is the sense with which people detect the sounds around them; through hearing people engage with the environment, communicate, express thoughts, and gain education (World Health Organization, 2021). This sense presents a fundamental role in language and auditory development (Besen et al., 2021). Globally around 430 million people including 34 million children present disabling hearing loss, which considerably reduces their quality of life (World Health Organization, 2021).

The definition of hearing loss varies in different classification systems. In general, categories of hearing deficit are mild (21-40 dB HL), moderate (41-70 dB HL), severe (71-95 dB HL), and profound (>95 dB HL) (Wroblewska-Seniuk et al., 2018). There are three main types of hearing loss. Sensorineural hearing loss is a consequence of a failure in the transduction of vibrations into neural impulses in the cochlea, conductive hearing loss is a consequence of interference in the transmission of sound through the external and middle ear, and mixed hearing loss is a combination of sensorineural and conductive hearing deficits (Wroblewska-Seniuk et al., 2018).

The universal newborn hearing screening is the best way to detect hearing loss in infants. It provides notably lowering the average age of identification (Joint Committee on Infant Hearing, 2019). This is the essential first step nevertheless, does not guarantee the next critical steps of timely identification and diagnosis of children with hearing loss, amplification, and referral to early intervention, all with the aim of developing language (Joint Committee on Infant Hearing, 2019). Furthermore, the American Academy of Pediatrics Committee (2017) affirms that regardless of previous hearing-screening results, all infants presenting or not risk factors should receive ongoing surveillance of communication development beginning at 2 months of age during medical visits.

Communication and linguistic competence are reachable when early intervention services are provided (Joint Committee on Infant Hearing, 2019). However, if unaddressed, hearing loss can harmfully impact several aspects of life such as communication, cognition, language, and speech development in children, education, mental health, and interpersonal relationships (World Health Organization, 2021). Currently, most needy people with hearing impairment do not have access to treatments (World Health Organization, 2021) and it is a national (Malta et al., 2016) and global public health problem (World Health Organization, 2021). It remains a fundamental research goal to identify children at risk of receiving delayed clinical support to aid all children achieve prompt diagnosis and therapies (Campbell & Bergelson, 2022).

Numerous causes of hearing loss can be prevented such as ear infections, common ear diseases, exposure to noise and chemicals, and vaccine-preventable illnesses (World Health Organization, 2021). Invasive meningococcal disease is an infectious disease caused by the bacterium *Neisseria meningitides* (Huang et al., 2022), affecting subjects of all age groups; nevertheless, the incidence is highest among children under five years of age (Cardoso et al., 2015). Although there are several antibiotic therapies, this disease remains a global public health challenge because clinical symptoms are frequently nonspecific and progress rapidly (Huang et al., 2022). The most common clinical manifestations of meningococcal disease are meningitis, septicemia, or both (Huang et al., 2022). Additional warning signs can include seizures, cognitive impairment, or impairment of consciousness (Maurer et al., 2009) and significant sequelae include neurological problems, osteoarticular damage, and hearing loss (Arteta-Acosta et al., 2022) which can be either unilateral or bilateral, varying from mild to profound (Rodenburg-Vlot et al., 2018). Meningitis causes inflammation of the inner ear development due to the infection via the internal auditory canal and/or via cochlear aqueduct (Lempinen et al., 2022). Damage affects the intracochlear structures, which the most important is organ of Corti and neural elements; consequently, hearing is impaired (Lempinen et al., 2022).

Since meningitis is a relevant health problem with major socio-economic consequences reaching people of all countries, it was an important topic of the Seventy-fifth World Health Assembly carried out in 2022, thus the World Health Organization has designed a global road map for defeating meningitis by 2030 (World Health Organization, 2022).

Due to the importance of health care professionals to be aware of child health surveillance after acquired diseases associated with hearing impairment in order to early diagnose hearing problems and the relevance of following guidelines for vaccinating children. This study aimed to present a case report of a child who acquired meningococcal disease and bilateral profound sensorineural hearing loss in primary infancy and was diagnosed four years later, which brought permanent harmful consequences.

## 2. Case Report

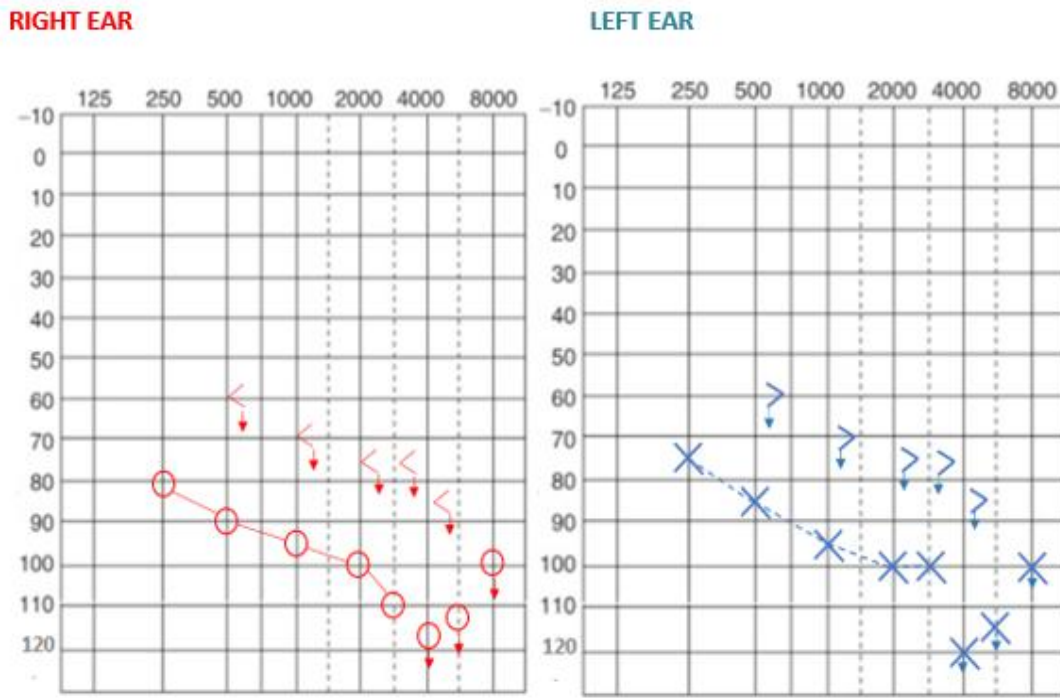
The present study was approved by the ethics committee of Agamenon Magalhães Hospital and a consent form was obtained from the participant.

In October 1999, a female patient was born in a public hospital in Pernambuco, Northeast Brazil, and underwent newborn hearing screening at the same hospital. She was screened for hearing loss and “passed” the screening in both ears. In 2000, at the age of six months, she acquired meningococcal meningitis C, was hospitalized for two months, and performed antibiotic therapeutics. This is the supposed cause of deafness.

In 2003, she started school at the age of three, however; only in 2004 at the age of four years and seven months, the school referred her to an otolaryngologist, and he requested an audiometric exam. The patient's mother reported that her daughter was the unique deafness student and could not perform well in school activities.

The audiometric evaluation detected a bilateral profound sensorineural hearing loss (Figure 1).

**Figure 1- Pure Tone Audiometry**



Frequency was measured in hertz, sound was measured in decibels; ○: right ear airway, X: left ear airway, <: right ear bone conduction, > left ear bone conduction, ↓: no patient response.

The speech was detected by the child about 95dB in both ears as can be seen in Figure 2.

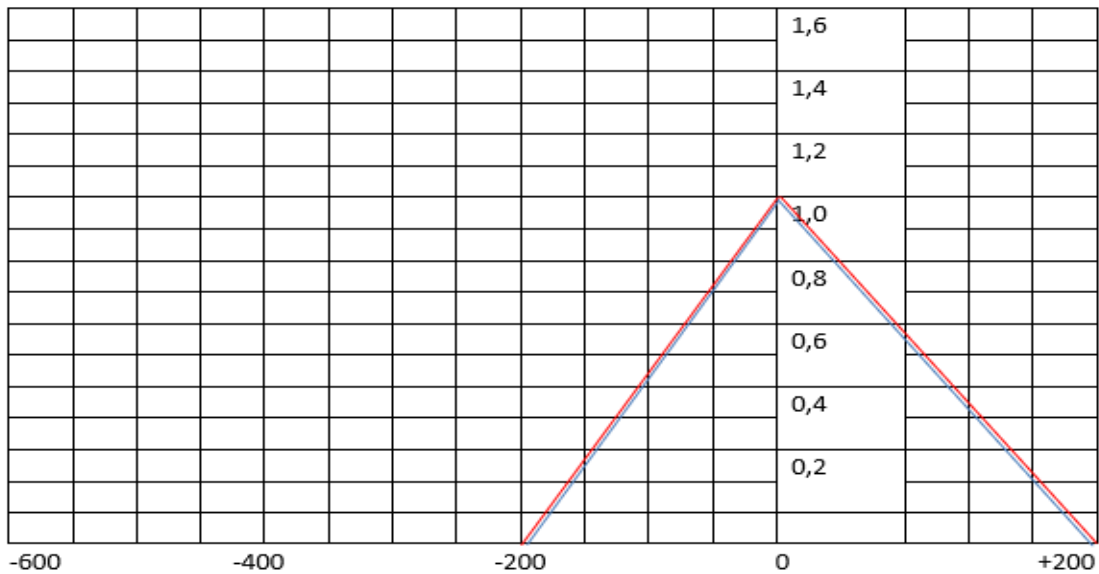
**Figure 2- Speech Audiometry Tests**

	SRPI	%	dB	MASKING	SRT(dB)	MASKING	SDT(dB)	MASKING	MASKING
RE	monosyllables						95		RE (tested LE)
	two syllables								Airway: —
	three syllables								Boneway: —
LE	monosyllables						95		LE (tested RE)
	two syllables								Airway: —
	three syllables								Boneway: —

RE: right ear; LE: left ear; SRPI: Speech Recognition Percentage Index; dB: decibels; SRT: speech reception threshold; SDT: speech detection threshold.

The imitanciometry demonstrated a type A bilateral tympanometric curve (Figure 3).

**Figure 3- Results of the imitanciometry**



CONTRA	RE	LE	IPSI	RE	LE
	↓	↓	500 Hz		
	↓	↓	1000 Hz		
	↓	↓	2000 Hz		
	↓	↓	4000 Hz		
	Probe LE	Probe RE			

CONTRA: contralateral acoustic reflexes; IPSI: ipsilateral acoustic reflexes; RE: right ear; LE: left ear; Hz: frequency in hertz.

The patient's mother reported that after hearing exams the school began to assist the patient with special attention. The teacher carried out some activities with the child. The patient's mother and grandmother believed that the school could resolve the "deafness problem"; nevertheless, the child's progress was minimal and did not correspond to her age.

By the time of 2007, a neighbor advised the patient's mother to find a Speech Language Pathologist in order to aid the child to speak. Thus, the patient was at the age of seven when started speech language therapy sessions at a public hospital. Therapy sessions were one time a week for twenty minutes. Initially, the child refused to go to the therapy room for one month, and when she accepted to enter the room, did not participate in the activities proposed. The speech language therapy sessions prioritized the development of interaction and the understanding and use of spoken language. After ten months, the patient started to interact more with the Speech Language Pathologist, who enrolled the child in a public hospital program that provides hearing aids to support people with hearing impairment. After the patient completed nine years of age, bilateral hearing prostheses were provided by the hospital. At this time, she started to listen when was called and spoken sounds. After

three months with bilateral hearing prosthesis, the patient was able to speak phonemic groups. All therapy sessions involved activities of interest to the child such as games with colors, animals, and pirates.

By the time of 2010, at the age of ten, the patient began to deny the use of hearing aids at home and school. She used hearing aids just in therapy sessions; however, she started missing some of them. The patient's grandmother reported that sometimes the family did not have money for the bus ticket. The Speech Language Pathologist discovered an unregulated noise in the patient's hearing aids and requested a technical review of them, which took three months. After this period, the child continued to deny the use of hearing prostheses, except during therapy sessions.

In 2012, the patient started her studies at a special school where the deaf community is clearly present, which quickly aroused her interest in Brazilian Sign Language. For this reason, the Speech Language Pathologist introduced Sign Language to all therapy sessions. Although the therapist also worked to promote oral language development, the child lost interest in speaking. In 2015, at age fourteen, the patient became completely fluent in Sign language, stopping speech therapy sessions.

### 3. Discussion

This case report indicates the importance of children's ongoing surveillance by a multidisciplinary team, following children's guidance vaccination, and the relevance of instructing families to seek medical and speech therapy services when a child has difficulties in hearing or speaking.

In 2010, the Meningococcal C conjugate vaccine was implemented in Brazil (da Silva et al., 2022). In 2000, when the patient acquired meningitis this vaccine was not implemented yet. Perhaps, if the patient had been vaccinated before being infected, she would not have had the disease. Vaccines not only protect people against any future infection but also immunize them against those infections for a very long time (Gunasekaran & Gothandam, 2020). Vaccination is the most successful way to prevent Meningococcal disease. It plays a fundamental role in avoiding outbreaks (Gioia et al., 2017).

The number of cases among children younger than 2 years has diminished posterior the introduction of Meningococcal C vaccine in the National Immunization Program in Brazil (Cardoso et al., 2015). However, the vaccination rates for this disease were considerably reduced in all states and in the Federal District of Brazil, during the COVID-19 pandemic (da Silva et al., 2022). Children who were not vaccinated can be infected by Meningococcal disease, suffering harmful consequences, including hearing loss like the patient reported in this study. Parents need to be aware of the importance of following vaccination guidance. Protecting infants from contamination by COVID-19 cannot put them at serious risk of contamination by other diseases.

Child health surveillance after acquired infections is paramount to detect the consequences of diseases. Patients who presented bacterial Meningitis should be regularly monitored with hearing tests for both ears as soon as the infection ends (Rodenburg-Vlot et al., 2018). This is most important for young children because they are less probable to complain about hearing problems and they more often suffer from a profound hearing loss (Rodenburg-Vlot et al., 2018). Recent data showed that more than a third of the patients had not done a hearing test after recovering from bacterial meningitis (Persson et al., 2022) and that should not happen.

The present case report showed that late diagnosis and treatment of hearing loss can cause an enormous delay in language acquisition and development. Moreover, the health care provided to this child was not completely efficient because therapy sessions were one time a week for twenty minutes; this is a too short period for the necessary rehabilitation. The later diagnosis and treatment in addition to waiting time for hearing aids generated a lack of adaptation to wearing hearing aids and posteriorly influenced the child to refuse to use them.

Sign languages are the primary mode of communication in hearing impaired people communities across the world, its use provides cognitive, linguistic, and communication skills development (Holmer et al., 2022). In this case report, the child began to use Sign language at the age of twelve years old, she adapted to a deaf community, and achieved a fluency level in Brazilian Sign language, which significantly contributed to her socialization. However, the speech language development also could be achieved if an early diagnosis would be performed. Early diagnosis and speech language intervention services can considerably aid children to develop communication and linguistic competence improving their quality of life (Malta et al., 2016).

Moreover, unaddressed hearing loss brings a significant cost to countries in various sectors (Tordrup et al., 2022). The healthcare sector presents high costs for treating children and adults because of failing to address hearing loss on time (Tordrup et al., 2022). Undiagnosed and Untreated hearing loss from a very early age also has a burden on the education sector due to the costs of providing school support to children (Tordrup et al., 2022). Additionally, unemployment and premature retirement among subjects with hearing impairment considerably affect the labor sector (Tordrup et al., 2022).

The present case report reflects the reality of many children who live in developing countries. In spite of the fact that there are many therapies for hearing impaired people such as hearing aids, cochlear implants, and rehabilitative therapy, the majority of those in need do not have access to treatments (World Health Organization, 2021). Most individuals with hearing loss live in low-income settings where health services for ear and hearing care are not usually available (World Health Organization, 2021).

It is paramount to provide the necessary health care to children with hearing loss, because it can make all difference in adulthood. The early hearing loss therapeutics can considerably ameliorate the communication, the development of language and speech, cognition, education, and socialization; as a result, these people can have better employment opportunities, enhancing their quality of life.

#### 4. Conclusion

The analyzed case demonstrated the importance of children's ongoing surveillance by a multidisciplinary team in order to detect hearing and communication problems. Audiological follow-up is paramount after bacterial meningitis especially for young children as well as it is essential to comply with children's guidance vaccination.

Additionally, it is required to provide health education to communities and adequate interventions for hearing impaired people, which can potentially aid them to develop their skills and to achieve a better quality of life.

#### Acknowledgments

We thank the patient who contributed substantially to this study.

This article was financed in part by the Coordenação de Aperfeiçoamento de Pessoal de Nível Superior – Brazil (CAPES) – Finance Code 001.

#### References

- Arteta-Acosta, C., Villena Martínez, R., & Santolaya de Pablo, M. E. (2022). Sequelae at Hospital Discharge in 61 Children With Invasive Meningococcal Disease, Chile, 2009-2019. *The Pediatric infectious disease journal*, 41(8), 607–613. <https://doi.org/10.1097/INF.0000000000003560>
- Besen, E., Paiva, K. M., Hillesheim, D., Cigana, L. B., & Haas, P. (2021). Congenital syphilis associated with hearing screening failure in southern Brazilian newborns. *Brazilian journal of otorhinolaryngology*, S1808-8694(21)00148-8. Advance online publication. <https://doi.org/10.1016/j.bjorl.2021.07.003>
- Campbell, E., & Bergelson, E. (2022). Characterizing North Carolina's Deaf and Hard of Hearing Infants and Toddlers: Predictors of Vocabulary, Diagnosis, and Intervention. *Journal of speech, language, and hearing research: JSLHR*, 65(5), 1894–1905. [https://doi.org/10.1044/2022\\_JSLHR-21-00245](https://doi.org/10.1044/2022_JSLHR-21-00245)

- Cardoso, C. W., Ribeiro, G. S., Reis, M. G., Flannery, B., & Reis, J. N. (2015). Effectiveness of meningococcal C conjugate vaccine in Salvador, Brazil: a case-control study. *PLoS one*, *10*(4), e0123734. <https://doi.org/10.1371/journal.pone.0123734>
- Committee on Practice and Ambulatory Medicine & American Academy of Pediatrics Bright Futures Periodicity Schedule Workgroup. (2017). 2017 Recommendations for Preventive Pediatric Health Care. *Pediatrics*, *139*(4), e20170254. <https://doi.org/10.1542/peds.2017-0254>
- da Silva, T., Brandão, L., Vieira, E., Maciel, T., da Silva, T., Luvisaro, B., de Menezes, F. R., & Matozinhos, F. P. (2022). Impact of COVID-19 pandemic on vaccination against meningococcal C infection in Brazil. *Vaccine: X*, *10*, 100156. <https://doi.org/10.1016/j.jvacx.2022.100156>
- Gioia, C., Lemos, A., Gorla, M., Mendoza-Sassi, R., Figueredo, B. S., Ballester, T., Von Groll, A., Wedig, B., Ethur, N. V., Bragança, L., Silva, P., & Milagres, L. G. (2017). Seroprevalence of bactericidal antibodies against serogroup B and C Meningococci in a University Hospital. *Brazilian journal of medical and biological research = Revista brasileira de pesquisas medicas e biologicas*, *50*(5), e5590. <https://doi.org/10.1590/1414-431X20175590>
- Gunasekaran, B., & Gothandam, K. M. (2020). A review on edible vaccines and their prospects. *Brazilian journal of medical and biological research = Revista brasileira de pesquisas medicas e biologicas*, *53*(2), e8749. <https://doi.org/10.1590/1414-431X20198749>
- Holmer, E., Schönström, K., & Andin, J. (2022). Associations Between Sign Language Skills and Resting-State Functional Connectivity in Deaf Early Signers. *Frontiers in psychology*, *13*, 738866. <https://doi.org/10.3389/fpsyg.2022.738866>
- Huang, L., Fievez, S., Gogouillot, M., Marié, L., Bénard, S., Elkaim, A., & Tin Tin Htar, M. (2022). A database study of clinical and economic burden of invasive meningococcal disease in France. *PLoS one*, *17*(4), e0267786. <https://doi.org/10.1371/journal.pone.0267786>
- Lempinen, L., Laulajainen-Hongisto, A., Aarnisalo, A. A., Bernardino, L., Peltola, H., Pitkäranta, A., Pelkonen, T., & Jero, J. (2022). Hearing impairment in Angolan children with acute bacterial meningitis with and without otitis media. *Acta paediatrica (Oslo, Norway 1992)*, *111*(8), 1585–1593. <https://doi.org/10.1111/apa.16383>
- Malta, D. C., Stopa, S. R., Canuto, R., Gomes, N. L., Mendes, V. L., Goulart, B. N., & Moura, L. (2016). Self-reported prevalence of disability in Brazil, according to the National Health Survey, 2013. Prevalência autorreferida de deficiência no Brasil, segundo a Pesquisa Nacional de Saúde, 2013. *Ciencia & saude coletiva*, *21*(10), 3253–3264. <https://doi.org/10.1590/1413-812320152110.17512016>
- Maurer, P., Hoffman, E., & Mast, H. (2009). Bacterial meningitis after tooth extraction. *British dental journal*, *206*(2), 69–71. <https://doi.org/10.1038/sj.bdj.2009.3>
- Persson, F., Bjar, N., Hermansson, A., & Gisselsson-Solen, M. (2022). Hearing loss after bacterial meningitis, a retrospective study. *Acta otolaryngologica*, *142*(3-4), 298–301. <https://doi.org/10.1080/00016489.2022.2058708>
- Rodenburg-Vlot, M., Ruytjens, L., Oostenbrink, R., & van der Schroeff, M. P. (2018). Repeated Audiometry After Bacterial Meningitis: Consequences for Future Management. *Otology & neurotology: official publication of the American Otological Society, American Neurotology Society [and] European Academy of Otology and Neurotology*, *39*(5), e301–e306. <https://doi.org/10.1097/MAO.0000000000001808>
- The Joint Committee on Infant Hearing. (2019) Year 2019 Position Statement: Principles and Guidelines for Early Hearing Detection and Intervention Programs. *JEHDI*, *4*(2), 1-44. <http://dx.doi.org/10.15142/fptk-b748>
- Tordrup, D., Smith, R., Kamenov, K., Bertram, M. Y., Green, N., Chadha, S., & WHO HEAR group (2022). Global return on investment and cost-effectiveness of WHO's HEAR interventions for hearing loss: a modelling study. *The Lancet. Global health*, *10*(1), e52–e62. [https://doi.org/10.1016/S2214-109X\(21\)00447-2](https://doi.org/10.1016/S2214-109X(21)00447-2)
- World Health Organization. (2021). World report on hearing. <https://www.who.int/publications/i/item/world-report-on-hearing>
- World Health Organization. (2022). Updates from the 75th World Health Assembly. <https://www.who.int/news/item/03-06-2022-updates-from-the-75th-world-health-assembly>
- Wroblewska-Seniuk, K., Dabrowski, P., Greczka, G., Szabatowska, K., Glowacka, A., Szyfter, W., & Mazela, J. (2018). Sensorineural and conductive hearing loss in infants diagnosed in the program of universal newborn hearing screening. *International journal of pediatric otorhinolaryngology*, *105*, 181–186. <https://doi.org/10.1016/j.ijporl.2017.12.007>