

Viabilidade da haste intramedular de poliamida 12 revestida com hidroxiapatita em fraturas experimentalmente induzidas em aves (*Plymouth rock* branca) jovens

Viability of polyamide 12 intramedullary rods coated with hydroxyapatite in experimentally induced fractures in young roosters (white *Plymouth rock*)

Viabilidad del clavo intramedular de poliamida 12 recubierta con hidroxiapatita en fracturas inducidas experimentalmente en aves jóvenes (*roca* blanca de *Plymouth*)

Recebido: 14/04/2020 | Revisado: 24/04/2020 | Aceito: 26/04/2020 | Publicado: 28/04/2020

Fernanda Gosuen Gonçalves Dias

ORCID: <https://orcid.org/0000-0001-6072-4789>

Universidade de Franca, Brazil

E-mail: fernandagosuen@yahoo.com.br

Leonardo Lamarca de Carvalho

ORCID: <https://orcid.org/0000-0002-9208-7865>

Universidade de Franca, Brazil

E-mail: lamarca.leo@hotmail.com

Luis Gustavo Gosuen Gonçalves Dias

ORCID: <https://orcid.org/0000-0003-3993-1649>

Faculdade de Ciências Agrárias e Veterinárias, Brazil

E-mail: gustavogosuen@gmail.com

Vitória Ferreira Nogueira de Paula Fontes

ORCID: <https://orcid.org/0000-0002-9788-3086>

Universidade de Franca, Brazil

E-mail: vitoriafnfontes@gmail.com

Ewaldo de Mattos Junior

ORCID: <https://orcid.org/0000-0001-9315-5447>

Universidade de Franca, Brazil

E-mail: ewaldo.junior@unifran.edu.br

Resumo

O presente estudo teve como objetivo avaliar a viabilidade de hastes intramedulares maciças confeccionadas com poliamida 12 e revestidas com hidroxiapatita em úmeros experimentalmente osteotomizados de galos (*Plymouth rock* branca) jovens. Foram utilizadas

16 aves com 45 dias de vida. Após anestesia geral, foram submetidas à osteotomia transversa completa da diáfise do úmero direito para implantação das referidas hastes que preencheram toda a extensão do canal medular e foram bloqueadas com dois parafusos corticais metálicos em cada fragmento ósseo. A técnica cirúrgica foi facilmente exequível não tendo nenhuma complicação intra-operatória. Por meio de exames clínico e radiográfico, observou-se que logo após o retorno anestésico, seis hastes (37,5%) quebraram próximas ao foco de fratura óssea, sendo o mesmo notado nas demais (62,5%) no 7º dia de cirurgia. Baseado nos dados obtidos pode-se hipotetizar que as hastes de poliamida 12 possam ter tido a resistência comprometida em decorrência das diversas etapas térmicas necessárias para a incorporação da hidroxiapatita. Ademais, a idade das aves pode ter contribuído para os resultados adversos deste estudo. No entanto, pesquisas futuras serão necessárias para confirmar tais hipóteses.

Palavras-chave: Biomaterial; Implante; Osteossíntese; Ortopedia; Polímero.

Abstract

The present study aimed the viability evaluation of solid intramedullary rods made with polyamide 12 and coated with hydroxyapatite in experimentally osteotomized humerus of young roosters (white *Plymouth rock*). Sixteen animals of 45 days old each were used. After general anesthesia, they underwent to complete transverse osteotomy of the right humerus diaphysis to implant the already described rods which filled the entire length of the medullary cavity and were fixed by two cortical stainless steel screws in each bone fragment. The surgical technique was well succeeded without any trans-operative intercurrentence. Through clinical and radiographic examination, it was observed that soon after the anesthesia recovery, six rods (37,5%) broke next to the fracture focus and the same was noticed with the others (62,5%) on seventh day post-surgery. Based on the obtained results, it can be hypothesized that polyamide 12 rods resistance could have been affected by all the thermal stages necessary to its incorporation with hydroxyapatite. Furthermore, the roosters' age may also have contributed to adverse outcomes. However, future researches will be necessary to confirm those hypotheses.

Keywords: Biomaterial; Implant; Osteosynthesis; Orthopedic; Polymer.

Resumen

El presente estudio tuvo como objetivo evaluar la viabilidad de las uñas intramedulares masivas hechas de poliamida 12 y recubiertas con hidroxiapatita en los húmero de gallos jóvenes osteotomizados experimentalmente (*roca blanca de Plymouth*). Se utilizaron 16 aves

con 45 días de vida. Después de la anestesia general, se les realizó una osteotomía transversal completa de la diáfisis del húmero derecho para la implantación de dichas uñas que llenaban todo el canal espinal y se bloquearon con dos tornillos metálicos corticales en cada fragmento óseo. La técnica quirúrgica fue fácilmente factible, sin complicaciones intraoperatorias. A través de exámenes clínicos y radiográficos, se observó que poco después del retorno de la anestesia, seis uñas (37.5%) se rompieron cerca del foco de fractura ósea, notándose lo mismo en las otras (62.5%) al séptimo día de la cirugía. Con base en los datos obtenidos, se puede hipotetizar que las varillas de poliamida 12 pueden haberse visto comprometidas en su resistencia debido a los diversos pasos térmicos necesarios para la incorporación de hidroxiapatita. Además, la edad de las aves puede haber contribuido a los resultados adversos de este estudio. Sin embargo, la investigación futura será necesaria para confirmar tales hipótesis.

Palabras clave: Biomaterial, Implante, Osteosíntesis, Ortopedia, Polímero.

1. Introduction

In mammals, osteosynthesis with intramedullary locked rod (IR) with metallic materials is used due to its facility of execution when compared to other techniques, however locking mistakes and movement permanence on fracture's focus are common (Spadeto Junior et al., 2011). Birds have an aggravation factor related to pneumatic bone with thin cortex (Castro et al., 2004; Alievi et al., 2008), demanding an IR with lightness, resistance to physical forces, biocompatibility and possibility of being locked by metallic screws in places without previous determination (Gouvêa et al., 2011), justifying the search for new bio-inert materials (Liu et al., 2016).

In this context, hydroxyapatite, which is composed with crystalline calcium phosphate, simulates bone tissue composition due to its chemical and structural similarity to the bone mineral stage, denoting biocompatibility, stability, bioactivity and osteoinduction, thus allowing to be used with the possibility of adding these features to other material used in orthopedics (Piattelli et al., 2000).

Cherobini et al. (2017) and Dias et al. (2018) analyzed the efficiency of massive rods made with polyamide 12 (PA-12) in experimentally induced humeral fractures in adult roosters during 60 days postoperative and they reported that the material have biocompatibility and enough resistance to maintain the fracture focus aligned, allowing osseous consolidation. Starting from that principle, the present study aimed the viability

evaluation of solid intramedullary rods made with polyamide 12 and coated with hydroxyapatite in experimentally osteotomized humerus of young roosters, hypothesizing that hydroxyapatite could induced a faster osseous consolidation when compared to that described by the aforementioned researches.

2. Material and Methods

The present study's methodology was based on laboratory research, from qualitative nature (Pereira et al., 2018).

2.1 Polyamide 12 rods

In this study, the massive IR made with PA-12 (4 mm in width and 120 mm in length) were produced at Three-Dimensional Technology Department of the Center of the Information Technology Renato Archer – Ministry of Science, Technology, Innovations and Communications in Campinas, SP, similar to those used in the studies by Cherobini et al. (2017) and Dias et al. (2018).

After confectioned, for hydroxyapatite impregnation, in the same Department, the PA-12 rods were submersed in acetic acid solution and distilled water at 80°C for 24 hours. Then, they were submitted to ultrasonic cleaning (to remove solution excesses) and drying in ambient temperature for 24 hours. After, the PA-12 rods functionalization was done by 3-aminopropyltriethoxysilane solution through agitation and reflux at 80°C for 24 hours, 3 ultrasonic cleanings (15 minutes each) and kiln drying (60°C) for two hours. Next, they were submerged in hydroxyapatite, ethanol and distilled water solution, kept in magnetic agitation (80°C for 24 hours), washed in distilled water and placed in a kiln at 60°C for 18 hours. To obtain the confirmation of hydroxyapatite impregnation, the PA-12 rods were analyzed by infrared method.

The PA-12 hydroxyapatite-coated rods were sterilized in an industrial autoclave (Lutz Ferrando Ótica e Instrumental Científico Ltda, Rio de Janeiro, RJ) at 134°C of temperature during 30 minutes.

2.2 Birds

This study was conducted on consent of the Animal Care and Use Committee of the University of Franca (n. 042/14). All procedures followed the guidelines given by the National Council on Animal Experimentation Control and the Brazilian Science Society of Laboratory Animals.

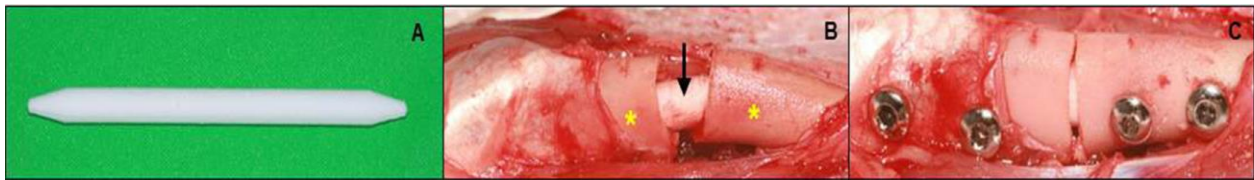
In total, 16 roosters from commercial breeders were used. The animals were acquired with five days old and were kept in a collective enclosure till 45 days old at University of Franca, with potable water and commercial ration *ad libitum*. Inclusion criteria was the absence of anatomical abnormalities by clinical inspection and through radiography examination.

Food fasting were established for two hours before the study. As pre-anesthetic medication was used ketamine (15 mg/kg - Agener União Saúde Animal, Embu - Guaçu – SP), meperidine (1 mg/kg - Sanofi - Aventis Farmacêutica Ltda, São Paulo, SP) and xylazine (0,5 mg/kg - Konig, Mairinque, SP) associated in the same syringe and applied intramuscularly on the pectoral musculature. After 15 minutes, anesthetic induction was performed with isoflurane (Virbac do Brasil Indústria e Comércio Ltda, São Paulo, SP) through facial mask followed by orotracheal intubation with Magil tube (diameter appropriate for the size of each animal) and anesthetic maintenance with the same medication diluted in 100% of oxygen. Also, a right brachial plexus block was done with bupivacaine 0,5% (1 mg/kg - Cristália Produtos Farmacêuticos Ltda, Itapira, SP).

The roosters were positioned in left lateral decubitus and submitted to right wing feather removal, followed by dermal antiseptis with alcohol 70% and chlorhexidine 1% (Indústria Farmacêutica Rioquímica Ltda, São José do Rio Preto, SP).

The surgical access to the right humerus was done on right wing's dorsolateral face, and after diaphysis exposure, the complete transversal osteotomy was performed on this region with a dental saw with continuous irrigation. After stabilization of the osteotomized fragments, the PA-12 rod hydroxyapatite-coated (Figure 1A) was implanted (Figure 1B) filling all intramedullary cavity and its diameter occupying most of the humerus. With the aid of a drill machine and a 1 mm drill two perforations were made in each bone fragment (distance of 10 mm between them, in lateromedially and craniocaudally direction to the humerus), through the two corticals and, consequently, the transposition of the PA-12 rod allocated in the medullary canal. After bone perforations, the rod's locking procedure was performed with with cortical stainless steel screws (Figure 1C) of 2 mm in diameter and length according to individual need.

Figure 1. Trans-operative photographic images of a rooster's (white *Plymouth rock*) right humerus osteosynthesis. A: polyamide 12 intramedullary rod coated with hydroxyapatite; B: rod implantation (arrow) into the humerus' medullary canal (*); C: locked rod on the right humerus with two conventional cortical screws in each bone fragment.



Source: Personal Archive.

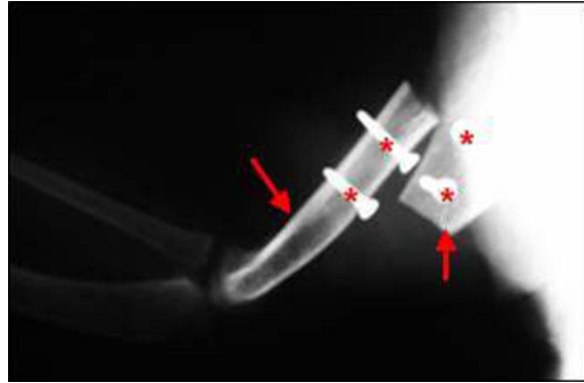
The synthesis of the adjacent soft tissues and skin was made with nylon suture thread (Shalon Medical[®], Goiânia, GO), in simple interrupted suture pattern.

The immediate post-operative analgesia was with 0,1 mg/kg of meloxicam (Ourofino Saúde Animal Ltda, Cravinhos, SP) and 1 mg/kg of butorphanol (Zoetis Indústria de Produtos Veterinários Ltda, Guarulhos, SP), both intramuscularly. Postoperatively, the animals were medicated with the same dosage of meloxicam (Ourofino Saúde Animal Ltda, Cravinhos, SP) for four consecutive days and the daily bandages were made with physiological solution (Eurofarma Laboratório S.A., Ribeirão Preto, SP) and chlorhexidine (Riohex[®] - Indústria Farmacêutica Rioquímica Ltda, São José do Rio Preto, SP).

3. Results and Discussion

The average surgery time was 40 ± 5 minutes, with no intraoperative complications and anesthetic recovery was 30 ± 5 minutes. In the immediate postoperative period, it was noticed through physical and radiographic exams that the implants had broken (Figure 2) in six animals (37,5%) right afterwards anesthetic recovery and consequent right wing movement. All other (10: 62,5%), they broke seven days after the orthopedic implantation; all them occurred next to the fracture focus.

Figure 2. Radiographic image of the right humerus of a rooster (white *Plymouth rock*) (arrows) after implant's fracture with polyamide 12 intramedullary rod coated with hydroxyapatite, pre-fixed with stainless steel screws (*).



Source: Personal Archive.

The birds were euthanized with ketamine (30 mg/kg) and xylazine (0,5 mg/kg) intramuscularly, followed by an anesthetic overload of intravenous thiopental (50 mg/kg - Cristália Produtos Químicos e Farmacêuticos Ltda, São Paulo - SP).

Studies related to the applicability of PA-12 IR coated with hydroxyapatite to osteosynthesis are scarce in the literature, especially in birds. The results of this study showed that the PA-12 IR coated with hydroxyapatite doesn't have sufficient resistance to support the forces exercised on the fracture focus. It was opted to use the PA-12 because it's a polymer of a high hardness and lightness, resistance and low cost, when compared to other polymers and, mainly, because it's biocompatible with organic tissues (Dias et al., 2018).

As Cherobini et al. (2017) and Dias et al. (2018) reported that the PA-12 IRs were promising on the birds osteosynthesis, possibly the unsatisfactory results on the present study can be attributed to the incorporation of hydroxyapatite which requires serial thermal cycles, which may have compromised the orthopedic implant resistance, making osteoinduction, osteoconduction and angiogenesis analysis impossible.

The low resistance of the PA-12 IRs may have occurred due to degradation by hydrolysis of the polymer chains, which directly compromises the functional properties (Dubin and Greenberg, 1981) of the implants, either for consecutives high temperature expositions to hydroxyapatite incorporation or sterilization cycle plus the pressure inside of the autoclave chamber. Sicard et al. (2002) also described that the heat treatment to sterilize can cause loss of polymers' dimensional stability and consequent deformations.

Another factor evolved on the unsatisfactory results of this study is probably the birds' age, since there is less bone resistance due to the predominantly organic composition with restricted mineral base (Spadeto Junior et al., 2011). Also, the fact that at this age the animals have more physical activity and constant wing movement, it may predispose to instability of the fracture focus (Alievi et al., 2008).

Regarding the orthopedics implants fractures' location, Rodrigues et al. (2009) reported that in studies with computer simulation, the areas with more tension occurs at the rod-screw interface near to the fracture focus due to the greater local mobility, corroborating with the results observed in the present study.

Unsatisfactory results were also described by Spadeto Junior et al. (2011) when analyzing three materials (polypropylene, polyacetal and polyamide) for the manufacture of IRs implanted in young bovine femurs (*ex vivo*), submitting the bones to compressive and flexion tests. The researchers reported that no material presented resistance to the analyzed variables when compared to the intact bone, although flexion force was higher in the polyamide group.

4. Final considerations

Based on the recommended methodology and obtained results, it's assumed that the hydroxyapatite incorporation to the PA-12 IRs probably compromised its resistance due to the successive thermal stages which cause polymer hydrolysis; however, further investigations will be necessary to solidify this assumption.

In front of the results obtained, it wasn't possible to confirm whether the hydroxyapatite incorporated in the polyamide 12 rod accelerates bone consolidation in young birds.

References

Alievi, M.M., Oliveira, A.N.C., Ferreira, P.A., Traesel, C., Guimarães, L.D., Flores, F., Silva, S.F. & Schossler, J.E.W. (2008). Osteossíntese de úmero em pombos domésticos (*Columbalivia*) associando-se pinos metálicos e polimetilmetacrilato intramedulares após osteotomia diafisária. *Arquivo Brasileiro de Medicina Veterinária e Zootecnia*, 60(4), 843-850. <http://www.scielo.br/pdf/abmvz/v60n4/11.pdf>.

Castro, P.F., Matera, J.M., Fantoni, D.T. & Guimarães, M.R. (2004). Uso de pino de aço intramedular na reparação de fraturas de ossos longos em psitacídeos: arara-azul

(*Anodorhynchus*), arara-canindé (*Ara ararauna*) e papagaio-verdadeiro (*Amazona aestiva*). *Clínica Veterinária*, 9(52), 56-64.

Cherobini, E.P., Carvalho, L.L., Garcia, D.O., Dias, F.G.G., Malta, C.A.S., Facin, A.C., Mattos-Junior, E., Magalhães, G.M. & Dias, L.G.G.G. (2017). Applicability of polyamide 12 intramedullary locked rods in the stabilization of induced humeral fracture in cockerels (*white plymouth rock*) - *in vivo* study. *Arquivo Brasileiro de Medicina Veterinária e Zootecnia*, 69(4), 771-776. <http://dx.doi.org/10.1590/1678-4162-9357>.

Dias, R.G., Magalhães, G.M., Dias, L.G.G., Rocha, J.R., Dias, F.G.G., Facin, A. C. & Mattos Júnior, E. (2018). Biocompatibility of polyamide 12 intramedullary rod after humeral consolidation in white *Plymouth Rock* birds. *Pesquisa Veterinária Brasileira*, 38(10), 1909-1912. <https://doi.org/10.1590/1678-5150-pvb-5776>.

Dubin, S. & Greenberg, A. (1981). Effect of repeated sterilization on the breaking strength of synthetic polyfilament suture. *Journal of the American Veterinary Medical Association*, 178(11), 1162.

Gouvêa, A.S., Alievi, M.M., Noriega, V., Dal-Bó, I.S., Pinto, T.M., Menezes, C.L.M., Silva, R.B., Silva, L.M., Velasque, A.G., Pinto, L.A.T. & Coelho, A.J.A. (2011). Microplacas de titânio em fraturas de tibiotarso em pombos domésticos. *Ciência Rural*, 41(3), 476-482. <https://doi.org/10.1590/S0103-84782011000300018>.

Liu, W., Wang, T., Yang, C., Darvell, B.W., Wu, J., Lin, K., Chang, L., Pan, H. & Lu, W.W. (2016). Alkaline biodegradable implants for osteoporotic bone defects-importance of microenvironment pH. *Osteoporosis International*, 27(1), 93-104. Doi: 10.1007/s00198-015-3217-8.

Pereira, A.S., Shitsuka, D.M., Parreira, F.J., Shitsuka, R. (2018). *Metodologia da Pesquisa Científica*. 1. ed. Universidade Federal de Santa Maria. Ed. UAB/NTE/UFSM. Disponível em: https://repositorio.ufsm.br/bitstream/handle/1/15824/Lic_Computacao_Metodologia_Pesquisa-Cientifica.pdf?sequence=1. Acesso em: 25 Abril de 2020.

Piattelli, A., Scarano, A., Piattelli, M., Caraggio, F. & Matarasso, S. (2000). Bone regeneration using bioglass: an experimental study in rabbit tibia. *Journal of Oral Implantology*, 26(1), 257-261. Doi:10.1563/1548-1336(2000)026<0257:brubae>2.3.co;2.

Rodrigues, L.B., Lopes, D.S., Folgado, J., Fernandes, P.R., Pires, E.B., Las Casas, E.B. & Faleiros, R.R. (2009). Bone remodeling analysis of a bovine femur for a veterinary implant design. *Computer Methods in Biomechanics and Biomedical Engineering*, 12(6), 683-690.

Sicard, G.K., Haashi, K. & Anley, P.A. (2002). Evaluation of 5 types of fishing material, 2 sterilization methods, and a crimp-clamp system for extra-articular stabilization of the canine stifle joint. *Veterinary Surgery*, 31(1), 78-84. doi:10.1053/jvet.2002.30539.

Spadeto Júnior, O., Rodrigues, L.B., Carvalho, W.T.V., Moreira, D. O., De Marval, C.A., Costa, C.G., Alves, G.E.S., Las Casas, E.B. & Faleiros, R.R. (2011). Sistemas osso-implante *ex vivo* utilizando haste intramedular polimérica para imobilização de fraturas femorais em bovinos jovens. *Ciência Rural*, (41)2, 301-306. <https://doi.org/10.1590/S0103-84782011000200020>.

Percentage of contribution of each author in the manuscript:

Fernanda Gosuen Gonçalves Dias - 20%

Leonardo Lamarca de Carvalho - 30%

Luis Gustavo Gosuen Gonçalves Dias - 20%

Vitória Ferreira Nogueira de Paula Fontes - 10%

Ewaldo de Mattos Junior - 20%