

Assessment of the location and extent of bone erosions in mandibular condyles using multislice computed tomography

Avaliação da localização e extensão das erosões ósseas em côndilos mandibulares usando tomografia computadorizada multislice

Evaluación de la localización y extensión de las erosiones óseas en los cóndilos mandibulares mediante tomografía computarizada multislice

Received: 11/03/2022 | Revised: 11/20/2022 | Accepted: 12/22/2022 | Published: 12/25/2022

Victória de Oliveira Ushli

ORCID: <https://orcid.org/0000-0003-0717-6749>

Universidade de São Paulo, Brazil

E-mail: victoria.ushli@usp.br

Marcelo Eduardo Pereira Dutra

ORCID: <https://orcid.org/0000-0001-5810-1574>

Universidade de São Paulo, Brazil

E-mail: marceloepdutra@bol.com.br

Wladimir Gushiken de Campos

ORCID: <https://orcid.org/0000-0002-2086-3087>

Universidade de São Paulo, Brazil

E-mail: wgushiken@hotmail.com

Celso Augusto Lemos Júnior

ORCID: <https://orcid.org/0000-0002-3372-6719>

Universidade de São Paulo, Brazil

E-mail: calemosj@usp.br

Jefferson Xavier Oliveira

ORCID: <https://orcid.org/0000-0002-8684-142X>

Universidade de São Paulo, Brazil

E-mail: jexolive@usp.br

Abstract

Erosion is an area of decreased density, discontinuity, or irregularity of the cortical bone, including the mandibular condyle. This study aimed to assess the location and extent of condyle bone erosion using multislice CT. CT images of 82 TMJ were evaluated from 41 symptomatic patients by two observers. The agreement between both observers was measured through the Kappa coefficient. Bone erosion in the condyle occurred as the following: anterior 1.2% (1 case); superior 62.2% (51 cases); no change 18.3% (15 cases); posterior and superior 12.2% (10 cases); superior and posterior 3.7% (3 cases); superior, anterior, and posterior 2.4% (2 cases). The prevalence of erosion in the condyle occurs predominantly on the upper aspect, with 80.5% of the cases.

Keywords: Mandibular condyle; Temporomandibular joint; Temporomandibular joint disorders; Spiral cone-beam computed tomography.

Resumo

A erosão é uma área de densidade diminuída, descontinuidade ou irregularidade do osso cortical, incluindo o côndilo mandibular. Este estudo teve como objetivo avaliar a localização e extensão da erosão óssea do côndilo usando TC multislice. Imagens de TC de 82 ATMs foram avaliadas de 41 pacientes sintomáticos por dois observadores. A concordância entre os dois observadores foi medida por meio do coeficiente Kappa. A erosão óssea no côndilo ocorreu da seguinte forma: anterior 1,2% (1 caso); superior 62,2% (51 casos); sem alteração 18,3% (15 casos); posterior e superior 12,2% (10 casos); superior e posterior 3,7% (3 casos); superior, anterior e posterior 2,4% (2 casos). A prevalência de erosão no côndilo ocorre predominantemente na face superior, com 80,5% dos casos.

Palavras-chave: Côndilo mandibular; Articulação temporomandibular; Transtornos da articulação temporomandibular; Tomografia computadorizada de feixe cônico espiral.

Resumen

La erosión es un área de disminución de la densidad, discontinuidad o irregularidad del hueso cortical, incluido el cóndilo mandibular. Este estudio tuvo como objetivo evaluar la ubicación y el alcance de la erosión ósea del cóndilo mediante TC multicorte. Dos observadores evaluaron imágenes de TC de 82 TMJ de 41 pacientes sintomáticos. La concordancia entre ambos observadores se midió a través del coeficiente Kappa. La erosión ósea en el cóndilo se

presentó de la siguiente manera: anterior 1,2% (1 caso); superior 62,2% (51 casos); sin cambio 18,3% (15 casos); posterior y superior 12,2% (10 casos); superior y posterior 3,7% (3 casos); superior, anterior y posterior 2,4% (2 casos). El predominio de erosión en el cóndilo se presenta predominantemente en la cara superior, con un 80,5% de los casos.

Palabras clave: Cóndilo mandibular; Articulación temporomandibular; Trastornos de la articulación temporomandibular; Tomografía computarizada de haz cónico espiral.

1. Introduction

Examination modalities through images of the temporomandibular joint (TMJ) have evolved over the last decade. With the advent of new techniques and improvements in technology, TMJ images could be better evaluated in terms of their anatomy and function. The correlation between images and clinical findings has led to a better understanding of the pathophysiology of temporomandibular disorders. Many techniques can be used to examine the TMJ, including conventional radiography, multi-slice computed tomography (CT), cone-beam CT and arthrographies. However, CT stands out mainly when studies of anatomical repairs and degenerative processes that affect the components of the joints are needed. (D. e. S. Campos et al., 2021; Lewis et al., 2008; Meral et al., 2022)

Temporomandibular disorders have presented frequent complaints to clinicians and are characterized by their multifactorial aspects associated with anatomical, functional and environmental changes, especially stress. (Ayyıldız et al., 2021; Bae et al., 2017; Tsai et al., 2021)

Degenerative joint diseases can cause synovial inflammation, remodeling, and bone degenerations characterized by osteophyte development, erosion, flattening, subchondral sclerosis, and pseudocysts. Erosion is an area of decreased density, discontinuity, or irregularity of the cortical bone that may evolve. (de Holanda et al., 2018; Leite-de-Lima et al., 2022; Yun et al., 2021)

Therefore, early erosion diagnosis can prevent the degenerative condition's eventual progression. Such a feat becomes possible with the use of multislice CT, which can obtain thin and, at the same time, excellent quality slices. The initial slices are recombined, forming new images of the anatomical structures with superior fidelity and detail, which enable the diagnosis even in the early stages of the lesion. (Emshoff et al., 2021; Koshal et al., 2021; Lewis et al., 2008)

Honda et al. (2006) evaluated bone anomalies of the mandibular condyle by CT, concluding that spiral CT is a highly reliable method for assessing and diagnosing cortical erosions of the mandibular condyle. (Honda et al., 2006) Furthermore, Marques et al. (2021) concluded that digital image filters do not improve the diagnosis of bone abnormalities in the temporomandibular joint on multislice CT. (Marques et al., 2021) Additionally, Reis et al. (2022) stated that acquisition protocols (voxel size and mA) and jaw position (closed and open) did not influence the detection of TMJ degenerative joint disease changes alterations. (de Oliveira Reis et al., 2022)

Hence, this study aimed to assess the location and extent of condyle bone erosion using multislice CT.

2. Methodology

CT images of 82 TMJ were evaluated from 41 symptomatic patients referred to a private radiology service by physicians and dentists for imaging evaluation. Images of patients with at least one sign and/or symptom reported in the clinical examination performed by the requesting professional were included in the study.

Two observers analyzed the images at a time interval of 30 days. The agreement between both observers was measured through the Kappa coefficient.

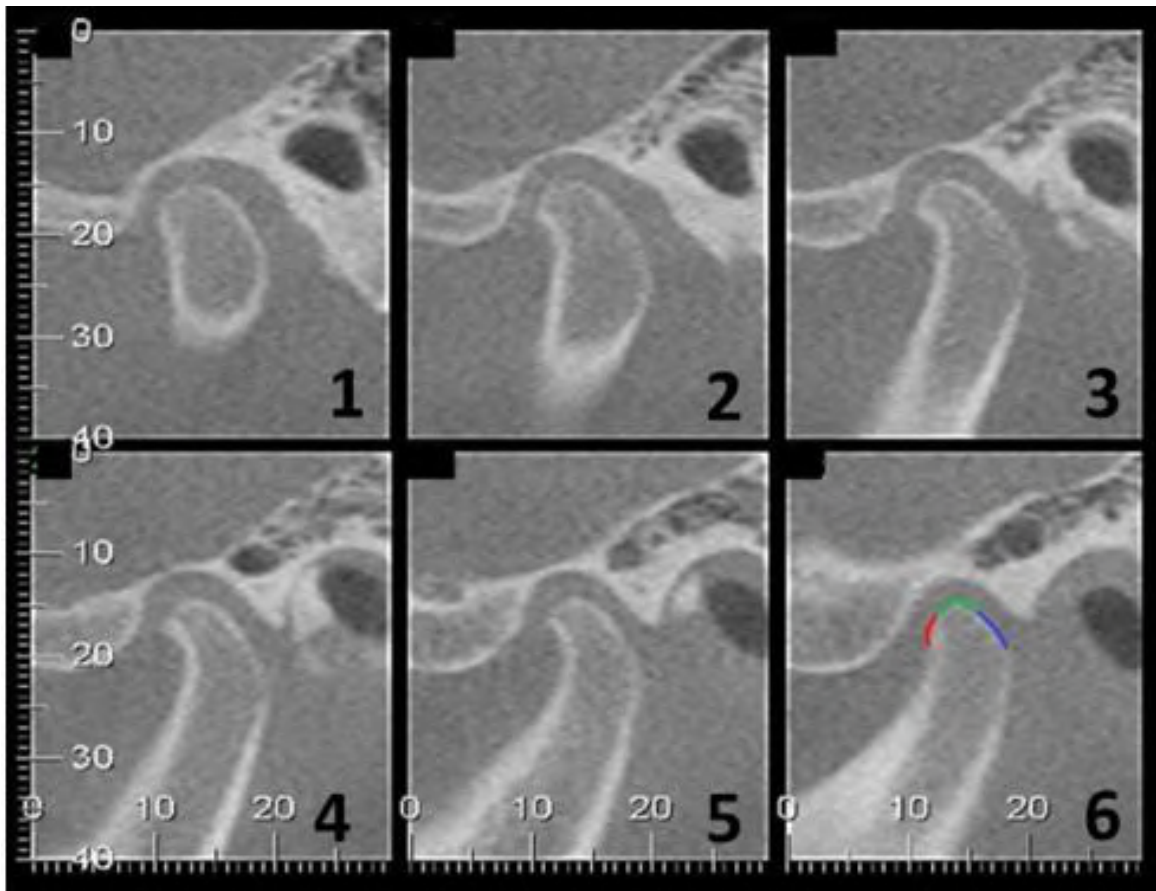
A 64-channel CT device (GE Medical Systems® - Little Chalfont, United Kingdom) was used. The electronically stored sagittal and coronal image sequences were evaluated. The files were electronically recorded on a data cloud in DICOM

(Digital Imaging and Communication in Medicine) format from a workstation equipped with a high-resolution graphic electronic program for typing and manipulation (Easy-Vision® Phillips – AP8000).

An iMac computer (Mac OsX 10.6, Apple, Inc., Cupertino, USA) was used to analyze the images, 2.5GHz processor, 4GB of memory, 500GB of RAM, with a 21.5-inch screen, resolution of 1920x1080 pixels. Osirix MD software (Apple Inc, version 3.9.4, 32 Bits - Pixmeo, Geneva, Switzerland) was used.

Erosion was classified according to its location on the condyle (anterior, superior, or posterior). (Figure 1)

Figure 1 - Different sagittal computed tomography sections of the condyle region. 6) shows the division of the condyle into anterior (red), superior (green) and posterior (blue) aspects.



Source: Authors.

3. Results

Through the analysis of the Kappa coefficient, we obtained a result of the detailed comparison of 0.797 between the first and second observers of the images, a value classified as good in the Kappa index. Considering only the macro comparison, the presence or absence of erosion regardless of the aspect on which it was located, a better result was found (0.874), classified as excellent. (Table 1)

Table 1 - Agreement between observers.

Macro	Detailed			
	Kappa	P-value	Kappa	P-value
Condylar erosion	0,874	<0,001	0,797	<0,001

Source: Authors.

The sample of this study was composed mostly of women, and the average age found was 41.71 years old, with the minimum age found being 18 years old and the maximum being 83 years old. (Table 2)

Table 2 - Descriptive statistics.

Age	
Mean	41,71
Media	38
Standard deviation	16,04
CV	38%
Q1	32
Q3	50
Min	18
Max	83
N	41
CI	4,91

Legend: Coefficient of variation (CV); First Quantile (Q1); Third Quantile (Q3); Minimum age (Min); Maximum Age (Max); Number of patients (N); Confidence Interval (CI). Source: Authors.

When analyzing the presence and location of bone erosion in the condyle, in the anterior, superior and posterior aspects, we came across the following results: anterior 1.2% (1 case); superior 62.2% (51 cases); no change 18.3% (15 cases); posterior and superior 12.2% (10 cases); superior and posterior 3.7% (3 cases); superior, anterior and posterior 2.4% (2 cases). Thus, the most prevalent response was erosion in the superior aspect of the condyle in 62.2% of the evaluated TMJs, being statistically significant compared to the other responses. (Table 3)

Table 3 - Distribution of condylar erosion.

Condylar erosion	N	%	P-value
Anterior	1	1,2%	<0,001
No change	15	18,3%	<0,001
Posterior Superior	10	12,2%	<0,001
Posterior Superior Anterior	2	2,4%	<0,001
Superior	51	62,2%	Ref.

Source: Authors.

4. Discussion

Although it is widely used in dental diagnostics, cone beam computed tomography presents very similar results to CT, being more advantageous only in relation to the lower cost and lower dose of irradiation per exam, according to Lewis et al. (2008) (Lewis et al., 2008). Thus, the literature is much richer in cone-beam than CT. Honda et al. (2006) (Honda et al., 2006) compared the diagnostic efficiency between helical and cone-beam CT based on autopsy material and concluded that there was no significant difference between the two modalities for detecting mandibular condyle abnormalities, which validates our CT study. Cara et al. (2017) (Cara et al., 2007) concluded that all CT imaging protocols accurately assess TMJ changes.

In this study, 81.7% of the evaluated mandibles presented some type of erosion, which disagrees with other related studies. Campos et al. (2008) (M. I. G. Campos et al., 2008) analyzed magnetic resonance imaging (MRI) and pain in TMJs with or without degenerative changes in the condyle of the mandible, such as erosion, osteophyte, avascular necrosis, and subchondral cyst. In their results, only 16% of the mandibles showed erosion.

Gil et al. (2012) (Gil et al., 2012) analyzed the relationship between bone changes in the TMJ and the position of the articular disc in symptomatic patients utilizing MRI, they found erosion in only 13.6% of the studied mandibles; a low percentage also compared to the present study. Koyama et al. (2007) (Koyama et al., 2007) studied bone alterations in the region of interest in TMJ patients using CT and concluded that erosion is the most frequent alteration in TMJ patients. In their results, 33% of the studied mandibles presented some erosion, a much lower number than our study, representing practically twice the frequencies found by Campos (M. I. G. Campos et al., 2008) and Gil (Gil et al., 2012).

Holanda et al. (2018) (de Holanda et al., 2018) and colleagues studying the prevalence of morphological changes in the TMJ of asymptomatic volunteers using cone-beam computed tomography had results that show a high prevalence of morphological changes, which are almost always associated with the presence of degenerative diseases in the joint. For Bae et al. (2017) (Bae et al., 2017), there is a relationship between the presence of joint pain and degenerative changes in the TMJ. In the sample analyzed by us, all patients had at least one sign and symptom of the TMJ. Still, it was impossible to establish a relationship between these changes and the patients' complaints, as Emshoff. et al (2016) (Emshoff et al., 2016) reported, where the relationship between erosion and chronic arthralgia has been reported. Bone changes were more prevalent in women, which agrees with our data, individuals with fewer teeth and older individuals. In their results, despite erosion being the second most frequent finding in the condyle head, only 12.69% of the sample presented this alteration, while in our evaluation, 71.7%.

Regarding the location of the erosion present on the mandible condyles (Table 3), the most prevalent aspect was the upper one, found alone in 62.2% of the analyzed ATMs. However, if we add up all the situations involving erosion on the upper aspect, the upper erosion itself and the upper anterior, posterior-anterior, and superior anterior and posterior erosions, its

prevalence was 80.5%. Erosion on the posterior aspect was the second most prevalent, appearing in 14.6% of cases in two forms: erosion found in the entire head of the mandible, that is, in the three aspects (2.4%) and erosion in the posterior aspect, accompanied by erosion on the upper aspect (12.2%). The literature on bone erosion in mandibles is poor concerning its location on the three aspects.

Since no alteration was found in only 18.3% of the cases, we assume that erosion is a very frequent bone alteration in symptomatic patients.

5. Conclusion

The prevalence of the location of erosion in the condyle occurs predominantly on the upper aspect, being present in 80.5% of the cases, followed by the posterior aspect, where erosion is present in 14.6% of all TMJs analyzed.

References

- Ayyıldız, E., Orhan, M., Bahşi, İ., & Yalçın, E. D. (2021). Morphometric evaluation of the temporomandibular joint on cone-beam computed tomography. *Surgical and Radiologic Anatomy*, 43(6), 975–996. <https://doi.org/10.1007/s00276-020-02617-1>
- Bae, S., Park, M.-S., Han, J.-W., & Kim, Y.-J. (2017). Correlation between pain and degenerative bony changes on cone-beam computed tomography images of temporomandibular joints. *Maxillofacial Plastic and Reconstructive Surgery*, 39(1), 1–6. <https://doi.org/10.1186/s40902-017-0117-1>
- Campos, D. S., de Araújo Ferreira Muniz, I., de Souza Villarim, N. L., Ribeiro, I. L. A., Batista, A. U. D., Bonan, P. R. F., & de Sales, M. A. O. (2021). Is there an association between rheumatoid arthritis and bone changes in the temporomandibular joint diagnosed by cone-beam computed tomography? A systematic review and meta-analysis. *Clinical Oral Investigations*, 25(5), 2449–2459. <https://doi.org/10.1007/s00784-021-03817-8>
- Campos, M. I. G., Campos, P. S. F., Cangussu, M. C. T., Guimarães, R. C., & Line, S. R. P. (2008). Analysis of magnetic resonance imaging characteristics and pain in temporomandibular joints with and without degenerative changes of the condyle. *Int J Oral Maxillofac Surg*, 37(6), 529–534. <http://dx.doi.org/10.1016/j.ijom.2008.02.011>
- Cara, A. C. B., Gaia, B. F., Perrella, A., Oliveira, J. X. O., Lopes, P. M. L., & Cavalcanti, M. G. P. (2007). Validity of single- and multislice CT for assessment of mandibular condyle lesions. *Dentomaxillofacial Radiology*, 36(1), 24–27. <https://doi.org/10.1259/dmfr/54883281>
- de Holanda, T., de Almeida, R., Silva, A., Damian, M., & Boscato, N. (2018). Prevalence of Abnormal Morphology of the Temporomandibular Joint in Asymptomatic Subjects: A Retrospective Cohort Study Utilizing Cone Beam Computed Tomography. *The International Journal of Prosthodontics*, 31(4), 321–326. <https://doi.org/10.11607/ijp.5623>
- de Oliveira Reis, L., Gaêta-Araujo, H., Rosado, L. P. L., Mouzinho-Machado, S., Oliveira-Santos, C., Freitas, D. Q., & Correr-Sobrinho, L. (2022). Do cone-beam computed tomography low-dose protocols affect the evaluation of the temporomandibular joint? *Journal of Oral Rehabilitation*, September 2022, 1–11. <https://doi.org/10.1111/joor.13381>
- Emshoff, R., Bertram, A., Hupp, L., & Rudisch, A. (2021). A logistic analysis prediction model of TMJ condylar erosion in patients with TMJ arthralgia. *BMC Oral Health*, 21(1), 1–9. <https://doi.org/10.1186/s12903-021-01687-w>
- Emshoff, R., Bertram, F., Schnabl, D., Stigler, R., Steinmaßl, O., & Rudisch, A. (2016). Condylar Erosion in Patients With Chronic Temporomandibular Joint Arthralgia: A Cone-Beam Computed Tomography Study. *Journal of Oral and Maxillofacial Surgery*, 74(7), 1343.e1-1343.e8. <https://doi.org/10.1016/j.joms.2016.01.029>
- Gil, C., Santos, K. C. P., Dutra, M. E. P., Kodaira, S. K., & Oliveira, J. X. (2012). MRI analysis of the relationship between bone changes in the temporomandibular joint and articular disc position in symptomatic patients. *Dentomaxillofac Radiol*, 41(5), 367–372. <http://dx.doi.org/10.1259/dmfr/79317853>
- Honda, K., Larheim, T. A., Maruhashi, K., Matsumoto, K., & Iwai, K. (2006). Osseous abnormalities of the mandibular condyle: Diagnostic reliability of cone beam computed tomography compared with helical computed tomography based on an autopsy material. *Dentomaxillofacial Radiology*, 35(3), 152–157. <https://doi.org/10.1259/dmfr/15831361>
- Koshal, N., Patil, D., Laller, S., Malik, M., Punia, R., & Sawhney, H. (2021). Assessment of correlation between bone quality and degenerative bone changes in temporomandibular joint by computed tomography -A retrospective study. *Journal of Indian Academy of Oral Medicine and Radiology*, 33(4), 364–371. https://doi.org/10.4103/jiaomr.jiaomr_230_21
- Koyama, J. I., Nishiyama, H., & Hayashi, T. (2007). Follow-up study of condylar bony changes using helical computed tomography in patients with temporomandibular disorder. *Dentomaxillofacial Radiology*, 36(8), 472–477. <https://doi.org/10.1259/dmfr/28078357>
- Leite-de-Lima, N. S., Duailibi-Neto, E. F., Chilvarquer, I., & Luz, J. G. C. (2022). Cone-beam computed tomography analysis of degenerative changes, condylar excursions and positioning and possible correlations with temporomandibular disorder signs and symptoms. *Brazilian Journal of Oral Sciences*, 21, 1–15. <https://doi.org/10.20396/bjos.v21i00.8665442>
- Lewis, E. L., Dolwick, M. F., Abramowicz, S., & Reeder, S. L. (2008). Contemporary Imaging of the Temporomandibular Joint. *Dental Clinics of North America*, 52(4), 875–890. <https://doi.org/10.1016/j.cden.2008.06.001>

Marques, L. M., Costa, A. L. F., Baeder, F. M., Corazza, P. F. L., Silva, D. F., Albuquerque, A. C. L. de, Junqueira, J. L. C., & Panzarella, F. K. (2021). Digital image filters are not necessarily related to improvement in diagnostic of degenerative bone changes in the temporomandibular joint on cone beam computed tomography. *Research, Society and Development*, 10(4), e44010414296. <https://doi.org/10.33448/rsd-v10i4.14296>

Meral, S. E., Karaaslan, S., Tüz, H. H., & Uysal, S. (2022). Evaluation of the temporomandibular joint morphology and condylar position with cone-beam computerized tomography in patients with internal derangement. *Oral Radiology*. <https://doi.org/10.1007/s11282-022-00618-x>

Tsai, C. M., Chai, J. W., Wu, F. Y., Chen, M. H., & Kao, C. T. (2021). Differences between the temporal and mandibular components of the temporomandibular joint in topographic distribution of osseous degenerative features on cone-beam computerized tomography. *Journal of Dental Sciences*, 16(3), 1010–1017. <https://doi.org/10.1016/j.jds.2020.12.010>

Yun, J. M., Choi, Y. J., Woo, S. H., & Lee, U. L. (2021). Temporomandibular joint morphology in Korean using cone-beam computed tomography: influence of age and gender. *Maxillofacial Plastic and Reconstructive Surgery*, 43(1). <https://doi.org/10.1186/s40902-021-00307-5>