

Association between reproductive disorders in pet females (Mammalia) and the development of hydrometra: an integrative literature review

Associação entre afecções reprodutivas em fêmeas (Mammalia) de companhia e o desenvolvimento de hidrometra: uma revisão integrativa da literatura

Asociación entre los trastornos reproductivos de las hembras de animales (Mammalia) de compañía y el desarrollo de hidrometra: una revisión bibliográfica integradora

Received: 11/07/2022 | Revised: 11/14/2022 | Accepted: 11/14/2022 | Published: 11/20/2022

Heitor Leocádio de Souza Rodrigues

ORCID: <https://orcid.org/0000-0002-7855-8640>

Universidade Federal de Uberlândia, Brasil

E-mail: heitor1605@hotmail.com

Fernanda Vianna Borges

ORCID: <https://orcid.org/0000-0002-2233-9377>

Universidade Federal de Uberlândia, Brasil

E-mail: fviannab@gmail.com

Lucas Maurício Lopes Navasquez

ORCID: <https://orcid.org/0000-0001-5891-5586>

Universidade Federal de Uberlândia, Brasil

E-mail: lucas.navasquez@gmail.com

Laís de Deus Sousa

ORCID: <https://orcid.org/0000-0002-6911-5282>

Universidade Federal de Uberlândia, Brasil

E-mail: laisdedeussousa@gmail.com

Vinicius José de Oliveira

ORCID: <https://orcid.org/0000-0003-2632-4129>

Universidade Federal de Uberlândia, Brasil

E-mail: [vet.viniciuss@gmail.com](mailto:veter.viniciuss@gmail.com)

Abstract

The estrous cycle is related to the reproduction of a female. However, some diseases directly interfere in the reproductive cycle, an example is the hydrometra, a disease in which occurs the deposition of aseptic and translucent fluid in the lumen of the uterus and that may indirectly interfere in the cyclicity and reproductivity of a female. Given the above, the objective of this integrative review was to identify alterations in organs of the reproductive tract of pet females that favor the development of a hydrometric condition. This is an integrative review of the literature. We selected 14 articles that reported or addressed the theme of hydrometra in pet females (bitches, cats and rabbits). After the selection of the articles, relevant clinical information that may influence the development of hydrometra was extracted. The main conditions related to hydrometra were found in the literature: ectopic location of ureters within the uterus wall and vagina; canine Gartner duct cyst with renal agenesis; urolithiasis; perineal and inguinal hernias; uterine aplasia; remnant ovary syndrome; adenoma and proliferative polyps in the endometrium; teratoma; uterine torsions and adenocarcinoma. Some authors report the importance of control in the use of exogenous progestins since the chronic stimulation of estrogen receptors in the uterine tissue may influence the increased production of intraluminal fluid. Finally, the importance of veterinary monitoring of animals in reproductive age and attitude for early diagnosis of disease and promotion of health and quality of life to females is highlighted.

Keywords: Female; Hydrometrics; Veterinary medicine; Teriogenology.

Resumo

O ciclo estral está relacionado com a reprodutividade de uma fêmea. No entanto, algumas afecções interferem diretamente no seu ciclo reprodutivo, um exemplo é a hidrometra, enfermidade em que ocorre a deposição de líquido asséptico e translúcido no lúmen do útero e que pode, indiretamente, interferir na ciclicidade e reprodutividade de uma fêmea. Diante do exposto, o objetivo dessa revisão integrativa foi identificar alterações de órgãos do trato reprodutivo de fêmeas de companhia que favorecem o desenvolvimento de um quadro de hidrometra. Trata-se de uma revisão integrativa da literatura. Foram selecionados 14 artigos que relatavam ou abordavam a temática da hidrometra em fêmeas de companhia (cadelas, gatas e coelhas). Após a seleção dos artigos, foi realizada a extração de informações clínicas relevantes que podem inferir no desenvolvimento da hidrometra. Foram encontradas na literatura as principais afecções relacionadas com a hidrometra: localização ectópica de ureteres dentro da parede do útero e vagina; cisto

canino do ducto de *Gartner* com agenesia renal; urolítiase; hérnias perineal e inguinal; aplasias uterinas; síndrome do ovário remanescente; adenoma e pólipos proliferativos no endométrio; teratoma; torções uterinas e adenocarcinoma. Alguns autores relatam a importância do controle no uso de progestágenos exógenos uma vez que o estímulo crônico dos receptores de estrogênio no tecido uterino pode influenciar no aumento da produção de fluido intraluminal. Por fim, salienta-se a importância do acompanhamento veterinário de animais em idade e atitude reprodutiva para diagnóstico precoce de afecção e promoção de saúde e qualidade de vida às fêmeas.

Palavras-chave: Fêmeas; Hidrometra; Medicina veterinária; Teriogenologia.

Resumen

El ciclo estral está relacionado con la reproducción de una hembra. Sin embargo, algunas enfermedades interfieren directamente en el ciclo reproductivo, un ejemplo es la hidrometra, una enfermedad en la que se produce la deposición de líquido aséptico y translúcido en el lumen del útero y que puede interferir indirectamente en la ciclicidad y reproductividad de una hembra. Además de la exposición, el objetivo de esta revisión integradora fue identificar las alteraciones de los órganos del tratamiento reproductivo de las fiebres de compañía que favorecen el desarrollo de un cuadrado de hidrometra. Se trata de una revisión bibliográfica integradora. Se han seleccionado 14 artículos que relatan o abordan la temática de la hidrometra en las fiestas de empresa (cadelas, gatas y coelhas). Tras la selección de los artículos, se extrajo la información clínica relevante que pudiera interferir en el desarrollo de la hidrometra. En la literatura se encontraron las principales afecciones relacionadas con la hidrometra: localización ectópica de uréteres dentro de la pared del útero y la vagina; quiste del conducto de Gartner canino con agenesia renal; urolitiasis; hernias perineales e inguinales; aplasia uterina; síndrome de ovario remanente; adenoma y pólipos proliferativos en el endometrio; teratoma; torsiones uterinas y adenocarcinoma. Algunos autores señalan la importancia de controlar el uso de progestágenos exógenos, ya que la estimulación crónica de los receptores de estrógenos en el tejido uterino puede influir en el aumento de la producción de líquido intraluminal. Por último, se destaca la importancia del seguimiento veterinario de los animales en edad reproductiva y la actitud ante el diagnóstico precoz de enfermedades y la promoción de la salud y la calidad de vida de las hembras.

Palabras clave: Hembra; Hidrometría; Medicina veterinaria; Teriogenología.

1. Introduction

The estral cycle is related to physiological stages mediated by neuroendocrine stimuli responsible for conferring to a female the ability to reproduce (Hafez et al., 2004). This need for knowledge about the reproductive biology of females holds an opportunity for the development of pharmacological agents aimed at the manipulation or inhibition of the estral cycle of each species (Silva, 2016).

In bitches, the estrous cycle has certain peculiarities that differ from other domestic species. They are monoestrous, typically non-seasonal, polytocous, spontaneous ovulators, their lutein phase like pregnant and non-pregnant individuals, and they have a long period of quiescence or anestrous between cycles; except for the Basenji breed, which has long estrous cycles (Derussi & Lopes, 2009; Concannon, 2011). The canine cycle is divided into 4 phases: proestrus, estrus, metestrus ('diestrus' - the post-estrus portion of the luteal phase), and anestrus typically lasting 80–240 days (Concannon, 2011; Nogueira et al., 2019). Another peculiarity is that during estrus, the dominant hormone is progesterone, while in other domestic species estrogen predominates at this stage (Carvalho et al., 2020).

The domestic cat is classified as being seasonally polyestrous and a long-day breeder. The seasonality is related to the light duration because the cat is positive photoperiodic (Michel, 1993; Silva, 2020). The cycle in queens includes proestrus, estrus, metestrus, diestrus, and anestrus; if ovulation does not occur, the cat will enter the interestrus (Silva, 2020). Traditionally, female cats are described as induced ovulators. Ovulation should not occur unless mating or a similar stimulus induces it (Chatdarong, 2003). Queens cycle repeatedly during the breeding season unless interrupted by pregnancy or pseudopregnancy. In the estrus, ovulation induced by coitus at the time of copulation, occurs the secretion of luteinizing hormone (LH) preceded by ovulation (Brown, 2006).

The rabbits have peculiar and irregular reproductive cycles when compared to the cycle of other females, and their ovulation is induced by a mechanical stimulus in the clitoris (Ferreira et al., 2012). Thus, its cycle lasts 16 days and is

composed of proestrus, estrus and if there is copulation, it can ovulate or not, if not ovule, the rabbit will manifest a pseudopregnancy and will have follicular regression (Jaruche, 2014).

Among the conditions that affect the reproductive tract of females associated with other clinical disorders that can interfere with the reproductive cycle, hydrometra stands out, a condition in which aseptic and translucent fluid is deposited in the lumen of the uterus (Johnston et al., 2001b; Pretzer, 2008). The main etiology of this alteration is cystic endometrial hyperplasia (HEC), which, in turn, consists of a hormone-dependent uterine alteration that considerably increases the secretory activity of the endometrial glands (Nascimento & Santos, 2003).

Secretory activity of the endometrial glands and reduction of myometrial activity is promoted by progesterone concentrations in the female's body (Fossum, 2014). Conditions of high concentrations of exogenous progestogen, induced by the administration of contraceptive drugs, for example, may promote uterine alterations, such as tissue thickening, leaving it edematous and with lymphocytic infiltrate and plasma cells, besides making the uterine glandular part cystic (Fossum, 2014; Chaves et al., 2020). Another bias related to this context lies in the deposition of sterile fluid in the uterine lumen whose drainage becomes impossible due to the inhibition of myometrium contractility by the action of progesterone, characterizing a hydrometra picture (Pretzer, 2008).

Thus, the objective of this integrative review was to identify alterations in organs of the reproductive tract of pet females that favor the development of a hydrometra.

2. Methodology

Evidence-based practice, based on the analysis of published studies, is a basic condition for the development of a reliable scientific reflection that will act as a moderator in decision-making (Barroso et al., 2020). Therefore, integrative reviews of the literature are an excellent choice for the above-mentioned purposes because it combines data from the theoretical and empirical literature, providing a more complete understanding of the theme of interest (Mendes et al., 2008).

The present study was developed in the form of an empirical integrative review of the literature according to the guidelines established by Joanna Briggs Institute Manual for Evidence Synthesis (Lockwood et al., 2020). Initially, the following research-based question was formulated according to the acronym PICO (*Population, Interest phenomenon, Context*): "What are the reproductive disorders that are related to hydrometra in pet females?"

Searches in the electronic databases of Medline (PubMed), Scielo, and Google Scholar literature took place between August 2022 and October 2022. The descriptors "*Hidrometra/Hydrometra*", "*Animais de Companhia/Animals, Companion OR Pets*", "*Fêmeas/Females*", and "*Mammalia*" were used, present in the *Descritores em Ciências da Saúde* (DeCS) and Medical Subject Headings (MeSH), combined with the Boolean operator "AND", whose search was limited to articles in Portuguese and English. No publication deadline was set so that we could cover as many articles/case reports as possible. This stage was performed by two authors independently. All articles addressing the theme were included.

Included in this review were all case reports on the diagnosis of hydrometra in mammalian females of companion animals made available in full by the search engines. Papers reporting hydrometric cases in domestic females that are not companion animals, such as cows, mares, goats, and sheep; as well as reports in wild felid females were excluded. In addition, articles describing studies in experimental models; letters to the editor, opinion articles, literature reviews, monographs, dissertations, and theses; articles without access to the full text; and those repeated by overlapping keywords were excluded.

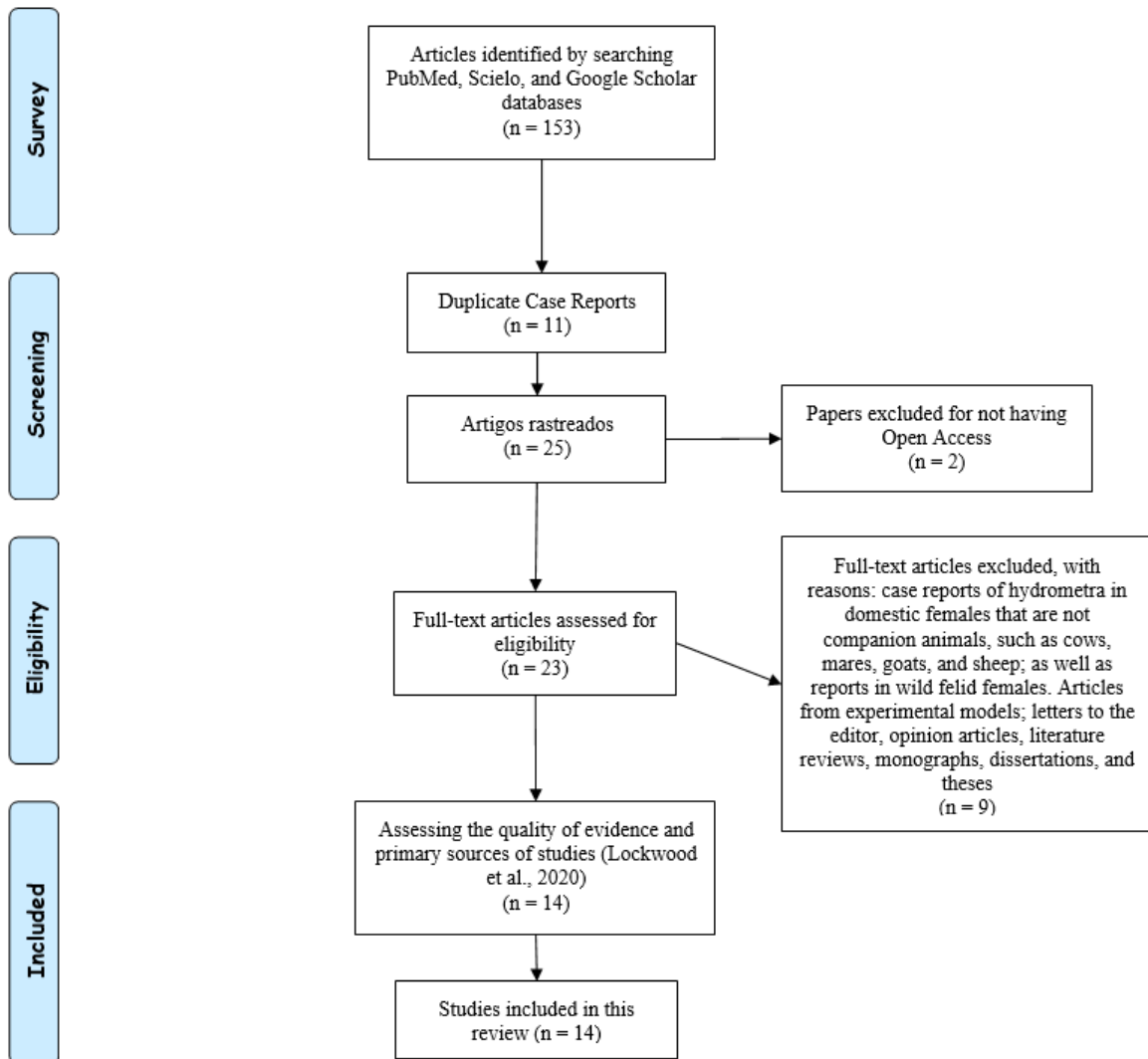
The articles pre-selected from the titles and abstracts were read in full. Thus, 14 articles were included in this review (Lapish, 1985; Macun & Özyurtlu, 2004; Oh et al., 2005; Payan-Carreira et al., 2006; Almeida et al., 2010; Sontas et al., 2013; Na & Choi, 2014; Kim et al., 2015; Fujita et al., 2016; Hristov et al., 2017; Chaves et al., 2019; Morales-Salinas et al., 2019; Machado et al., 2020; Holzlsauer et al., 2022). After this process, the articles were categorized, allowing the gathering of

information such as the description of the clinical case, present conditions of females, findings of clinical, laboratory, imaging, and necropsy examinations, discussion of the points that can infer in the development of hydrometra and/or diseases.

To evaluate the quality of evidence and primary sources of the studies (Whittemore et al., 2014) that were inserted in the final *corpus* of the analysis, the guidelines established by Joanna Briggs Institute Manual for Evidence Synthesis (Lockwood et al., 2020) were followed. Based on this, all selected articles present the level of quality of 4D evidence, because they are composed of studies and/or case reports on the theme addressed in the review.

For the development of this review, some obstacles found are that the hydrometra presents a complex and often asymptomatic pathogenesis, being found in veterinary medical consultations by other signs that the animal presents. Thus, few studies and reports describe specific cases of this condition. The Figure 1 represents the process of selecting articles to compose this integrative literature review.

Figure 1 - Flowchart of the article selection process to compose this integrative literature review.



Source: Prepared by the authors (2022).

3. Results and Discussion

We started this section of case reports with a description of a five-month-old Labrador Retriever bitch who had firm nodules in her abdomen that disappeared before the veterinary consultation. Then, four weeks later, this abdominal swelling presented severe characteristics, causing the tutor to seek professional help. On physical examination, three firm and palpable

nodules were presented in the abdomen, each approximately 13 cm in diameter with the presence of free fluid in the abdominal cavity. Therefore, the animal was referred for an exploratory laparotomy (Lapish, 1985).

During laparotomy it was possible to identify that most of the abdominal cavity was occupied by the distended right horn of the uterus, providing the impression of two distinct nodules. The third nodule was the distended right kidney. It was also possible to observe that the right ureter and horn were dilated. During hysterectomy and ureteronephrectomy, 4 liters of liquid were aspirated, confirming the hydrometra. The authors state that the ureter was the main responsible for the deposition of fluid in the uterine lumen since 4 cm of the right ureter was located ectopically within the wall of the uterus and vagina (Lapish, 1985).

Another singular case of a one-year-old unbred dog submitted to the collection of mature oocytes for reproductive strategies *in vitro* was reported by Kim et al. (2015). The bitch was submitted to laparotomy 72 hours after ovulation, determined by the serum concentration of progesterone, in which an abnormal increase had been found in the left uterine horn. Despite the presence of unilateral hydrometra, it was possible to recover 16 mature oocytes. This was the first study to confirm the *in vivo* maturation of oocytes in a dog with hydrometra, suggesting that oocytes recovered from canids with reproductive diseases may be valuable sources for assisted reproduction technologies (Kim et al., 2015).

Fujita et al. (2016) found in a 10-month-old female poodle toy canine, urogenital abnormality during surgical sterilization. Through an exploratory laparotomy, it was possible to identify a cyst adherent to the cervix with ipsilateral hydrometra and unilateral renal agenesis. Histopathological and immunohistochemical analysis of the cyst was consistent with Wolffian duct debris or a Gartner duct cyst. Thus, they concluded that this is a rare case of a canine cyst of the Gartner duct with renal agenesis and uterine anomaly (Fujita *et al.*, 2016).

Another interesting association was described by Chaves and associates (2020). A seven-year-old dog with no defined breed, domiciled in the municipality of Teresina (PI), was admitted to a veterinary clinic presenting anorexia, thinness, mucous membranes hyporange, dysuria, mild abdominal pain, and reddish urine. On ultrasound examination, thickening of the uterus, presence of bladder stones, and presence of uroliths were observed on contrast radiography. The surgical procedure was indicated where two uroliths were removed and, after ovariosalpingohysterectomy (OSH), it was found that it was a hydrometra. Hydrometra and urolithiasis are very frequent conditions in dogs, and several are the predisposing factors for such occurrences, such as feeding, genetic predisposition, and even age (Chaves et al., 2020).

In a case report of hydrometra of a 10-year-old Yorkshire terrier bitch, whose heat occurred a month ago, she had a history of depression, anorexia, vomiting, polyuria, polydipsia, and evident signs of pain during abdominal palpation. The uterus collected through OSH presented a bilateral increase in the horn dimensions, and thinning of its wall, without ulcers and cysts (Payan-Carreira et al., 2006). The anatomopathological characteristics found were the decrease in the relationship between endometrium and myometrium, endometrial stroma had edema and rarefaction of the glands of the region, strong nuclear expression of estrogen receptors in the endometrium and myometrium; the fluid of the uterus was aqueous, slightly yellowish and without cellularity (Payan-Carreira et al., 2006).

Another case present in the literature refers to a female who presented a right perineal hernia and left inguinal hernia, resulting from uterine dilation caused by hydrometra (Machado et al., 2020). The patient was a 12-year-old Pinscher bitch, weighing 3 kg, suffering from anuria and constipation in the 36 hours before the consultation; no reports of trauma and a history of her last heat having occurred 30 days ago. On physical examination, pale mucous membranes, tachycardia, tachypnea, body temperature at 39.8° C, abdominal pain on touch, increased volume in the left inguinal region, and increase in volume in the right perineal region, and reactive popliteal lymph nodes were observed. The abdominal ultrasound findings were consistent with dilated uterine horns, with the presence of fluid and unilaterally displaced in the left inguinal region,

confirmatory of hydrometra. The bitch was submitted to surgical procedures of therapeutic OSH, inguinal and perineal herniorrhaphy, receiving medical discharge on the 10th postoperative day (Machado et al., 2020).

In the case reported, the authors concluded that the presence of the right perineal hernia and left inguinal hernia were due to uterine dilation caused by hydrometra. Compression in the pelvic wall by the uterus caused by increased fluid in the uterine lumen, associated with weakening of the musculature influenced the development of perineal hernia in the patient (Radlinsky, 2013). The hydrometra was the primary cause, which in turn stimulated the appearance of inguinal and perineal hernias because no other possible causes were identified (Machado et al., 2020).

Oh et al. (2005) described the first case of hydrometra from a segmental aplasia in the uterine body. They address the picture of this condition in a dog without a defined breed and five years old. Suspicion was initiated from an abdominal x-ray and transabdominal ultrasound revealed a marked dilation of the fluid-filled uterine horns without any evidence of a uterine body. A piece of cord tissue was identified as a plastic/dysplastic remnant, connecting the cervix and right uterine horn. In both uterine horns, there was an accumulation of fluid, which inferred the diagnosis of hydrometra. Finally, it was concluded that the hydrometra observed in both uterine horns were induced by an obstruction resulting from segmental aplasia in the uterine body (Oh et al., 2005).

In a similar case, Almeida et al. (2010) reported a case of partial uterine segmental aplasia in a dog without a defined race, sexually mature, in anestrus, and who presented normal cyclic activity. The bitch was part of an experimental control group and after euthanasia, she was referred for necropsy for pathological analysis. Macroscopically the uterine body presented thickness reduction in the middle of a caudal region, with an absence of lumen at this point, and hydrometra in its cranial portion and uterine horns. In the histological evaluation, it was possible to identify a reduction of the total thickness of the uterine body in its middle-tailed third, a reduction of the total thickness of the uterine wall in the horns, and a reduction of the number of endometrial glands (Almeida et al., 2010).

Even with uterine aplasia, the anestrus phase of the bitch was identified through vaginal cytology and dosage of serum progesterone, associated with the presence of corpus luteal in regression and ovarian follicles in various stages of development in the ovaries. These findings corroborate other cases of segmental aplasia of the uterus, confirming that this condition does not alter the ovarian cyclic activity in the bitch (Johnston, Kustritz & Olson, 2001), different from what occurs in other species (Nascimento & Santos, 2003; Schlafer & Miller, 2007).

Hydrometra associated with the cranial part of uterine aplasia is often described in other species, such as sows, cows, and sheep (Webb, 1985; Birth & Saints, 2003). However, in it is an atypical condition, still little is reported (Almeida et al., 2010).

Holzlsauer et al. (2022) reported a case of a Brazilian Terrier bitch, nine years ago, with a history of ovariohysterectomy (OHE) performed six years ago, domiciled in the municipality of Araguaína, which presented the veterinary consultation with inappetence, prostration, vomiting, characteristics of heat and report of copulation three days before the consultation, an atypical case of remaining ovary syndrome (ROS) associated with polycystic ovary was diagnosed and hydrometra. The medical team performed an exploratory celiotomy where the presence of a uterine horn near the left ovary was found, which was hyperplastic and polycystic (Holzlsauer et al., 2022).

ROS is an important condition in the development of hydrometra cases. This is because the persistence of ovarian fragments in the abdominal cavity after an OHE brings consequences such as signs of heat, persistent heat, ovarian cysts, vulvar secretion, accumulation of fluid in remnants of the uterus that lead to the development of hydrometra, and may evolve to cases of pyometra if microorganisms rise to the uterine bed containing liquid, as in previous cases of hydrometra (Parker & Snead, 2014; Holzlsauer et al., 2022).

Another case of affection that generated a case of hydrometra was described by Sontas et al. (2013). It is a 5-year-old poodle dog, sexually intact, with a history of an inguinal mass two years ago. After OHE and inguinal hernia repair surgery, the dog's reproductive system was collected and referred for pathological analysis. On histopathological examination, it was possible to identify the massive presence of fluid in the uterine horns, localized edema, hyperemia in the lamina of the uterus, and diffuse hemorrhage in the uterus. Such alterations were associated with the fact that both the broad ligaments and the uterine body were passing through the inguinal ring of the hernia (Sontas et al., 2013).

In 2004, Macun and Özyurtlu reported the case of a 1-year-old unbred cat who was treated at the Department of Obstetrics and Gynecology at the Faculty of Veterinary Medicine in a Turkish city with suspected miscarriage due to a recurrence of a bloody vaginal discharge. During ultrasonography, the presence of fetuses was not detected, however, the presence of a large zone in the uterus was identified, with anechoic characteristics. From the characteristics of the intrauterine fluid, they determined the diagnosis of hydrometra. Histopathological examination of the uterus revealed an adenoma and proliferative polyps in the endometrium (Macun & Özyurtlu, 2004).

A 3-year-old unbred cat was evaluated in the Department of Obstetrics and Clinical Gynecology at Istanbul University complaining of abdominal distension. In laboratory tests, abnormalities such as mild leukocytosis and increased urea were detected. On ultrasound examination, a uterus filled with fluid and a mass in the right ovary was found. A surgical excision was performed, and the mass was diagnosed as unilateral mature ovarian teratoma associated with a case of hydrometra. The authors state that there were no descriptions of feline teratoma associated with other uterine alterations in the literature (Sabuncu et al., 2018).

In cats, the hydrometra is characterized by aqueous fluid and drain (Von-Reitzenstein et al., 2000). In addition, congenital anomalies, neoplasms, inflammatory processes, scar ligation, or accidental, impotence of the vulva, vagina, cervix, or uterus can cause the formation of hydrometra in cats (Johnston et al., 2001b).

Morales-Salinas et al. (2019) reported a case of hydrometra associated with uterine torsion. It is a five-year-old palomino domestic rabbit (*Oryctolagus cuniculus*), of the Palomino breed, which presented a gradual picture of anorexia, adipsia, and apathy. On physical examination, the rabbit presented a distended abdomen and was sensitive to palpation, presenting algesia. On ultrasound examination, it was observed that the uterus was very dilated and with abundant fluid, suggesting hydrometra or hematometra. During the surgical treatment, performed from an ovariohysterectomy, it was confirmed that the right uterine horn was completely twisted with abundant fluid in its lumen. Thus, the rabbit was diagnosed with uterine torsion and a right unilateral hydrometer. The female died one day after surgery and was referred for a necropsy. The rabbit presented severe necrotic areas in the endometrium and severe diffuse transmural edema, the fluid present in the uterine lumen was sterile and non-inflammatory, clear and slightly cloudy, and aqueous to viscous (Morales-Salinas et al., 2019).

In another case, a 1.5-year-old domestic rabbit, with no history of reproduction, presented intermittent anorexia and severe abdominal distension for 4 months. On abdominal radiographic examination, severe abdominal distension was found with decreased abdominal details, in addition, it was possible to observe a large, multilobulated mass, with distinct opacity of soft tissues that occupied the middle to the caudal abdomen, displacing the stomach and small intestine cranially and colon dorsally. On ultrasound examination, an anechoic fluid was contained within well-defined walls of the multilobulated mass, identified as a uterus, determining a hydrometra (Na & Choi, 2014).

During exploratory laparotomy, the uterine horns were twisted and congested, with the serous of the left horn darker than that of the right. After OHE, the liquid collected in the right horn was yellowish and sero-sanguinolent fluid, while that of the left horn was dark red. Both were cultured in microbiological tests, and gram-positive micrococci and bacilli were found in the left horn fluid (Na & Choi, 2014).

Hristov et al. (2017) found another hydrometra-related condition in a 4-year-old rabbit, with no defined race, which presented a considerable and symmetrical increase in the abdominal region, obtaining the diagnosis of hydrometra after ultrasound examination in which a significant increase of the uterus with an anechoic structure was identified. She was referred for a medial laparotomy. After the removal of the uterus from the abdominal cavity, a mass was identified in the bifurcation zone of the uterine horns and for histological identification of the mass all the material collected during the surgical procedure was forwarded for pathological analysis (Hristov et al., 2017). Histological examination of the mass found in the rabbit in the report by Hristov et al. (2017) confirmed a moderate to well-differentiated adenocarcinoma. The macroscopic examination of the fluid collected from the uterus was clear and transparent; furthermore, the microbiological examination of the samples proved the presence of a small amount of *Serratia marcescens* (Hristov et al., 2017).

Culture techniques and antibiogram of exudate extracted from females, when they do not provide the growth of microorganisms in specific diagnostic tests, establish the diagnosis of hydrometra, corroborating information described in the literature (Rautela et al., 2019; Holzlsauer et al., 2022).

The etiology of hydrometra is still unclear concerning its relationship with the reproductive cycle and ovulation in rabbits (Na & Choi, 2014; Hristov et al., 2017). The release of oocytes in the species triggered with stimulation, in addition, Adams (1987) reports the possibility of self-induced ovulation in rabbits. As a consequence, there is an increase in progesterone levels that promote increased secretion of the endometrial glands and induce the closure of the uterine cervix, resulting in the continuous accumulation of fluid in the uterus (Hristov et al., 2017). Finally, Asakawa et al. (2008) studied the presence of α estrogen receptors (ER α) and progesterone receptors in normal uterine tissue, being found in 59.3% of normal tissues and 93.8% of adenocarcinomas tissues for at least one of the receptors.

Relationship between progestogen therapy and hydrometra

Hydrometra is differentiated from mucometra due to variations in physical composition and hydration level, which can be influenced by the activity rate of estrogenic hormones (Schlafer & Foster, 2016). An intrinsic factor of hydrometra is the intense nuclear expression of estrogen receptors in all endometrial cells and myometrium (Vermeirsch et al., 2002). The chronic stimulation of estrogen receptors in uterine tissue may influence the increase in intraluminal fluid production, promoting the thickening of uterine horns and leading to the development of hydrometric conditions (Payan-Carreira et al., 2006). Thus, the application of progestogen as a contraceptive and estrogen method for mating are being associated with uterine diseases (Smith, 2006).

In the case report of hydrometra of Payan-Carreira et al. (2006) in the uterine women of the bitch, the proportion of cells presenting the high expression of the nuclear estrogen receptor reached 100% in the uterine glands and superficial epithelium, with a much higher distribution rate than in the heat and pro-estrus controls for all evaluated cells (Payan-Carreira et al., 2006).

In cats, hydrometra is not often associated with cats with advanced cystic endometrial hyperplasia and does not lead to systemic clinical symptomatology (Von-Reitzenstein et al., 2000; Pereira et al., 2022). Thus, it is common for them to present preoperative tests within the parameters of normality and be referred for elective OSH surgery, making hydrometra an unexpected finding of the surgical procedure or necropsy (Barni et al., 2013; Soares, 2019). This disease has been reported in other species associated with the exogenous administration of substances that stimulate estrogen receptors (Pretzer, 2008).

The study by Voorwald et al., (2015) verified molecular alterations in the uterus of females with the administration of exogenous progestogen, when compared to females that did not receive this therapy. The excessive concentration of circulating progesterone gradually induces fluid accumulation in the uterus, predisposing it to opportunistic bacterial infection (Hagman, 2017). Progesterone increases the activity of the endometrial secretory glands, the thickness of the endometrium and decreases

the contractility of the myometrium and may alter the closure of the cervix and impair the drainage of uterine fluids, especially in females in the diestrus phase of the estrous cycle, especially nulliparas; elderly and young animals that are treated with progestágenos (Barni et al., 2013; Soares, 2019).

4. Final Considerations

It was possible to identify numerous factors that can predispose domestic females to the development of hydrometra and the risks that these conditions, often asymptomatic, have. In addition, the occurrence of hydrometra in the absence of other pathological features in the uterus is not so frequent. It is important to emphasize that veterinary medical follow-up of animals of age and reproductive attitude is regular, so that cases of hydrometry are prevented and, consequently, abortions, reproductive risks, and predisposition of females to severe conditions of this condition are avoided.

References

- Adams C. E. (1987). *The UFAW Handbook on the Care and Management of laboratory animals*, 6 th edn. Publisher: Ed T Poole, Avon, Longmanq Scientific and Technical.
- Almeida, M. V. D., Rezende, E. P., Lamounier, A. R., Rachid, M. A., Nascimento, E. F., Santos, R. L., & Valle, G. R. (2010). Aplasia segmentar de corpo uterino em cadela sem raça definida: relato de caso. *Arquivo Brasileiro de Medicina Veterinária e Zootecnia*, 62, 797-800. <https://doi.org/10.1590/S0102-09352010000400005>
- Asakawa, M. G., Goldschmidt, M. H., Une, Y., & Nomura, Y. (2008). The immunohistochemical evaluation of estrogen receptor- α and progesterone receptors of normal, hyperplastic, and neoplastic endometrium in 88 pet rabbits. *Veterinary Pathology*, 45(2), 217-225. <https://doi.org/10.1354/vp.45-2-217>
- Barni, B. D. S., Albuquerque, P. B. D., & Contesini, E. A. (2013). Hiperplasia endometrial cística em cadelas e gatas: revisão de literatura. *Ci. Anim.*, 9-19.
- Barroso, J. E. M., da Silva, A. V., Barroso, M. C. M., Silva, G. C., & da Silva, L. A. (2020). Controle Populacional de Cães: uma revisão integrativa. *HUMANIDADES E TECNOLOGIA (FINOM)*, 19(1), 20-34.
- Brown, J. L. (2006). Comparative endocrinology of domestic and nondomestic felids. *Theriogenology*, 66(1), 25-36. <https://doi.org/10.1016/j.theriogenology.2006.03.011>
- Carvalho, A. M. H., Santos, A. D. F., & Silva, C. M. (2020). Indução do estro e métodos para controle das fases do ciclo estral em cadelas. *Ciênc. Anim.(Impr.)*, 117-129.
- Chatdarong, K. (2003). *Reproductive physiology of the female cat* (Vol. 162, No. 162).
- Chaves, L. D. C. S., Silva, F. L., de Sousa, J. M. C., de Alencar Oliveira, J. R., da Silva, C. R. A., Holanda, M. S., & Santos, L. P. (2019). Urolitíase e hidrometra em cadela: relato de caso. *Pubvet*, 14, 128. <https://doi.org/10.31533/pubvet.v14n1a494.1-5>
- Concannon, P. W. (2011). Reproductive cycles of the domestic bitch. *Animal reproduction science*, 124(3-4), 200-210. <https://doi.org/10.1016/j.anireprosci.2010.08.028>
- Derussi, A. A. P., & Lopes, M. D. (2009). Fisiologia da ovulação, da fertilização e do desenvolvimento embrionário inicial na cadela. *Revista Brasileira de Reprodução Animal*, 33(4), 231-237.
- Ferreira, W. M., Machado, L. C., Jaruche, Y. D. G., Carvalho, G. D., Oliveira, C. D., Souza, J. A. S., & Caríssimo, A. P. G. (2012). Manual prático de cunicultura. *Bambuú: Associação Brasileira de Cunicultura*.
- Fossum, T. W. (2014). *Cirurgia de Pequenos Animais*. São Paulo: Elsevier, 4ª ed., v. 1, 2014.
- Fujita, A., Tsuboi, M., Uchida, K., & Nishimura, R. (2016). Complex malformations of the urogenital tract in a female dog: Gartner duct cyst, ipsilateral renal agenesis, and ipsilateral hydrometra. *Japanese Journal of Veterinary Research*, 64(2), 147-152.
- Hafez, E. S. E., Jainudeen, M. R., & Rosnina, Y. (2004). Hormônios, fatores de crescimento e reprodução. *Reprodução animal*, 7, 33-53.
- Hagman, R. (2017). Aspectos moleculares das doenças uterinas em cadelas. *Reprodução em Animais Domésticos*, 52, 37-42. <https://doi.org/10.1111/rda.13039>
- Holzlsauer, G. M., de Oliveira, F. A., Martins, L. C. T., Bosso-Holzlsauer, A. C. S., & de Araújo, F. A. P. (2022). Apresentação atípica e resolução cirúrgica de síndrome do ovário remanescente em cadela Terrier brasileiro idosa. *Brazilian Journal of Development*, 8(4), 30567-30579. <https://doi.org/10.34117/bjdv8n4-505>
- Jaruche, Y. G. (2014). *Nota técnica: Ciclo estral das coelhas*. Available at: <http://acbc.org.br/site/index.php/notas-tecnicas/estral-ciclo>. Accessed on: November 03, 2022.
- Johnston, S. D., Kustritz, M. V. R., Olson, P. N. S. (2001). *Disorders of the canine uterus and uterine tubes (oviducts)*. In: Johnston, S. D., Kustritz, M. V. R., Olson, P. N. S. *Canine and feline theriogenology*. Philadelphia: W.B. Saunders, 206-224.

- Johnston, S. D., Kustritz, M. V. R., Olson, P. N. S. (2001b). *Hydrometra/Mucometra/Hematometra*. In: Johnston, S. D., Kustritz, M. V. R., Olson, P. N. S. Canine and feline theriogenology. Philadelphia: W.B. Saunders, 206-224.
- Kim, M. J., Jo, Y. K., Kang, S. C., Oh, H. J., Kim, G. A., Setyawan, E. M. N., ... & Lee, B. C. (2015). Recovery of In Vivo Matured Oocytes from a Bitch with Hydrometra. *Journal of Veterinary Clinics*, 32(6), 536-539. <https://doi.org/10.17555/jvc.2015.12.32.6.536>
- Hristov, K., Mehandzhyski, N., Peev, I., & Georgiev, G. (2017). Case study of hydrometra and uterine adenocarcinoma in a pet rabbit. *Med Inform*, 3(1), 544-550. <https://doi.org/10.18044/Medinform.201741.544>
- Lapish, J. P. (1985). Hydronephrosis, hydroureter and hydrometra associated with ectopic ureter in a bitch. *Journal of Small Animal Practice*, 26(10), 613-617. <https://doi.org/10.1111/j.1748-5827.1985.tb02187.x>
- Lockwood, C., Porrit, K., Munn, Z. et al. (2020). *Chapter 2: Systematic reviews of qualitative evidence*. In: Aromataris, E., Munn, Z. *JBIR Manual for Evidence Synthesis*. <https://doi.org/10.46658/JBIRM-17-02>
- Machado, A. V. P., Lugocho, G., Santos, A. P. I. D., Gonçalves, M. E. P., Oliveira, M. T. D., Vilela, J. A. P., & Beckmann, D. V. (2020). Hérnia perineal em canina fêmea. *Acta Scientiae Veterinariae*, 48(Suppl 1), 491.
- Macun, H. C., & Özyurtlu, N. (2004). Endometrial polyps and adenoma in a cat with hydrometra: case report. *Turkish Journal of Veterinary & Animal Sciences*, 28(2), 447-449.
- Mendes, K. D. S., Silveira, R. C. D. C. P., & Galvão, C. M. (2008). Revisão integrativa: método de pesquisa para a incorporação de evidências na saúde e na enfermagem. *Texto & contexto-enfermagem*, 17, 758-764. <https://doi.org/10.1590/S0104-07072008000400018>
- Michel, C. (1993). Induction of oestrus in cats by photoperiodic manipulations and social stimuli. *Laboratory animals*, 27(3), 278-280. <https://doi.org/10.1258/002367793780745381>
- Morales-Salinas, E., Preza-Romero, F., Quintal-Parra, M. D., & García, J. C. (2019). Torsión uterina e hidrometra unilateral en una coneja (*Oryctolagus cuniculus*) de compañía. *Revista Clínica Veterinaria*, 5. <https://doi.org/10.22201/fmvz.23958766e.201934>
- Na, S., & Choi, J. (2014). Uterine torsion associated with hydrometra and pyometra in a domestic rabbit. *Journal of Veterinary Clinics*, 31(6), 544-546. <https://doi.org/10.17555/ksvc.2014.12.31.6.544>
- Nascimento, E. F., Santos, R. L. (2003). *Patologia do sistema genital feminino*. In: Nascimento, E. F., Santos, R. L. *Patologia da reprodução dos animais domésticos*. 2.ed. Rio de Janeiro: Guanabara Koogan, 15-89.
- Nogueira, C. S., Ferreira, M. H., da Silva, W. C., Silva, L. K. X., Batista, H. R., Araújo, L. J. S., ... & da Silva, É. B. R. (2019). Determinação da fase do ciclo estral através da anamnese e citologia vaginal associada à dosagens hormonais. *Brazilian Journal of Animal and Environmental Research*, 2(3), 1037-1045.
- Oh, K. S., Son, C. H., Kim, B. S., Hwang, S. S., Kim, Y. J., Park, S. J., ... & Cho, K. O. (2005). Segmental aplasia of uterine body in an adult mixed breed dog. *Journal of veterinary diagnostic investigation*, 17(5), 490-492. <https://doi.org/10.1177/104063870501700517>
- Parker, K., & Snead, E. (2014). Atypical presentation of ovarian remnant syndrome in a dog. *Journal of the American Animal Hospital Association*, 50(4), e1-e5. <https://doi.org/10.5326/JAAHA-MS-6025>
- Payan-Carreira, R., Pina, J., Costa, M., Seixas, F., & Pires, M. A. (2006). Oestrogen receptors in a case of hydrometra in a bitch. *Veterinary record*, 158(14), 487. <https://doi.org/10.1136/vr.158.14.487>
- Pereira, L. N. C., de Castro, G. Z. S., Gutjahr, C. A., Bombem, B. D. R., Cruz, M. F. R., Calderon, C., & dos Santos, A. P. M. E. (2022). Achados macroscópicos no sistema reprodutor de cadelas e gatas submetidas a ovariohisterectomia: Relato de experiência. *PUBVET*, 16, 188. <https://doi.org/10.31533/pubvet.v16n05a1102.1-5>
- Pretzer, S. D. (2008). Clinical presentation of canine pyometra and mucometra: a review. *Theriogenology*, 70(3), 359-363. <https://doi.org/10.1016/j.theriogenology.2008.04.028>
- Radlinsky, G. A. (2013). *Surgery of the Perineum, Rectum Anus*. In: Fossum, T.W. *Small Animal Surgery*. 4th. edn. St. Louis: Elsevier, 1175.
- Rautela, R., & Katiyar, R. (2019). Review on canine pyometra, oxidative stress and current trends in diagnostics. *Asian Pacific Journal of Reproduction*, 8(2), 45. <https://doi.org/10.4103/2305-0500.254645>
- Sabuncu, A., Enginler, S. Ö., Çetin, A. C., Dal, G. E., Bamaç, Ö. E., Yildirim, F., & Yildar, E. (2018). Unilateral Ovarian Mature Teratoma and Hydrometra Case in a Queen. *Dicle Üniversitesi Veteriner Fakültesi Dergisi*, 11(1), 55-58.
- Schlafer, D. H., Miller, R. B. (2007). *Female genital system*. In: Maxie, M.G. Jubb, Kennedy, and Palmer's Pathology of Domestic Animals. 4.ed. Philadelphia: Elsevier Saunders, 429-564. <https://doi.org/10.1016/B978-070202823-6.50174-3>
- Schlafer, D. H., Foster, R. A. (2016). *Sistema genital feminino*. In: Maxie, M.G. Jubb, Kennedy, and Palmer's Pathology of Domestic Animals, 358. <https://doi.org/10.1016/B978-0-7020-5319-1.00015-3>
- Silva, L. D. M. D. (2020). Considerações sobre a reprodução da gata. *Ci. Anim.*, 57-69.
- Silva, L. D. M. D. (2016). Controle do ciclo estral em cadelas. *R. bras. Reprod. Anim.*, 180-187.
- Smith, F. O. (2006). Piometra canina. *Theriogenology*, 66, 3, 610-612. <https://doi.org/10.1016/j.theriogenology.2006.04.023>

- Soares, N. C. S. (2019). Hiperplasia endometrial cística associada a hidrometra felinos: relato de caso. Available at: <https://repositorio.ifgoiano.edu.br/handle/prefix/802>. Accessed on: November 03, 2022.
- Sontas, B. H., Toydemir, F. S., Erdogan, Ö., Şennazli, G., & Ekici, H. (2013). Inguinal herniation with hydrometra/mucometra in a poodle bitch. *The Canadian Veterinary Journal*, 54(9), 840.
- Vermeirsch, H., Van den Broeck, W., Coryn, M., & Simoens, P. (2002). Immunohistochemical detection of androgen receptors in the canine uterus throughout the estrus cycle. *Theriogenology*, 57(9), 2203-2216. [https://doi.org/10.1016/S0093-691X\(02\)00908-1](https://doi.org/10.1016/S0093-691X(02)00908-1)
- Von-Reitzenstein, M., Archbald, L. F., Newell, S. M. (2000). Theriogenology question of the month. *Journal of the American Veterinary Medical Association*, 2016(8), 1221-1223. <https://doi.org/10.2460/javma.2000.216.1221>
- Voorwald, F. A., Marchi, F. A., Villacis, R. A. R., Alves, C. E. F., Toniollo, G. H., Amorim, R. L., ... & Rogatto, S. R. (2015). Molecular expression profile reveals potential biomarkers and therapeutic targets in canine endometrial lesions. *PLoS One*, 10(7), e0133894. <https://doi.org/10.1371/journal.pone.0133894>
- Webb, P. (1985). Segmental aplasia and hydrometra in a goat. *The Veterinary Record*, 117(1), 13-13. <https://doi.org/10.1136/vr.117.1.13>
- Whittemore, R., Chao, A., Jang, M., Minges, K. E., & Park, C. (2014). Methods for knowledge synthesis: an overview. *Heart & Lung*, 43(5), 453-461. <https://doi.org/10.1016/j.hrtlng.2014.05.014>