

## Neonatal uterine prolapse: case report in a maternity in the Brazilian Amazon

Prolapso uterino neonatal: relato de caso em uma maternidade da Amazônia brasileira

Prolapso uterino neonatal: reporte de caso en una maternidad en la amazonia brasileña

Received: 11/28/2022 | Revised: 12/12/2022 | Accepted: 12/13/2022 | Published: 12/18/2022

**Thaís Prinzeff Borges**

ORCID: <https://orcid.org/0000-0002-4613-945X>

Amazon State University, Brazil

E-mail: [prinzeff\\_t18@yahoo.com.br](mailto:prinzeff_t18@yahoo.com.br)

**Fernanda Nogueira Barbosa Lopes**

ORCID: <https://orcid.org/0000-0001-8711-6599>

State Department of Health of Amazonas, Brazil

E-mail: [fernandanbl@hotmail.com](mailto:fernandanbl@hotmail.com)

**José Fernandes de Souza Viana**

ORCID: <https://orcid.org/0000-0002-1237-0346>

Amazon State University, Brazil

E-mail: [viana\\_fernandes@hotmail.com](mailto:viana_fernandes@hotmail.com)

### Abstract

**Objective:** To present a case of neonatal uterine prolapse at a reference maternity hospital. **Methodology:** This is a case report of neonatal uterine prolapse that occurred at a tertiary maternity hospital in Manaus, Amazonas, Brazil. The data presented were collected from medical records that contained the history and reports of the examinations performed. **Results and Discussion:** The newborn was delivered vaginally in cephalic presentation. The apgar scores were 8 and 10 (at 1 and 5 min of life, respectively). On physical examination, the patient weighed 2,971 g, had mild edema, atypical facies, a visible increase in head circumference, flexed limbs, and reduced subcutaneous tissue. On the 4<sup>th</sup> postoperative day of myelomeningocele repair, a pinkish, edematous, interlabial mass was observed in the genital region, compatible with uterine cervix prolapse. At 15 days of age, a Foley probe No. 6 was inserted, inflated with 5 mL distilled water, and occluded with a dermal dressing concomitant with local estrogen application (1 mL) once a day. **Conclusion:** Uterine prolapse is a rare condition in newborns and is usually associated with spina bifida. The treatment is conservative in most cases, and the prognosis is generally favorable.

**Keywords:** Uterine prolapse; Newborn; Case reports; Obstetrics.

### Resumo

**Objetivo:** apresentar um caso de prolapso uterino neonatal ocorrido em uma maternidade de referência. **Metodologia:** Trata-se de um relato de caso de prolapso uterino neonatal ocorrido em uma maternidade terciária em Manaus, Amazonas – Brasil. Os dados apresentados foram coletados em prontuário médico que constam relatórios e laudos de exames realizados. **Resultados e Discussão:** Recém-nascido de parto vaginal, em apresentação cefálica. Apgar 8 e 10 (em 1° e 5° minutos de vida, respectivamente). Ao exame físico, apresentou-se com peso de 2.971 gramas, edema leve, fácies atípica, visível aumento do perímetro cefálico, flexão de membros; tecido subcutâneo reduzido. No 4° dia pós-operatório de mielomeningocele foi observada em região genital, massa rósea, edemaciada, interlabial, compatível com prolapso do colo uterino. Aos 15 dias de vida foi inserida sonda de Foley nº 6, insuflada com 5ml de água destilada e oclusão com curativo dérmico concomitante com aplicação de estrogênio local (1ml) uma vez ao dia. **Conclusão:** Prolapso uterino é uma condição rara em bebês recém-nascidos que geralmente está associada com espinha bífida. O tratamento é conservador na maioria dos casos e o prognóstico geralmente é favorável.

**Palavras-chave:** Prolapso uterino; Recém-nascido; Relatos de casos; Obstetrícia.

### Resumen

**Objetivo:** presentar un caso de prolapso uterino neonatal ocurrido en una maternidad de referencia. **Metodología:** Este es un reporte de caso de prolapso uterino neonatal ocurrido en una maternidad de tercer nivel en Manaus, Amazonas – Brasil. Los datos presentados fueron recolectados de las historias clínicas que contienen informes e informes de exámenes realizados. **Resultados y Discusión:** Recién nacido de parto vaginal, en presentación cefálica. Apgar 8 y 10 (a los 1 y 5 minutos de vida, respectivamente). Al examen físico el paciente pesaba 2.971 gramos, presentaba edema leve, facies atípica, visible aumento del perímetro cefálico, extremidades flexionadas; Tejido subcutáneo reducido. Al 4.º día postoperatorio se observó una masa interlabial rosada, edematosa, en región genital, compatible con prolapso de cervix uterino. A los 15 días de edad se insertó una sonda de Foley No. 6, se infló con 5ml de agua destilada y se ocluyó con un vendaje dérmico concomitante con la aplicación de estrógenos locales (1ml) una vez al día. **Conclusión:** El

prolapso uterino es una condición rara en los recién nacidos que generalmente se asocia con espina bífida. El tratamiento es conservador en la mayoría de los casos y el pronóstico generalmente es favorable.

**Palabras clave:** Prolapso uterino; Recién nacido; Informes de casos; Obstetricia.

## 1. Introduction

Neonatal uterine prolapse is a rare clinical condition that most often occurs in association with congenital anomalies (Noyes, 1927). In 1753, a case of neonatal uterine prolapse was reported for the first time. In the last 50 years, few cases of genital prolapse in neurologically normal newborns have been reported, with two cases reported in Brazil in 2019 (Henn, Juul & Van Rensburg, 2015; Saramago, Paranhos & Ribeiro, 2019).

Uterine prolapse has a multifactorial etiology. In 82% to 86% of cases, it may be associated with spinal cord malformations responsible for interrupting the innervation of the pelvic floor muscles (Noyes, 1927; Abdelsalam, Desouki & Abd alaal, 2006). Some factors also related to uterine prolapse include increased intraabdominal pressure during prolonged labor, obstetric trauma, pelvic bone malformations, and premature birth (McGlone & Patole, 2004; Lockwood, Durkee & Groth, 2012).

Neonatal prolapse is clinically diagnosed through visualization of a red mass or bulge through the vaginal opening. The cervical external os is usually seen at the end of the prolapsed mass, the urethral orifice is usually normal, and rectal prolapse may be present (Fraser, 1961; Porges, 1993).

Two distinct types of neonatal prolapses have been described, with the aim of guiding treatment and counseling. Type 1 corresponds to 77% of the cases, with most neonates born with cephalic presentation. It is associated with neural tube defects (mainly spina bifida with meningocele or myelomeningocele), requiring more complex reduction procedures, in addition to the importance of surgical repair of the neurological defect for the prevention of recurrence. Type 2, on the other hand, corresponds to 23% of cases and occurs in neurologically normal newborns, most in breech presentation. Simple digital reduction is usually sufficient for resolution (Henn, Juul & Van Rensburg, 2015).

Prolapse treatment ranges from watchful waiting to surgical management (Saksono & Maulidyan, 2015). Early treatment is important to prevent lesions and metaplasia of the endometrial lining due to prolonged exposure, which could affect future fertility (Hyginus & John, 2013; Saramago, Paranhos & Ribeiro, 2019).

In view of the above, the objective of this report was to present a case of neonatal uterine prolapse that occurred in a reference Maternity located in the city of Manaus, state of Amazonas, in the year 2020.

## 2. Methodology

This was a descriptive, narrative, and reflective study of a single case of a newborn with congenital malformations (myelomeningocele and congenital clubfoot) and a diagnosis of neonatal uterine prolapse. This neonate was hospitalized and treated at the Ana Braga maternity, a reference tertiary maternity located in Manaus, the capital of the state of Amazonas. This maternity is also the field of action of the medical residency in gynecology and obstetrics at the State University of Amazonas, which the main researcher is linked to and, therefore, she accompanied the consultations and evolution of the reported case.

Aiming to guide the collection of information and structuring of the case report, a data collection protocol was created with the following topics: information about pregnancy, childbirth and the newborn, physical examination of the newborn, complementary exams, description of the therapy and procedures performed and evolution and outcome of the case. The researchers collected data from the medical record and also from documents such as: pregnant woman's cards and live birth certificate and medical reports of tests that may have been performed.

This research complies with the ethical principles that guide research involving human participants set out in Resolution of the National Health Council No.466/2012. The study was approved by the Research Ethics Committee (CAAE 60858022.3.0000.5016 and opinion number:5.621.589).

The parents of the newborn were invited to participate in this study and were informed about the objectives, risks, and benefits. They were informed that they may refuse to participate in the study or interrupt their participation at any time without any type of damage. After acceptance, they signed a free and informed consent form.

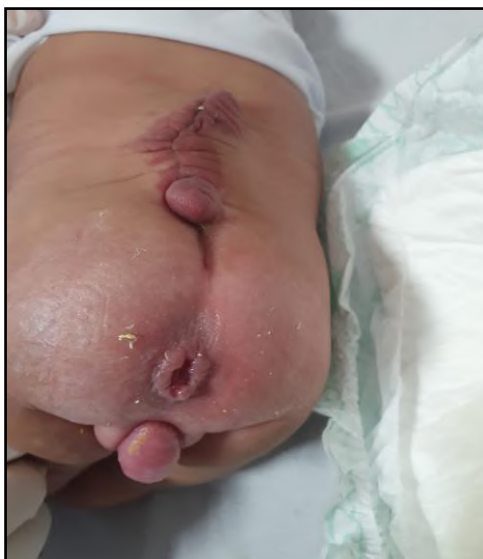### 3. Results and Discussion

The neonate was born to a 32-year-old woman, G3 P1c 2n A0 (three pregnancies, one cesarean delivery, two normal deliveries, and zero abortions), with a gestational age of 39 weeks. The neonate was delivered vaginally in the municipality of Itacoatiara, a city located 270 km away from the capital, Manaus, AM, on March 3, 2020.

The apgar scores were 8 and 10 at 1 and 5 min of life, respectively. On physical examination, the patient weighed 2,971 g, had mild edema, atypical facies, a visible increase in head circumference, flexed limbs, and reduced subcutaneous tissue. Respiratory, cardiovascular, abdominal, and genitourinary evaluations were within the normal limits. Examination of the lower limbs revealed congenital clubfoot. Neurological evaluation showed the presence of a myelomeningocele. The impressions at this time were myelomeningocele and congenital clubfoot.

After 1 day of life, she was sent to the capital for evaluation. Successful myelomeningocele surgery was performed, as shown in figure 1, which shows the surgical scar in the thoracic, lumbar, and sacral spine regions.

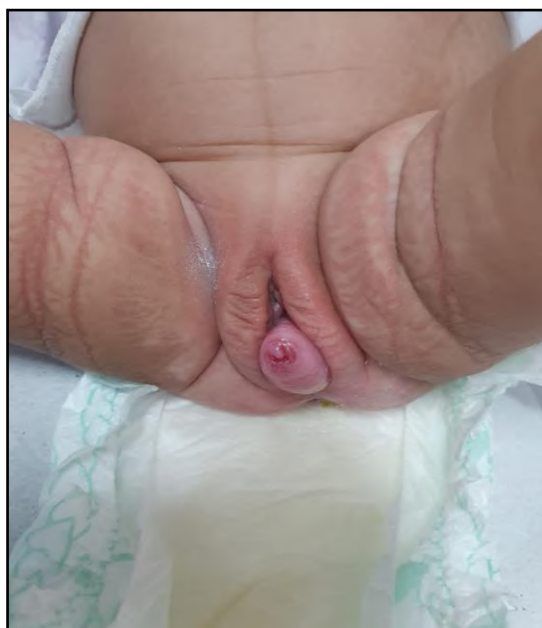**Figure 1** – Surgical scar for myelomeningocele correction.



Source: Authors.

Transfecontanel ultrasonography revealed dilatation of the ventricular system. At 13 days of life, an ultrasound of the entire abdomen was performed, which showed no abdominal abnormalities. On the 4<sup>th</sup> postoperative day of the myelomeningocele repair, a pink, edematous, interlabial mass was observed in the genital region, which was compatible with uterine prolapse. On physical examination, extrusion of approximately 2 cm of the uterus through the vaginal introitus was observed, as shown in Figure 2.

**Figure 2** – Neonatal uterine prolapse.

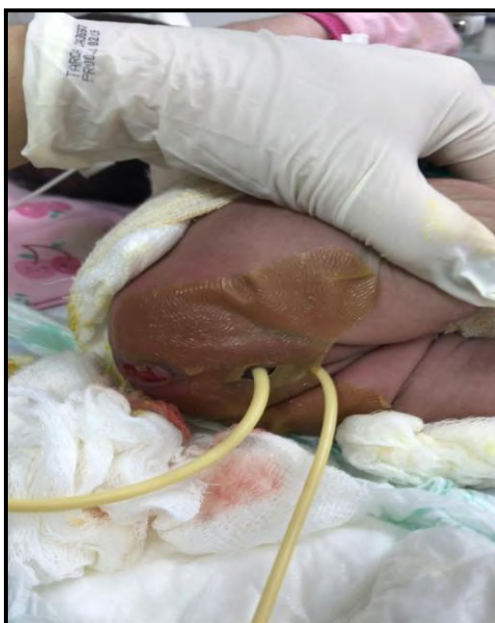

Source: Authors.

Manual reduction of the uterine cervix was performed without success because the cervix tended to prolapse continuously. At 15 days of life, a Foley's probe number 6 was inserted into the vaginal cavity, inflated with 5 mL distilled water, and occluded with a dermal dressing concomitant with application of local estrogen (1 mL) once a day. (Figure 3) After 48 h of incubation with the probe, the uterus prolapsed again. A new attempt at reduction was not made at that time, and only topical estrogen was maintained. After 3 days, manual reduction was again performed and a number 6 Foley's tube was inserted and inflated with 5 mL distilled water mixed with topical estrogen. The procedure was successful. The probe was removed, and the neonate was observed clinically. There was no recurrence of the prolapse after 6 months, as shown in figure 4. The final diagnosis was genital prolapse, congenital clubfoot, myelomeningocele, and ventriculomegaly.

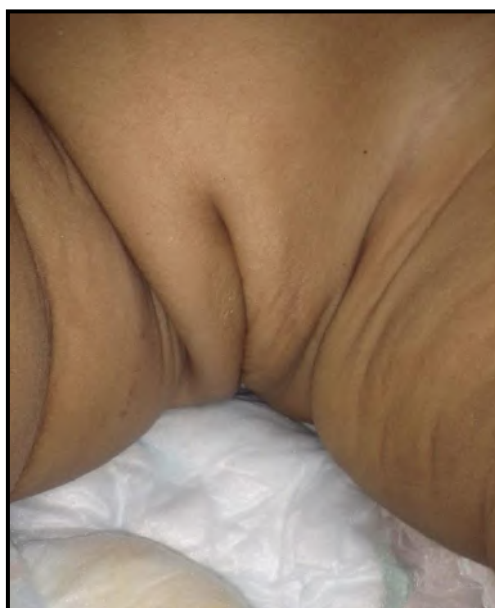
The uterus and vagina are suspended in their anatomical location by the pelvic diaphragm and endopelvic fascia (which is composed of uterosacral ligaments, cardinal ligaments, and pubocervical fascia). Congenital uterine prolapse is the result of weakness in the pelvic region (muscles and ligaments). This weakness may be secondary to congenital weakness in the pelvic musculature or defective innervation. The supporting pelvic muscles are normally innervated by the perineal branch of the sacral nerve. Injury to these nerves or their spinal cord components results in paralysis of the pelvic diaphragm with subsequent descent of the pelvic visceral structures (Jijo, Betele & Ali, 2018).

**Figure 3** - Procedure for inserting the number 6 Foley's probe into the vaginal cavity.



Source: Authors.

**Figure 4** – Progression of the case in the 6<sup>th</sup> month of life.



Source: Authors.

Understanding prolapse requires a basic knowledge of the functional anatomy of the pelvic floor. The pelvis is composed of two anterior and lateral bones, the sacrum and coccyx posteriorly, levator ani and coccygeal muscles, and the pelvic fascia. The ischiococcygeus, iliococcygeus, and pubococcygeus muscles, which arise from the spinal and pelvic bones, provide muscular support. These muscles insert into the coccyx and are innervated by the perineal branch of the fourth sacral nerve and branches of the inferior rectal and perineal nerves (Loret de Mola & Carpenter, 1996).

Increase in intraabdominal pressure caused by sneezing, laughing, or coughing are counteracted by pelvic floor muscle contractions. When there is a defect in the function of these nerves or their spinal cord components, flaccid pelvic floor paralysis

allows descending protrusions of the pelvic viscera. In newborns, this manifests as a poorly developed intergluteal cleft and bulging of the perineum, which is accentuated by crying or straining. In more severe cases, a rectal prolapse may occur (Saramago, Paranhos & Ribeiro, 2019; Yıldızdaş et al., 2019).

Although genital prolapse is usually observed immediately after birth, with the possibility that the etiological event occurs during the prenatal period, there are also reports of cases in which genital prolapse was observed at 3 weeks of life (Morales de Machín. et al, 2013; Saramago, Paranhos & Ribeiro, 2019). There has also been a report in Korea of a newborn with very low birth weight who was managed with manual reduction within 10 days of life and bandaging of the lower limbs with elastic bandage (Hwang, Kim & Kim, 2021; Chukwubuike & Odetunde, 2019).

Although the exact etiology of uterine prolapse in newborns is not well known, few risk factors have been attributed to the development of the disease in newborns, most of which are related to spina bifida (82–86%) (Mukenge et al., 2021). In the present case, uterine prolapse was associated with myelomeningocele in the lumbosacral region. Birth trauma, congenital cutis laxa, and prematurity are also among the factors related to the condition (Cheng et al., 2005; Jijo, Betele & Ali, 2018). Timely management of uterine prolapse in newborns is essential to prevent lesions and metaplasia in the endometrium from prolonged exposure to the external environment and to prevent other associated complications, such as urinary retention and obstructive uropathy (Saha et al., 2014; Jijo, Betele & Ali, 2018).

Radical approaches are rarely performed, especially in patients with spinal cord defect associated with recurrent prolapse after conservative management has been suggested in the literature. These approaches are recommended when there is recurrent prolapse despite multiple prolapse reductions or when there is evidence of vaginal hypertrophy or laceration. The fixation methods that have been suggested include cervical sacropexy and abdominal sacrocolpopexy. There have also been rare cases that have been reported to be treated with hysterectomy (Jijo, Betele & Ali, 2018).

In general, conservative management has a success rate of over 90%, although it is not yet possible to determine the long-term outcomes. Different conservative treatment techniques have been described, such as inserting a vaginal tampon made of antiseptic-coated gauze, using a pessary with a penrose drain, and a pessary using a rubber bottle or Foley's catheter (Dixon, Acosta & Young, 1974; Abdelsalam, Desouki & Abd alaal, 2006).

Among the surgical treatment modalities, we can highlight the temporary lip fusion presented by Ajabor and Okojie (1976). In this procedure, a hypertonic saline solution was used to reduce edema, with posterior partial fusion of the lips with suture maintained for 2 weeks. Other authors have performed temporary labial fusion with a crepe bandage from the lower abdomen to the lower third of the legs. Another procedure is the placement of a single suture to the labia majora which is maintained for 2 months (Fathi & Pinter, 2014). The last option is the combination of digital reduction under sedation with bladder catheterization and crepe bandage, applied in a mermaid fashion on the lower limbs (extending from the buttocks to the lower part of the legs, saving the anus for evacuation), with removal after 72 h (Hyginus & John, 2013).

#### **4. Conclusion**

Uterine prolapse is a rare condition in newborns and is usually associated with spina bifida. The treatment is conservative in most cases, and the prognosis is generally favorable. In neurologically abnormal neonates (presence of spina bifida and meningomyelocele), there is an increased risk of recurrence.

The condition can be successfully managed with manual reduction and bandaging of both ends using a gauze. This simple and effective procedure is recommended for cases of congenital uterine prolapse in newborns since it is easy to apply, inexpensive, can be performed in a primary facility, and has no associated complications.

In addition to highlighting the uniqueness of the clinical case, the presentation can contribute to generating discussions with health professionals, specialists and other researchers, provoking new studies and expanding knowledge, thus contributing to the advancement of medicine and propaedeutics of the conservative clinical approach in the treatment of neonatal uterine prolapse.

## References

- Abdelsalam S. E., Desouki N. M. & Abd alaal N. A. (2006). Use of Foley catheter formangement of neonatal genital prolapse: case report and reviewof the literature. *J Pediatr Surg*. 41(2):449-52. doi: 10.1016/j.jpedsurg.2005.11.031
- Ajabor L. N. & Okojie S.E. (1976). Genital prolapse in the newborn. *Int Surg.*, 61(9):496-7.
- Cheng, P. J., et al. (2005). Prenatal diagnosis of fetal genital prolapse. *Ultrasound Obstet Gynecol.*, 26: 204–206. doi: 10.1002/uog.1960
- Chukwubuike, K. E. & Odetunde, O. A. (2019). Uterovaginal Prolapse in a Newborn: A Case Report. *International Journal of Innovative Studies in Medical Sciences (IJISMS)*, 3(1).
- Dixon R. E., Acosta A. A. & Young R. L. (1974). Penrose pessary management of neonatal genital prolapse. *Am J Obstet Gynecol*. 119(6):855-7. doi: 10.1016/0002-9378(74)90104-5
- Fathi K. & Pinter A. (2014). Semiconservative management of neonatal vaginal prolapsed. *J Pediatr Surg Spec.*, 8(3).
- Fraser R. D. (1961). A case of genital prolapse in a newborn baby. *Br Med J*. 1(5231):1011-2. doi: 10.1136/bmj.1.5231.1011
- Jijo Z. W., Betele M. T. & Ali A. S. (2018). Congenital Uterovaginal Prolapse in a Newborn: case report. *Case Reports in Obstetrics and Gynecology*. 1425953.
- Yıldızdaş H. Y., et al. (2019). Spontaneously resolved uterine prolapse in a neonate with spina bifida. *The Turkish Journal of Pediatrics.*, 61:979-981. doi: 10.24953/turkjped.2019.06.026.
- Henn, E. W., Juul, L. & van Rensburg, K. (2015). Pelvic organ prolapse in theneonate: report of two cases and review of the literature. *IntUrogynecol J.*, 26(4):613-5. doi: 10.1007/s00192-014-2539-y
- Hyginus E. O. & John C. O. (2013). Congenital uterovaginal prolapse presentat birth. *J Surg Tech Case Rep*. 5(2):89-91. doi: 10.4103/2006-8808.128741
- Hwang J. H., Kim D. H. & Kim, H. S. (2021). Genital Prolapse Treated by Manual Reduction and Strapping of Lower Extremities in a Very Low Birth Weight Infant: A Case Report. *Perinatology*, 32(3):147-150.
- Lockwood G., Durkee C., Groth T. (2012). Genital prolapse causing urinaryobstruction and hydronephrosis in a neonate: a case and review ofthe literature. *J Neonatal Surg*. 1(3):39.
- Loret de Mola J R & Carpenter S. E. (1996). Management of genital prolapse in neonates and young women. *Obstet Gynecol Surv.*, 51(4):253-60. doi: 10.1097/00006254-199604000-00022
- Morales de Machín, A. M., etc al. (2013). Defecto del tubo neural, prolapso genital neonatal y polimorfismo de la metiltetrahidrofolato reductasa: Presentación de un caso. *Revista de Obstetricia y Ginecología de Venezuela*, 73(2), 132-137.
- McGlone L., & Patole S. (2004). Neonatal genital prolapse. *J Paediatr ChildHealth.*, 40(3):156-7. doi: 10.1111/j.1440-1754.2004.00321.x
- Mukenge T., et al. (2021). Uterine Prolapse: The Other Exceptional Complication of Spina Bifida in Newborns. *Open Journal of Pediatrics*, 11, 50-54.
- Noyes, I. H. (1927). Uterine prolapse associated with spina bifida in thenewborn, with report of a case. *Am J Obstet Gynecol.*, 13(2):209-13. doi: 10.1016/S0002-9378(27)90514-6
- Porges R. F. (1993). Neonatal genital prolapse. *Pediatrics*. 91(4):853-4.
- Saha, D. K. et al., (2014). Neonatal uterine prolapse - a case report. *Mymensingh Med J.*, 23(2):401-5.
- Saksono S. & Maulidyan A. (2015). Neonatal genital prolapse: a case report. *J Pediatr Surg Case Rep*. 3(4):176-8. doi: 10.1016/j.epsc.2015.02.013
- Saramago A. L. P., Paranhos M. B. & Ribeiro C.T. (2019). Prolapso uterino neonatal: relato de dois casos clínicos em hospital universitário e uma breve revisão da literatura. *FEMINA*; 47(7): 421-5.