

Mandibular morphological analysis of rats with osteoporosis and periradicular lesions

Análise morfológica mandibular de ratas com osteoporose e lesões perirradiculares

Análisis morfológico mandibular de ratas con osteoporosis y lesiones perirradiculares

Recebido: 08/12/2022 | Revisado: 20/12/2022 | Aceitado: 22/12/2022 | Publicado: 26/12/2022

Samanta Roberto Cordeiro

ORCID: <https://orcid.org/0000-0002-1096-3869>
Universidade do Grande Rio, Brazil
E-mail: sammycordeiro@yahoo.com.br

Luciana Armada

ORCID: <https://orcid.org/0000-0002-5877-9657>
Universidade Estácio de Sá, Brazil
E-mail: luadias@hotmail.com

Rachel Moreira Morais Santos

ORCID: <https://orcid.org/0000-0003-1400-5534>
Universidade Federal Fluminense, Brazil
E-mail: moraissant@yahoo.com.br

Juliana de Noronha Santos Netto

ORCID: <https://orcid.org/0000-0002-2990-7744>
Universidade Estácio de Sá, Brazil
E-mail: julianansn@yahoo.com.br

Márcia de Deus Santos

ORCID: <https://orcid.org/0000-0003-3789-4346>
Universidade do Grande Rio, Brazil
E-mail: marciareginaldsantos@gmail.com

Warley Oliveira Silva

ORCID: <https://orcid.org/0000-0002-2326-2367>
Universidade do Grande Rio, Brazil
E-mail: warleyosodonto@gmail.com

Sabrina de Castro Brazil

ORCID: <https://orcid.org/0000-0002-1412-7200>
Universidade do Grande Rio, Brazil
E-mail: sabrinacbrasil@hotmail.com

Abstract

The aim of the study was to perform a morphological analysis of the effects of osteoporosis on the periodontal ligament of rats with periradicular injury. Adult rats (n = 24), of the Wistar lineage, 3 months old, were included in the study. Twelve animals were ovariectomized (group OVX) and 12 were operated by simulation (group C). One hundred and twenty days after surgery, all animals were anesthetized, and in each animal, periradicular lesion was developed in the mandibular left first molar, by making a coronal opening in the mesial fossa on the occlusal surface until the pulp was exposed. At the end of each experimental time interval (21 and 40 days after the lesion developed), the animals were sacrificed, and blood was collected to confirm the effects of castration by serum estrogen measurement. The jaws were removed and prepared for quantitative analysis of the periodontal ligament thickness, by using an optical microscope. Comparative analysis of the data was performed using the non-parametric Kruskal-Wallis and Dunn Multiple Comparison tests. A reduction in serum estrogen levels was observed in the OVX groups (p <0.01), and a significant increase in the periodontal ligament thickness in Group C 21, when compared with Group OVX 40 days (p <0.01), and Group C 40 compared with Group OVX 40 days (p <0.01). In all samples with osteoporosis, there were signs of resorption in the alveolar bone, and significant periodontal ligament thickening in animals with longer exposure to the disease.

Keywords: Morphology; Periapical periodontitis; Postmenopausal osteoporosis.

Resumo

O objetivo do trabalho foi realizar uma análise morfológica dos efeitos da osteoporose no ligamento periodontal de ratas com lesão perirradicular. Ratas adultas (n= 24), da linhagem Wistar, com 3 meses de idade foram incluídas no estudo. Doze animais foram ovariectomizados (grupo OVX) e 12 foram operados por simulação (grupo C). Cento e vinte dias após a cirurgia todos os animais foram anestesiados, e a lesão perirradicular foi desenvolvida nos primeiros molares inferiores esquerdos através de abertura coronária na fôssula mesial da superfície oclusal até a exposição pulpar. Ao final de cada período experimental (21 e 40 dias após desenvolvimento da lesão), os animais foram sacrificados e o

sangre coletado para a confirmação dos efeitos da castração através da dosagem sérica de estrogênio, e as mandíbulas removidas e preparadas para análise quantitativa da espessura do ligamento periodontal em microscópio óptico. A análise comparativa dos dados foi realizada através dos testes não paramétricos *Kruskal-Wallis* e *Dunn's Multiple Comparison*. Houve uma redução nos níveis séricos de estrogênio nos grupos OVX ($p < 0.01$) e aumento significativo na espessura do ligamento periodontal do grupo C 21 quando comparado ao grupo OVX 40 dias ($p < 0.01$) e C 40 comparado ao grupo OVX 40 dias ($p < 0.01$). A osteoporose demonstrou sinais de reabsorção no osso alveolar em todas as amostras, espessamento do ligamento periodontal significativo em animais com maior tempo de exposição à doença.
Palavras-chave: Morfologia; Periodontite periapical; Osteoporose pós- menopausa.

Resumen

El objetivo de este estudio fue realizar un análisis morfológico de los efectos de la osteoporosis en el ligamento periodontal de ratas hembra con lesiones perirradiculares. Se incluyeron en el estudio ratas adultas ($n=24$), cepa Wistar, de 3 meses de edad. Doce animales fueron ovariectomizados (grupo OVX) y 12 fueron operados de forma simulada (grupo C). Después de 120 días de cirugía, todos los animales fueron anestesiados y la lesión perirradicular se desarrolló en los primeros molares inferiores izquierdos a través de una abertura coronal en la fosula mesial desde la superficie oclusal hasta la exposición pulpar. Posteriormente (21 y 40 días después del desarrollo de la lesión), los animales fueron sacrificados y se extrajo sangre para confirmar los efectos de la castración a través de la dosificación de estrógenos séricos, y las mandíbulas se extrajeron y prepararon para el análisis cuantitativo del grosor del ligamento periodontal bajo microscopio óptico. Se utilizaron las pruebas de comparación múltiple de *Kruskal-Wallis* y *Dunn*. Hubo una reducción en los niveles de estrógenos séricos en los grupos OVX ($p < 0,01$) y un aumento significativo en el grosor del ligamento periodontal en el grupo C 21 en comparación con el grupo OVX 40 días ($p < 0,01$) y C 40 en comparación con la OVX 40 días ($p < 0,01$). La osteoporosis mostró signos de reabsorción ósea alveolar en todas las muestras y un engrosamiento significativo de los ligamentos periodontales en los animales con mayor exposición a la enfermedad.

Palabras clave: Morfología; Periodontitis periapical; Osteoporosis posmenopáusica.

1. Introduction

The periradicular lesion is a consequence of the immune-inflammatory response caused by bacterial pathogens of endodontic origin, characterized by alveolar bone resorption around the tooth apex, by means of osteoclast action that degrades the bone matrix, resulting in periradicular bone lesion (Boyle *et al.*, 2003; Yao *et al.*, 2005; Oseko *et al.*, 2009).

Although there are highly efficacious protocols for eradication of the disease of endodontic origin, different responses to infection may occur to the same type of treatment, thereby influencing the susceptibility, development, or severity of the disease. This fact may explain the exacerbation, delayed cure of endodontic lesions, and explain why well treated canals may result in [treatment] failure. Disease Modifiers with potential to influence the periradicular lesion, include systemic conditions (diabetes and viral infections), genetic (genetic polymorphism), and acquired habits (smoking) (Siqueira & Lopes, 2011).

Osteoporosis is defined as a disease of the skeleton, characterized by compromising the resistance and quality of bone, with deterioration of the microarchitecture, thereby increasing the risk of fractures (Yamashiro & Takano-Yamamoto, 2001).

In Brazil, postmenopausal osteoporosis in women over the age of 49 has a prevalence of 32.7% (Faisal-Cury & Zacchello, 2007). According to Yamashiro & Takano-Yamamoto, 2001, the main factor of human postmenopausal osteoporosis is the reduction in estrogen levels, associated with acceleration of bone resorption. In case of premature menopause, thus reduction in bone mass is more exacerbated, and estrogen is the determinant factor in the establishment of postmenopausal osteoporosis (Klinbanski *et al.*, 2001).

López-López *et al.*, 2015 reported that women with postmenopausal osteopenia or osteoporosis have 4.2 time more chances of developing a radiolucent periradicular lesion when compared with women of the same age with healthy bone.

The main biological mechanisms responsible for the gain and loss of bone during growth and in adult life are similar among human beings and rats, and rats respond to hormone therapy in a similar manner (Oliveira *et al.*, 2003; Fits *et al.*, 2004). Therefore, in comparison with the animal model, the effects of sex steroid deficiency caused by castration are more prevalent in female than in male rats. Therefore, females have an increase in body weight, oral bone remodeling and increase in thickness of the periodontal ligament, and this is more event in time intervals of 60 and 90 days after castration (Armada *et al.*, 2006).

With the purpose of evaluating the influence of endodontic infection on thickening of the periodontal ligament, in the present study, the proposal was to evaluate the periradicular morphology in time intervals of 21 and 40 days after the induction of periradicular lesions in rats with osteoporosis induced by ovariectomy, compared with rats without osteoporosis induced.

2. Materials and Methods

This research project was conducted in accordance with the Ethical Principles of Animal Experimentation of the Brazilian College of Animal Experimentation (“Colégio Brasileiro de Experimentação Animal - COBEA”) and obtained approval from the Committee on Ethics and Animal research of UFF (CEPA), Protocol Number 00134/09.

2.1 Sample Selection

For conducting this study, isogenic, virgin, adult rats (n= 24), of the Wistar lineage (*Rattus Norvegicus Albinus*), 90 days old were used. They were kept in cages, at controlled ambient temperature (25 to 27°C), constant humidity and light/dark cycle of 12 hours (6:00h to 18:00h), with water and food (Nuvilab, Sogorb Indústria e Comércio LTDA, SP, Brazil) *ad libitum*. The animals were kept in the bioterium of the department of Physiopharmacology of the Biomedical Institute of the “Universidade Federal Fluminense” (UFF).

2.2 Determination of Phases of the Estrous Cycle

Daily collections of vaginal smears were performed between 9:00 and 10:00 hours for a period of fifteen days, for the purpose of sample selection. The vaginal fluid, collected with the aid of a plastic tip containing 0.9% sodium chloride solution, was deposited on glass slides, and was analyzed while fresh, under an optical microscope (Leica DM500, Heerbrugg, Sweden) with a 10x objective, The fluid was classified according to the properties of the types of cells found in each phase of the estrous cycle.¹² Only animals that had a regular estrous cycle were included in the study.

2.3 Castration

After this stage of evaluation and sample selection, half of the rats were submitted to bilateral removal of the ovaries (ovariectomy), under anesthesia with Thiopental (Thiopentax, Cristália, São Paulo, Brazil) (0.1ml /100 g body weight), while the remaining rats, Control Group, underwent surgical stress only (pseudo-operated).

2.4 Periradicular Lesion Development

One hundred and twenty days after surgery, all the animals were anesthetized with Thiopental (0.1ml /100g body weight); the enamel and dentin of the left mandibular first molars were worn with a ½ spherical carbide burr (KG Sorensen, São Paulo, Brazil) driven by a low-speed motor (Dentec, CS 421, Brazil). The opening was made in the mesial fossa of the occlusal surface until pulp was exposed.

Thus, 4 Experimental Groups were formed:

- Control Group with lesion of 21 days (C 21 days): n=6
- Ovariectomized Group with lesion of 21 days OVX 21 days): n=6
- Control Group with lesion of 40 days (C 40 days): n=6
- Ovariectomized Group with lesion of 40 days OVX 40 days): n=6

On conclusion of each experimental time interval (21 and 40 days after development of the lesion), the animals were

ethanized by exsanguination, under anesthesia with Thiopental (0.2 ml/100 g body weight), and the left hemi-mandibles were removed.

2.5 Optical Microscopy

After removal, the left hemi-mandibles were placed in a fixer (Bouin's solution) for 24 hours in refrigerator (3-10°C) and were then immersed in FAS decalcifying solution (10% acetic acid, 0.85% NaCl and 10% formalin solution), at ambient temperature for approximately 30 days. At the end of the decalcification period, the parts were embedded in paraffin. serial sections of 6µm were made in the mesio-distal direction and were stained with Hematoxylin-Eosin (HE), (Beçak&Paulete,1976; Lillie&Fullmei, 1976) and then observed under an Optical Microscope (Leica, model DMRBE).

2.6 Morphometric Analysis of the Periodontal Ligament

Morphometric analysis of the periodontal ligament was performed with images of the mandibular histological sections stained with the hematoxylin and eosin technique, by using a video microscope system (model DMRBE, Sony Video Camera; Leica). The periodontal ligament thickness was determined by the distance between the apical region and adjacent alveolar bone, by means of Image J software (National Institute of Mental Health, Bethesda, Maryland, USA).

2.7 Statistical Analysis

Comparative analysis of the data was performed by using the non-parametric *Kruskal-Wallis* and *Dunn Multiple Comparison tests*, with use of the *Graph Pad Prism 6* program (Graph Pad Software, Inc, California, USA). The statistical significance considered was $p < 0.05$.

3. Results

The numerical values of thickening of the periodontal ligament revealed significant increase in the periodontal ligament thickness of Group C 21 when compared with Group OVX 40 days ($p < 0.01$) and C 40 when compared with Group OVX 40 days ($p < 0.01$) (Table 1) (Figure 1).

Table 1 - Numerical values of periodontal ligament thickening.

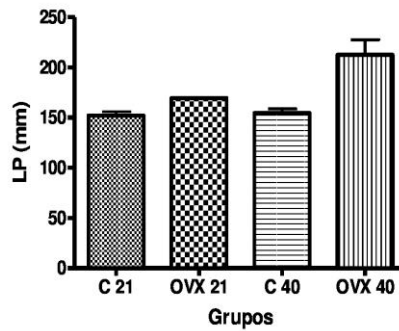
Periodontal Ligament Thickness	
Groups	Mean ± Standard Deviation
C 21	151.9± 9.0
OVX 21	169.2± 1.2
C 40	154.5± 9.4
OVX 40	212.3± 33.8

Source: Own authorship.

In Table 1 the results are expressed as means and standard deviations C: control for time intervals of 21, 40 days and

OVX: ovariectomized in time intervals of 21, 40 days. *Kruskal-Wallis Test* $p < 0.0083$ (value adjusted by Dunn Multiple Comparison test).

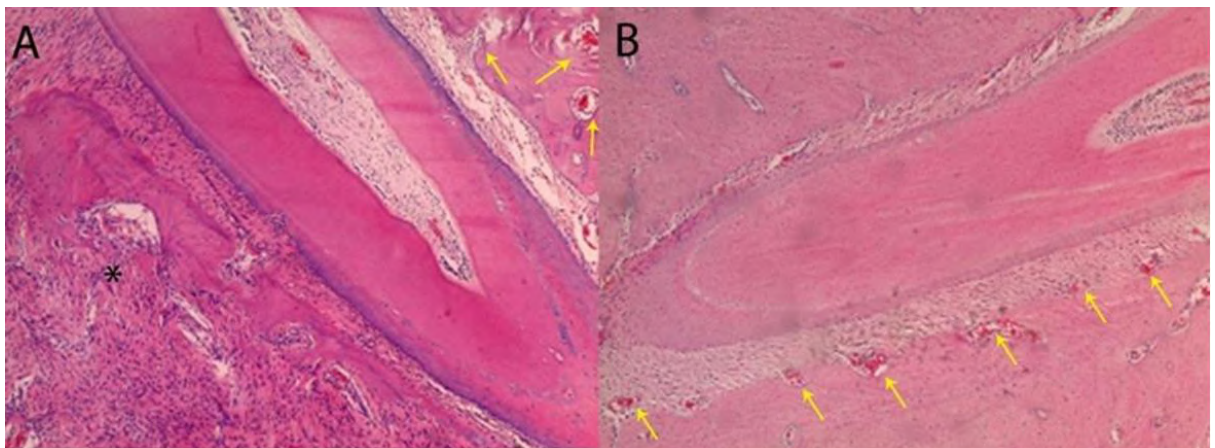
Figure 1 - Numerical values (mm) of thickening of the periodontal ligament increase between groups.



Source: Own authorship.

In Figure 1, the numerical values of thickening of the periodontal ligament increase in the periodontal ligament thickness of Group C 21 compared with Group OVX 40 days and C 40 when compared with Group OVX 40 days.

Figure 2 - Histological analyses.



Source: Own authorship.

In Figure 2 it is observed that Groups OVX demonstrated irregularities on the bone surface, associated to the presence of a higher number of osteoclasts, which had ample cytoplasm, nuclei and increase in inflammatory infiltrate into the adjacent tissue.

Table 2 - Serum estrogen assessment.

Estrogen (pgmL ⁻¹)	
Groups	Mean ± Standard Deviation
21-C	293.7 ± 5.12
21-OVX	56.3± 1.36*
40-C	280.42± 4.2
40-OVX	51.07± 3.81*

Source: Own authorship.

Table 2, analysis of serum level in ovariectomized rats (OVX) compared with the respective control (C) in different experimental time intervals. *P < 0.01 OVX vs. C. Data are presented with means and standard deviations. The validity of the results was based on the success of ovariectomy in induction of osteoporosis, by means of confirming the higher and more significant levels of serum estrogen, when compared with the Control Groups (p<0,01). In the intragroup evaluation, the Control Group showed no difference between the time intervals of 21 and 40 days. While in the Test Group (OVX) statistically significant difference was shown between the time intervals of 21 days and 40 days, with greater reduction in estrogen levels in Group OVX 40 (p <0.01).

4. Discussion

The increase in periodontal ligament thickness was significant in Group OVX 40, characterizing larger periradicular lesions. These findings demonstrated a relationship with the time of exposure to etiological factors of the endodontic infections, and corroborated the reports of (Friedman, 2008) and (Siqueira & Lopes, 2011), who established a correlation between size of the periradicular lesion and the number of bacteria, thereby pointing out the possibility of an unfavorable prognosis. These results corroborated the radiographic findings of BRASIL *et al.*, 2017 who verified that the long period of estrogen deficiency combined with infection of endodontic origin could influence the progression of apical periodontitis. Histological analysis is considered the gold standard in evaluating periodontal and periradicular status. Although periapical radiographs are invariably used as the main parameter for assessing thickening of the periodontal ligament and success of endodontic treatment, radiographic interpretation is subject to bias and may harm the reliability of the results.

Changes in bone metabolism, arising from sexual steroid deficiency in women in the postmenopausal period, constitute the main cause of osteoporosis (Horan & Timmins, 2009).

Induction of osteoporosis in adult rats was confirmed by evaluating the serum levels of estrogen, similarly to the findings of Gomes-Filho *et al.*, 2015. This animal model is well established and has been successfully reproduced in evaluations of the development of periradicular lesions (Qian *et al.*, 2016; Brasil *et al.*, 2017; Romualdo *et al.*, 2018).

Histologically, it was possible to recognize the imbalance of bone homeostasis, with an increase in osteoclasts and, consequently, bone resorption in the Ovariectomized Experimental Groups, in comparison with the Control that was not ovariectomized, but submitted only to surgical stress and induction of periradicular lesion. These findings corroborated those found by QIAN *et al.*, 2016, who observed increased bone resorption in the Ovariectomized Group, in comparison with the Pseudo-operated Group (P< 0.05). They also reported an increase in the osteoclast counts and resorption lacunae in Group OVX,

in comparison with the Control ($P < 0,01$). In a similar manner, Gomes-Filho *et al.*, 2015, presented findings of increase in osteoclasts, tissue resorption, and increase in inflammatory infiltrate in Group OVX when compared with Control Group, similar to the findings in the Test Group of the present study. This datum is valuable when we compare it with the findings of Romualdo *et al.*, 2018, who observed increase in the gene expression of pro-inflammatory MMPs, such as IL-1 β , TNF- α , IL-6, MMP-8 and MMP-13 in the Ovariectomized Group with induction of periradicular lesion. Moreover, the same increase was not repeated in the Ovariectomized Group without induction of periradicular lesion. This confirmed that the association of the condition of osteoporosis could be a modifying factor of induction of endodontic collapse, thereby aggravating the process of bone resorption of the periradicular lesion. In 2020, Qian *et al.*, 2020 also related the activity of FSH, which, in women, performs the function of estrogen production, with the direct increase in osteoclast formation. They suggested that FSH may also have an indirect effect on osteoclastogenesis by mean osteoclastogenesis s of the molecule of secretion of IL-1 β , IL-6, e TNF- α in fibroblasts of the periodontal ligament.

Relative to the systemic effects, they observed that increased FSH in postmenopausal women was related to a local increase in LPD, and concluded that the postmenopausal hormone effect associated with local factors such as bacterial plaque increased the susceptibility to more severe periradicular lesions. Estrogen was also associated with regulation of over expression of NLRP3/Caspase-1/IL-1 β in OVX rats between the time intervals of 7 and 28 days. This finding was related to the probability of aggravation of periradicular lesions in the experiment of Guan *et al.*, 2020.

5. Conclusion

Rats with osteoporosis induced by means of ovariectomy showed an increase in the quantity of osteoclasts and inflammatory infiltrate, factors that were related to the significant thickening of the periodontal ligament by means of induction of periradicular lesions. The increase in periodontal [ligament] thickness with osteoporosis induced, was associated with the time of exposure to low levels of estrogen and the infection of endodontic origin. These results suggested that changes in bone, as a result of a long period of estrogen deficiency, may have an influence on the progression of periradicular lesions. More future studies are needed to investigate the correlation between the effects of osteoporosis and periradicular injury, with the inclusion of other evaluation methods such as computed microtomography.

References

- Armada, L., Nogueira, C.R.R., Neves, U.L., Souza, P. S., Detogne, J.P., Armada-Dias, L., Moreira, R. M., & Nascimento-Saba, C. C. A. (2006). Mandible analysis in sex steroid-deficient rats. *Oral diseases*, 12(2), 181-186. [10.1111/j.16010825.2005.01184.x](https://doi.org/10.1111/j.16010825.2005.01184.x)
- Boyle, W.J., Simonet, W.S., Lacey, D. L. (2003). Osteoclast differentiation and activation. *Nature*, 423 (6937), 337-342. [10.1038/nature01658](https://doi.org/10.1038/nature01658)
- Brasil, S.C., Santos, R.M.M., Fernandes, A., Alves, F. R. F, Pires, F. R., Siqueira Jr, J.F., & Armada, L. (2017). Influence of oestrogen deficiency on the development of apical periodontitis. *International endodontic journal*, 50(2), 161-166. [10.1111/iej.12612](https://doi.org/10.1111/iej.12612)
- Faisal-Cury, A., & Zacchello, K. P. (2007). Osteoporose: prevalência e fatores de risco em mulheres de clínica privada maiores de 49 anos de idade. *Acta Ortopédica Brasileira*. 15(3), 146-150. doi.org/10.1590/S1413-78522007000300005
- Fitts, J.M., Klein, R.M., & Powers, C. A. (2004). Comparison of tamoxifen and testosterone propionate in male rats: differential prevention of orchidectomy effects on sex organs, bone mass, growth, and the growth hormone—IGF-I axis. *Journal of andrology*. 25(4), 523-534. [10.1002/j.1939-4640.2004.tb02823.x](https://doi.org/10.1002/j.1939-4640.2004.tb02823.x)
- Friedman, S. (2008). Expected outcome in the prevention and treatment of apical periodontitis. In: Ostarvik D, Pitt Ford T (eds) *essencial Endodontology*. Oxford, UK: Blackwell Munksgaard Ltd, 408-469.
- Gomes-filho, J.E., Wayama, T., Dornelles, R.C.M., Ervolino, E., Coclete, G.A., Duarte, P.C.T., Yamanri, G. H., Lodi, C. S., Dezan-Júnior, E., & Cintra, L.T.A. (2015). Effect of raloxifene on periapical lesions in ovariectomized rats. *Journal of endodontics*, 41(5), 671-675. [10.1016/j.joen.2014.11.027](https://doi.org/10.1016/j.joen.2014.11.027)

- Guan, X., Guan, Y., Shi, C., Zhu, X., He, Y., Wei, Z., Yang, J., & Hou, T. (2020). Estrogen deficiency aggravates apical periodontitis by regulating NLRP3/caspase-1/IL-1 β axis. *American journal of translational research*, 12(2), 660.
- Horan, A., & Timmins, F. (2009). The role of community multidisciplinary teams in osteoporosis treatment and prevention. *Journal of Orthopaedic Nursing*, 13, 85-96.
- Klibanski, A., Adams-Campbell, L., Bassford, T. L., & Blair, N. S. (2001). Osteoporosis prevention, diagnosis, and therapy. *Journal of the American Medical Association*, 285(6), 785-795. 10.1001/jama.285.6.785
- Lopez-Lopez, J., Castellanos-Cosano, L., Estrugo-Devesa, A., Gomez-Vaquero, C., Velasco-Ortega, E., & Segura-Egea, J.J. (2015). Radiolucent periapical lesions and bone mineral density in post-menopausal women. *Gerodontology*. 32,195–201. 10.1111/ger.12076
- Marcondes, F.K., Bianchi, F.J., & Tanno, A.P. (2002). Determination of the estrous cycle phases of rats: some helpful considerations. *Brazilian journal of biology*, 62(4A),609-614. 10.1590/s1519-69842002000400008
- Olivera, M.I., Bozzini, C., Meta, I.F., Bozzini, C. E., Alipi, R. M. (2003). The development of bone mass and bone strength in the mandible of the female rat. *Growth, development, and aging*, 67(2),85-93.
- Oseko, F., Yamamoto, T., Akamatsu, Y., Kanamura, N., Iwakura, Y., Imanishi, J., Kita, M. (2009). IL-17 is involved in bone resorption in mouse periapical lesions. *Microbiology and immunology*, 53(5), 287-294. 10.1111/j.1348-0421.2009.00123.x
- Qian, H., Guan, X., & Bian, Z. F.S.H. (2016). Aggravates bone loss in ovariectomised rats with experimental periapical periodontitis. *Molecular medicine reports*, 14(4),2997-3006. 10.3892/mmr.2016.5613
- Qian H, Jia J, Yang Y, & Bian Z, Ji Y. (2020). Follicle-Stimulating Hormone Exacerbates the Progression of Periapical Inflammation Through Modulating the Cytokine Release in Periodontal Tissue. *Inflammation*, 43,1572–1585. 10.1007/s10753-020-01234-9
- Romualdo, P.C., Lucisano, M., Paula-Silva, F.W.G., Leoni, G.B., Sousa-Neto, M.D., Silva, R.A.B., Silva, L. A.B., & Nelson-Filho, P. (2018). Ovariectomy exacerbates apical periodontitis in rats with an increase in expression of proinflammatory cytokines and matrix metalloproteinases. *Journal of Endodontics*, 44(5),780-785. 10.1016/j.joen.2018.01.010
- Siqueira, J.F., & Lopes, H. P. (2011). Treatment of endodontic infections. London, Quintessence.
- Yamashiro, T., & Takano-Yamamoto, T. (2001) Influences of ovariectomy on experimental tooth movement in the rat. *Journal of dental research*, 80(9),1858-1861. 10.1177/00220345010800091701
- Yao G.-Q., Itokawa, T., Paliwal, I., & Insogna, K. (2005). CSF-1 induces fos gene transcription and activates the transcription factor Elk-1 in mature osteoclasts. *Calcified tissue international*, 76(5),371-378. 10.1007/s00223-004-0099-8