

Clinical resolution in diagnosis of leukoplastic lesion associated with oral dysplasia: case report

Resolução clínica no diagnóstico de lesão leucoplásica associada à displasia oral: relato de caso

Resolución clínica en el diagnóstico de lesión leucoplásica asociada a displasia oral: reporte de caso

Received: 01/15/2023 | Revised: 01/22/2023 | Accepted: 01/23/2023 | Published: 01/26/2023

Angela Victoria de Souza Freire

ORCID: <https://orcid.org/0000-0001-6937-9969>

Nilton Lins University, Brazil

E-mail: freireangela12@gmail.com

Jefferson Pires da Silva Júnior

ORCID: <https://orcid.org/0000-0001-6977-1629>

Nilton Lins University, Brazil

E-mail: juniervasconcelos15@gmail.com

Bruna Mirely da Silva Cavalcante

ORCID: <https://orcid.org/0000-0003-2786-7686>

Nilton Lins University, Brazil

E-mail: brunnasilvva2101@gmail.com

Flávio Lima do Amaral Silva

ORCID: <https://orcid.org/0000-0002-4182-3316>

Nilton Lins University, Brazil

E-mail: flavio_amaral@live.com

Leandro Coelho Belém

ORCID: <https://orcid.org/0000-0001-5355-6262>

Nilton Lins University, Brazil

E-mail: leandro.belem@uniltonlins.edu.br

Allysson Soares

ORCID: <https://orcid.org/0000-0001-5485-0092>

Nilton Lins University, Brazil

E-mail: allyssons@hotmail.com

Abstract

The objective of the present study is to report a clinical case that emphasizes the diagnosis of mild epithelial dysplasia located in the unilateral region of the buccal mucosa. Patient, 49 years old, female, pheoderma, attended the dental clinic of the Nilton Lins University, referring a dental fracture as the main reason for the consultation. The intraoral clinical examination revealed a unilateral lesion in the buccal mucosa with plaque characteristics and whitish coloration. Initially, it was decided to perform an excisional biopsy of the lesion with a diagnostic hypothesis of lichen planus. The extracted pieces were sent to the Department of Pathology and Legal Medicine of the Federal University of Amazonas School of Medicine for confirmation of the diagnostic hypothesis, confirmed by the report as mild epithelial dysplasia. Subsequently, the patient was referred to perform the other dental procedures that were later scheduled and is under follow-up, with no complaints or adverse complications. Therefore, given the clinical resolution presented, the differential diagnosis was essential, enabling a satisfactory clinical conduct.

Keywords: Oral diagnosis; Biopsy; Hairy leukoplakia.

Resumo

O objetivo do presente trabalho é relatar um caso clínico que enfatiza o diagnóstico de displasia epitelial leve localizada em região unilateral de mucosa jugal. Paciente, 49 anos, gênero feminino, feoderma, compareceu à clínica de odontologia da Universidade Nilton Lins, relatando como queixa principal fratura dentária. No exame clínico intraoral, destaca-se lesão unilateral em mucosa jugal com característica de placa e coloração esbranquiçada. Inicialmente optou-se pela realização de biópsia excisional da lesão com hipótese diagnóstica de líquen plano. As peças removidas foram enviadas para o Departamento de Patologia e Medicina Legal da Faculdade de Medicina da Universidade Federal do Amazonas para confirmação da hipótese diagnóstica, confirmada através do laudo como displasia epitelial leve. A paciente foi então encaminhada para realização dos outros procedimentos odontológicos posteriormente planejados e segue em acompanhamento, não apresentando queixas ou complicações adversas. Portanto, diante da resolução clínica apresentada, o diagnóstico diferencial se mostrou essencial, possibilitando uma conduta clínica satisfatória.

Palavras-chave: Diagnóstico buccal; Biópsia; Leucoplasia oral.

Resumen

El objetivo de este estudio es reportar un caso clínico que enfatiza el diagnóstico de displasia epitelial leve localizada en la región unilateral de la mucosa bucal. Paciente, 49 años, sexo femenino, feoderma, acudió a la clínica de odontología de la Universidad Nilton Lins, refiriendo fractura dental como principal motivo de consulta. En el examen clínico intraoral destaca una lesión unilateral en la mucosa bucal con características de placa y coloración blanquecina. Inicialmente se decidió realizar una biopsia excisional de la lesión con hipótesis diagnóstica de liquen plano. Las piezas extraídas fueron enviadas al Departamento de Patología y Medicina Legal de la Facultad de Medicina de la Universidad Federal de Amazonas para la confirmación de la hipótesis diagnóstica, confirmada por el informe como displasia epitelial leve. Posteriormente se remitió al paciente para realizar los demás procedimientos odontológicos que luego se programaron y se encuentra en seguimiento, sin quejas ni complicaciones adversas. Por tanto, ante la resolución clínica presentada, el diagnóstico diferencial se mostró fundamental, posibilitando una conducta clínica satisfactoria.

Palabras clave: Diagnóstico buccal; Biopsia; Leucoplasia vellosa.

1. Introduction

In the daily clinical routine, the dentist is faced with adverse oral conditions, from oral lesions considered malignant, as well as benign (Speight et al., 2018). Oral epithelial dysplasia (OED) is an alteration of the epithelium with malignant potential which occurs through gradual and chronic development, if not treated, can progress to a potential squamous cell carcinoma (Pritzker et al., 2021; Moraes et al. al., 2020). In addition, this disorder presents itself in different degrees, namely: mild, moderate and severe (Ranganathan & Kavitha, 2019; Woo, 2019). In mild epithelial dysplasia (MED), cellular and architectural alterations are limited only to the basal and parabasal layers. In moderate cases, alterations go beyond these layers, reaching two thirds of the epithelium, while in severe cases two thirds are exceeded (Gupta et al.).

Clinically, OED can present in different forms, from leukoplakia to erythroplakia (Odell et al., 2021). Regarding its etiology, this epithelial anomaly is associated with its clinical manifestation since dysplasia is a disease detected only by histopathological examinations (Nag & Das, 2018). However, potentially malignant oral disorders are also associated with excessive consumption of cigarettes and/or alcohol (Speight et al., 2018). By removing the tissue fragment in the histopathology, it is possible to observe a set of alterations such as: irregular epithelial stratification, teardrop-shaped epithelial projections, and individual cells that exhibit premature keratinization (Pritzker et al., 2021; Moraes et al., 2020).

Furthermore, potentially malignant oral diseases may be clinically similar and have differential diagnoses due to their variation in shape, color and behavior with the underlying tissue (Pritzker et al., 2021; Woo., 2019). In these cases, a biopsy is required to aid in the conclusive diagnosis (Singh et al., 2021). This procedure can be performed incisionally through partial tissue removal or excisionally, with total tissue removal (Tilakaratne et al., 2019).

In the resolution of this anomaly, performing a previous biopsy to aid in the differential diagnosis is necessary as the only condition to determine the real state of the pathology and, thus guide the choice of treatment (Singh et al., 2021; Odell et al., 2021). There are solutions that are presented conservatively through the long-term follow-up indicated for injuries at a stage considered mild (Tilakaratne et al., 2019). However, when concentrated in a moderate or severe stage, surgical treatment aimed at total removal of the lesion is indicated (Awadallah et al., 2018).

Therefore, the objective of the present study is to report a clinical case that emphasizes the diagnosis of MED located in the unilateral region of the buccal mucosa.

2. Methodology

The present case report was performed in a single surgical moment and periodic clinical follow-ups. The present report was filed and approved by the Committee for Ethics and Research in Human Beings of Nilton Lins University under opinion number 5,632,356. The confidentiality and privacy of the patient who was informed about the treatment plan and

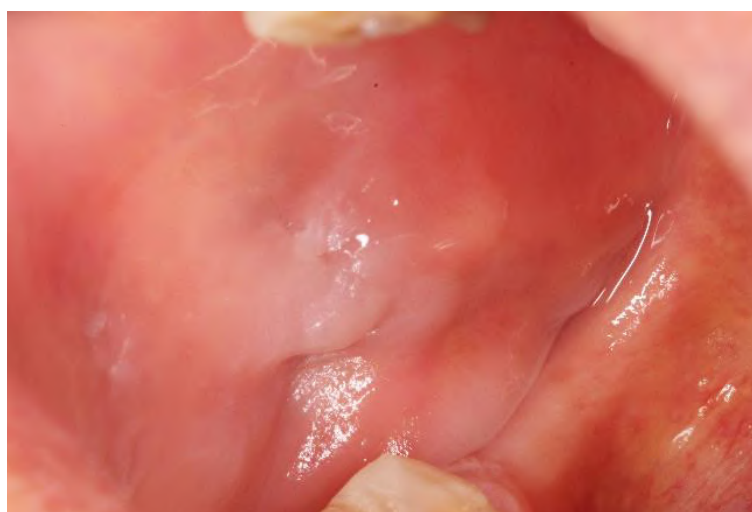
clarified about the risks and benefits of the procedure was respected. The patient signed the Terms of Free and Clear Consent to register her adherence to the present study. The description of this type of study can be found widely in the literature (Estrela, 2018).

3. Case Report

Patient, 49 years old, female, pheoderma, attended the Nilton Lins University dentistry clinic, reporting tooth fracture as the main complaint. After signing the free and informed consent form, she started the treatment. During the anamnesis, the patient reported daily use of cigarettes, in addition to the routine consumption of alcoholic beverages, which was explained as a way of dealing with her usual stress and anxiety. In addition, she declared that she had no other adverse systemic conditions.

In the extraoral clinical examination, there was no finding of significant clinical status. On the other hand, the intraoral examination highlighted: active cavitated lesions on teeth 15, 21, 35 and 43; indication of extraction of teeth 27 and 36; dental absence of teeth 16, 22, 24, 25, 26, 44, 45 and 46 and presence of calcified biofilm in the upper and lower arches. In addition to a unilateral lesion in the jugal mucosa located on the right side, with the characteristic of a plaque and whitish color, with no painful symptoms on palpation (Figure 1). In view of the reported case, the following treatment plan was chosen: scraping of the upper and lower arches; removal of root remnants; composite resin restorations and excisional biopsy of the lesion. Figure 1: Unilateral lesion in the buccal mucosa with plaque characteristics.

Figure 1 - Unilateral lesion in the buccal mucosa with plaque characteristics.

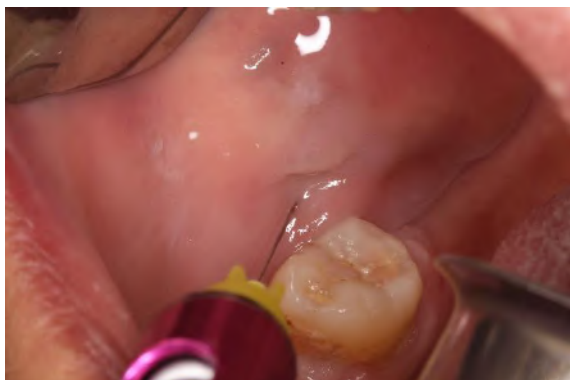

Source: Authors.

Based on the clinical characteristics presented, the diagnostic hypothesis of lichen planus was verified, requiring confirmation through a histopathological report. After planning, the surgery began. Intra and extraoral antisepsis were performed with 0.12% chlorhexidine digluconate in mouthwash for 1 minute; and 2% chlorhexidine digluconate, respectively, for topical use, followed by assembly of the operative field. Soon after, infiltrative anesthesia was performed in the peripheral zone of the lesion, with a margin of approximately 1 cm from the base, using 2% lidocaine associated with epinephrine at a concentration of 1:100,000 (Figure 2). When the effect of total analgesia was achieved, the base of the lesion was clamped using a curved Kelly clamp, delimiting the area to be sectioned (Figure 3). Once clamping was completed, the tissue was pulled in two directions, right and left, to aid removal during the incision step. Subsequently, the incision was made in each direction, removing the lesion through single and continuous cuts with a #15 scalpel blade following the clamping delimitation

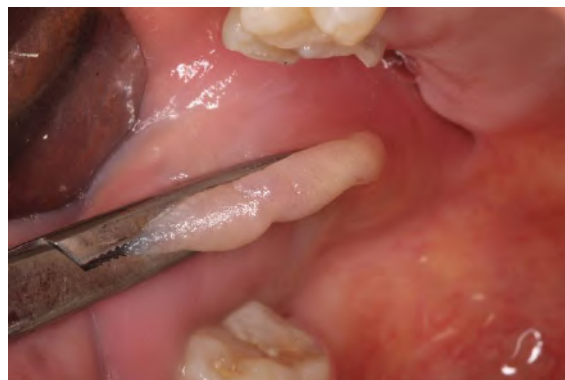(Figures 4 and 5).

Figure 2 - Infiltrative anesthesia.



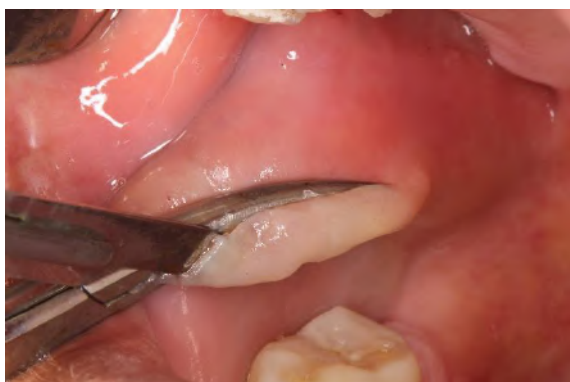Source: Authors.

Figure 3 - Clamping at the base of the lesion.



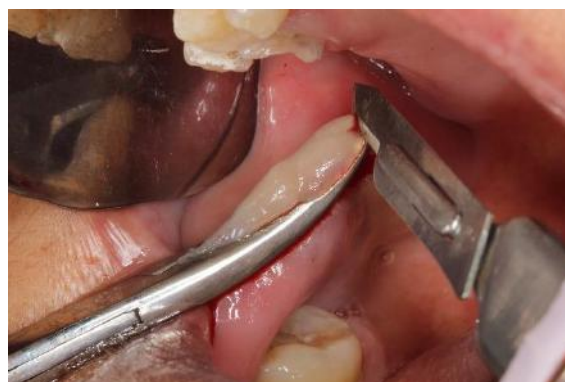Source: Authors.

Figure 4 - Upper peripheral incision.



Source: Authors.

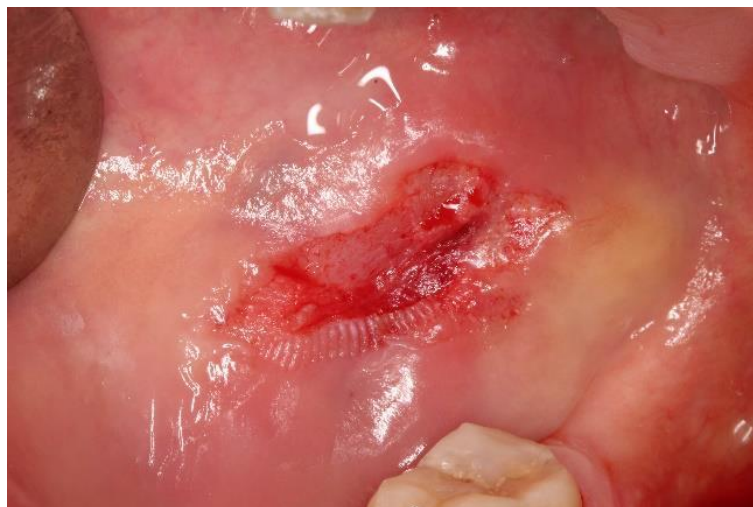Figure 5 - Inferior peripheral incision.



Source: Authors.

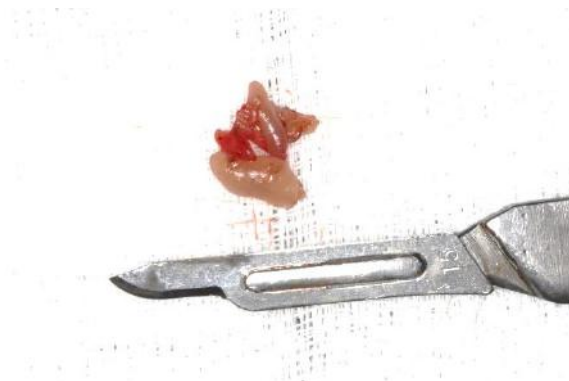Subsequently to the cuts, hemostasis was controlled with gauze soaked in a 0.9% saline solution on the tissue (Figure 6). In addition, the presence of minor salivary glands was not observed inside. Confirming the appropriate profile of the tissue and the absence of associated pathologies, the co-option of the ridge was concluded by means of suture with simple stitches, using 4-0 nylon thread. The removed parts were immersed in a 10% formaldehyde solution in collection pots and sent to the Department of Pathology and Legal Medicine of the Federal University of Amazonas School of Medicine for confirmation of the diagnostic hypothesis (Figures 7 and 8).

Figure 6 - Surgical area after removal of the lesion.



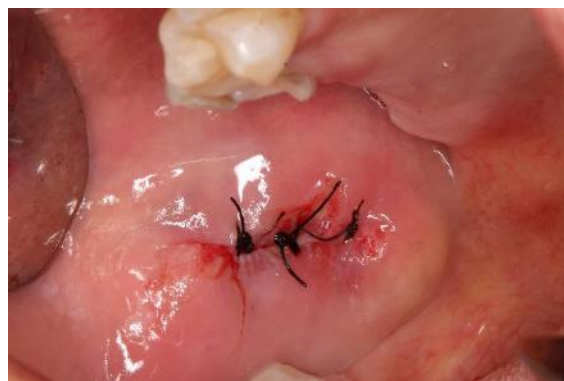Source: Authors.

Figure 7 - Surgical parts.



Source: Authors.

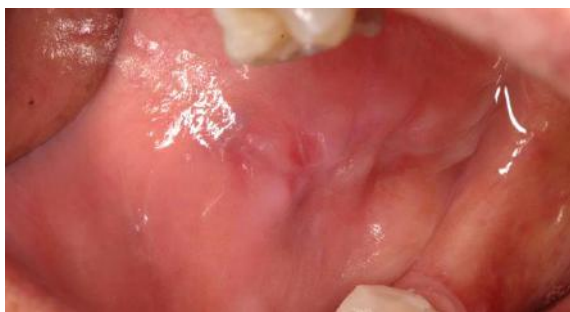Figure 8 - Synthesis with simple points.



Source: Authors.

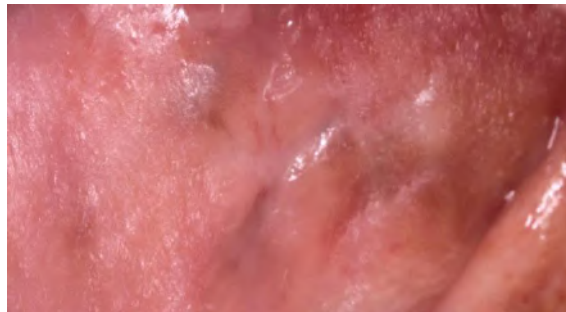For postoperative care, the following were prescribed: anti-inflammatory (nimesulide 100mg), 1 tablet every 12 hours for 3 days; and analgesic (dipyron sodium 500mg), 1 pill every 6 hours for 2 days. The patient was informed about dietary and hygiene care in the region where the surgical procedure was performed. After 10 days, she returned for the suture removal where adequate tissue healing still in the process of repair can be highlighted (Figure 9). The patient was then referred to perform the other dental procedures planned later. Furthermore, as a form of multidisciplinary treatment, she was also directed to seek psychological assessment. At the end of the 6-month follow-up period, the clinical characteristics of the mucosa continue to be normal, with no signs of adversity or recurrence of the pathology (Figure 10).

Figure 9 - Scar appearance after 10 days.



Source: Authors.

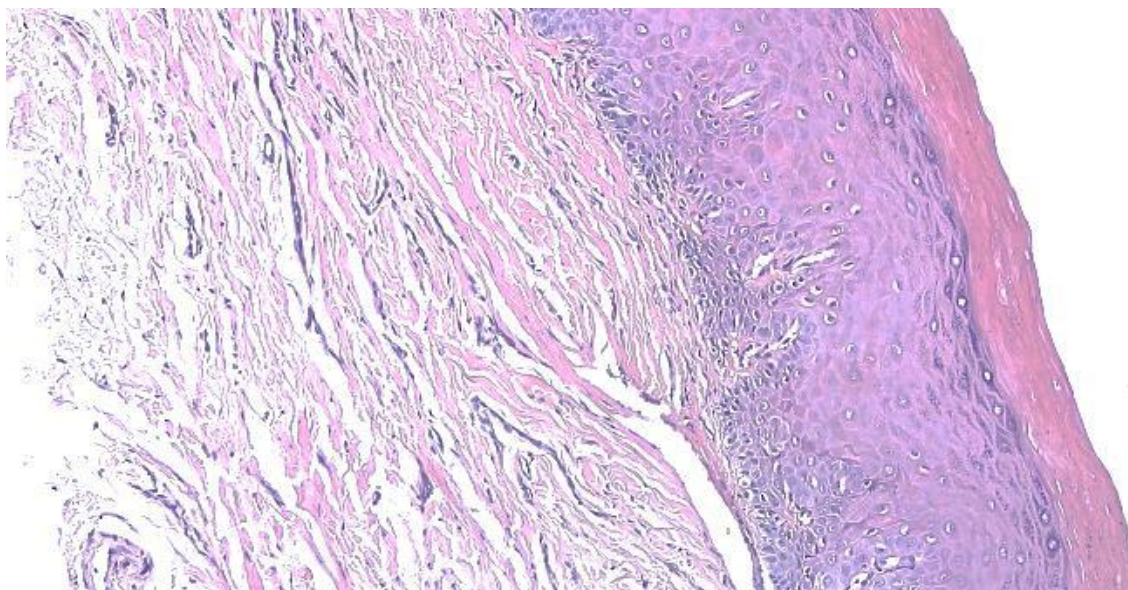
Figure 10 - Clinical appearance after 6 months.



Source: Authors.

In the histopathological sections stained with hematoxylin and eosin, the following is evident: tissue fragment characterized by changes in the epithelium lining represented by loss of sharpness. In addition, alteration in the basal layer with areas of acanthosis, hyperkeratosis and hyperchromatism was noted. The underlying connective tissue presented a discreet chronic inflammatory infiltrate. In view of the aforementioned observations, combined with the clinical characteristics present in the case, the lesion was diagnosed as MED (Figure 11).

Figure 11 - Histopathological section.



Source: Authors.

4. Discussion

During dental care, it is necessary to clinically recognize and evaluate lesions of the oral mucosa, being essential to detect possible signs of malignancy where histopathological examination in case of doubt is the best resource for lesions considered pre-malignant (Nag & Kumar Das., 2018; Abati et al., 2020). When previously diagnosed, potentially malignant lesions become conclusive, enabling their identification and indication for the most appropriate treatment (Tanriver et al., 2021). Considering that cases of mild, moderate and severe OED can progress to an oral squamous cell carcinoma, in which its evolution occurs according to the change in the diagnosed grade, early diagnosis is essential for treatment (Pritzker et al., 2021; Hankinson et al., 2021).

According to Locca et al. (2020), dysplasia, when in the mild stage, has a lower risk of evolution to oral cancer compared to the moderate or severe stages, requiring only surgical removal in cases of severe dysplastic lesions. In the present clinical case, as opposed to the literature because it is a lesion considered small, we opted for total surgical removal with extension to the adjacent healthy tissue. However Freitas et al. (2021), state that injuries considered serious should be surgically removed. There is a literary limitation related to the management of the lower categories, to the point that it can generate discussions about the permanence or removal of the pathological content.

When choosing the technique for performing the biopsy, whether partial or total, both are indicated for clinically diagnosed and/or perceptible dysplastic and malignant lesions (Essat et al., 2022). However, Kim et al. (2022), reported that in some cases, patients initially diagnosed with MED, where incisional removal was chosen after an interval of two years, were diagnosed with invasive carcinoma, demonstrating a short evolutionary period which may influence the choice of clinical management. In the present case, an excisional biopsy was performed, completely removing the lesion, a resource that may act directly in the intervention of the pathological condition.

For Bernard et al. (2021), the total removal of dysplastic lesions located in the oral epithelium does not reduce the rate of malignant progression, serving only for diagnosis and not for definitive curative management. Despite this, in a comparative study, Tilakaratne et al., (2019), reported that patients not treated surgically had a higher rate of malignant transformation compared to the operated group. In the present case report, the excisional biopsy was chosen not only to aid in the diagnosis, but also in the possible treatment in order to avoid a new surgical time since it acts in the total removal of the pathological fragment.

Regarding the use of the cutting instrument, during the excision of the lesion, excision can be performed using a scalpel blade or using a laser (Gilvetti et al., 2021; Suter et al., 2020) For Gilvetti et al. (2021), the indication of the instrument is directed to the extent of the lesion, where the scalpel is more indicated for well-defined lesions, while the laser at low intensity for more diffused areas. In addition, when performing biopsies with a laser or scalpel, the size of the lesion is taken into account when choosing the instrument due to the suspected level of intraoperative bleeding, opting for the use of laser, while the use of a scalpel is chosen for minor lesions (Suter et al., 2020).

There are also factors considered in a possible relationship between the disease and exogenous agents (Kierce et al., 2021; Porter et al., 2018). Alcohol and tobacco consumption, according to Kierce et al. (2021), are confirmed as risk factors for progression of squamous cell carcinoma, however, they also state that these factors are less defined when compared to risks for progression of OED. Porter et al. (2018) also associate these exposures with a strongly increased risk of carcinoma, on the other hand, they point out that patients with potentially malignant lesions, users of these exogenous agents, have an increased risk for progression to OED. In the present clinical case, the patient was instructed regarding the reduction of alcohol and tobacco consumption,

Male adults have a higher global prevalence for lesions considered pre-malignant or malignant (Mello et al., 2018). As for age, both these lesions stop appearing around the third to fifth decades of life in males (Singh et al., 2020). However, in the present clinical case, the patient was of the female gender, aged 49 years, demonstrating that despite the literature emphasizing the highest prevalence, gender is not a determining factor for the onset of the pathology, but rather a point to be considered in the course of the differential diagnosis.

5. Conclusion

Therefore, in view of the clinical resolution presented, the differential diagnosis proved to be essential, enabling a satisfactory clinical conduct. The patient is being followed up with no complaints or adverse complications. In addition, it is

important to highlight the need for further studies and research related to the topic addressed, aiming at understanding and mechanisms for the diagnosis and treatment of the pathology.

Acknowledgments

I would like to thank the Department of Pathology and Forensic Medicine of the Faculty of Medicine of the Federal University of Amazonas for carrying out the histopathological report stage.

References

- Abati, S., Bramati, C., Bondi, S., Lissoni, A., & Trimarchi, M. (2020). Oral cancer and precancer: a narrative review on the relevance of early diagnosis. *Int J Environ Res Public Health*, 17 (24), 9160.
- Awadallah, M., Idle, M., Patel, k., & Kademani, D. (2018). Management update of potentially premalignant oral epithelial lesions. *Oral Surg Oral Med Oral Pathol Oral Radiol*, 125 (6), 628-636.
- Bernard, C., Blanas, N., & Magalhães, M. (2021). Outcomes of oral epithelial dysplasia managed by observation versus excision at a Canadian Tertiary Centre. *J Oral Maxillofac Surg*, 79 (10), e98-e99.
- Essat, M., Cooper, K., Bessey, A., Clowes, M., Chilcott, J. B., Hunter, K. D., & et al. (2022). Diagnostic accuracy of conventional oral examination for detecting oral cavity cancer and potentially malignant disorders in patients with clinically evident oral lesions: Systematic review and meta-analysis. *Head & Neck*, 44 (4), 998-1013.
- Estrela, C. (2018). *Metodologia Científica: Ciências, Ensino, Pesquisa*. Editora Artes Médicas.
- Freitas, B. S., Batista, D. C. R., Roriz, C. F. S., Silva, L. R., Normando, A. G. C., Silva, A. R. S., & et al. (2021). Binary and WHO dysplasia grading systems for the prediction of malignant transformation of oral leukoplakia and erythroplakia: a systematic review and meta-analysis. *Clin Oral Investig*, 25 (7), 4329-4340.
- Gilvetti, C., Soneji, C., Bisase, B., & Barrett, A. W. (2021). Recurrence and malignant transformation rates of high grade oral epithelial dysplasia over a 10 year follow up period and the influence of surgical intervention, size of excision biopsy and marginal clearance in a UK regional maxillofacial surgery unit. *Oral Oncol*, 121, 105462.
- Gupta, R. K., Kaur, M., & Manhas, J. (2019). Tissue level based deep learning framework for early detection of dysplasia in oral squamous epithelium. *J Inf Syst*, 6 (2), 81-86.
- Hankinson, P. M., Mohammed-Ali, R. I., Smith, A. T., & Khurram, S. A. (2021). Malignant transformation in a cohort of patients with oral epithelial dysplasia. *Br J Oral Maxillofac Surg*, 59 (9), 1099-1101.
- Kierce, J., Shi, Y., Klieb, H., Blanas, N., Xu, W., & Magalhães, M. (2021). Identification of specific clinical risk factors associated with the malignant transformation of oral epithelial dysplasia. *Head Neck*, 43 (11), 3552-3561.
- Kim, E., Chung, M., Jeong, H. S., Baek, C. H., & Cho, J. (2022). Histological features of differentiated dysplasia in the oral mucosa: a review of oral invasive squamous cell carcinoma cases diagnosed with benign or low-grade dysplasia on previous biopsies. *Hum Pathol*, 126, 45-54.
- Locca, O., Sollecito, T. P., Alawi, F., Weinstein, G. S., Newman, JG., & et al. (2020). Potentially malignant disorders of the oral cavity and oral dysplasia: a systematic review and meta-analysis of malignant transformation rate by subtype. *Head Neck*, 42 (3), 539-555.
- Mello, F. W., Miguel, A. F. P., Dutra, K. L., Porporatti, A. L., Warnakulasuriya, S., Guerra, E. N. S., & et al. (2018). Prevalence of oral potentially malignant disorders: a systematic review and meta-analysis. *J Oral Pathol Med*, 47 (7), 633-640.
- Moraes, E. F., Pinheiro, J. C., Lira, J. A., Mafra, R. P., Barbosa, C. A., Souza, L. B., & et al. (2020). Prognostic value of the immunohistochemical detection of epithelial-mesenchymal transition biomarkers in oral epithelial dysplasia: a systematic review. *Med Oral Patol Oral Cir Bucal*, 25 (2), 205-216.
- Nag, R., & Kumar, Das R., (2018). Analysis of images for detection of oral epithelial dysplasia; a review. *Oral Oncol*, 78, 8-15.
- Odell, E., Kujan, O., Warnakulasuriya, S., & Sloan, P. (2021). Oral epithelial dysplasia: recognition, grading clinical significance. *Oral Dis*, 27 (8), 1947-1976.
- Porter, S., Gueiros, L. A., Leão, J. C., & Fedele, S. (2018). Risk factors and etiopathogenesis of potentially premalignant oral epithelial lesions. *Oral Surg Oral Med Oral Pathol Oral Radiol*, 125 (6), 603-611.
- Pritzker, K. P. H., Darling, M. R., Hwang, J. T., & Mock, D. (2021). Oral potentially malignant disorders (OPMD): what is the clinical utility of dysplasia grade? *Expert Rev Mol Diagn*, 21 (3), 289-298.
- Ranganathan, K., & Kavitha, L. (2019). Oral epithelial dysplasia: classifications and clinical relevance in risk assessment of oral potentially malignant disorders. *J Oral Maxillofac Pathol*, 23 (1), 19-27.
- Singh, H. P., Thippeswamy, S. H., Gandhi, P., Salgotra, V., Choudhary, S., & Agarwal, R., (2021). A retrospective study to evaluate biopsies of oral and maxillofacial Lesions. *J Pharm Bioallied Sci*, 13 (1), 116-119.

Singh, S., Singh, J., Chandra, S., & Samadi, F. M. (2020). Prevalence of oral cancer and oral epithelial dysplasia among north indian population: a retrospective institutional study. *J Oral Maxillofac Pathol*, 24(1), 87-92.

Speight, P. M., Khurram, S. A., & Kujan, O. (2018). Oral potentially malignant disorders: risk of progression to malignancy. *Oral Surg Oral Med Oral Pathol Oral Radiol*, 125 (6), 612-627.

Suter, V. G. A., Altermatt, H. J., & Bornstein, M. M. (2020). A randomized controlled trial comparing surgical excisional biopsies using CO2 laser, Er:YAG laser and scalpel. *Int J Oral Maxillofac Surg*, 49 (1), 99-106.

Tanriver, G., Soluk, T. M., & Ergen, O. (2021). Automated detection and classification of oral lesions using deep learning to detect oral potentially malignant disorders. *Cancers*, 13 (11), 2766.

Tilakaratne, W. M., Jayasooriya, P. R., Jayasuriya, N. S., & De Silva, R. K. (2019). Oral epithelial dysplasia: causes, quantification, prognosis, and management challenges. *Periodontol 2000*, 80 (1), 126-147.

Woo, S. B., (2019). Oral epithelial dysplasia and premalignancy. *Head Neck Pathol*, 13 (3), 423-439.