

## Management of external cervical resorption with internal approach: 18 months of follow-up

Manejo da reabsorção cervical externa com abordagem interna: 18 meses de acompanhamento

Manejo de la resorción cervical externa con abordaje interno: 18 meses de seguimiento

Received: 06/02/2023 | Revised: 06/13/2023 | Accepted: 06/14/2023 | Published: 06/18/2023

### **Keren Scheidegger de Aguiar da Fonsêca**

ORCID: <https://orcid.org/0000-0002-1681-5330>  
Universidade Federal do Espírito Santo, Brasil  
E-mail: [kerenfonseca@hotmail.com](mailto:kerenfonseca@hotmail.com)

### **Claudia Mendonça Reis Romano**

ORCID: <https://orcid.org/0000-0002-9421-2455>  
Universidade Federal do Espírito Santo, Brasil  
E-mail: [claudiareis.endo@gmail.com](mailto:claudiareis.endo@gmail.com)

### **Juliana Machado Barroso Xavier**

ORCID: <https://orcid.org/0000-0001-8523-2406>  
Universidade Federal do Espírito Santo, Brasil  
E-mail: [julimbarroso@hotmail.com](mailto:julimbarroso@hotmail.com)

### **Iandara de Lima Scardini**

ORCID: <https://orcid.org/0000-0001-8573-211X>  
Universidade de São Paulo, Brasil  
E-mail: [iandara.scardini@gmail.com](mailto:iandara.scardini@gmail.com)

### **Francisco Carlos Ribeiro**

ORCID: <https://orcid.org/0000-0001-9085-1447>  
Universidade Federal do Espírito Santo, Brasil  
E-mail: [franciscocarlosr@hotmail.com](mailto:franciscocarlosr@hotmail.com)

### **Abstract**

**Introduction:** External cervical resorption (ECR) in advance stages may have a probable pulp involvement. In some of these cases, the accessibility of the resorptive process can be performed by an intraradicular approach. **Aim:** To report the management of an ECR, classified as Class 2cp according to Patel classification, with an internal approach. **Case report:** A 22-year-old male patient presented a complaint of dentin hypersensitivity related to left maxillary lateral incisor and reported a history of previous dental trauma. Based on the clinical, radiographic and tomographic findings, the left maxillary lateral incisor was diagnosed as symptomatic irreversible pulpitis with ECR class 2cp of Patel classification. The patient was scheduled for endodontic treatment, with an internal approach, and repair of the resorbed area. Intracanal dressing of calcium hydroxide paste was used in the root canal and resorption gaps. The root canal filling was performed in two steps: obturation of the apical and middle third with gutta-percha by lateral condensation technique and obturation of the cervical third and filling the resorbed area with MTA. After 18 months signs and symptoms compatible with success were observed, and the tomographic and radiographic images suggested a successful endodontic treatment and evolutionary process of repair of bone and mineralized dental tissues. **Conclusion:** Patel class 2cp ECR treatment through an internal approach, including conventional endodontic treatment and recovery of the reabsorbed area with calcium hydroxide and MTA is a viable treatment option, but may cause tooth discoloration.

**Keywords:** Endodontics; Case reports; Tooth resorption; Root canal therapy.

### **Resumo**

**Introdução:** A reabsorção cervical externa (RCE) em estágios avançados pode ter um provável envolvimento pulpar. Em alguns desses casos, o acesso ao processo reabsortivo pode ser realizado por uma abordagem intrarradicular. **Objetivo:** Relatar o tratamento de uma RCE, classificada como Classe 2cp segundo a classificação de Patel, através de uma abordagem interna. **Relato de caso:** Paciente do gênero masculino, 22 anos, apresentou queixa de hipersensibilidade dentinária relacionada ao incisivo lateral superior esquerdo com histórico de trauma dental prévio. Com base nos achados clínicos, radiográficos e tomográficos, o incisivo lateral superior esquerdo foi diagnosticado como pulpite irreversível sintomática com RCE classe 2cp de Patel. O paciente foi encaminhado para tratamento endodôntico, com abordagem interna, e reparo da área reabsorvida. Medicação intracanal de pasta de hidróxido de cálcio foi utilizada no canal radicular e nas lacunas de reabsorção. A obturação do canal radicular foi realizada em duas etapas: obturação do terço apical e médio com gutta-percha pela técnica de condensação lateral e obturação do terço cervical e preenchimento da área reabsorvida com MTA. Após 18 meses foram observados sinais e sintomas

compatíveis com sucesso, sendo que as imagens tomográficas e radiográficas sugeriram sucesso do tratamento endodôntico e processo evolutivo de reparação do osso e tecidos dentários mineralizados. Conclusão: O tratamento da RCE classe 2cp de Patel através de uma abordagem interna, incluindo tratamento endodôntico convencional e recuperação da área reabsorvida com hidróxido de cálcio e MTA é uma opção de tratamento viável, mas pode causar descoloração dentária.

**Palavras-chave:** Endodontia; Relatos de caso; Reabsorção de dente; Tratamento do canal radicular.

### Resumen

**Introducción:** La reabsorción cervical externa (RCE) en estadios avanzados puede tener probable afectación pulpar. En algunos de estos casos, el acceso al proceso de reabsorción puede lograrse mediante un abordaje intraradicular. **Objetivo:** Reportar el tratamiento de una RCE, clasificada como Clase 2cp según la clasificación de Patel, a través de un abordaje interno. **Caso clínico:** Paciente masculino de 22 años de edad, consulta por hipersensibilidad dentinaria en incisivo lateral superior izquierdo con antecedente de trauma dentario previo. Con base en los hallazgos clínicos, radiográficos y tomográficos, el incisivo lateral superior izquierdo fue diagnosticado como pulpitis irreversible sintomática con RCE clase 2cp de Patel. El paciente fue derivado para tratamiento endodóntico, con abordaje interno, y reparación del área reabsorbida. Se utilizó medicación intracanal de pasta de hidróxido de calcio en el conducto radicular y en los espacios de reabsorción. La obturación del conducto radicular se realizó en dos tiempos: obturación de los tercios apical y medio con gutapercha mediante la técnica de condensación lateral y obturación del tercio cervical y obturación de la zona reabsorbida con MTA. A los 18 meses se observaron signos y síntomas compatibles con el éxito, con imágenes tomográficas y radiográficas que sugerían un tratamiento endodóntico exitoso y un proceso evolutivo de reparación ósea y mineralización de los tejidos dentarios. **Conclusión:** El tratamiento de RCE clase 2cp de Patel mediante un abordaje interno, incluyendo tratamiento endodóntico convencional y recuperación del área reabsorbida con hidróxido de calcio y MTA es una opción de tratamiento viable, pero puede causar decoloración dental.

**Palabras clave:** Endodoncia; Informes de casos; Resorción dentaria; Tratamiento del conducto radicular.

## 1. Introduction

According to the American Association of Endodontic (2020) resorption is a condition associated with either a physiologic or a pathologic process resulting in a loss of dentin, cementum and/or bone (AAE, 2020). External cervical resorption (ECR) is a type of pathological resorption which initiated on the external aspect of the root, below the epithelial attachment (Heithersay, 2004; Patel & Beddis, 2019). The etiology of ECR remains unclear and several potential predisposing factors have been identified, such as trauma, intracoronal bleaching, orthodontics, orthognathic and other dentoalveolar surgery (Heithersay, 1999; Mavridou et al., 2017; Irinakis et al., 2020).

The clinical presentation of ECR varies considerably depending on the extent of the resorptive process (Heithersay, 2004). In early stage, the affected tooth is commonly asymptomatic, and ECR may be an incidental radiographic finding as a radiolucency in the cervical region of a tooth. In advanced stage, cervical cavitation, localized gingival inflammation and bleeding, contour and/or pinkish discoloration of the overlying enamel may be present (Patel & Beddis, 2019; Heithersay, 1999; Mavridou et al., 2017; Consolaro, 2016; Algedairi, 2019). At this stage, the patient may present with pulpal and/or periapical symptoms (Patel et al., 2009).

The radiographic appearance of ECR is variable and influenced by the size and nature of the lesion (Patel et al., 2018). If the lesion is proximally located, radiographic assessment shows an irregular mottled, or ‘moth-eaten’ image in the main lesion area and radiopaque line of demarcation between the resorptive lesion and that of an apparently intact dental pulp (Heithersay, 2004; Consolaro, 2016). However, according to European Society of Endodontology there is no classical radiographic appearance of ECR lesion, and the limitations of periapical radiographs can result in misdiagnosis and/or poor management (ESE, 2018). Authors suggest that cone beam computed tomography (CBCT) is more suitable for diagnosis, treatment planning, to determine the location and extent of the defect, the restorability of the tooth and the proximity of the lesion relative to the pulp canal (Patel & Beddis, 2019; Irinakis et al., 2020; Patel et al., 2018a; ESE, 2018; Aljarbou, 2029; Rodrigues Mazón et al., 2022).

The objectives of treatment of ECR lesion are the elimination of the resorptive tissue, sealing of the resultant defect

and prevention of recurrence, being significantly influenced by its location, nature, stage of progression, and accessibility of resorptive process (Heithersay, 2004; Patel & Beddis, 2019). Internal repair associated with root canal treatment is one of the treatment options for ECR proposed by ESE (2018), indicated when there is pulp involvement and the accessibility of the resorptive process is performed by an internal approach (Patel et al., 2018b). This case report presents the nonsurgical management of a tooth with ECR Patel class 2Cp lesion (Patel et al., 2018a), including conventional endodontic treatment and sealing of the resultant defect with Mineral Trioxide Aggregate (MTA) by an internal approach.

## 2. Methodology

The present study is a case report with a single patient retrospective description, focused in a phenomenon that was described in maximum detail as possible (Pereira et al., 2018; Alpi, 2019). The evaluated tooth was diagnosed with a ECR treated with an internal approach. Follow-up was carried out between June 13, 2018, and November 25, 2019. The case report nature is qualitative and descriptive.

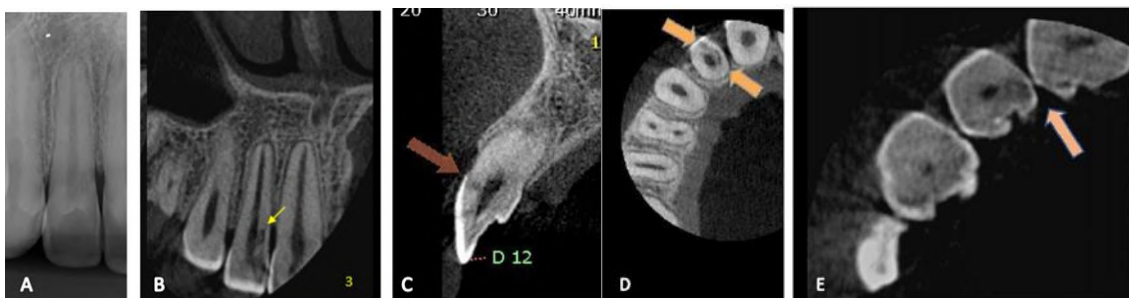A written informed consent was obtained from the patient before the treatment. This case report was approved by the Ethics Committee of the University (protocol number 98743318.6.0000.5060) and follows the ethical principles of the Declaration of Helsinki.

## 3. Case Report

A 22-year-old male patient presented at the clinic of the School of Dentistry of the Federal University of Espírito Santo, Brazil. The patient reported pain related to left maxillary lateral incisor, with exacerbation when exposed to heat or cold, and with pulsation at night. The patient reported a history of dental trauma involving this tooth when he was 12 years old, and six months after dental trauma, he underwent orthodontic treatment. An intraoral clinical examination showed presence of a small localized swelling in the marginal gingival of tooth No. 22, without tenderness to percussion or palpation. The tooth was responsive to thermal pulp test, with an intense and prolonged sensitivity. On probing, a respective pocket depth of 6 mm was detected in the mesiobuccal region of left maxillary lateral incisor.

Radiographic assessment showed an irregular mottled radiolucency mesial to the pulp space of tooth No. 22 with preservation of the pulpal limits, and a breakdown of the crest of alveolar bone mesial (Figure 1 A).

**Figure 1** - In A, radiographic examination showing an irregular mottled radiolucency mesial to pulp space, and a breakdown of the crest of alveolar bone mesial of left maxillary lateral incisor. In B, C, D, and E, CBCT examination showing a hypodense area with radicular perforation in cervical third of left maxillary lateral incisor, and the breakdown of the crest of alveolar bone underlying the area of ECR (orange arrows).



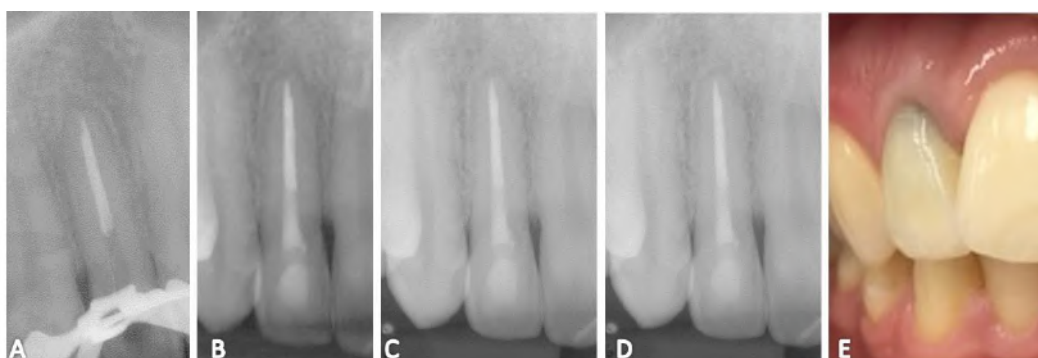
Fonte: Autores.

CBCT examination revealed a hypodense area with a circumferential spread of 180° in the cervical region of tooth No. 22, and with radicular perforation of the existing resorption defect (Figures 1 B, C, D and E).

Based on the clinical, radiographic and tomographic findings, the tooth No. 22 was diagnosed as symptomatic irreversible pulpitis with ECR Patel class 2Cp lesion. Thus, the treatment plan included the management nonsurgical of the root canal and repair of the resorptive defect via an orthograde approach using MTA.

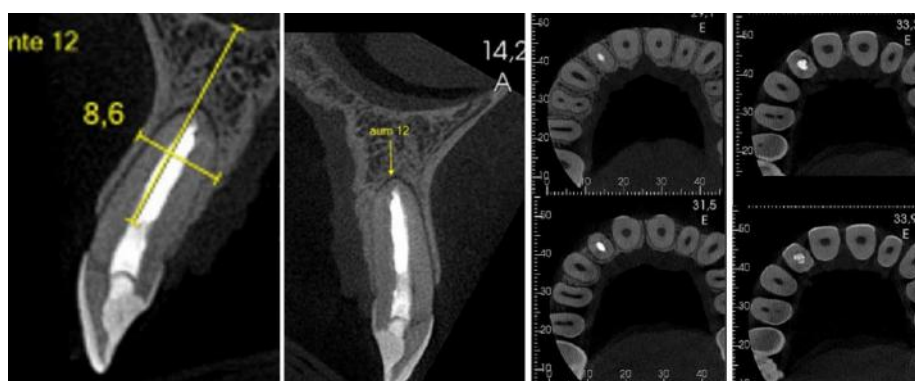
The root canal treatment was performed using the modified Oregon technique, with hand files and 2.5% sodium hypochlorite. After chemo-mechanical preparation, the resorptive defects and root canal system were filled with an intracanal dressing of calcium hydroxide paste. On the second appointment, apical and middle third of root canal were filling with gutta-percha and AH Plus cement (Dentsply Sirona, Ballaigues, Switzerland), using the Tagger's Hybrid technique, at the level of ECR lesion (Figure 2a). The resorption defects and root canal cervical third were sealed with white MTA (Angelus, Londrina, Brazil) and the crown was restored with glass ionomer cement (Maxxion R; FGM, Santa Catarina, Brazil) (Figure 2b). The patient was referred to the Department of Restorative Dentistry for definitive restoration.

**Figure 2** - In A, conventional root canal filling of apical and middle third with gutta-percha and AH Plus sealer. In B, filling of resorption defects and the cervical third with white MTA. In C fifteen months follow-up. In D, eighteen months follow-up. In E, tooth discoloration.



Fonte: Autores.

**Figure 3** - Eighteen months after treatment; CBCT images showing the restoration of the crestal alveolar bone, a progressive bone neoformation, and a good adaption to the MTA (21 November 2019).



Fonte: Autores.

Radiographic and tomographic images of fifteen- and eighteen-months follow-ups showed the restoration of the crestal alveolar bone, a progressive bone neoformation, and a good adaption to the MTA (Figures 2c, 2d and Figure 3). Clinical examinations revealed absence of signal and symptoms and normal color of surrounding soft tissue. A tooth discoloration was observed (Figure 2e).

#### 4. Discussion

The etiology of ECR is not well understood, although dental trauma and orthodontics are associated with more than 35% of ECR cases (Patel & Beddis, 2019; Heithersav, 1999; Mavridou et al., 2017; Irinakiset al., 2020). This case report showed the effect of a non-surgical approach in the success of treatment of a tooth with ECR Patel class 2Cp lesion, with historic of dental trauma and orthodontics.

The space of root canal is surrounded by a protective layer, resistant to the resorptive process, identified radiographically by a radiopaque line<sup>15</sup>. This layer is referred to as the pericanalar resorption-resistant sheet (PRRS), and consists primarily of predentine and dentine (Mavridou et al., 2016). The presence of this barrier explains the asymptomatic nature of ECR at initial stage and it could be postulated that pulpal symptoms only develop when the resorption ultimately penetrates through PRRS and is secondarily invaded by oral microorganisms (Heithersav, 2004). Thus, ECR represents an asymptomatic condition at early and intermediate stages, with scarcity of clinical signs. In most of cases, ECR lesion is diagnosed in advanced stages, when they are symptomatic, and show clinical signs, such as a cervical pink stain and other findings (Patel et al., 2009; Pace et al., 2018). In this case report, the diagnosis of ECR was established 10 years later dental trauma and orthodontics, when the pulpal symptoms were present.

The management of ECR lesion depends on several factors, such as its location, nature, stage of progression, and accessibility of resorptive process (Heithersav, 2004; Patel & Beddis, 2019; ESE, 2018). The ESE and American Association of Endodontists & American Academy of Oral & Maxillofacial Radiology recommends that CBCT should be considered for the assessment and/or management of root resorption (Patel et al., 2018a). Early diagnosis and appropriate management have shown to improve the likelihood of tooth retention (Heithersav, 2004), and the CBCT scan has demonstrated a significant impact on clinical decision-making in cases of ECR (Rodrigues Mazón et al., 2022). Recently, authors have classified ECR into 3-dimensions, considering the ECR lesion height, circumferential spread, and proximity to the root canal (Patel et al., 2018a). ESE used this classification for the most recent position statement of ECR which recommends internal repair and root canal treatment in cases classified as Class 2Cp, according to Patel classification based on CBCT images, like present study (ESE, 2018). The root canal treatment was required due diagnosis of symptomatic irreversible pulpitis.

The objectives of treatment of ECR lesion are the elimination of the resorptive tissue, sealing of the resultant defect and prevention of recurrence, (Heithersav, 2004; Patel & Breddis, 2019; ESE, 2018). In the present case report a CaOH-based intracanal medication was used to interrupt the resorptive process, reducing the action of osteoclasts. Besides that, CaOH has an antibacterial action, reduces the clastic activity, stimulates repair and inducts of hard tissue deposition, being indicated in cases of root resorptions (Farhad & Mohammadi, 2005).

The correct filling of the resorption defect using a material with a good sealing ability and excellent biocompatibility, cease the process and its recurrence is not detected. MTA was used to seal the resorption defect, and showed a restoration of crestal alveolar bone and good adaption (Algedairi, 2019; Pace et al., 2008; Yilmar et al., 2010). The MTA have a good sealing ability that can serve as repair material, present excellent biocompatibility, but cause tooth discoloration, as seen in the present study (Figure 2e). More recently, new formulations of tricalcium silicate-based materials have been introduced as an alternative to MTA. These materials, such as Biodentin, presents better physical, chemical, and biological properties, and do not cause tooth discoloration, have no long setting time and have better handling properties than MTA (Algedairi, 2019; Hung et al., 2014; Kaup et al., 2015) and can be an alternative in cases of ECR (Rotondi et al., 2020; Howait et al., 2021).

#### 5. Final Considerations

The nonsurgical management, with an internal approach of external cervical resorption (ECR), classified as Class 2cp



according to Patel classification, including conventional endodontic treatment and reparation of the resorbed area with calcium hydroxide and Mineral Trioxide Aggregate, is a viable treatment option, however it can cause tooth discoloration.

For future research and articles, new materials based on calcium silicate should be investigated in cases of ECR treated with internal approach.

## References

- AAE. (2020). Glossary of Endodontic Terms. American Association of Endodontists.
- Aljarbou F. A. (2019). Five-Year Recall after Treatment of External Cervical Resorption. *Case reports in dentistry*, 2019, 4957408. <https://doi.org/10.1155/2019/4957408>.
- Alqedairi A. (2019). Non-Invasive management of invasive cervical resorption associated with periodontal pocket: A case report. *World journal of clinical cases*, 7(7), 863–871. <https://doi.org/10.12998/wjcc.v7.i7.863>.
- Alpi, K. M., & Evans, J. J. (2019). Distinguishing case study as a research method from case reports as a publication type. *Journal of the Medical Library Association: JMLA*, 107(1), 1–5. <https://doi.org/10.5195/jmla.2019.615>
- Consolaro A. (2016). External cervical resorption: diagnostic and treatment tips. *Dental Press Journal of Orthodontics*, 2016; 21 (5): 19-25. <https://doi.org/10.1590/2177-6709.21.5.019-025.oin>
- European Society of Endodontology (ESE) developed by, Patel, S., Lambrechts, P., Shemesh, H., & Mavridou, A. (2018a). European Society of Endodontology position statement: External Cervical Resorption. *International endodontic journal*, 51(12), 1323–1326. <https://doi.org/10.1111/iej.13008>.
- Farhad, A., & Mohammadi, Z. (2005). Calcium hydroxide: a review. *International dental journal*, 55(5), 293–301. <https://doi.org/10.1111/j.1875-595x.2005.tb00326.x>.
- Heithersay G. S. (1999). Invasive cervical resorption: an analysis of potential predisposing factors. *Quintessence international*, 30(2), 83–95.
- Heithersay GS. (2004). Invasive cervical resorption. *Endodontic Topics*; 7 (1): 73–92. <https://doi.org/10.1111/j.1601-1546.2004.00060.x>
- Howait, M., Shaker, M., Aljuhani, H., & AlMohnna, M. (2021). External Cervical Resorption: A Case Report and Brief Review of the Literature, and Treatment Algorithms. *The journal of contemporary dental practice*, 22(3), 298–303.
- Hung C. J., Kao C. T., Shie M. Y., Huang T. H. (2014). Comparison of host inflammatory responses between calcium-silicate base material and IRM. *Journal of Dental Sciences*; 9: 158–164. <https://doi.org/10.1016/j.jds.2013.08.002>
- Irinakis, E., Aleksejuniene, J., Shen, Y., & Haapasalo, M. (2020). External Cervical Resorption: A Retrospective Case-Control Study. *Journal of endodontics*, 46(10), 1420–1427. <https://doi.org/10.1016/j.joen.2020.05.021>.
- Kaup, M., Schäfer, E., & Dammaschke, T. (2015). An in vitro study of different material properties of Biodentine compared to ProRoot MTA. *Head & face medicine*, 11, 16. <https://doi.org/10.1186/s13005-015-0074-9>
- Mavridou, A. M., Bergmans, L., Barendregt, D., & Lambrechts, P. (2017). Descriptive Analysis of Factors Associated with External Cervical Resorption. *Journal of endodontics*, 43(10), 1602–1610. <https://doi.org/10.1016/j.joen.2017.05.026>.
- Mavridou, A. M., Hauben, E., Wevers, M., Schepers, E., Bergmans, L., & Lambrechts, P. (2016). Understanding External Cervical Resorption in Vital Teeth. *Journal of endodontics*, 42(12), 1737–1751. <https://doi.org/10.1016/j.joen.2016.06.007>.
- Pace, R., Giuliani, V., & Pagavino, G. (2008). Mineral trioxide aggregate in the treatment of external invasive resorption: a case report. *International endodontic journal*, 41(3), 258–266. <https://doi.org/10.1111/j.1365-2591.2007.01338.x>.
- Patel, J., & Beddis, H. P. (2019). How to assess and manage external cervical resorption. *British dental journal*, 227(8), 695–701. <https://doi.org/10.1038/s41415-019-0781-x>
- Patel, S., Kanagasigam, S., & Pitt Ford, T. (2009). External cervical resorption: a review. *Journal of endodontics*, 35(5), 616–625. <https://doi.org/10.1016/j.joen.2009.01.015>.
- Patel, S., Mavridou, A. M., Lambrechts, P., & Saberi, N. (2018b). External cervical resorption-part 1: histopathology, distribution and presentation. *International endodontic journal*, 51(11), 1205–1223. <https://doi.org/10.1111/iej.12942>.
- Pereira, A. S., Shitsuka, D. M., Parreira, F. J., & Shitsuka, R. (2018). *Metodologia pesquisa científica*. UFSM. [https://repositorio.ufsm.br/bitstream/handle/1/15824/Lic\\_Computacao\\_Metodologia-Pesquisa-Cientifica.pdf](https://repositorio.ufsm.br/bitstream/handle/1/15824/Lic_Computacao_Metodologia-Pesquisa-Cientifica.pdf)
- Rodríguez Mazón, M., Garcia-Font, M., Doria, G., Durán-Sindreu, F., & Abella, F. (2022). Influence of Cone-beam Computed Tomography in Clinical Decision-making among Different Specialists in External Cervical Resorption Lesions: A Before-After Study. *Journal of endodontics*, 48(9), 1121–1128. <https://doi.org/10.1016/j.joen.2022.05.010>.
- Rotondi, O., Waldon, P., & Kim, S. G. (2020). The Disease Process, Diagnosis and Treatment of Invasive Cervical Resorption: A Review. *Dentistry journal*, 8(3), 64. <https://doi.org/10.3390/dj8030064>
- Yilmaz, H. G., Kalender, A., & Cengiz, E. (2010). Use of mineral trioxide aggregate in the treatment of invasive cervical resorption: a case report. *Journal of endodontics*, 36(1), 160–163. <https://doi.org/10.1016/j.joen.2009.07.002>.