

Two-stage treatment of skeletal Class II malocclusion: case report

Tratamento em duas fases de má oclusão de Classe II esquelética: relato de caso

Tratamiento en dos fases de la maloclusión de Clase II esquelética: reporte de caso

Recebido: 12/07/2023 | Revisado: 19/07/2023 | Aceitado: 20/07/2023 | Publicado: 23/07/2023

Thiara Guimarães Macedo

ORCID: <https://orcid.org/0009-0007-6754-5768>

Universidade para o Desenvolvimento do Estado e da Região do Pantanal, Brazil

E-mail: tguimaraesm@gmail.com

Ricardo Alves de Souza

ORCID: <https://orcid.org/0000-0003-2113-6663>

Universidade Estadual do Sudoeste da Bahia, Brazil

E-mail: ricardoorto@gmail.com

Marcelo de Castellucci e Barbosa

ORCID: <https://orcid.org/0000-0002-7410-0077>

Universidade Federal da Bahia, Brazil

E-mail: mcastellucci@uol.com.br

Gregório Bonfim Dourado

ORCID: <https://orcid.org/0000-0002-2204-8860>

Universidade para o Desenvolvimento do Estado e da Região do Pantanal, Brazil

E-mail: drgregoriourdourado@outlook.com

Marcio Rodrigues de Almeida

ORCID: <https://orcid.org/0000-0002-2684-0943>

Universidade para o Desenvolvimento do Estado e da Região do Pantanal, Brazil

Email: marcioalmeida@icloud.com

Ana Claudia de Castro Ferreira Conti

ORCID: <https://orcid.org/0000-0001-9658-1652>

Universidade para o Desenvolvimento do Estado e da Região do Pantanal, Brazil

Email: accfconti@uol.com.br

Abstract

Objective: class II malocclusion is one of the most frequent problems in orthodontics and is characterized by maxillary prognathism, mandibular retrognathism, or both. The aim of this study is to report the case of a patient with Angle Class I and Skeletal Class II malocclusion in the growth phase treated in two phases with AEB and orthodontic mini-implant. Case report: female patient, 9 years old, reported an accentuated projection of the anterior teeth. She had the habit of interposing the lower lip, dolichofacial pattern, Angle Class I molars, and great projection of the upper incisors. In the first phase was used AEB, and in the second phase an interradicular mini screw with sliding jig to finalize Class II correction on the left side. Conclusion: it's evident the benefits of first orthopedic/functional phase in overbite correction and success of the proposed treatment through the stability after 4 years of case management.

Keywords: Orthodontics; Malocclusion; Malocclusion Angle Class II; Extraoral traction appliances.

Resumo

Objetivo: a má oclusão de Classe II é um dos problemas mais frequentes em ortodontia e se caracteriza por prognatismo maxilar, retrognatismo mandibular, ou ainda pelo envolvimento de ambos. O objetivo deste trabalho é relatar o caso de uma paciente com má oclusão Classe I de Angle e Classe II esquelética em fase de crescimento tratada em duas fases com AEB e mini-implante ortodôntico. Relato de caso: paciente do sexo feminino, 9 anos, relatou como queixa principal a projeção acentuada dos dentes anteriores. Apresentava o hábito de interposição do lábio inferior, padrão dolicofacial, molares em Classe I de Angle e grande projeção dos incisivos superiores. Na primeira fase foi utilizado AEB, e na segunda fase mini implante interradicular com sliding jig para finalizar a correção da Classe II do lado esquerdo. Conclusão: fica evidente os benefícios da primeira fase ortopédica/funcional na correção do trespassse horizontal, e o sucesso no tratamento proposto visto a estabilidade após 4 anos de controle do caso.

Palavras-chave: Ortodontia; Má oclusão; Má oclusão Classe II de Angle; Aparelhos de tração extrabucal.

Resumen

Objetivo: la maloclusión de Clase II es uno de los problemas más comunes en ortodoncia y se caracteriza por el prognatismo maxilar, retrognatismo mandibular o la combinación de ambos. El objetivo del presente es relatar el caso clínico de una paciente con maloclusión de Clase I de Angle molar y Clase II esquelética en fase de crecimiento tratada en das fases con AEB (aparato extrabucal) y miniimplante ortodôntico. Presentación del caso: paciente de sexo femenino, 9 años de edad, reportó como queja principal la protrusión acentuada de los dientes anteriores. Presentaba el

hábito de interposición del labio inferior, patrón dolicofacial, molares en Clase I de Angle y gran protrusión de los incisivos superiores. En la primera fase se utilizó el AEB y en la segunda fase se colocó un miniimplante interradicular con un dispositivo tipo sliding jig para finalizar la corrección de la Clase II en el lado izquierdo. Conclusión: se destacan los beneficios de la primera fase ortopédica/funcional en la corrección del overjet, así como el éxito del tratamiento propuesto, evidenciado por la estabilidad después de 4 años de seguimiento del caso.

Palabras clave: Ortodoncia; Maloclusión; Maloclusión Clase II de Angle; Aparatos de tracción extraoral.

1. Introduction

Angle Class II malocclusion is one of the most frequent problems in orthodontics, it has a strong genetic nature involved (George et al., 2021) and according to a systematic review carried out by De Ridder et al. (2022), its average prevalence among malocclusions is 23.8% (SD 14.6) of patients.

It can be featured by maxillary prognathism, mandibular retrognathism, or both. Usually, mandibular retrognathia is present as the most involved jaw. As this malocclusion has a skeletal component, various orthodontic and/or orthopedic appliances, fixed or removable, have been reported in the literature for its treatment (McNamara, 1981; Proffit et al., 1998; Tulloch et al., 1998).

There are basically two ways for the treatment of Class II malocclusion, which can be performed in two phases, or in just one. In the two-stage correction, the patient (who is in the pre-pubertal growth phase) first goes through the orthopedic/functional phase, and then performs the fixed orthodontic appliance correction to improve the occlusion (Tulloch et al., 1998). To decide which is the best treatment protocol, patient's age, growing stage, occlusal and aesthetic commitment, must be considered (Renata Rodrigues de Almeida-Pedrin, 2005).

The main goal of performing an orthopedic/functional phase before orthodontic treatment is to improve the maxillomandibular relationship, correcting or reducing skeletal discrepancy and improving overjet and overbite (Henriques et al., 2009). This treatment option increases the patient's self-esteem, as it benefits muscle relationships and facial harmony, important for the stability of the treatment (Almeida et al., 2011).

Literature associates reduction of the incidence of traumatism in anterior teeth due to the skeletal modifications of the orthopedic treatment and the reduction of the overjet (Garrett et al., 2013; Maltagliati et al., 2004; Tewari et al., 2020). According to a study, 16.49% of the cases of incisor injury presented overjet greater than 3 mm and 18.95% inadequate lip sealing (Tewari et al., 2020). Another study also relates inadequate lip posture and increased overjet as the main risk factors to traumatic dental injuries, common features of Class II patients (Maltagliati et al., 2004).

The aim of this study is to report the case of a patient with Angle Class I and Skeletal Class II malocclusion in the growth phase treated in two phases with AEB and orthodontic mini-implant.

2. Methodology

Bibliographical research was realized to ensure the theoretical foundation, with articles published between years 2005 to 2023 and using the keywords Orthodontics; Malocclusion; Malocclusion Angle Class II; Extraoral Traction Appliances. The methodology refers to qualitative and descriptive case report of a patient with Angle Class I malocclusion and skeletal Class II malocclusion treated in two phases with AEB and orthodontic mini-implant. In this context, the patient was treated at a private clinic in Jequié - Bahia - Brazil, and all data collected from observation/anamnesis, imaging exams and photographs were preponderant to elucidate the case, as well as to substantiate the richness of descriptions. A written informed consent was obtained from the patient's family before the treatment, her image was preserved and respected ethical issues.

3. Case report

Background

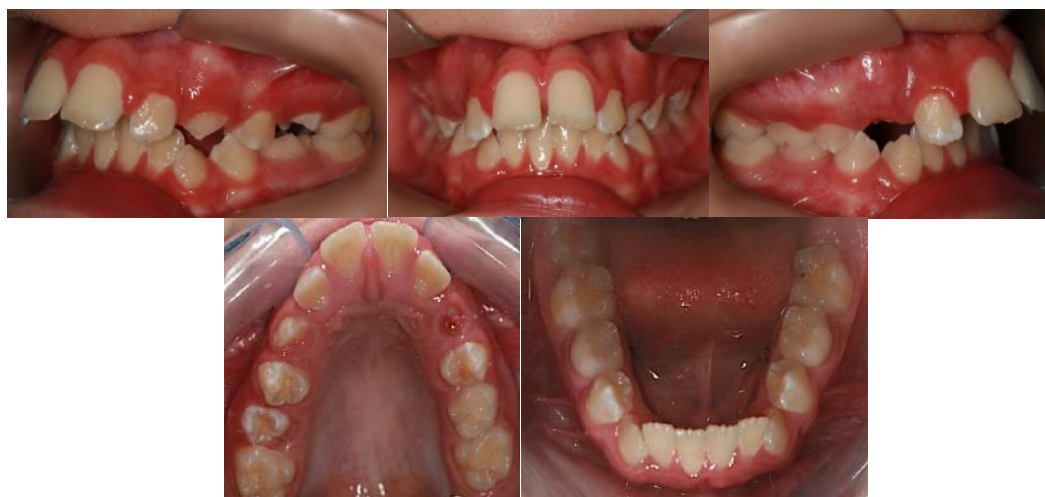Female patient, 9 years old, complained about the sharp projection of the teeth. They informed that the child had used a pacifier until he was 5 years old. After a detailed anamnesis, it was observed that the patient had the habit of interposition of the lower lip, dolichofacial pattern, molars in Angle Class I and great projection of the upper incisors (Figures 1 and 2). Cephalometric evaluation revealed a marked anterior-superior buccal inclination ($1.NA = 36.55^\circ$ and $1-NA = 10.17\text{mm}$), vertical growth tendency ($SN. GoMe = 42.12^\circ$) and ANB of 4.95° . In the carpal radiograph, it was observed that the patient was in the pre-growth spurt phase, favoring the planning of the therapy in two phases (Figure 3).

Figure 1 - Inicial face images at pre-treatment.



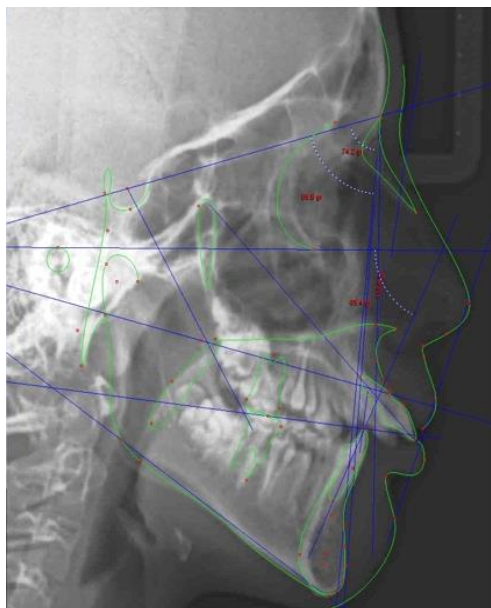
Source: Authors.

Figure 2 - Dental arches images at pre-treatment.



Source: Authors.

Figure 3 - Lateral telerradiografy with USP cephalometric tracing.



Source: Authors.

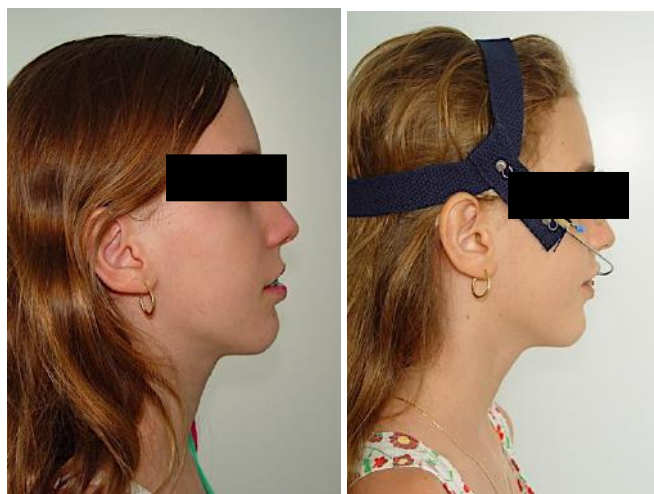Treatment options

The initial objective of the treatment was to correct the accentuated overbite to improve facial aesthetics and smile, masticatory and phonation functions. The literature provides several treatment options, such as extraoral appliance with retraction headgear, maxillary expansion, functional orthopedic appliances (Bionator), fixed orthodontic appliance with extraction of premolars, use of skeletal anchorage. In this case, we choose for a two-phase treatment with retraction headgear high traction, taking the advantage that the patient was in a pre-growth spurt phase, followed by refinement of the occlusion with a fixed orthodontic appliance.

Treatment Plan and Progress

The use of the headgear was started with high traction, facebow inserted in the triple tubes of the first permanent maxillary molars and heavy ½" intermaxillary elastic (Morelli, Sorocaba-SP, Brazil), with initial force between 375 and 450 g/f. The recommendation for using the device was from 16h to 20h a day, and the patient was very cooperative. The period of orthopedics was approximately 3 years, 2 years of active phase and 1 year of contention at night, stopping its use after the patient's menarche to take advantage of the entire growth spurt. After 1 year and 2 months of use, a significant improvement in the reduction of overjet was already observed (Figure 4).

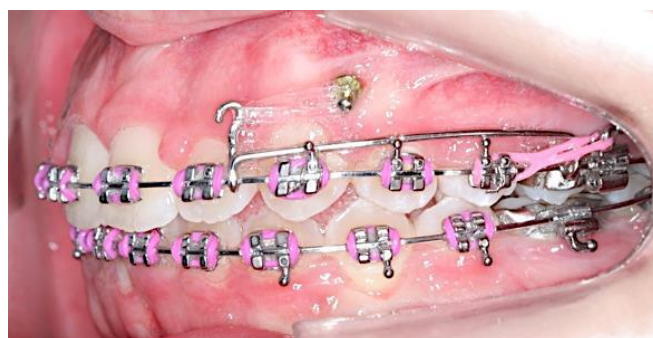Figure 4 - Orthopedic treatment phase. In the first image, during the active phase, and in the second, in the contention phase.



Source: Authors.

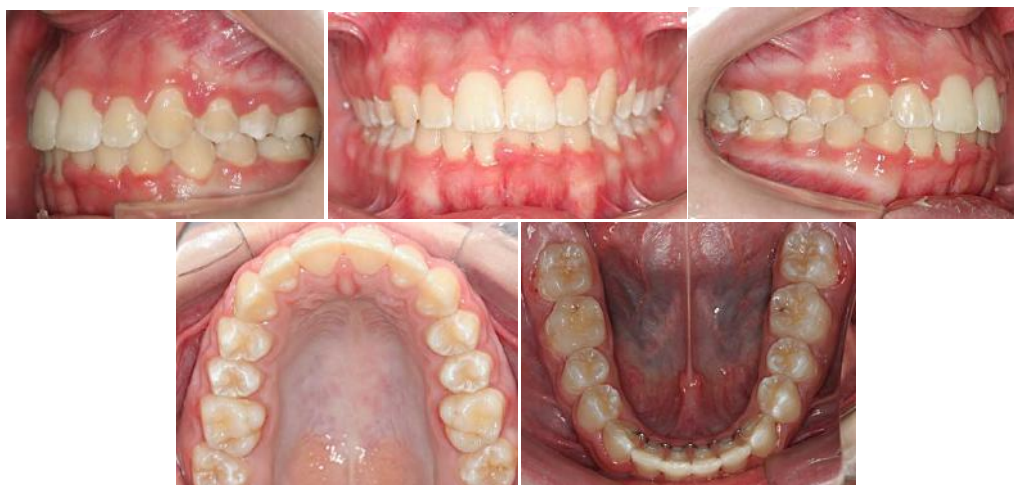The orthodontic phase began during the orthopedic phase, when braces with prescription Roth slot 0.022 (Abzil-3M, São José do Rio Preto-SP, Brazil) were bonded. After the alignment and leveling, to correct Class II on the left side, an interradicular mini orthodontic implant (Morelli 1.5mm x 8mm, Sorocaba-SP) was installed between elements 23 and 24, with a sliding jig for distalization of element 26 (Figure 5). After correction and removal of the mini-implant, Class II 3/16" medium elastic (Morelli, Sorocaba-SP) was used for refinement. The orthodontic phase was completed after 24 months, without extraction of premolars, and showed a great result, with complete correction of the overjet. The retainer protocol was a wraparound removable appliance in the upper arch, and a lingual 3x3 fixed retainer in the lower arch (Figures 6 and 7).

Figure 1 - Class II correction with mini-implant and sliding jig.



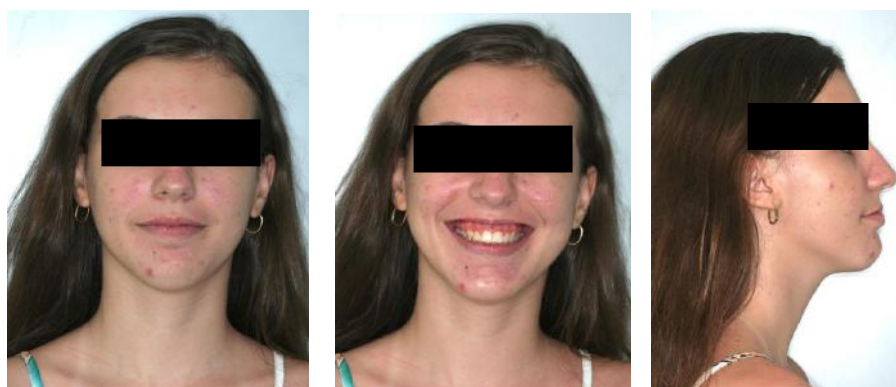Source: Authors.

Figure 2 - Dental arches images at the end of treatment.



Source: Authors.

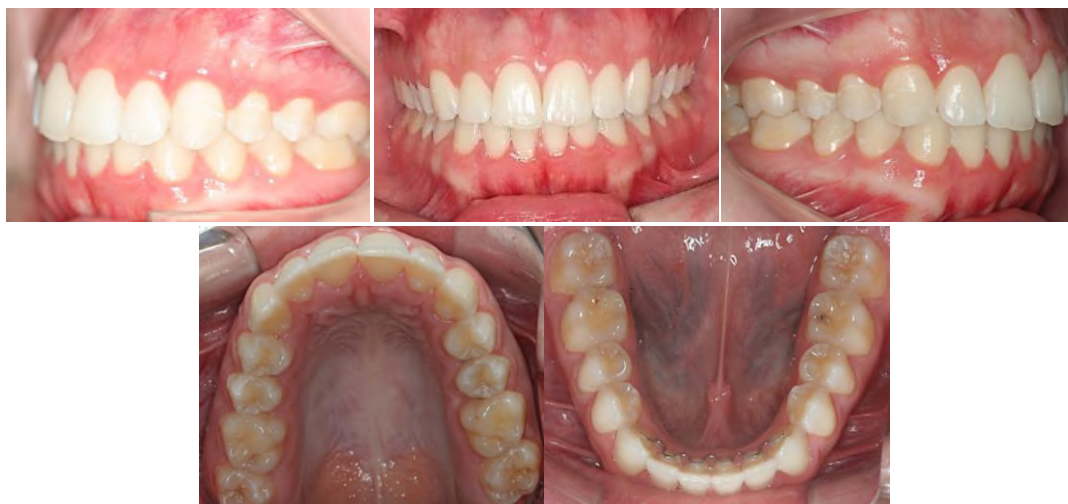Figure 7 - Final face images at the end of treatment.



Source: Authors.

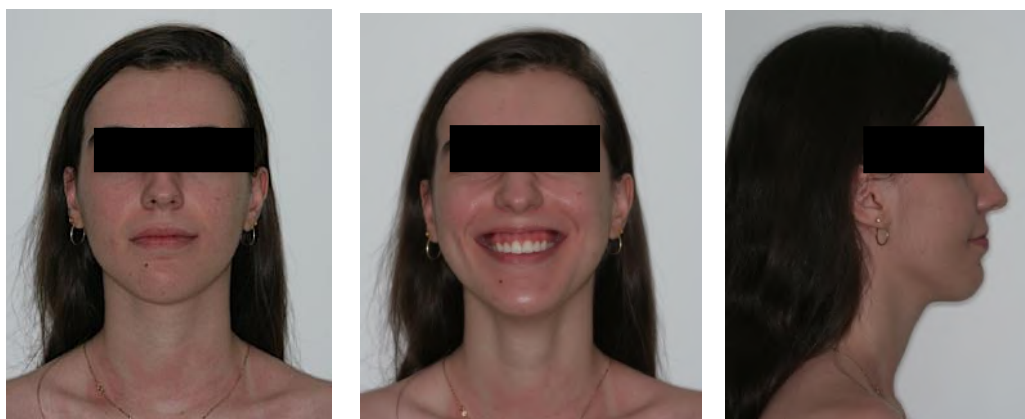In the retention phase, it is evident that the treatment carried out achieved the desired result, which is not limited only to correcting problems, but also to long-term stability. In the 4-year follow-up, good stability of the correction was achieved, and the dolichofacial pattern was maintained. It was noted that the gummy smile became more evident in adulthood, but it was not a complaint reported by the patient (Figures 8 and 9).

Figure 8 - Dental arches images after 4 years of treatment.



Source: Authors.

Figure 9 - Face images after 4 years of treatment.



Source: Authors.

4. Discussion

In this case report, it was not considered whether the two-phase treatment would speed up the treatment. The main objective was to improve the facial aesthetics compromised by the malocclusion, favoring the patient's social interactions. To evaluate the effectiveness of two-phase orthodontic treatment, some authors have investigated if changes in the first orthopedic phase make any difference at the end of treatment, since differential growth effects can be induced in early treatment. According to them, children with moderate to severe malocclusion did not get significant gains in maxillary and occlusal relationships with early treatment followed by corrective orthodontics. The severity of the initial problem and the length of treatment did not justify the two-phase treatment, and didn't influenced on the outcome (Tulloch et al., 1998).

A recent systematic review evaluated the effects of orthodontic treatment on prominent maxillary incisors in children between 7 and 11 years old treated in two phases, compared to adolescents aged between 12 and 16 years old treated in a single phase. For the authors, the only justification for treating in two phases is to reduce the risk of incisal trauma, and the results showed that there was a risk reduction of 33% and 41% in the groups treated with functional orthopedic appliances and headgear, respectively. However, the authors point out that this decision must be taken after an evaluation that considers the amount of the

overjet and the child's engagement in activities that increase the risk of trauma (Batista et al., 2018; Thiruvengkatachari et al., 2015).

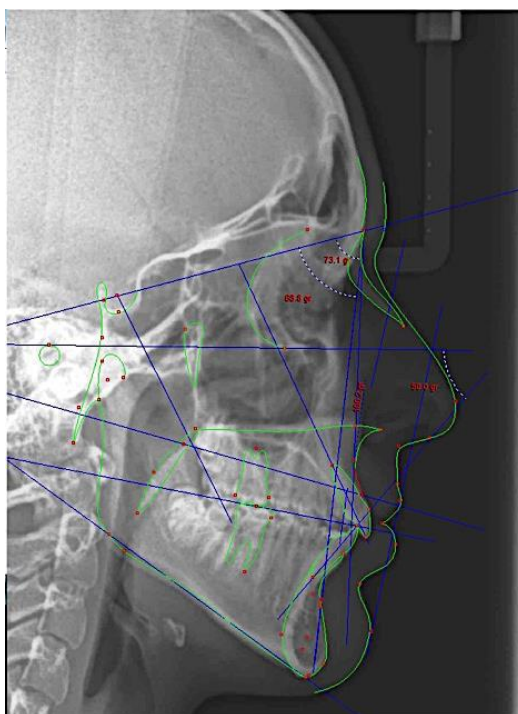
The patient's initial cephalometric analysis showed an ANB angle of 4.95° , interincisal angle of 117.58° , I.NA of 36.55° and initial I-NA of 10.17 mm, which clinically expresses itself in a marked overjet, increased buccal inclination of the upper incisors and impairment of facial pleasantness, as we can observe through the lateral telerradiograph (Figure 2). In line with the main indication for two-phase treatment (Batista et al., 2018; Thiruvengkatachari et al., 2015), the data presented above confirm the need for an early approach. At the end of the first phase of treatment, there was a significant reduction in overjet and improvement in facial aesthetics, thus reducing the risk of trauma, and solving the main complaint of the treatment, as shown in figure 7.

In updating data from a systematic review (Harrison et al., 2007), Thiruvengkatachari, Harrison (Thiruvengkatachari et al., 2015) stated that early treatment followed by a later orthodontic phase appears to significantly reduce the incidence of new incisal trauma compared to single-phase treatment in adolescence, and that there are no other advantages of the two-phase treatment. These data were also found by Batista et al. (2018); Thiruvengkatachari et al. (2015). Despite the current best scientific evidence suggesting that early treatment for Class II division I malocclusion is no longer effective in improving the final orthodontic results (Kalha, 2014; Veitz-Keenan & Liu, 2019), this does not mean that it is never indicated. For some authors, in patients with unpleasant aesthetics or with a lifestyle that exposes them to the risk of trauma, it should be considered (Brierley et al., 2017).

Clinically, is possible to observe relevant gains in aesthetic terms on patient's face, but when observing the ANB before treatment (4.95°) and after treatment (4.68°), the data did not show major skeletal changes. However, to confirm this data, Wits analysis was performed, and it showed that there was a change in the skeletal relationship of the maxilla and mandible, since the initial Wits was 4.99mm (skeletal Class II) and the final one was 1.06 mm indicating a skeletal Class I. The explanation for this may be that the ANB measurement uses a cranial plane as a reference that may be vulnerable to anatomical variations of the N point, which may lead to increased or decreased readings of the ANB angle. In addition, counterclockwise rotations of the jaws, as well as the rotation of the SN line, or even the location of the lower or upper sella, can influence the reading of the ANB angle (Jacobson, 1975).

At the end of the treatment, the skeletal relationship was Class I, and the correction was supported by dental and skeletal changes that can be confirmed by the final cephalometric data: Wits 1.06mm, I.NA 23.62° and I-NA 5.08 mm (Figure 10 / Table 1). Kallunki et al. (2021) compared early treatment of Class II malocclusion with headgear activator and used untreated individuals as a control group. Results showed that there were minor skeletal changes, indicating that treatment effects were mainly due to dentoalveolar changes. These findings agree with Dolce et al. (2007), who compared skeletal changes in single-phase and two-phase treatment of Class II malocclusion. The authors observed that the changes occurred in some variables (SNA, SNB, ANB and Mandibular Plane), and typically of small magnitude. At the end of treatment, there was no relevant skeletal difference between groups.

Figure 10 - Final teleradiograph and USP cephalometric tracing.



Source: Authors.

Table 1 - Cephalometric measurements and their changes before and after treatment according to the USP Cephalometric Analysis.

	INICIAL	FINAL	NORMA	DIF.
SNA	77.59°	78.02°	82°	- 0.43°
SNB	72.65°	73.34°	80°	- 0.69°
ANB	4.95°	4.68°	2°	0.27°
WITS	4.99mm	1.06mm	0mm	3,93mm
FMA	36.31°	35.75°	25°	0.56°
SN. GoMe	42.12°	43.59°	32°	-1.47°
Â. INTERINCISAL	117.58°	120.21°	131°	2.63°
1.NA	36.55°	23.62°	22°	12.93°
1-NA	10.17mm	5.08mm	4 mm	5.09mm
1.NB	20.92°	31.29°	25°	-10.77°
1-NB	3.69mm	7.96	4mm	- 4.27mm
IMPA	86.15°	94.56°	90°	-8.41°

Source: Authors.

To determine the association between types of malocclusions and quality of life in children, researchers used the DAI (Dental Aesthetic Index) and the Child Perception Questionnaire (CPQ8-10) in a sample of 102 children aged between 8 and 10 years. Among them, 61% (62.22 children) had some type of malocclusion. Among those with maxillary anterior irregularity ≥ 2 mm, 78.6% were bothered by the appearance of their teeth ($P = 0.003$) and 42.9% ($P = 0.047$) had difficulty to pay attention in class. Of those with lower anterior irregularity ≥ 2 mm, 18.8% felt sad ($P = 0.039$). The results support evidence that individuals are sensitive to aesthetic changes, demonstrating the importance of incorporating subjective aspects to the orthodontic diagnosis, and reveal the importance of early correction of certain types of malocclusions (Martins-Junior et al., 2012).

A recent paper evaluated the impact of dental carie, malocclusion and traumatic dental injuries (TDI) on the Quality of Life Related to Oral Health of Brazilian Children (OHRQoL). Results showed that dental caries is still the most common oral condition associated with all aspects of OHRQoL, but malocclusion primarily affects children's emotional and social well-being. These results are probably due to the DAI is an index that assesses changes in anterior teeth, which are more closely related to esthetics, which may require orthodontic treatment to improve oral health, dental and esthetic functions, and eventually improve the OHRQoL (Martins et al., 2018).

Sardenberg et al. (2013) tested the hypothesis that malocclusion and its impact on quality of life has no effect on Brazilian schoolchildren aged 8 to 10 years using the CPQ8-10 and DAI. The results refuted the initial hypothesis, demonstrating that malocclusions in the anterior segment (spacing and overjet) had 30.0% more negative impact on OHRQoL than those without malocclusion. Accordingly, a previous study with a similar age group showed that malocclusion in anterior teeth, especially crowding and overjet, was of concern for children (Dias & Gleiser, 2010).

Clinicians usually consider the age of 20 years to be an indicator of complete facial skeletal growth (Panherz et al., 2015). So, when we compare the immediate result with the control photos after 4 years of treatment (when the patient turned 20 years old), we can suggest that there was stability in the result, due to maintenance of dental alignment and overjet, and good intercuspation. The occlusal results proved to be stable in the long term, and the changes that occurred are associated with physiological aging processes and not with relapse. Relapses in the molar relationship and overjet can be explained by the combination of tooth movement and an unfavorable post-treatment maxillomandibular growth pattern, especially when combined with failure to intercuspitate the posterior teeth (Moro et al., 2020)

Another study evaluated the stability of Class II treatment with headgear followed by edgewise mechanotherapy after 5.75 years of treatment. Sample was divided into an experimental group treated as explained, and two control groups: one with untreated Class II malocclusion, and the other with normal occlusion individuals. The results showed stability in the post-treatment, however a small relapse in the overjet was observed. The authors associate relapse with normal maxillary growth, combined with a significantly lower growth rate of the mandible when compared to the control group, corroborating the findings explained above in the reported patient (Maltagliati et al., 2004)

Another study evaluated long-term cephalometric stability between two groups of patients. One group was treated non-extraction with elastic in Class II (EG, n=20), and the other also without extraction, but with AEB (HG, n=23). The results showed that the groups were similar to each other, and that the HG group had a significantly greater mandibular protrusion, a smaller occlusal plane angle and mesialization of upper molars, but the long-term stability between the groups was similar in terms of overjet maintenance, overbite and molar relation (Janson et al., 2023).

In the initial images, the patient did not present accentuated gingival exposure, despite the dolichofacial pattern. However, at the end of the treatment, the presence of gummy smile was observed, and the suspicion is that there was a clockwise rotation of the occlusal plane due to the use of headgear, even with high traction, with contribution of elastic mechanics in Class II (Figure 6 and 8). According to the literature, exposure of gingival tissue when smiling is not a negative characteristic (Kokich

et al., 1999; Kokich et al., 2006; Larissa Suzuki, 2011), but values greater than 3.0 mm of exposure can be considered unaesthetic (Machado, 2014).

5. Conclusion

In this case report, the orthopedic use of headgear followed by orthodontic treatment contributed to satisfy the family's expectations, their concern with facial aesthetics, and preventing the risk of trauma to the upper incisors. Refinement of occlusion was performed later, with the fixed appliance. Based on the benefits of the first orthopedic/functional phase in the correction of overbite, combined with the patient's collaboration, it can be stated that the proposed treatment was successful in view of the results obtained at the end, in addition to the stability after 4 years of control.

Declaration of patient consent: The authors certify that they have obtained all appropriate patient consent.

Financial support and sponsorship: Nil.

Conflicts of interest: There are no conflicts of interest.

Referências

- Almeida, M. R. d., Pereira, A. L. P., Almeida, R. R. d., Almeida-Pedrin, R. R. d., & Filho, O. G. d. S. (2011). Prevalência de má oclusão em crianças de 7 a 12 anos de idade. *Dental Press J Orthod*, *16*, 123-131.
- Batista, K. B., Thiruvengkatachari, B., Harrison, J. E., & O'Brien, K. D. (2018). Orthodontic treatment for prominent upper front teeth (Class II malocclusion) in children and adolescents. *Cochrane Database Syst Rev*, *3*(3), CD003452. <https://doi.org/10.1002/14651858.CD003452.pub4>
- Brierley, C. A., DiBiase, A., & Sandler, P. J. (2017). Early Class II treatment. *Aust Dent J*, *62 Suppl 1*, 4-10. <https://doi.org/10.1111/adj.12478>
- De Ridder, L., Aleksieva, A., Willems, G., Declerck, D., & Cadenas de Llano-Perula, M. (2022). Prevalence of Orthodontic Malocclusions in Healthy Children and Adolescents: A Systematic Review. *Int J Environ Res Public Health*, *19*(12). <https://doi.org/10.3390/ijerph19127446>
- Dias, P. F., & Gleiser, R. (2010). Orthodontic concerns of Brazilian children and their parents compared to the normative treatment need. *J Oral Sci*, *52*(1), 101-107. <https://doi.org/10.2334/josnusd.52.101>
- Dolce, C., McGorray, S. P., Brazeau, L., King, G. J., & Wheeler, T. T. (2007). Timing of Class II treatment: skeletal changes comparing 1-phase and 2-phase treatment. *Am J Orthod Dentofacial Orthop*, *132*(4), 481-489. <https://doi.org/10.1016/j.ajodo.2005.08.046>
- Garrett, P. H., Sarlani, E., Grace, E. G., & Greenspan, J. D. (2013). Chronic temporomandibular disorders are not necessarily associated with a compromised endogenous analgesic system. *J Orofac Pain*, *27*(2), 142-150. <https://doi.org/10.11607/jop.943>
- George, A. M., Felicita, A. S., Milling Tania, S. D., & Priyadharsini, J. V. (2021). Systematic review on the genetic factors associated with skeletal Class II malocclusion. *Indian J Dent Res*, *32*(3), 399-406. https://doi.org/10.4103/ijdr.IJDR_59_20
- Harrison, J. E., O'Brien, K. D., & Worthington, H. V. (2007). Orthodontic treatment for prominent upper front teeth in children. *Cochrane Database Syst Rev*(3), CD003452. <https://doi.org/10.1002/14651858.CD003452.pub2>
- Henriques, R. P., Janson, G., Henriques, J. F. C., Freitas, M. R. d., & Freitas, K. M. S. d. (2009). Efeitos do aparelho Jasper Jumper no tratamento da má oclusão de Classe II. *R Dental Press Ortodon Ortop Facial*, *14*, 82-96.
- Jacobson, A. (1975). The "Wits" appraisal of jaw disharmony. *Am J Orthod*, *67*(2), 125-138. [https://doi.org/10.1016/0002-9416\(75\)90065-2](https://doi.org/10.1016/0002-9416(75)90065-2)
- Janson, G., Niederberger, A. L. G., Janson, G., Valerio, M. V., Caldas, W., & Valarelli, F. P. (2023). Stability of Class II malocclusion treatment with Class II elastics. *Am J Orthod Dentofacial Orthop*, *163*(5), 609-617. <https://doi.org/10.1016/j.ajodo.2021.10.017>
- Kalha, A. S. (2014). Early orthodontic treatment reduced incisal trauma in children with class II malocclusions. *Evid Based Dent*, *15*(1), 18-20. <https://doi.org/10.1038/sj.ebd.6400986>
- Kallunki, J., Bondemark, L., & Paulsson, L. (2021). Early headgear activator treatment of Class II malocclusion with excessive overjet: a randomized controlled trial. *Eur J Orthod*, *43*(6), 639-647. <https://doi.org/10.1093/ejo/cjaa073>
- Kokich, V. O., Jr., Kiyak, H. A., & Shapiro, P. A. (1999). Comparing the perception of dentists and lay people to altered dental esthetics. *J Esthet Dent*, *11*(6), 311-324. <https://doi.org/10.1111/j.1708-8240.1999.tb00414.x>
- Kokich, V. O., Kokich, V. G., & Kiyak, H. A. (2006). Perceptions of dental professionals and laypersons to altered dental esthetics: asymmetric and symmetric situations. *Am J Orthod Dentofacial Orthop*, *130*(2), 141-151. <https://doi.org/10.1016/j.ajodo.2006.04.017>
- Larissa Suzuki, A. W. M., Marcos Alan Vieira Bittencourt. (2011). An evaluation of the influence of gingival display level in the smile esthetics. *Dental Press J Orthod*, *16*(37), 1-10.

- Machado, A. W. (2014). 10 commandments of smile esthetics. *Dental Press J Orthod*, 19, 136-157.
- Maltagliati, L. A., Henriques, J. F., Janson, G., Almeida, R. R., & Freitas, M. R. (2004). Influence of orthopedic treatment on hard and soft facial structures of individuals presenting with Class II, Division 1 malocclusion: a comparative study. *J Appl Oral Sci*, 12(2), 164-170. <https://doi.org/10.1590/s1678-77572004000200016>
- Martins, M. T., Sardenberg, F., Bendo, C. B., Vale, M. P., Paiva, S. M., & Pordeus, I. A. (2018). Dental caries are more likely to impact on children's quality of life than malocclusion or traumatic dental injuries. *Eur J Paediatr Dent*, 19(3), 194-198. <https://doi.org/10.23804/ejpd.2018.19.03.5>
- Martins-Junior, P. A., Marques, L. S., & Ramos-Jorge, M. L. (2012). Malocclusion: social, functional and emotional influence on children. *J Clin Pediatr Dent*, 37(1), 103-108. <https://doi.org/10.17796/jcpd.37.1.y75430328427210j>
- McNamara, J. A., Jr. (1981). Components of class II malocclusion in children 8-10 years of age. *Angle Orthod*, 51(3), 177-202. [https://doi.org/10.1043/0003-3219\(1981\)051<0177:COCIMI>2.0.CO;2](https://doi.org/10.1043/0003-3219(1981)051<0177:COCIMI>2.0.CO;2)
- Moro, A., Mattos, C. F. P., Borges, S. W., Flores-Mir, C., & Topolski, F. (2020). Stability of Class II corrections with removable and fixed functional appliances: A literature review. *J World Fed Orthod*, 9(2), 56-67. <https://doi.org/10.1016/j.ejwf.2020.04.003>
- Pancherz, H., Bjerklin, K., & Hashemi, K. (2015). Late adult skeletofacial growth after adolescent Herbst therapy: a 32-year longitudinal follow-up study. *Am J Orthod Dentofacial Orthop*, 147(1), 19-28. <https://doi.org/10.1016/j.ajodo.2014.06.011>
- Proffit, W. R., Fields, H. W., Jr., & Moray, L. J. (1998). Prevalence of malocclusion and orthodontic treatment need in the United States: estimates from the NHANES III survey. *Int J Adult Orthodon Orthognath Surg*, 13(2), 97-106. <https://www.ncbi.nlm.nih.gov/pubmed/9743642>
- Renata Rodrigues de Almeida-Pedrin, A. P., Renato Rodrigues de Almeida, Marcio Rodrigues de Almeida, José Fernando Castanha Henriques. (2005). Efeitos do AEB conjugado e do Bionator no tratamento da Classe II, 1a divisão*. *Dental Press Ortodon Ortop Facial*, 10, 37-54.
- Sardenberg, F., Martins, M. T., Bendo, C. B., Pordeus, I. A., Paiva, S. M., Auad, S. M., & Vale, M. P. (2013). Malocclusion and oral health-related quality of life in Brazilian school children. *Angle Orthod*, 83(1), 83-89. <https://doi.org/10.2319/010912-20.1>
- Tewari, N., Mathur, V. P., Siddiqui, I., Morankar, R., Verma, A. R., & Pandey, R. M. (2020). Prevalence of traumatic dental injuries in India: A systematic review and meta-analysis. *Indian J Dent Res*, 31(4), 601-614. https://doi.org/10.4103/ijdr.IJDR_953_19
- Thiruvengkatachari, B., Harrison, J., Worthington, H., & O'Brien, K. (2015). Early orthodontic treatment for Class II malocclusion reduces the chance of incisal trauma: Results of a Cochrane systematic review. *Am J Orthod Dentofacial Orthop*, 148(1), 47-59. <https://doi.org/10.1016/j.ajodo.2015.01.030>
- Tulloch, J. F., Phillips, C., & Proffit, W. R. (1998). Benefit of early Class II treatment: progress report of a two-phase randomized clinical trial. *Am J Orthod Dentofacial Orthop*, 113(1), 62-72, quiz 73-64. [https://doi.org/10.1016/S0889-5406\(98\)70277-X](https://doi.org/10.1016/S0889-5406(98)70277-X)
- Veitz-Keenan, A., & Liu, N. (2019). One phase or two phase orthodontic treatment for Class II division 1 malocclusion ? *Evid Based Dent*, 20(3), 72-73. <https://doi.org/10.1038/s41432-019-0049-y>