

## **High-resolution CBCT assessing a maxillary central incisor with root bifurcation: A case report**

**TCFC de alta resolução utilizada na avaliação de um incisivo central superior com bifurcação radicular: Relato de caso**

**CBCT de alta resolución evaluando un incisivo central superior con bifurcación radicular: Reporte de un caso**

Received: 07/31/2023 | Revised: 08/15/2023 | Accepted: 08/17/2023 | Published: 08/21/2023

**Ana Luiza Esteves Carneiro**

ORCID: <https://orcid.org/0000-0002-3799-5043>

University of São Paulo, Brazil

E-mail: [ana.esteves.carneiro@usp.br](mailto:ana.esteves.carneiro@usp.br)

**Rubens Spin-Neto**

ORCID: <https://orcid.org/0000-0002-9562-0610>

Aarhus University, Denmark

E-mail: [rsn@dent.au.dk](mailto:rsn@dent.au.dk)

**Daniela Miranda Richarte de Andrade Salgado**

ORCID: <https://orcid.org/0000-0003-4646-7389>

University of São Paulo, Brazil

E-mail: [daniricharte@usp.br](mailto:daniricharte@usp.br)

**Núbia Rafaelle Oliveira de Meneses**

ORCID: <https://orcid.org/0000-0002-0933-650X>

University of São Paulo, Brazil

E-mail: [nu\\_meneses@usp.br](mailto:nu_meneses@usp.br)

**Edna Alejandra Gallardo López**

ORCID: <https://orcid.org/0000-0002-3312-1939>

University of São Paulo, Brazil

E-mail: [e.gallardo@usp.br](mailto:e.gallardo@usp.br)

**Alice Souza Villar Cassimiro Fonseca**

ORCID: <https://orcid.org/0000-0001-5119-3760>

University of São Paulo, Brazil

E-mail: [alicesvcf@usp.br](mailto:alicesvcf@usp.br)

**Claudio Costa**

ORCID: <https://orcid.org/0000-0003-2831-8670>

University of São Paulo, Brazil

E-mail: [clacosta@usp.br](mailto:clacosta@usp.br)

### **Abstract**

Cone beam computed tomography (CBCT) is an imaging modality widely used in endodontics, since it provides three-dimensional images without superposition of structures. The maxillary central incisor usually presents a single root and one root canal, but anatomical variations can happen. The aim of the present paper is to report a high-resolution CBCT evaluation of an upper central incisor with root bifurcation. This paper shows a descriptive and qualitative assessment of high-resolution CBCT images for endodontic purposes. A 39-year-old male patient was referred to a radiologic clinic to acquire CBCT images of the right upper central incisor, as the referring clinician noticed an anatomical difference between the two upper central incisors on a panoramic radiograph and suspected of dens invaginatus. CBCT images were acquired in high resolution (voxel size of 0.08 mm) and a restricted field-of-view (4x4 cm). CBCT volume displayed an anatomical variation of the central incisor, which presented root bifurcation and two root canals, with a normal clinical crown. The present case report shows a rare diagnosis of a maxillary central incisor presenting bifurcated root with two root canals, and to the best of the authors' knowledge, this is the first case report to present high-resolution CBCT images with disclosed acquisition protocols to diagnose a bifurcated central incisor. The documentation of unusual cases has great didactic value and contributes to information propagation. In the present case, high-resolution CBCT allowed a detailed evaluation of both roots and root canals, facilitating the clinician's diagnostic task.

**Keywords:** Cone-Beam Computed Tomography; Anatomic Variation; Endodontics.

## Resumo

A tomografia computadorizada de feixe cônico (TCFC) é uma modalidade de imagem amplamente utilizada em endodontia, pois fornece imagens tridimensionais sem sobreposição de estruturas. O incisivo central superior geralmente apresenta uma única raiz e um canal radicular, mas variações anatômicas podem ocorrer. O objetivo deste trabalho é relatar a avaliação de um incisivo central superior com bifurcação radicular por meio de TCFC de alta resolução. Este artigo apresenta uma avaliação descritiva e qualitativa de imagens de TCFC de alta resolução para fins endodônticos. Um paciente do sexo masculino de 39 anos foi encaminhado a uma clínica radiológica para adquirir imagens de TCFC do incisivo central superior direito, pois o dentista solicitante notou uma diferença anatômica entre os dois incisivos centrais superiores em uma radiografia panorâmica e suspeitou de dens invaginatus. As imagens TCFC foram adquiridas em alta resolução (voxel de 0,08 mm) e um campo de visão restrito (4x4 cm). O volume da TCFC apresentou uma variação anatômica do incisivo central, que apresentava bifurcação radicular e dois canais radiculares, com coroa clínica normal. O presente relato de caso mostra um diagnóstico raro de um incisivo central superior apresentando uma raiz bifurcada com dois canais radiculares e, até onde sabemos, este é o primeiro relato de caso a apresentar imagens de TCFC de alta resolução, com protocolos de aquisição divulgados, para diagnosticar um incisivo central bifurcado. A documentação de casos inusitados tem grande valor didático e contribui para a propagação da informação. No presente caso, a TCFC de alta resolução permitiu uma avaliação detalhada das raízes e dos canais radiculares, facilitando o diagnóstico.

**Palavras-chave:** Tomografia Computadorizada de Feixe Cônico; Variação Anatômica; Endodontia.

## Resumen

La tomografía computarizada de haz cónico (CBCT, por sus siglas en inglés) es una modalidad de imagen ampliamente utilizada en endodoncia, ya que proporciona imágenes tridimensionales sin superposición de estructuras. El incisivo central superior suele presentar una sola raíz y un conducto radicular, sin embargo, pueden ocurrir variaciones anatómicas. El objetivo del presente trabajo es reportar la evaluación CBCT de alta resolución de un incisivo central superior con bifurcación radicular. Este artículo muestra una evaluación descriptiva y cualitativa de imágenes CBCT de alta resolución con fines endodónticos. Un paciente de 39 años, de sexo masculino, fue referido a una clínica radiológica para adquirir imágenes CBCT del incisivo central superior derecho, ya que el odontólogo remitente notó una diferencia anatómica entre los dos incisivos centrales superiores en una radiografía panorámica y sospechaba de dens invaginatus. Las imágenes CBCT fueron adquiridas en alta resolución (tamaño de vóxel de 0,08 mm) y con un campo de visión reducido (4x4 cm). El volumen CBCT mostró una variación anatómica del incisivo central, que presentó bifurcación y dos conductos radiculares, con una corona clínica normal. El presente reporte de caso muestra un diagnóstico poco frecuente de un incisivo central superior que presenta una raíz bifurcada con dos conductos radiculares y, según el conocimiento de los autores, es el primero que presenta imágenes CBCT de alta resolución con protocolos de adquisición divulgados para diagnosticar un incisivo central bifurcado. La documentación de casos inusuales tiene un gran valor didáctico y contribuye a la difusión de la información. En el presente caso, la CBCT de alta resolución permitió una evaluación detallada tanto de las raíces como de los conductos radiculares, facilitando la tarea del diagnóstico clínico.

**Palabras clave:** Tomografía Computarizada de Haz Cónico; Variación Anatômica; Endodoncia.

## 1. Introduction

Periapical radiographs are widely used for diagnosis and planning of root canal treatment, since they provide detailed information regarding root anatomy, periapical status, pulp chamber anatomy and probable number of root canals. However, being a two-dimensional imaging modality, periapical radiographs are often unable to properly illustrate the complex morphology and peculiarities of the root and root canal system (Caputo et al., 2016).

Cone-Beam Computed Tomography (CBCT) is a relatively novel imaging modality that is being widely used to determine root canal anatomy in vivo, providing three-dimensional images without superposition of structures, at a reasonable radiation dose (Durack & Patel, 2012). CBCT images enable the assessment of a tooth in three different planes (axial, sagittal and coronal), currently being used in various endodontic applications such as analysis of root's internal and external morphology, assessment of root canal preparation, obturation, retreatment, coronary infiltration and tooth invagination (Mabrouk et al., 2021; Setzer & Lee, 2021), overcoming the limitations of conventional radiography.

The maxillary central incisor usually presents a single root and a single root canal, with occasional lateral canals and apical ramifications (Cabo-Valle, 2001). In other words, it is a tooth with a relatively simple anatomy. Altman (Altman, 1970) and Vertucci (Vertucci, 1984) state that maxillary central incisors have one root and one canal in 100% of cases. A maxillary

central incisor with more than one root is a rare phenomenon (Heling, 1977). The literature reports a few cases of periapical radiographs diagnosing double-rooted maxillary central incisors (Cabo-Valle, 2001; Heling, 1977; Henry, 1970; Mader, 1980; Patterson, 1970; Rao Genovese, 2003) and only once case using CBCT images as the diagnostic tool (Levin, 2015). However, quite often some development alterations can interfere with the central incisor's anatomy. Dens invaginatus (DI), also known as dens in dente, is a development anomaly that happens from the infolding of the outer surface of the tooth towards the pulp, prior to dental tissues calcification, resulting in an invagination into the tooth (González-Mancilla et al., 2022; Kalogeropoulos et al., 2023). The invagination may be limited to the pulp chamber, or it might extend to the root, where communication between the root canal and the invagination could be present (Mabrouk et al., 2021).

In the present case report, a detailed tomographic evaluation revealed a maxillary central incisor presenting a bifurcated root and two root canals, with a normal clinical crown, while ruling out the presence of developmental anomalies.

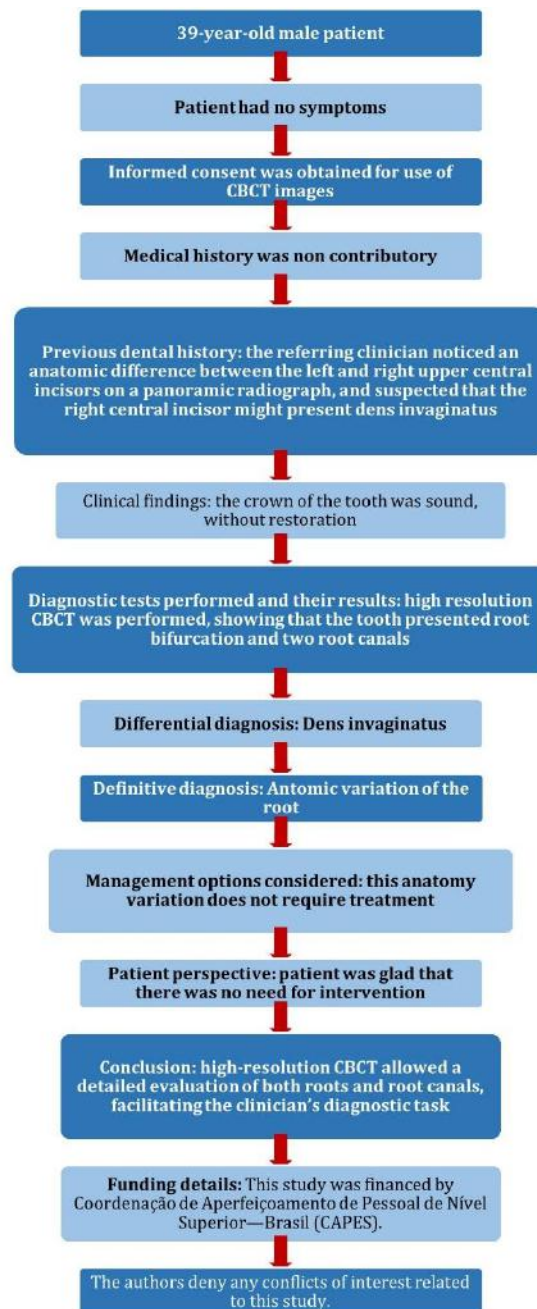
## **2. Methodology**

The present paper is a case study of qualitative nature (Pereira et al., 2018) that aims to provide detailed information regarding high-resolution Cone Beam Computed Tomography (CBCT) assessment of an upper right central incisor with root bifurcation. This is a retrospective assessment of CBCT images and patient information recorded on University of São Paulo's database, approved by the local Research Ethics Committee under the number 3.239.265. The patients provided informed consent for the use of their anonymized CBCT images.

## **3. Case Report**

This case report has been written according to Preferred Reporting Items for Case reports in Endodontics (PRICE) 2020 guidelines (Nagendrababu et al., 2020) (Figure 1).

**Figure 1** – PRICE 2020 flowchart.

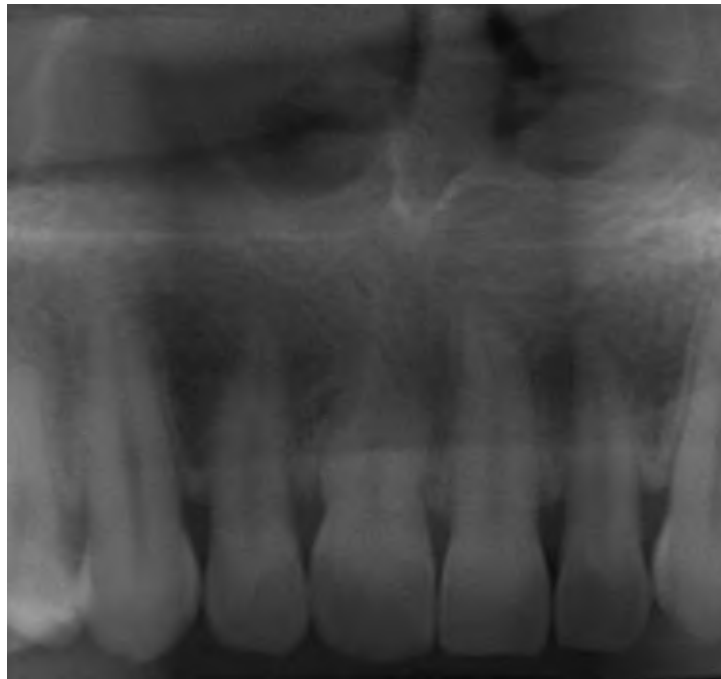


Source: Authors.

The flowchart summarizes the main clinical and radiographic aspects of this case report.

A 39-year-old male patient was referred to a radiology clinic to perform CBCT acquisition of the upper right central incisor. The referring clinician noticed an anatomic difference between the left and right upper central incisors on a panoramic radiograph and suspected that the right central incisor might present a developmental anomaly such as dens invaginatus, so they requested a CBCT scan to further assess it (Figure 2). The patient reported no symptomatology. Due to general data protection regulation, the initial panoramic radiograph was not available for comparison.

**Figure 2** – Panoramic reconstruction of CBCT images at 45-mm thickness, mimicking a panoramic radiograph.



Source: Authors.

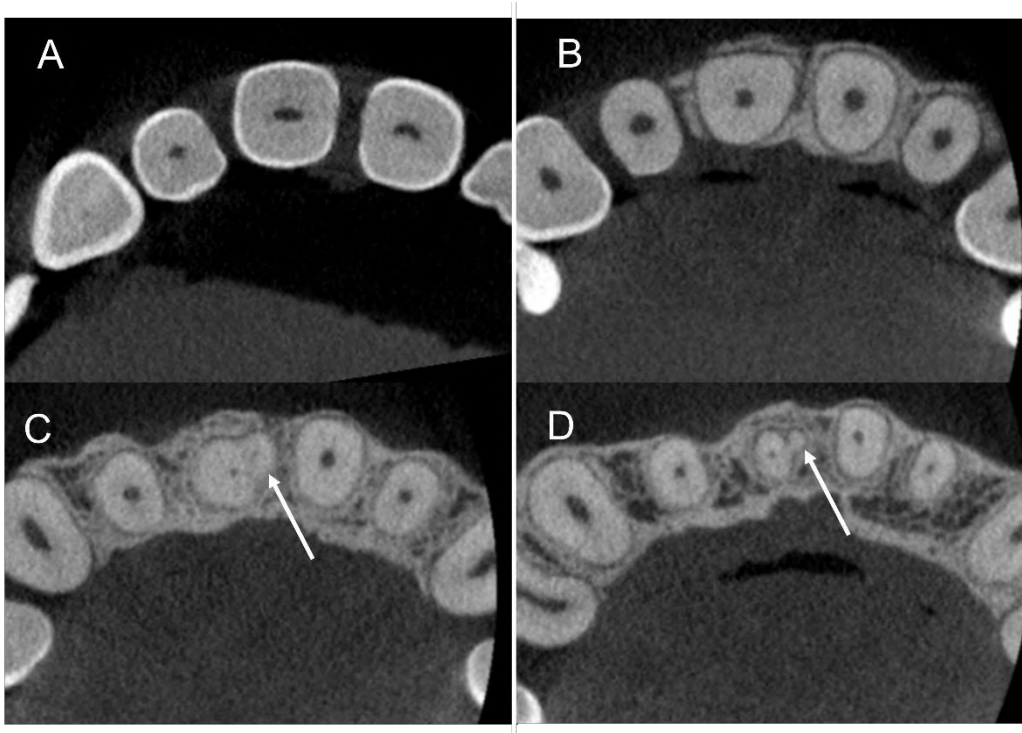
The panoramic reconstruction shows anatomic variations in the root of the upper right central incisor, when compared to the upper left central incisor.

For image acquisition the high-resolution protocol was performed on Veraview R100 (J. Morita Corporation, Osaka, Japan), with the following acquisition protocol: 99kV (kilovoltage), 8mA (Milliampere), 9.4 seconds, FOV (Field of View) 4x4mm and voxel size 0.0800 mm. The images were exported in DICOM format and evaluated on OnDemand3D planning software (CyberMed, Seoul, Korea).

The CBCT images were thoroughly evaluated by an experienced oral and dentomaxillofacial radiologist, that assessed the region of interest on three main planes: sagittal, coronal and axial. The radiologist also repositioned the tomographic images in different reformations in order to observe the entire upper right central incisor in longitudinal planes, being able to perform buccal-lingual and mesial-distal assessments on coronal and sagittal planes, considering the long axis of the tooth. After detailed evaluation of the tomographic volume, the radiologist diagnosed the presence of an anatomical variation: the upper right central incisor presented one crown, a bifurcated root and two root canals.

The crown of the upper right central incisor presented no anatomic variations, no filling materials and no cavities. The coronal third of the root presented a more oval shape compared to the left central incisor, with one single root canal. The root started to bifurcate on the apical portion of the middle third, where a small accessory root was seen on the mesio-buccal aspect of the main root, presenting its separate root canal. On the apical third of the tooth the two roots were separated, each one presenting one root canal that ended on its own apical foramen (Figure 3). The main root had a length of 12.81mm, while the bifurcated root had a length of 5.37 mm.

**Figure 3** – CBCT axial images showing the crown (A), coronal third (B), middle third (C) and apical third (D) of the upper right central incisor. The white arrows indicate the accessory root.

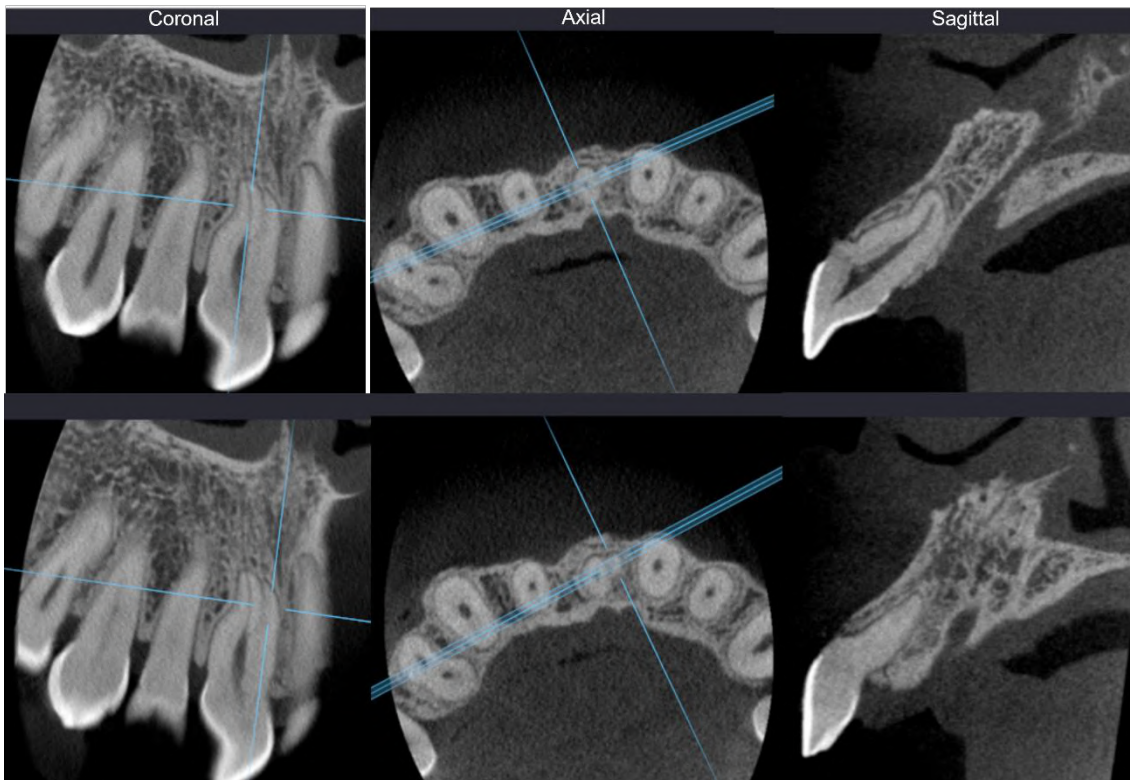


Source: Authors.

On the apical portion of the incisor root a small accessory root can be observed, presenting a separate root canal.

In order to properly illustrate this anatomic variation to the endodontist, the CBCT volume had to be angled in a way that captured the long axis of the tooth, both roots and both root canals, enabling the visualization of where the accessory root began as well as the entire course of the two roots. Figure 4 shows how the CBCT volume was repositioned to better illustrate each root, and Figure 5 shows the three-dimensional reconstruction the upper right central incisor.

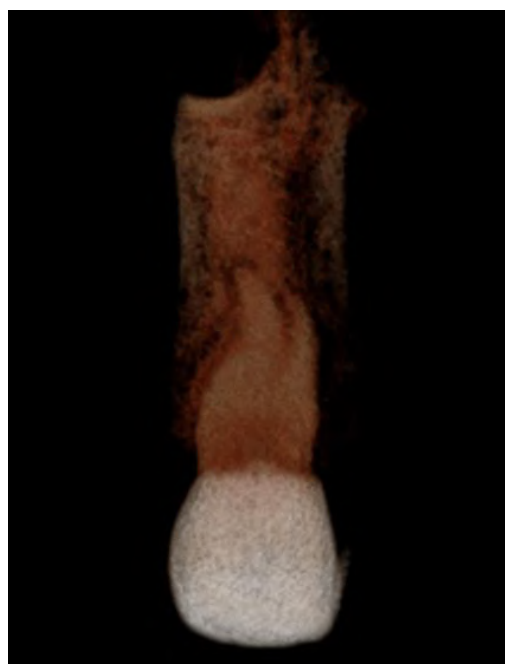
**Figure 4** – CBCT Coronal, Axial and Sagittal images repositioned to show the long axis of the main root (top row) and the accessory root (bottom row) of the upper right central incisor.



Source: Authors.

When the CBCT slices are positioned according to the long axis of the tooth they are able to properly illustrate the anatomy of each root in the three dimensions: height, width and depth.

**Figure 5** – CBCT three-dimensional reconstruction of the upper right central incisor.



Source: Authors.

This reconstruction is able to clearly illustrate how the accessory root is positioned on the mesio-buccal aspect of the main root.

#### 4. Discussion

Although much is known about the usual dental anatomy, anatomical variations may occur in any group of teeth, depending on the person. The maxillary central incisor in deciduous and permanent dentition most often presents a single root and one root canal (Cabo-Valle, 2001; Calvert 2014; Castro-Nunez, 2020; Garlapati et al., 2014; Kumar Gupta et al., 2015; Lambruschini & Camps, 1993; Levin, 2015; Lin et al., 2006; Nunes, 2020; Rao Genovese F, 2003). However, in rare situations, this group of teeth can contain more than one root or root canal, or even reveal themselves with a series of anomalous anatomies, such as: fusion, twinning, macrodontia and dens invaginatus. Such changes can occur simultaneously or separately and may involve a single tooth in the arch or even affect the contralateral tooth (Cabo-Valle, 2001; Calvert, 2014; Garlapati et al., 2014; Heling, 1977; Henry, 1970; Hosomi et al., 1989; Kumar Gupta et al., 2015; Lambruschini & Camps, 1993; Levin, 2015; Lin et al., 2006; Mader, 1980; Patterson, 1970; Rao Genovese, 2003; Sponchiado et al., 2006; Vinothkumar et al., 2017). According to Garlapati et al. (Garlapati et al., 2014) the development of accessory root canals emerging through the root surface may be caused by a failed fusion of the Hertwig's epithelial root sheath with the cemento-enamel junction during root formation, due to traumatic or idiopathic injuries.

There are some case reports of permanent maxillary central incisors that showed morphological variations exclusively in their root, most of them documented by periapical radiographs. Heling (Heling, 1977) reported an upper left central incisor with a supernumerary tiny root turned mesial and smaller than the main root, bifurcating from the cervical root portion. Patterson (Patterson, 1970) and Mader (Mader, 1980) reported the presence of two roots in both upper central incisors, without specifying their length and position. Other authors (Lin et al., 2006) in 2006, observed a supernumerary root in the palatal aspect of an upper left central incisor, presenting the same length of the main root. In 2017, Jajoo (S Jajoo, 2017) reported a primary upper central incisors presenting two roots of the same length.

Angled periapical radiographs can be used to assess this anatomical variation. Genovese and Marsico (Rao Genovese F, 2003) reported the presence of two roots (buccal and palatine) and two root canals in an upper right central incisor, while the literature also shows reports of central incisors presenting two root canals in a single root (Calvert, 2014; Lambruschini & Camps, 1993). However, assessing these teeth only by periapical radiographs could possibly lead to iatrogenic injuries, since the information they provide is limited by the superimposition of structures (Garlapati et al., 2014; Heling, 1977; Henry, 1970; Lambruschini & Camps, 1993; Lin et al., 2006; Mader, 1980; Patterson, 1970; Rao Genovese, 2003).

Failures in endodontic therapy are potentiated by the lack of clinical suspicion of possible changes in root anatomy. Some authors report the need for endodontic re-approach in central incisors that had previously undiagnosed morphological variations in their roots. Patients had persistent painful symptoms, caused by the absence of filling of a supernumerary root canal (Calvert, 2014; 2014; Lambruschini & Camps, 1993; Rao Genovese, 2003). In 2014, Garlapati et al. (Garlapati et al., 2014) altered the horizontal angle of a periapical radiograph to diagnose the presence of a supernumerary palatal root without endodontic filling in the upper left central incisor.

The American Association of Endodontists and the American Academy of Oral and Maxillofacial Radiology suggest the use of CBCT to identify potential accessory canals in teeth when a bidimensional image doesn't offer enough information (Endodontists & Radiology, 2011). The risk that radiation poses to the patient has been a constant concern in the scope of dental radiology, due to the frequent use of intraoral and extraoral radiographs (Bornstein, Scarfe, Vaughn, & Jacobs, 2014). The ALARA principle ("as low as reasonably achievable") indicated that the patient should be exposed to the lowest possible dose of radiation, and has now been replaced by ALADA ("as low as diagnostically acceptable") which considers that upon the



indication of the scan, the appropriate FOV, mAs, and kVp settings, such as high definition/high resolution parameters should be selected to obtain a diagnostically acceptable and interpretable image (Jaju & Jaju, 2015). Considering this case report, since the clinician's hypothesis was a developmental anomaly in a tooth that did not present symptomatology, a high-resolution CBCT protocol shouldn't have been the first choice, following the ALADA principle. A standard-resolution protocol would likely be able to diagnose this anatomical variation at a lower radiation burden to the patient. High-resolution protocols offer a more detailed and clear tomographic image, but it is critical for health care providers to weigh the potential benefit of diagnostic information against the radiation burden of the imaging procedure (Ludlow, Davies-Ludlow, Brooks, & Howerton, 2006). Moreover, oral and maxillofacial radiologists have the responsibility to communicate the radiation dose and the associated risks of CBCT acquisitions to their referring practitioners, spreading awareness about the difference between "diagnostically acceptable" and "beautiful" images (Jaju & Jaju, 2015).

Few recent studies have employed CBCT as the imaging modality of choice for diagnosis and treatment planning of upper central incisors. In the case reported by Sponchiado et al. (Sponchiado et al., 2006), an upper right central incisor presented two roots of similar size, being equidistant from each other (mesial and distal). Levin et al. (Levin, 2015) found the existence of a supernumerary root in the upper left central incisor, of shorter length and width compared to the main root, originating from the middle third and mesial aspect of the main root. Gupta et al. (Kumar Gupta et al., 2015) also observed the presence of a shorter supernumerary root in the upper left central incisor, located in the distal aspect of the tooth, bifurcating from the cervical third. Vinothkumar et al. (Vinothkumar et al., 2017) reported the fusion of the upper right central incisor with a supernumerary tooth, presenting a C-shaped root canal.

Only two studies reported information regarding CBCT acquisition. Levin et al. (Levin A, 2015) used CBCT unit Carestream 9300 (Kodak®) but didn't report the selected FOV. Vinothkumar et al. (Vinothkumar et al., 2017) used CBCT unit Promax 3D (Planmeca®) with 0.2 mm voxel, 68x42mm FOV, acquisition time of 10.8s, 54 to 90kV and 1 to 14 mA. The present case report shows a rare diagnosis of a maxillary central incisor presenting a bifurcated root with two root canals, and to the best of the authors' knowledge, this is the first case report to present high-resolution CBCT images with disclosed acquisition protocols to diagnose a bifurcated central incisor. The limitations of this case report are the absence of clinical photographs and panoramic radiograph. The documentation of unusual cases has great didact value and contributes to information propagation, favoring the acknowledgment of similar cases that may require endodontic intervention.

## 5. Final Considerations

Upper central incisors can present more than one root and more than one root canal, therefore extensive knowledge of dental anatomy is essential for proper endodontic treatment of this group of teeth. The appropriate use of diagnostic aids like CBCT with limited FOV and low effective dose has enabled a detailed assessment of root anatomy before endodontic intervention, facilitating successful endodontic treatment in difficult cases. Future studies with long-term monitoring of endodontic interventions in teeth with root bifurcation could bring further knowledge regarding this anatomic variation.

## References

- Altman M. G. J., Seidberg B. H., Langeland K. (1970). Apical root canal anatomy of human maxillary central incisors. *Oral surgery, oral medicine, and oral pathology*, 30(5).
- Bornstein, M. M., Scarfe, W. C., Vaughn, V. M., & Jacobs, R. (2014). Cone beam computed tomography in implant dentistry: a systematic review focusing on guidelines, indications, and radiation dose risks. *International journal of oral & maxillofacial implants*, 29.
- Cabo-Valle M, G.-G. J. (2001). Maxillary central incisor with two root canals: an unusual presentation. *Journal of oral rehabilitation*, 28(8).
- Calvert, G. (2014). Maxillary central incisor with type V canal morphology: case report and literature review. *Journal of endodontics*, 40(10).

- Caputo, B. V., Noro Filho, G. A., de Andrade Salgado, D. M., Moura-Netto, C., Giovani, E. M., & Costa, C. (2016). Evaluation of the Root Canal Morphology of Molars by Using Cone-beam Computed Tomography in a Brazilian Population: Part I. *J Endod*, 42(11), 1604-1607.
- Castro-Nunez, G. M. (2020). Tratamento endodôntico de canino superior birradicular: relato de caso. In M. C. Kuga (Ed.), *Escalante-Otárola, Wilfredo Gustavo* (Vol. 10, pp. 74-77). *Dent. press endod.*
- Durack, C., & Patel, S. (2012). Cone beam computed tomography in endodontics. *Braz Dent J*, 23(3), 179-191.
- Endodontists, A. A. o., & Radiology, A. A. o. O. a. M. (2011). Use of cone-beam computed tomography in endodontics Joint Position Statement of the American Association of Endodontists and the American Academy of Oral and Maxillofacial Radiology. *Oral Surg Oral Med Oral Pathol Oral Radiol Endod*, 111(2), 234-237.
- Garlapati, R., Venigalla, B. S., Chintamani, R., & Thumu, J. (2014). Re - treatment of a Two-rooted Maxillary Central Incisor - A Case Report. *J Clin Diagn Res*, 8(2), 253-255.
- González-Mancilla, S., Montero-Miralles, P., Saúco-Márquez, J. J., Areal-Quecuty, V., Cabanillas-Balsera, D., & Segura-Egea, J. J. (2022). Prevalence of Dens Invaginatus assessed by CBCT: Systematic Review and Meta-Analysis. *J Clin Exp Dent*, 14(11), e959-e966.
- Heling, B. (1977). A two-rooted maxillary central incisor. *Oral surgery, oral medicine, and oral pathology*, 43(4).
- Henry, P. (1970). Two-rooted central incisor. *Oral surgery, oral medicine, and oral pathology*, 30(3).
- Hosomi, T., Yoshikawa, M., Yaoi, M., Sakiyama, Y., & Toda, T. (1989). A maxillary central incisor having two root canals geminated with a supernumerary tooth. *J Endod*, 15(4), 161-163.
- Jaju, P., & Jaju, S. (2015). Cone-beam computed tomography: Time to move from ALARA to ALADA. *Imaging science in dentistry*, 45(4).
- Kalogeropoulos, K., Solomonidou, S., Xiropotamou, A., & Eyuboglu, T. F. (2023). Endodontic management of a double-type IIIB dens invaginatus in a vital maxillary central incisor aided by CBCT: A case report. *Aust Endod J*, 49(2), 365-372.
- Kumar Gupta, S., Saxena, P., Khetarpal, S., & Solanki, M. (2015). Management of a Two-rooted Maxillary Central Incisor Using Cone-beam Computed Tomography: Importance of Three-dimensional Imaging. *J Dent Res Dent Clin Dent Prospects*, 9(3), 205-208.
- Lambruschini, G. M., & Camps, J. (1993). A two-rooted maxillary central incisor with a normal clinical crown. *J Endod*, 19(2), 95-96.
- Levin A, S. A., Katzenell V, Gottlieb A, Ben Itzhak J, Solomonov M. (2015). Use of Cone-beam Computed Tomography during Retreatment of a 2-rooted Maxillary Central Incisor: Case Report of a Complex Diagnosis and Treatment. *Journal of endodontics*, 41(12).
- Lin, W. C., Yang, S. F., & Pai, S. F. (2006). Nonsurgical endodontic treatment of a two-rooted maxillary central incisor. *J Endod*, 32(5), 478-481.
- Ludlow, J. B., Davies-Ludlow, L. E., Brooks, S. L., & Howerton, W. B. (2006). Dosimetry of 3 CBCT devices for oral and maxillofacial radiology: CB Mercuray, NewTom 3G and i-CAT. *Dentomaxillofac Radiol*, 35(4), 219-226.
- Mabrouk, R., Berzougua, L., & Frih, N. (2021). The Accuracy of CBCT in the Detection of Dens Invaginatus in a Tunisian Population. *Int J Dent*, 2021, 8826204.
- Mader CL, K. J. (1980). Double-rooted maxillary central incisor. *Oral surgery, oral medicine, and oral pathology*, 50(1).
- Nagendrabadu, V., Chong, B. S., McCabe, P., Shah, P. K., Priya, E., Jayaraman, J., et al. (2020). PRICE 2020 guidelines for reporting case reports in Endodontics: a consensus-based development. *Int Endod J*, 53(5), 619-626.
- Nunes, E. (2020). Tratamento endodôntico de incisivo lateral superior com duas raízes: relato de caso. In M. A. B. d. Sá (Ed.), *Silveira, Frank Ferreira* (Vol. 10, pp. 62-67). *Dent. press endod: Ilus.*
- Patterson, J. (1970). Bifurcated root of upper central incisor. *Oral surgery, oral medicine, and oral pathology*, 29(2).
- Pereira A. S. et al. (2018). Metodologia da pesquisa científica. UFSM.
- Rao Genovese F, M. E. (2003). Maxillary central incisor with two roots: a case report. *Journal of endodontics*, 29(3).
- S Jajoo, S. (2017). Primary Maxillary Bilateral Central Incisors with Two Roots. *Int J Clin Pediatr Dent*, 10(3), 309-312.
- Setzer, F. C., & Lee, S. M. (2021). Radiology in Endodontics. *Dent Clin North Am*, 65(3), 475-486.
- Sponchiado, E. C., Jr., Ismail, H. A., Braga, M. R., de Carvalho, F. K., & Simões, C. A. (2006). Maxillary central incisor with two root canals: a case report. *J Endod*, 32(10), 1002-1004.
- Vertucci, F. J. (1984). Root canal anatomy of the human permanent teeth. *Oral Surg Oral Med Oral Pathol*, 58(5), 589-599.
- Vinothkumar, T. S., Kandaswamy, D., Arathi, G., Ramkumar, S., & Felsypremila, G. (2017). Endodontic Management of Dilacerated Maxillary Central Incisor fused to a Supernumerary Tooth using Cone Beam Computed Tomography: An Unusual Clinical Presentation. *J Contemp Dent Pract*, 18(6), 522-526.