

## Should we be concerned about accessory mandibular foramina and canals? A cone-beam computed tomography study

Devemos nos preocupar com forames e canais mandibulares acessórios? Um estudo com tomografia computadorizada de feixe cônico

¿Debemos preocuparnos por los forámenes y conductos mandibulares accesorios? Un estudio con tomografía computarizada de haz cónico

Received: 08/07/2023 | Revised: 08/20/2023 | Accepted: 08/21/2023 | Published: 08/24/2023

**Maria Clara Avila de Oliveira**

ORCID: <https://orcid.org/0000-0002-4381-3103>  
Professor Edson Antônio Velano University, Brazil  
Email: [clarinha.oliveira.mca@gmail.com](mailto:clarinha.oliveira.mca@gmail.com)

**Marilza do Carmo Oliveira**

ORCID: <https://orcid.org/0000-0001-6072-4180>  
RD Digital – Dental Diagnostic Services, Brazil  
Email: [radiografias.dentarias@hotmail.com](mailto:radiografias.dentarias@hotmail.com)

**Bruno Henrique Figueiredo Matos**

ORCID: <https://orcid.org/0009-0003-6717-1541>  
Pontifical Catholic University of Minas Gerais, Brazil  
Email: [brunomatos@pucpcaldas.br](mailto:brunomatos@pucpcaldas.br)

**Alexandre Augusto Sarto Dominguetto**

ORCID: <https://orcid.org/0000-0002-3346-0586>  
Professor Edson Antônio Velano University, Brazil  
Email: [alexandre.dominguetto@gmail.com](mailto:alexandre.dominguetto@gmail.com)

### Abstract

**Objective:** Analyze the prevalence of mandibular accessory foramina and canals using cone-beam computed tomography (CBCT). **Methodology:** 136 mandibles divided into 10 predetermined areas were analyzed through CBCT looking for accessory foramina and canals. The Chi-square and Wilcoxon tests were used. **Results:** We found 1.316 accessory foramina, which 486 were accompanied by canals. 70.3% of accessory foramina were on the internal mandibular surface, most below the mylohyoid line and genial tubercles. The M1 area had the highest number of foramina, especially in the internal surface. The right mandibular side revealed a significantly greater number of foramina when compared to the left side. The mean diameter of accessory foramina analyzed was 0.85mm. Most of the accessory canals were on the internal mandibular surface, with a longer average length when compared to external surface canals. **Conclusion:** Our study showed that more detailed studies of accessory mandibular foramina and canals should be carried out, since a high prevalence of these structures and they have not named or classified yet. Furthermore, procedures that reach the internal mandibular surface, especially the anterior region, may be more subject to complications, as well as failure of anesthetic blocks on the right side of the mandible.

**Keywords:** Mandible; Anatomic variation; Cone-Beam Computed Tomography.

### Resumo

**Objetivo:** Analisar a prevalência de forames e canais acessórios mandibulares através de tomografia computadorizada de feixe cônico (TCFC). **Metodologia:** 136 mandíbulas divididas em 10 áreas pré-determinadas foram analisadas através de TCFC a procura de forames e canais acessórios. Foram utilizados os testes de Qui-quadrado e Wilcoxon. **Resultados:** Encontramos 1.316 forames acessórios, no qual 486 estavam acompanhados também por canais. 70.3% dos forames estavam localizados na superfície interna mandibular, a maioria abaixo da linha milo-hióidea e tubérculos genianos. A área M1 apresentou o maior número de forames, especialmente sua face interna. O lado direito mandibular revelou significativamente maior número de forames quando comparado ao lado esquerdo. O diâmetro médio dos forames analisados foi de 0.85mm. A maioria dos canais acessórios se encontrava na superfície interna mandibular, com uma média de comprimento maior quando comparada aos canais da superfície externa. **Conclusão:** Concluímos que estudos mais detalhados sobre forames e canais acessórios devem ser realizados, visto que a prevalência de tais estruturas na mandíbula é alta, e esses ainda não foram nomeados ou classificados. Além disso, procedimentos que atinjam a superfície interna mandibular, especialmente sua região anterior, podem estar mais sujeitos a complicações, assim como falhas de bloqueios anestésicos no lado direito da mandíbula.

**Palavras-chave:** Mandíbula; Variação anatômica; Tomografia Computadorizada de Feixe Cônico.

## Resumen

**Objetivo:** Analizar la prevalencia de foramen y conductos mandibular accesorios mediante tomografía computarizada de haz cónico (TCHC). **Metodología:** 136 mandíbulas divididas en 10 áreas predeterminadas fueron analizadas por TCHC en busca de forámenes y conductos accesorios. Se utilizaron las pruebas de Chi-cuadrado y Wilcoxon. **Resultados:** Encontramos 1.316 forámenes accesorios, de los cuales 486 también estaban acompañados de canales. El 70,3% de los forámenes se ubicaron en la superficie mandibular interna, la mayoría por debajo de la línea milohioidea y tubérculos geniales. El área M1 tenía el mayor número de forámenes, especialmente su superficie interna. El lado mandibular derecho reveló un número significativamente mayor de forámenes en comparación con el lado izquierdo. El diámetro medio de los forámenes analizados fue de 0,85mm. Los forámenes mentonianos eran más grandes en el lado derecho. La mayoría de los conductos accesorios se ubicaron en la superficie mandibular interna, con una longitud promedio mayor en comparación con los conductos de la superficie externa. **Conclusión:** Concluimos que se deben realizar estudios más detallados sobre los forámenes e conductos accesorios, ya que la prevalencia de este tipo de estructuras en la mandíbula es alta y aún no han sido nombradas ni clasificadas. Además, los procedimientos que alcanzan la superficie mandibular interna, especialmente su región anterior, pueden estar más sujetos a complicaciones, así como fallas en los bloqueos anestésicos en el lado derecho de la mandíbula.

**Palabras clave:** Mandíbula; Variación anatómica; Tomografía Computarizada de Haz Cónico.

## 1. Introduction

Accessory foramina and canals in mandibles are all apertures in this bone, except the tooth sockets, mental and mandibular foramen (Sutton, 1974). These foramina are usually not observed with conventional radiographic techniques (Sisman, 2012), better detected in cone beam computed tomography (CBCT) (Katakami et al., 2018). The unintentional injury of its contents (vessels and nerves) can lead to complications such as hemorrhages, sensory losses, and development of neuromas (Przystanska & Bruska, 2012; Mendonza et al., 2004). These foramina can serve as a route for tumor metastasis (Murlimanju et al., 2011) and invasion of tumor cells on the mandibular surface (Fanibunda & Matthews, 1999).

Anesthetic blocks are subject to failures, whose causes can be technical, pharmacological, or anatomical (Meyer et al., 2007). Failures in inferior alveolar nerve block are frequent, deriving from the anatomical variability of the mandibular bone and surrounding soft tissues, which includes accessory foramina and canals (Bremer, 1952; Frommer et al., 1972; Rood, 1977; Wilson et al., 1984). Studies report accessory branches that directly innervate to lower teeth, passing through these foramina, justifying anesthetic failures (Murlimanju et al., 2011; Stein et al., 2007). However, some authors have studied the presence of mandibular accessory foramina (Sutton, 1974; Przystanska & Bruska, 2012; Stein et al., 2007; Soto et al., 2012), and have no specific classification or nomenclature (Przystanska & Bruska, 2012).

This study aims to evaluate the prevalence of accessory foramina and canals in human mandibles through predetermined areas and measure their diameter and length.

## 2. Methodology

### Ethical Approval

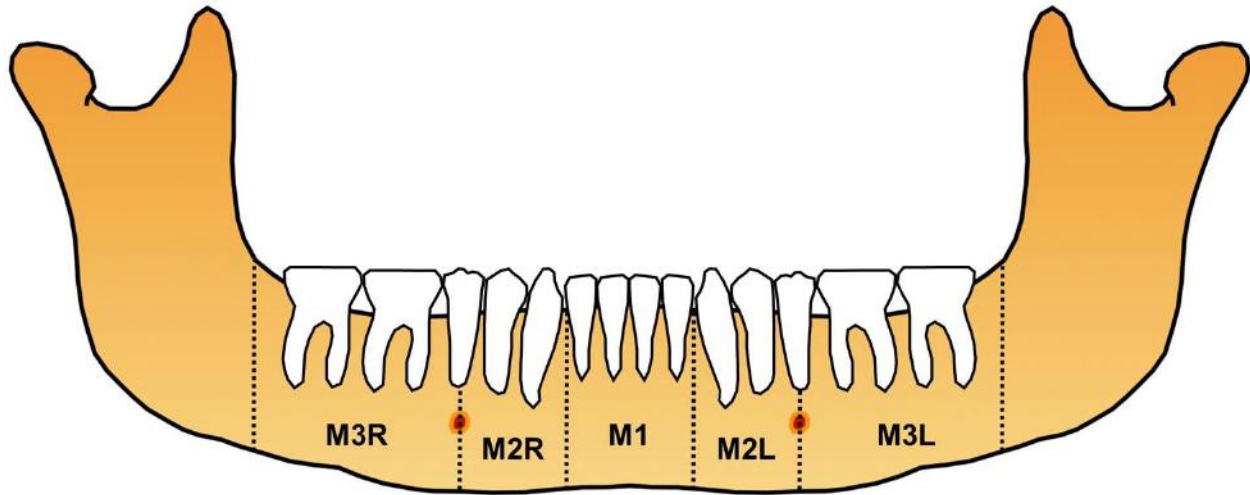
This study was approved by the Ethics Committee of Professor Edson Antônio Velano University (UNIFENAS), Alfenas, Brazil (CAAE:60611722.5.0000.5143).

### Mandible Division

The mandible division was based in Muley et al. (2022) study. The mandible was divided into 10 areas (Figure 1). The division of these areas were identical in internal and external surface (5 areas/surface). The distal of the lower lateral incisors, the mental foramen and the ascending branch were used as anatomical parameters. Anterior mandible region corresponding to the M1 area. The M2 area comprises the parasymphysis region (distal of the lateral incisor to the mental

foramen). The M3 area was determined as the posterior region to the mental foramen. Furthermore, we divided these areas into external (buccal) and internal (lingual) surface, and M2 and M3 areas into right (R) and left (L) sides.

**Figure 1** - Proposed classification of accessory foramina and canals in the mandibular arch by areas.



Mandibular area: M3R - right posterior region to the mental foramen; M2R - right parasymphysis region (distal of the lateral incisor to the mental foramen); M1 - anterior mandible region; M2L - left parasymphysis region (distal of the lateral incisor to the mental foramen); M3L - left posterior region to the mental foramen. These areas were analyzed both on the external (buccal) and internal (lingual) surfaces. Source: Authors.

### Mandible Analysis

The mandibles were analyzed using CBCT obtained from a Specialized Radiological Center in Varginha, Minas Gerais, Brazil. Images with distortion or overlapping, patients with a history of mandibular trauma, craniofacial malformations or syndromes were excluded. Patients >18 y.o., male/female, with all inferior teeth were included. The CBTC images were obtained at 87kV and 8 mA, with a scan time within an interval of 8,01 to 8,655 seconds, with a voxel size of 180  $\mu$ m and slice thickness of 0,180 mm. The sections obtained in the sagittal, axial and coronal planes, and each multiplanar data measuring 180  $\times$  180  $\times$  180  $\mu$ m pixels at 16 bits were stored in the computer. Detailed analysis of the foramina and accessory canals was performed using CS 3D software. The curved slicing mode was used for the evaluation and inspection of the images, being employed the cross-sectional view, using as a guideline the sagittal section where these structures are in evidence. The contrast and density of the CT scans were modified for better visualization of the canals and accessory foramina. The location, quantity, and diameter (or length) of the accessory foramina and canals in each area were noted. The diameter of the mental foramina was also analyzed, as well as the accessory foramina in this region, considered as accessory mental foramina. In addition, the foramina were considered above or below the genial tubercles and mylohyoid line. This study is laboratorial quantitative research.

### Statistical Analysis

Descriptive measures such as minimum, maximum, median, interquartile range, mean and standard deviation (s.d.) and percentages were presented as measures to describe variable results. The Chi-square test was used to compare the mandibular areas by accessory foramina and canals prevalence. The Wilcoxon test was used to compare two measurements performed in the same sample unit. A p value <.05 was considered statistically significant for all analyses, which were performed with SPSS v21.0 software (IBM Corporation, New York, NY, USA).

### 3. Results

One thousand three hundred and sixteen accessory foramina were found in 136 mandibles. Table 1 represents the average of foramina by mandibular area. The internal surface showed 925 (70.3%) foramina, the majority (n = 743, 80.3%) below the mylohyoid line and genial tubercles. Furthermore, 61.0% (n = 802) of the mandibles had at least 3 accessory foramina at the internal surface. The M1 area showed a significant number of foramina (n = 529, 40.2%) compared to the other areas (p <0.001). Besides, the M1 internal area showed the highest number of foramina (n= 401, 30.5%), being significantly compared to the other areas (p <0.001). Still on the internal surface, there was a significant difference between the M2R and M3L areas (p <0.001), with greater number of foramina on the right side (n = 231) (Table 2).

**Table 1** - Number of foramina identified by mandibular area.

Mandibular Area	Accessory Foramina		
	External Surface	Internal Surface	Total
<b>M3R</b>			
Min-Max*	0.0 – 4.0	0.0 – 7.0	0.0 – 9.0
Mean ± s.d.**	0.5 ± 0.8	1.0 ± 1.2	1.5 ± 1.4
Median (P <sub>25</sub> ; P <sub>75</sub> )	0.0 (0.0; 1.0)	1.0 (0.0; 2.0)	1.0 (0.0; 2.0)
<b>M2R</b>			
Min-Max	0.0 – 3.0	0.0 – 4.0	0.0 – 7.0
Mean ± s.d.	0.5 ± 0.7	1.2 ± 1.1	1.7 ± 1.3
Median (P <sub>25</sub> ; P <sub>75</sub> )	0.0 (0.0; 1.0)	1.0 (0.0; 2.0)	2.0 (1.0; 3.0)
<b>M1</b>			
Min-Max	0.0 – 6.0	0.0 – 7.0	0.0 – 9.0
Mean ± s.d.	0.9 ± 1.2	2.9 ± 1.4	3.9 ± 1.8
Median (P <sub>25</sub> ; P <sub>75</sub> )	1.0 (0.0; 1.0)	3 (2.0; 4.0)	4.0 (2.3; 5.0)
<b>M2L</b>			
Min-Max	0.0 – 3.0	0.0 – 4.0	0.0 – 5.0
Mean ± s.d.	0.6 ± 0.8	0.7 ± 0.8	1.3 ± 1.2
Median (P <sub>25</sub> ; P <sub>75</sub> )	0.0 (0.0; 1.0)	1 (0.0; 1.0)	1 (0.0; 2.0)
<b>M3L</b>			
Min-Max	0.0 – 2.0	0.0 – 5.0	0.0 – 6.0
Mean ± s.d.	0.3 ± 0.6	0.9 ± 1.1	1.2 ± 1.2
Median (P <sub>25</sub> ; P <sub>75</sub> )	0.0 (0.0; 1.0)	1.0 (0.0; 1.0)	1.0 (0.0; 2.0)

\*Minimum-Maximum. \*\*Standard Deviation. Source: Authors.

**Table 2** - Comparative analysis between the mandibular areas and the number of foramina.

Mandibular Areas	Accessory Foramina		
	External Surface	Internal Surface	Total
<b>M3R</b>			
Mean ± s.d.*	0.5 ± 0.8	1.0 ± 1.2	1.5 ± 1.4
Median (P <sub>25</sub> ; P <sub>75</sub> )	0.0 (0.0; 1.0)	1.0 (0.0; 2.0)	1.0 (0.0; 2.0)
<b>M2R</b>			
Mean ± s.d.	0.5 ± 0.7	1.2 ± 1.1	1.7 ± 1.3
Median (P <sub>25</sub> ; P <sub>75</sub> )	0.0 (0.0; 1.0)	1.0 (0.0; 2.0)	2.0 (1.0; 3.0)
<b>M1</b>			
Mean ± s.d.	0.9 ± 1.2	2.9 ± 1.4	3.9 ± 1.8
Median (P <sub>25</sub> ; P <sub>75</sub> )	1.0 (0.0; 1.0)	3 (2.0; 4.0)	4.0 (2.3; 5.0)
<b>M2L</b>			
Mean ± s.d.	0.6 ± 0.8	0.7 ± 0.8	1.3 ± 1.2
Median (P <sub>25</sub> ; P <sub>75</sub> )	0.0 (0.0; 1.0)	1 (0.0; 1.0)	1 (0.0; 2.0)
<b>M3L</b>			
Mean ± s.d.	0.3 ± 0.6	0.9 ± 1.1	1.2 ± 1.2
Median (P <sub>25</sub> ; P <sub>75</sub> )	0.0 (0.0; 1.0)	1.0 (0.0; 1.0)	1.0 (0.0; 2.0)
p	< 0.001	< 0.001	< 0.001
Conclusion	<b>M1 &gt; M3R-M2R-M3L</b>	<b>M1 &gt; M3R-M2R-M3L-M2L M2R &gt; MDL</b>	<b>M1 &gt; M3R-M2R-M3L-M2L</b>

\*Standard Deviation. The significance refers to the Friedman test (p <0.05). Source: Authors.

In total, regarding mandibular right and left sides, the right side showed more foramina (n = 437, 33.2%) and was significant (p <0.001) compared to the left side (n = 350, 26.5%) (Table 3). Specifically, the M3R external and M2R internal areas showed a prevalence of foramina. Significant differences were identified on the external surface (p = 0.011), with a higher number of foramina in the M3R area (n = 71) compared to M3L area (n = 44). On the internal surface, the M2R area showed a greater number of foramina (n = 166) compared to the M3L area (n = 100). All mandibular areas analyzed had a greater number of foramina on the internal surface when compared to the external surface, even with significant results, except for the M2L area (p =0.241) (Table 4).

**Table 3 - Comparative analysis between right and left sides by mandibular areas and surfaces.**

Mandibular Area	Accessory Foramina		
	External Surface	Internal Surface	Total
<b>M3R</b>			
Mean ± s.d.*	0.5 ± 0.8	1.0 ± 1.2	1.5 ± 1.4
Median (P <sub>25</sub> ; P <sub>75</sub> )	0.0 (0.0; 1.0)	1.0 (0.0; 2.0)	1.0 (0.0; 2.0)
<b>M3L</b>			
Mean ± s.d.	0.3 ± 0.6	0.9 ± 1.1	1.2 ± 1.2
Median (P <sub>25</sub> ; P <sub>75</sub> )	0.0 (0.0; 1.0)	1.0 (0.0; 1.0)	1.0 (0.0; 2.0)
p	<b>0.011</b>	0.425	<b>0.034</b>
Conclusion	<b>M3R &gt; M3L</b>	M3R = M3L	<b>M3R &gt; M3L</b>
<b>M2R</b>			
Mean ± s.d.	0.5 ± 0.7	1.2 ± 1.1	1.7 ± 1.3
Median (P <sub>25</sub> ; P <sub>75</sub> )	0.0 (0.0; 1.0)	1.0 (0.0; 2.0)	2.0 (1.0; 3.0)
<b>M2L</b>			
Mean ± s.d.	0.6 ± 0.8	0.7 ± 0.8	1.3 ± 1.2
Median (P <sub>25</sub> ; P <sub>75</sub> )	0.0 (0.0; 1.0)	1 (0.0; 1.0)	1 (0.0; 2.0)
p	0.131	<b>&lt; 0.001</b>	<b>0.007</b>
Conclusion	M2R = M2L	<b>M2R &gt; M2L</b>	<b>M2R &gt; M2L</b>

\*Standard Deviation. The significance refers to the Wilcoxon test (p <0.05). Source: Authors.

**Table 4 - Comparative analysis between mandibular areas and surfaces.**

Mandibular Area	Accessory Foramina		p Conclusion
	External Surface (a)	Internal Surface (b)	
<b>M3R</b>			
Mean ± s.d.*	0.5 ± 0.8	1.0 ± 1.2	<b>&lt; 0.001</b>
Median (P <sub>25</sub> ; P <sub>75</sub> )	0.0 (0.0; 1.0)	1.0 (0.0; 2.0)	<b>a &lt; b</b>
<b>M2R</b>			
Mean ± s.d.	0.5 ± 0.7	1.2 ± 1.1	<b>&lt; 0.001</b>
Median (P <sub>25</sub> ; P <sub>75</sub> )	0.0 (0.0; 1.0)	1.0 (0.0; 2.0)	<b>a &lt; b</b>
<b>M2L</b>			
Mean ± s.d.	0.6 ± 0.8	0.7 ± 0.8	0.241
Median (P <sub>25</sub> ; P <sub>75</sub> )	0.0 (0.0; 1.0)	1 (0.0; 1.0)	a = b
<b>M3L</b>			
Mean ± s.d.	0.3 ± 0.6	0.9 ± 1.1	<b>&lt; 0.001</b>
Median (P <sub>25</sub> ; P <sub>75</sub> )	0.0 (0.0; 1.0)	1.0 (0.0; 1.0)	<b>a &lt; b</b>

\*Standard Deviation. The significance refers to the Wilcoxon test (p <0.05). Source: Authors.

Comparing the regions above the mylohyoid line (Tables 5-6), we identified that the M3R area had a significantly greater number of foramina (n = 76) compared to the M2R and M2L areas. Moreover, the left side showed significant differences between the M3 (n = 57) and M2 (n = 10) areas. In the regions below the mylohyoid line, the M2R area presented significant results, representing the highest number of accessory foramina. The right side also showed significant results, revealing a greater number of foramina in the M2 area when compared to the same area on the left side, regardless of whether

above or below the mylohyoid line. Still in the M2 area, regardless of the side, a greater number of foramina below the mylohyoid line was observed.

**Table 5** - Prevalence of foramina above and below the mylohyoid line.

Mandibular Area	Accessory Foramina	
	Above MHL*	Below MHL
<b>M3R</b>		
Min-Max**	0.0 – 4.0	0.0 – 6.0
Mean ± s.d.***	0.6 ± 0.8	0.4 ± 0.8
Median (P <sub>25</sub> ; P <sub>75</sub> )	0.0 (0.0; 1.0)	0.0 (0.0; 1.0)
<b>M2R</b>		
Min-Max	0.0 – 3.0	0.0 – 4.0
Mean ± s.d.	0.2 ± 0.6	1.0 ± 0.9
Median (P <sub>25</sub> ; P <sub>75</sub> )	0.0 (0.0; 0.0)	1.0 (0.0; 1.0)
<b>M2L</b>		
Min-Max	0.0 – 1.0	0.0 – 3.0
Mean ± s.d.	0.1 ± 0.3	0.7 ± 0.8
Median (P <sub>25</sub> ; P <sub>75</sub> )	0.0 (0.0; 0.0)	0.5 (0.0; 1.0)
<b>M3L</b>		
Min-Max	0.0 – 3.0	0.0 – 4.0
Mean ± s.d.	0.4 ± 0.7	0.5 ± 0.8
Median (P <sub>25</sub> ; P <sub>75</sub> )	0.0 (0.0; 1.0)	0.0 (0.0; 1.0)
p	<b>&lt; 0.001</b>	<b>&lt; 0.001</b>
Conclusion	<b>M3R &gt; M2R-M2L M3L &gt; M2L</b>	<b>M2R &gt; M2L-M3L-M3R</b>

\*Mylohyoid Line. \*\*Minimum-Maximum. \*\*\*Standard Deviation. The significance refers to the Friedman test (p <0.05). Source: Authors.

**Table 6** – Prevalence of foramina above and below the mylohyoid line.

Mandibular Area	Accessory Foramina		p Conclusion
	Above MHL* (a)	Below MHL (b)	
<b>M3R</b>			
Min-Max**	0.0 – 4.0	0.0 – 6.0	0.130
Mean ± s.d.***	0.6 ± 0.8	0.4 ± 0.8	a = b
Median (P <sub>25</sub> ; P <sub>75</sub> )	0.0 (0.0; 1.0)	0.0 (0.0; 1.0)	
<b>M2R</b>			
Min-Max	0.0 – 3.0	0.0 – 4.0	<b>&lt; 0.001</b>
Mean ± s.d.	0.2 ± 0.6	1.0 ± 0.9	<b>a &lt; b</b>
Median (P <sub>25</sub> ; P <sub>75</sub> )	0.0 (0.0; 0.0)	1.0 (0.0; 1.0)	
<b>M2L</b>			
Min-Max	0.0 – 1.0	0.0 – 3.0	<b>&lt; 0.001</b>
Mean ± s.d.	0.1 ± 0.3	0.7 ± 0.8	<b>a &lt; b</b>
Median (P <sub>25</sub> ; P <sub>75</sub> )	0.0 (0.0; 0.0)	0.5 (0.0; 1.0)	
<b>M3L</b>			
Min-Max	0.0 – 3.0	0.0 – 4.0	0.518
Mean ± s.d.	0.4 ± 0.7	0.5 ± 0.8	a = b
Median (P <sub>25</sub> ; P <sub>75</sub> )	0.0 (0.0; 1.0)	0.0 (0.0; 1.0)	

\*Mylohyoid Line. \*\*Minimum-Maximum. \*\*\*Standard Deviation. The significance refers to the Wilcoxon test (p <0.05). Source: Authors.

### Foramina Diameters

Concerning the accessory foramina diameter, the average was 0.9mm on the internal surface and 0.8mm on the external surface. The accessory mental foramina had the largest diameters, with an average of 3.5mm and 3.4mm on the right and left sides, respectively. No significant results were found about the accessory foramina, in contrast to the diameter of the mental foramen, which showed significant results, being greater on the right side.

### Accessory canals

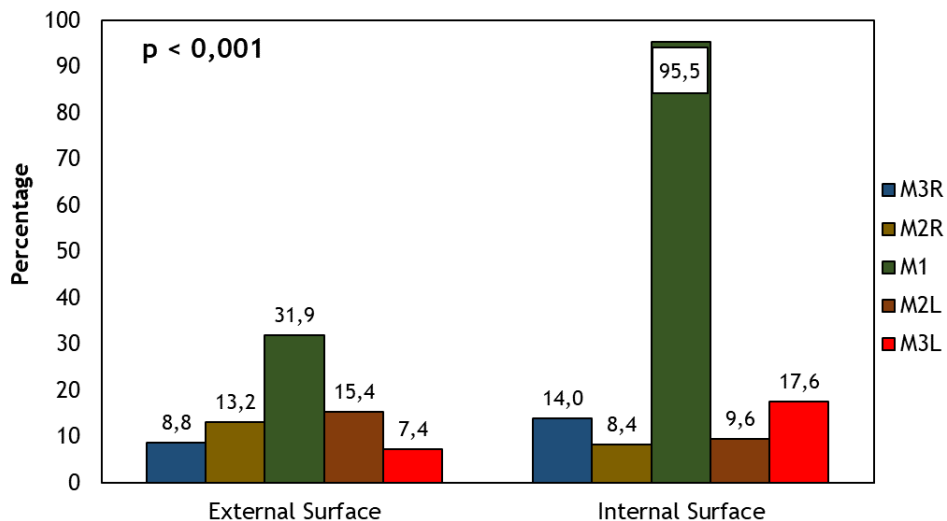
Regarding 1.316 foramina studied, 486 (37.0%) were accompanied by accessory canals, with 354 on the internal mandibular surface, representing most canals. The length (mean) of these canals on the internal surface was statistically superior compared to the canals on the external surface. The areas M1 and M3 at the internal surface showed a statistically greater length of accessory canals when compared to the same areas externally (Figure 2).

## 4. Discussion

In our study, we divided the mandible into ten main areas, including the symphysis, parasymphysis and the mandibular body, evaluating the external and internal surfaces. Concerning the 136 mandibles analyzed using CBCT, we found 1.316 accessory foramina (9.7 foramen/mandible). Muley et al. (2022) also analyzed the body and mandibular symphysis looking for accessory foramina using CBCT and showed 245 accessory foramina in 50 mandibles (4.9 foramen/mandible). Sutton in 1974 revealed a total of 2.449 accessory foramina observed in 300 mandibles, an average of 8.1 foramen per mandible, and even including the mandibular ramus in his analysis, he showed a slightly smaller average of foramina. Fanibunda and Matthews returned to the subject on two occasions (1999 and 2000), having observed 1.121 accessory foramina in 89 mandibles (12.5 foramen/mandible). Haveman and Tebo (1976), even excluding the symphysis region, found a greater number of accessory foramina, an average of 35.5 foramina per mandible, about 5.332 foramina in 150 bones. We emphasize that the number of foramina found by these two authors could be even greater, since in our study the M1 area, corresponding to the symphysis, presented the highest prevalence of accessory foramina. It is possible that these variations in the average number of foramina, when comparing different studies, can be explained by some factors such as population variations (Muley et al. studied Indian mandibles; Sutton used mandibles predominantly from Australian aborigines; Haveman and Tebo, although they carried out their work in Texas, USA, used mandibles imported from India; Fanibunda and Matthews carried out their study in the north of England), the bone condition and the method of analysis (dry mandible or CBCT).

In addition, the studies differ about the areas analyzed. Sutton (1974) and Fanibunda and Mathews (1999 and 2000) analyzed the entire mandibular extension. Haveman and Tebo (1976) however, excluded an important part of the mandible in their experiment, studying only the regions posterior to the second premolar. In our study, like Muley et al. (2022), only ramus was not analyzed, giving greater importance to the toothed areas.

**Figure 2 - Presence of accessory canals by mandibular area.**



The significance refers to the Chi-square test ( $p < 0.05$ ). Source: Authors.

Sisman et al. (2012) studied accessory foramina in the mental foramen area, finding 14 foramina in 504 mandibles, and observing a greater number in the posteroinferior region of the mental foramen. Katakami et al. (2008), after studying the same region, observed 17 accessory mental foramina in 150 mandibles, and most of the foramina found were in the posterior region of the mental foramen. In our analysis, 11 accessory mental foramina were found, the majority posterior to the mental foramen (n = 6, 54.5%), corroborating the authors. This fact deserves attention, especially in dentoalveolar and aesthetic-functional surgeries, such as the miniplates fixation for orthodontic anchorage and orthognathic surgeries, where the insertion is performed posteriorly to the mental foramen. In addition, accessory foramina in this region had the largest diameters (about 4x) compared to foramina in other areas.

Przystanska and Bruska (2012) studied only the internal surface of the mandibular symphysis and observed 700 accessory foramina in 397 cases, the majority above the genial tubercles. Soto et al. (2012) also studied this region and, of the 160 accessory foramina found, 82.0% (n = 131) were above the genial tubercles. Still in 2012, Murlimanju et al. published that 95.5% of the mandibles had foramina belonging to this region, with most of the foramina also above these structures. Particularly, the M1 area of our study (corresponding to the mandibular symphysis), showed the highest number of foramina (n = 529, 40.2%), especially in the internal surface, revealing 401 foramina, representing 30.5% of the total found. However, unlike the authors, we found most foramina below the genial tubercles (TAB). Muley et al. (2022) found similar results, which 89.0% of the foramina found were in the anterior region of the mandible, the majority (76.0%) on the lingual surface and below the genial tubercles. Failures in the anesthetic blockade in these areas of the mandible can be explained by the presence of these foramina, and through them nervous vascular bundles pass, such as branches of the mylohyoid nerve, often innervating the lower teeth (Madeira et al., 1978; Stein et al., 2007).

Regarding the molars and premolars region, Muley et al. (2022) found more foramina on the right side compared to the left side. Similar manner in our study revealed significantly more foramina on the right side in areas M2 and M3. In addition, the M2 areas showed a greater number of foramina on the internal surface, as well as the results published by these authors. However, analyzing only the left side, these researchers found more foramina on the external mandibular surface, diverging from our study. Narayana and Prashanthi (2003) mentioned the presence of an accessory mandibular foramen with 10.0mm in diameter, nevertheless accessory foramina with this diameter are not routinely found in the literature (Sutton, 1974; Haveman and Tebo, 1976; Soto et al., 2012). In our research, the areas analyzed also did not show large diameter foramina, and despite the non-significant results, the mental accessory foramina had the largest diameters.

## 5. Conclusion

Our study showed that more detailed studies of accessory mandibular foramina and canals should be carried out, since a high prevalence of these structures and they have not named or classified yet. Furthermore, procedures that reach the internal mandibular surface, especially the anterior region, may be more subject to complications, as well as failure of anesthetic blocks on the right side of the mandible.

## Acknowledgments

The authors thank the Professor Edson Antônio Velano University – UNIFENAS, for providing the facilities and staff necessary for this experiment. Also, the authors express appreciation to the Brazilian Funding Agency FAPEMIG (Fundação de Amparo à Pesquisa do Estado de Minas Gerais) for providing the fellowship.



## References

- Bremer, G. (1952). Measurements of special significance in connection with anesthesia of the inferior alveolar nerve. *Oral Surgery, Oral Medicine, Oral Pathology*, 5, 966–988.
- Fanibunda, K. & Matthews, J. N. S. (1999). Relationship between accessory foramina and tumor spread in the lateral mandibular surface. *Journal of Anatomy*, 195, 185-190.
- Fanibunda, K. & Matthews, J. N. S. (2000). The relationship between accessory foramina and tumor spread on the medial mandibular surface. *Journal of Anatomy*, 196, 23-29.
- Frommer, J., Mele, F. A., & Monroe, C. W. (1972). The possible role of the mylohyoid nerve in mandibular posterior tooth sensation. *Journal of the American Dental Association*, 85, 113–117.
- Haveman, C. W. & Tebo, H. G. (1976). Posterior accessory foramina of the human mandible. *Journal of Prosthetic Dentistry*, 35, 462-468.
- Katakami, K., Mishima, A., Shiozaki, K., Shimoda, S., Hamada, Y., & Kobayashi, K. (2008). Characteristics of accessory mental foramina observed on limited cone-beam computed tomography images. *Journal of Endodontics*, 34, 1441-1445.
- Madeira, M. C., Percinoto, C., & Silva, M. G. M. (1978). Clinical significance of supplementary innervation of the lower incisor teeth: A dissection study of mylohyoid nerve. *Oral Surgery, Oral Medicine, Oral Pathology*, 46, 608-614.
- Mendoza, C. C., Vasconcelos, B. C. E., Sampaio, G., Cauás, M., & Batista, J. E. M. (2004). Localização topográfica do forame mandibular: estudo comparativo em mandíbulas humanas secas. *Revista de Cirurgia e Traumatologia Buco-Maxilo-Facial*, 4(2), 137-142.
- Meyer, T. N., Lemos, L. M., Nascimento, C. N. M., & Lellis, W. R. R. (2007). Effectiveness of nasopalatine nerve block for anesthesia of maxillary central incisors after failure of the anterior superior alveolar nerve block technique. *Brazilian Dental Journal*, 18, 69-73.
- Muley P., Kale L., Choudhary S., Aldhuwayhi S., Thakare A., & Mallineni S.K. (2022). Assessment of accessory canals and foramina in the mandibular arch using cone-beam computed tomography and a new classification for mandibular accessory canals. *Biomed Res Int*, 2022, 5542030. <https://doi.org/10.1155/2022/5542030>.
- Murlimanju, B. V., Prabhu, L. V., & Prameela, M. D. (2011). Accessory mandibular foramina: prevalence, embryological basis, and surgical implications. *Journal of Clinical and Diagnostic Research*, 5, 1137-1139.
- Narayana, K. & Prashanthi, N. (2003). Incidence of large accessory mandibular foramen in human mandibles. *European Journal of Anatomy*, 7, 139-141.
- Przystanska, A., & Bruska, M. (2010). Accessory mandibular foramina: histological and immunohistochemical studies of their contents. *Archives of Oral Biology*, 55, 77-80.
- Przystanska, A. & Bruska, M. (2012). Anatomical classification of accessory foramina in human mandibles of adults, infants, and fetuses. *Anatomical Science International*, 87, 141-143.
- Rood, J. P. (1977). The nerve supply of the mandibular incisor region. *British Dental Journal*, 143, 227–230.
- Sisman, Y., Sahman, H., Sekerci, A. E., Tokmak, T. T., Aksu, Y., & Mavili, E. (2012). Detection and characterization of the mandibular accessory foramen using CT. *Dentomaxillofacial Radiology*, 41, 558-563.
- Soto, R., Cáceres, F., & García, R. (2012). Presencia y morfometría de forámenes y canales en relación a las espinas mentonianas. *International Journal of Morphology*, 30 (2), 417-421.
- Stein, P., Brueckner, J. & Milliner, M. (2007). Sensory innervation of mandibular teeth by the nerve to the mylohyoid: implications in local anesthesia. *Clinical Anatomy*, 20, 591-595.
- Sutton, R. N. (1974). The practical significance of mandibular accessory foramina. *Australian Dental Journal*, 19, 167-173.
- Wilson, S., Johns, P. I., & Fuller, P. M. (1984). Accessory innervation of mandibular anterior teeth in cats. *Brain Research*, 298, 392–396.